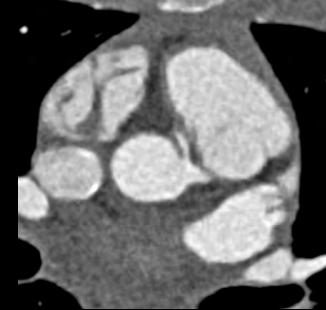



Scanner des cardiopathies congénitales



Dr Volodia Dangouloff-Ros

*Service de Radiopédiatrie
du Pr Boddaert
Hôpital Necker, Paris, France*



Programme



Programme

- Avantages, Inconvénients → Indications
- Technique de réalisation et d'interprétation
- Exemples



Avantages, Inconvénients → Indications



Avantages, Inconvénients → Indications

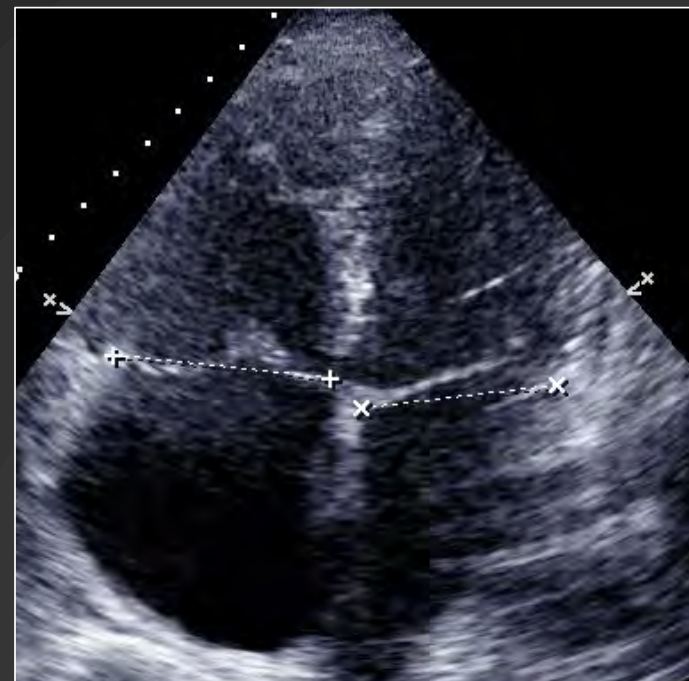- Comparaison à l'échographie:

- Avantages:

- Pas gêné par les poumons
 - Visualisation 3D
 - Résolution spatiale
 - Relecture aisée (moins opérateur dépendant)

- Inconvénients:

- Besoin d'immobilité (quelques minutes)
 - Pas d'image de flux
 - Etude limitée des valves et des CIA/CIV
 - Rayonnements ionisants



Avantages, Inconvénients → Indications

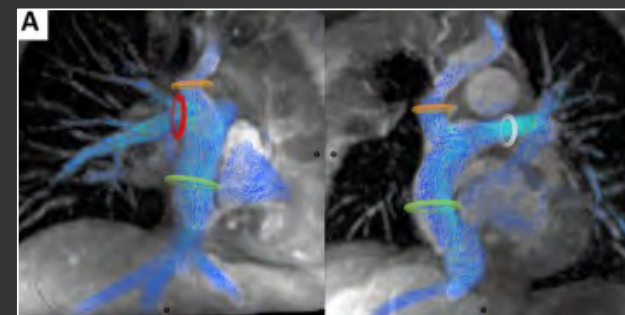
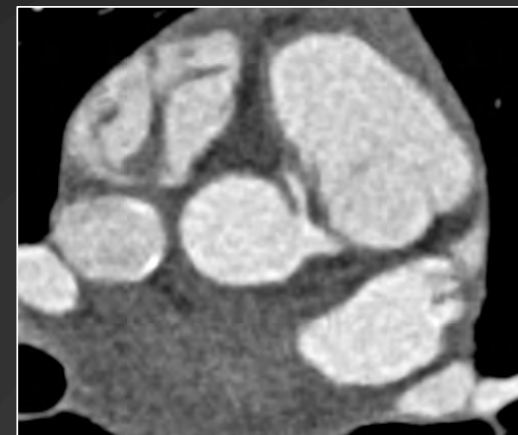
- Comparaison à l'IRM:

- Avantages:

- Résolution spatiale (petits vaisseaux)
 - Rapidité d'acquisition
 - Disponibilité
 - Moins artéfacté par le matériel chirurgical

- Inconvénients:

- Pas d'imagerie dynamique (ciné, flux)
 - Pas d'image de rehaussement
 - Rayonnements ionisants



Avantages, Inconvénients → Indications

- Indications:
 - Imagerie vasculaire:
 - Coronaires
 - Artères pulmonaires, aorte, veines caves et pulmonaires
 - Montages chirurgicaux
 - Cardiopathies complexes:
 - Anatomie vasculaire
 - Rapports anatomiques
 - Extracardiaque:
 - Collections médiastinales, péri-valvulaires
 - Retentissement pulmonaire, trachéal

Technique de réalisation



Technique de réalisation

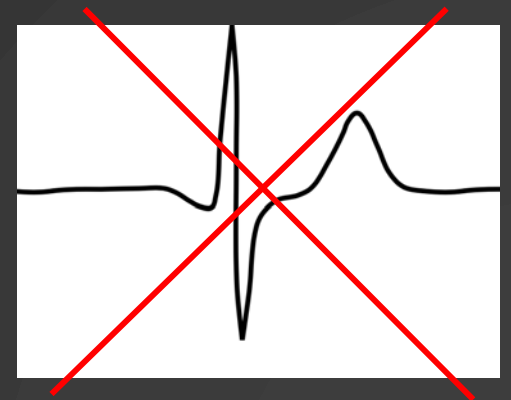
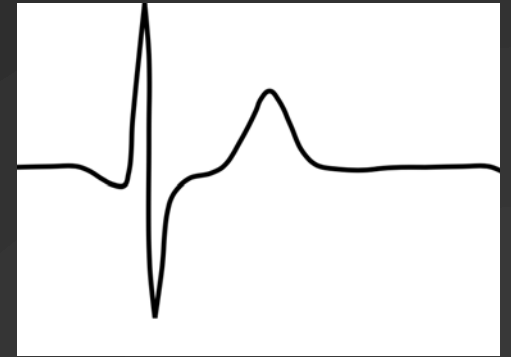
- Où ?
 - Où les manipulateurs ont l'habitude de la pédiatrie
 - Où les manipulateurs / radiologues savent faire
- Sur quel scanner ?
 - La majorité... si le module cardio est disponible
 - Différences de rapidité d'acquisition, de « boîtes », de qualité

Technique de réalisation

- Synchronisation
- Injection
- Apnée
- Sédation

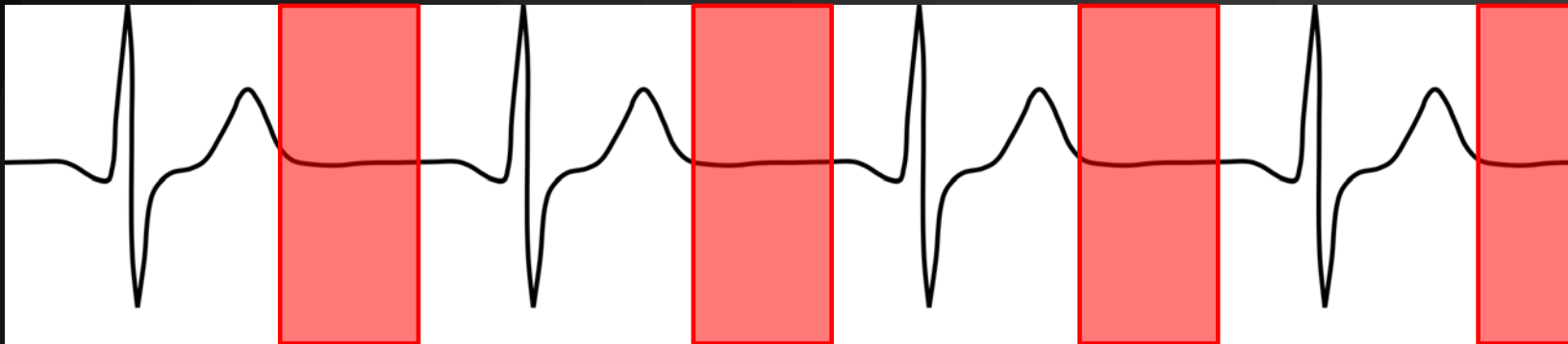
Technique de réalisation

- Quelle acquisition : Gating ou sans gating ?
 - Gating = Synchronisation à l'ECG (\approx coroscanner)
 - Avec des électrodes reliées au scanner
 - Pour les structures très mobiles
 - Nécessite un savoir-faire paramédical
 - Sans gating = Angioscanner « standard »
 - Sans électrodes
 - Pour structures peu mobiles
 - Faisable partout



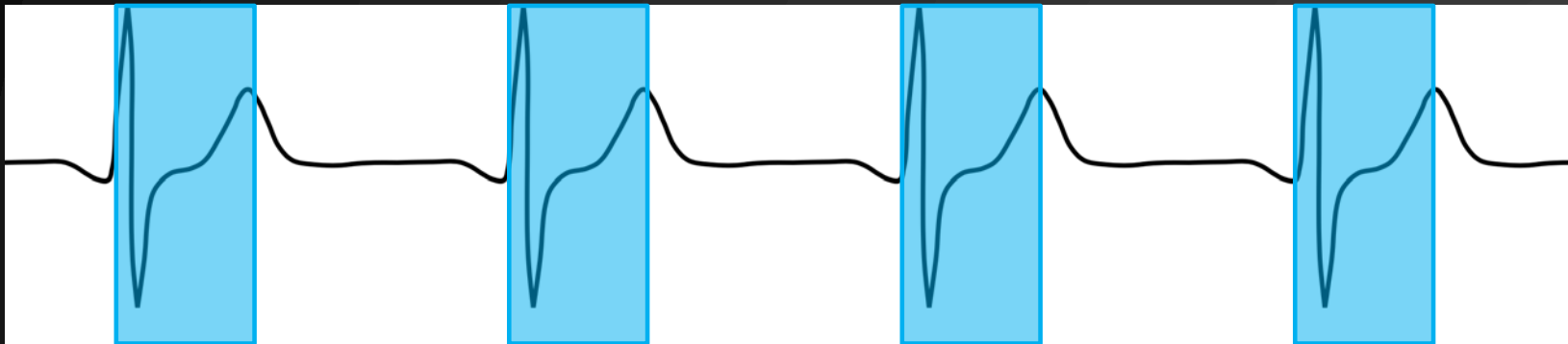
Technique de réalisation

- Acquisition avec gating cardiaque
 - Synchronisation à l'ECG
 - Acquisition pendant une partie du cycle cardiaque
 - < 75 bpm : diastole



Technique de réalisation

- Acquisition avec gating cardiaque
 - Synchronisation à l'ECG
 - Acquisition pendant une partie du cycle cardiaque
 - < 75 bpm : diastole
 - > 75 bpm : systole
- (pour remplissage coronaire optimal)



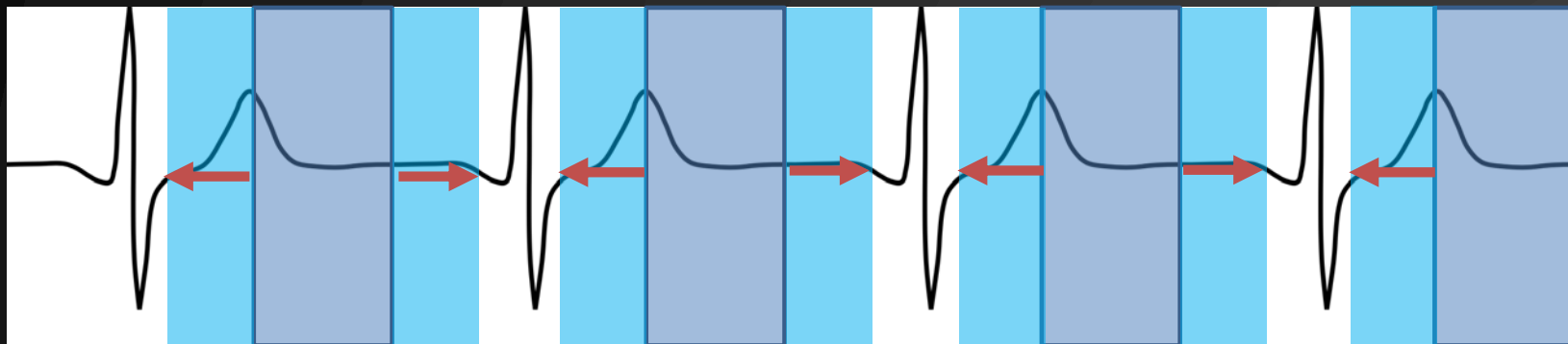
Technique de réalisation

- Acquisition avec gating cardiaque

- Pading :

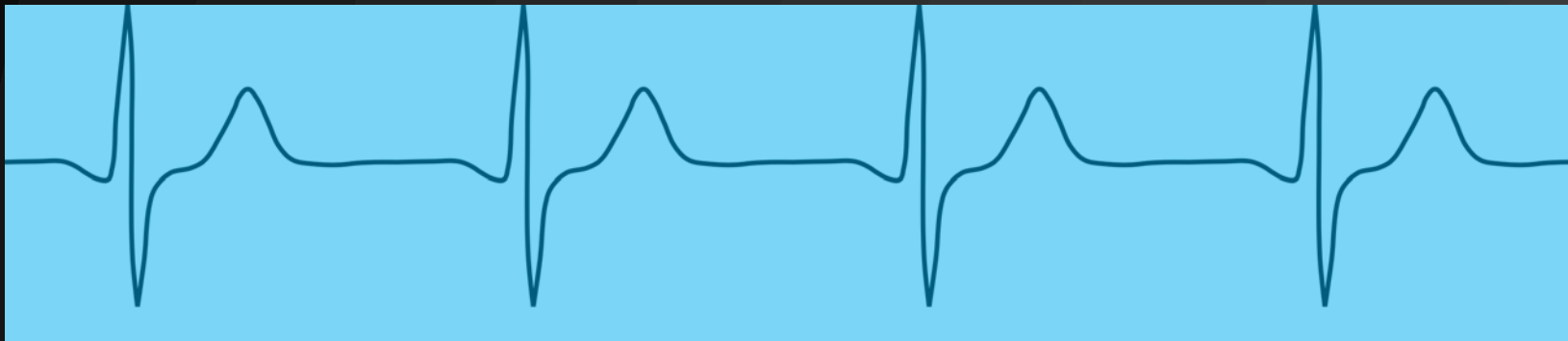
- = Remplissage dynamique

- Extension de l'acquisition aux phases adjacentes
 - Permet de reconstruire des phases intermédiaires entre systole et diastole
 - Utile si on a peur de rater l'acquisition : plusieurs chances



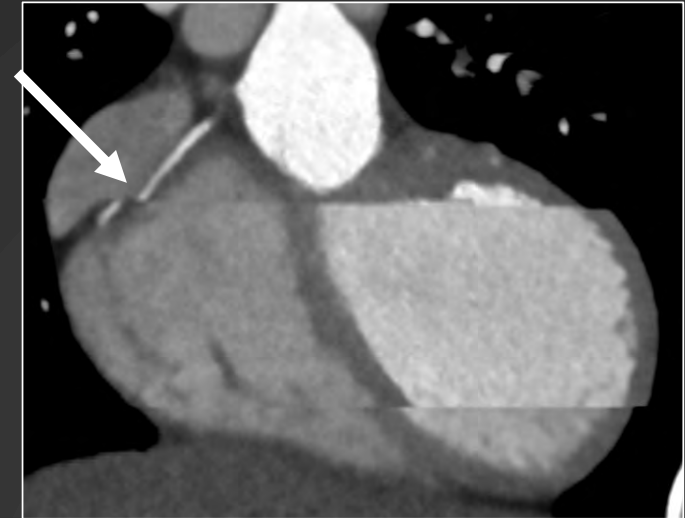
Technique de réalisation

- Acquisition avec gating cardiaque
 - Pading « extrême » = Acquisition « rétrospective »
 - = Acquisition de tout le cycle cardiaque
 - Permet de reconstruire toutes les phases
 - Donc permet de mesurer les volumes et fonctions cardiaques
 - MAIS : très irradiant, donc EXCEPTIONNEL chez l'enfant



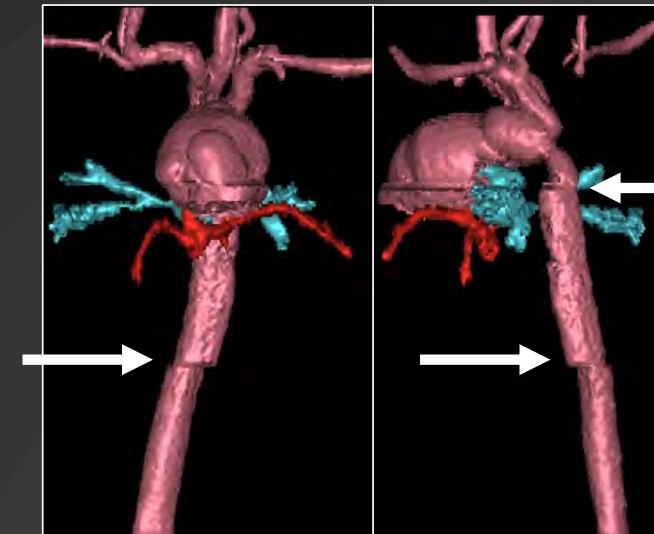
Technique de réalisation

- Acquisition avec gating cardiaque
 - Problèmes:
 - Acquisition pendant une partie du cycle cardiaque
 - Fonctionne si rythme cardiaque régulier
 - Si irrégulier : se trompe sur le moment de la diastole
 - Rythme rapide : pas un problème si régulier
 - Ne peut pas toujours acquérir tout le cœur en une fraction de cycle cardiaque (quelques ms)
 - plusieurs « boîtes »
 - Densité du produit de contraste variable
 - Mouvements entre les boîtes
 - Influence variable **selon la génération de scanner** (rapidité, largeur des boîtes)



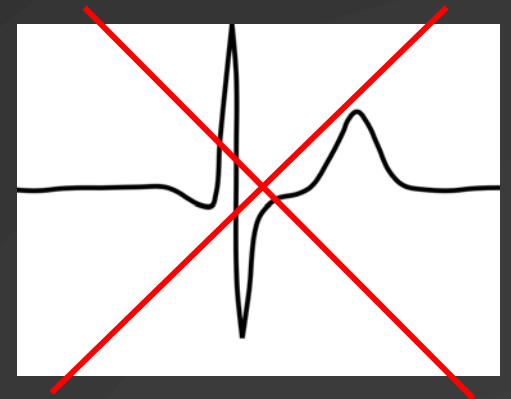
Technique de réalisation

- Acquisition avec gating cardiaque
 - Problèmes:
 - Acquisition pendant une partie du cycle cardiaque
 - Fonctionne si rythme cardiaque régulier
 - Si irrégulier : se trompe sur le moment de la diastole
 - Rythme rapide : pas un problème si régulier
 - Ne peut pas toujours acquérir tout le cœur en une fraction de cycle cardiaque (quelques ms)
 - plusieurs « boîtes »
 - Densité du produit de contraste variable
 - Mouvements entre les boîtes
 - Influence variable **selon la génération de scanner** (rapidité, largeur des boîtes)



Technique de réalisation

- Acquisition SANS gating cardiaque
 - Angioscanner standard
- Quand on ne s'intéresse pas au cœur lui-même ni au coronaires
 - Aorte, artères pulmonaires, retours veineux...
- En cas de risque d'échec avec gating:
 - Rythme cardiaque irrégulier
 - Respiration ample



Technique de réalisation

- Synchronisation
- **Injection**
- Apnée
- Sédation

Technique de réalisation

Injection de produit de contraste iodé

- Besoin d'une opacification vasculaire intense
 - Dose plus élevée (comme abdomen)
 - **Débit le plus élevé possible** pour avoir un bolus dense
 - Facteur de qualité ++
 - Besoin d'une « grosse » perfusion
- Cardiopathie : vitesse de circulation imprévisible → intérêt du **smart prep**
- Temps d'acquisition:
 - Le plus souvent mixte : AP et Aorte
 - Parfois: temps veineux cave nécessaire (anomalie de veine cave, DCPT...)
 - acquisition tardive ou biphasique




Technique de réalisation

- Synchronisation
- Injection
- **Apnée**
- Sédation

Technique de réalisation

Apnée


- Peut être longue (10-30 s)
- Facteur clé pour éviter les « marches »
- Pas besoin d'une grande inspiration: que « bloquer »
- Donc dépend:
 - Du degré de compréhension de l'enfant
 - De sa capacité respiratoire à tenir l'apnée
 - ... du manipulateur radio



Technique de réalisation

Apnée

- Bébés
 - Respiration libre pas trop gênante car petite amplitude
 - Mais: pas d'agitation ! : une seule chance



Technique de réalisation

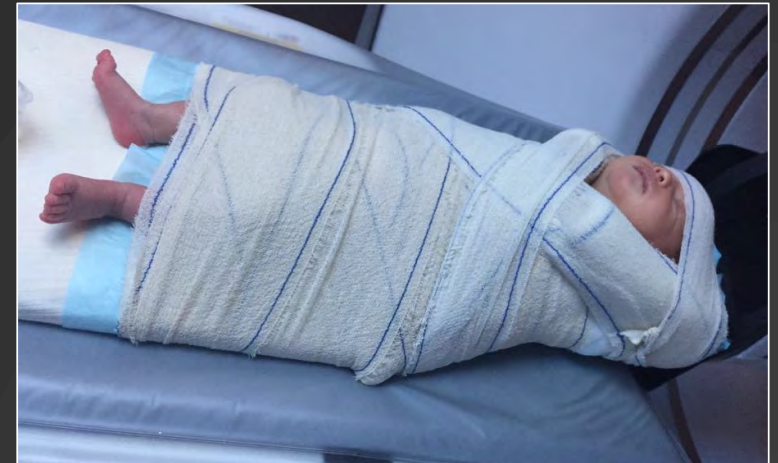- Synchronisation
- Injection
- Apnée
- **Sédation**



Technique de réalisation

Sédation ?

- Besoin d'immobilité thoracique pendant \approx 10 minutes
- < 5 kgs: après biberon \rightarrow sommeil
- < 5 ans: dépend le degré de coopération
 - Installation « libre »
 - « Planchage » uniquement
 - Sédation (pentobarbital ou autre) et « planchage »
- > 5-6 ans: devient trop grand pour sédation habituelle
 - Sédation « médicalisée »
 - Anesthésie générale

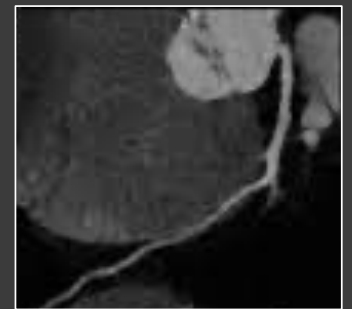
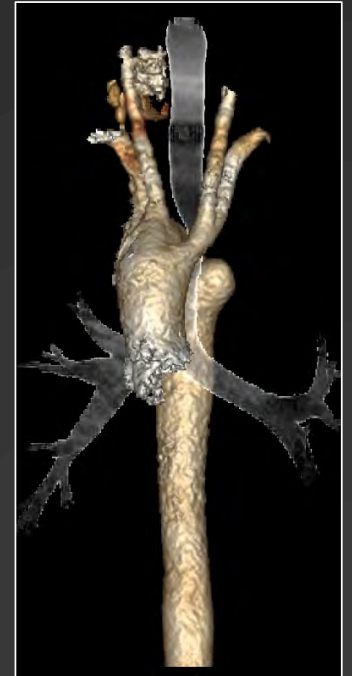
Technique d'interprétation et exemples



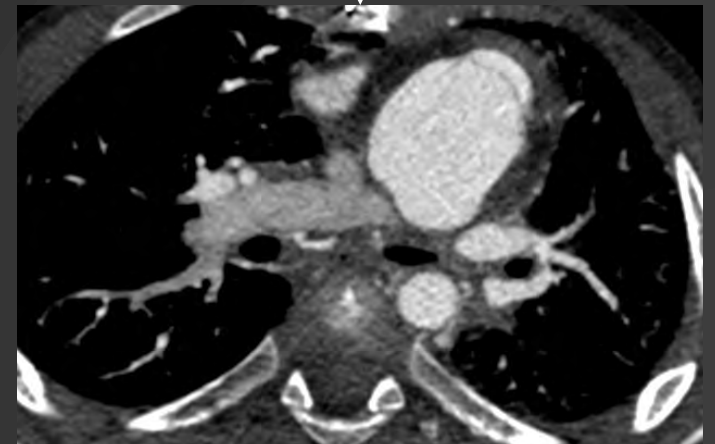
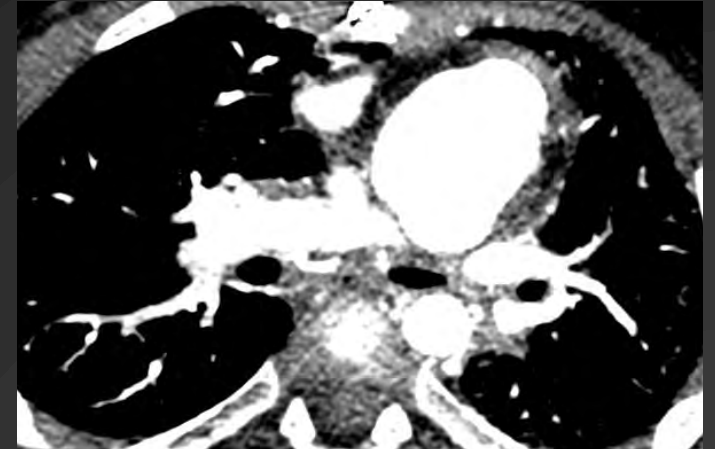
Technique d'interprétation

- Affichage
 - Peut être anormal selon le type de PACS
 - Tenter affichage 2D, 3D...
- Sur console d'interprétation des constructeurs de scanner
 - Multiphase
 - Reconstructions: 3D, curviligne, lumière...



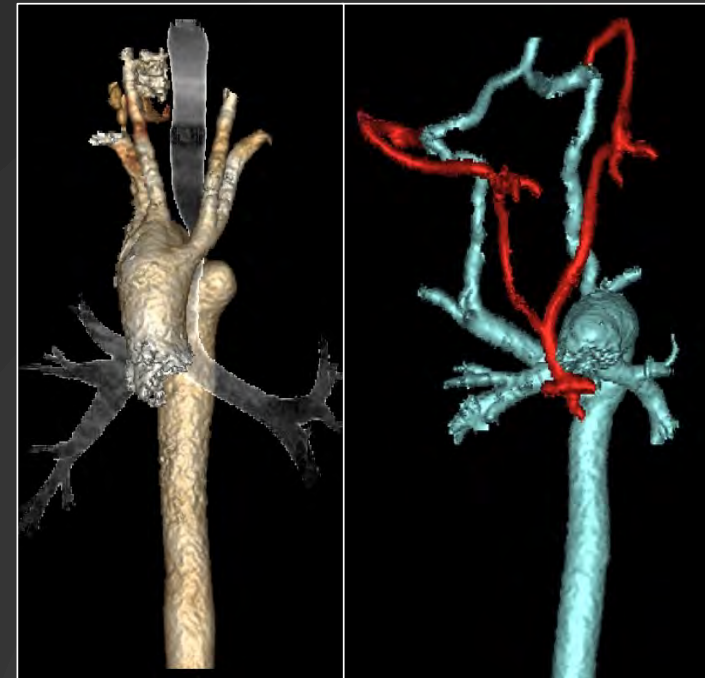
Technique d'interprétation

- Filtre et Fenêtre
 - Choisir filtre « mou »
(pas parenchyme pulmonaire)
 - Fenêtrage:
 - Elargir la fenêtre par rapport au fenêtrage médiastinal standard
 - Adapter manuellement au contraste souhaité



Technique d'interprétation

- Reconstructions
 - Moyen de communiquer un résultat
 - Comprendre les rapports anatomiques
 - ⚠ Choix de l'opérateur ! ⚠
- Reconstructions
 - 3D: choix des structures et de leur représentation



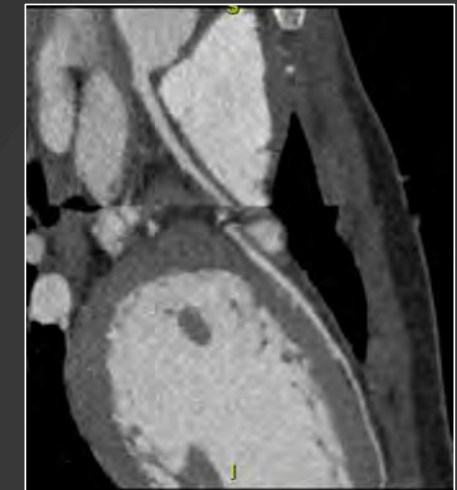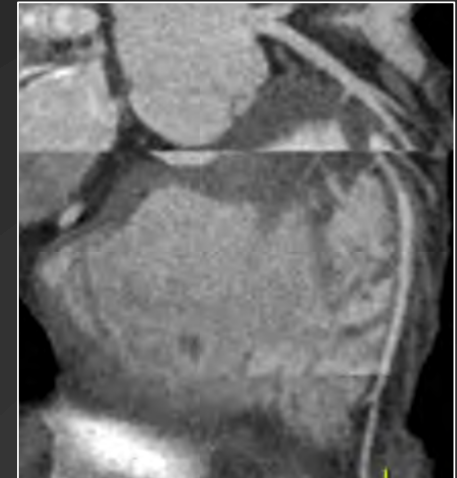Technique d'interprétation

- Reconstructions
 - Moyen de communiquer un résultat
 - Comprendre les rapports anatomiques
 - ⚠ Choix de l'opérateur ! ⚠
- Reconstructions
 - 3D: choix des structures et de leur représentation



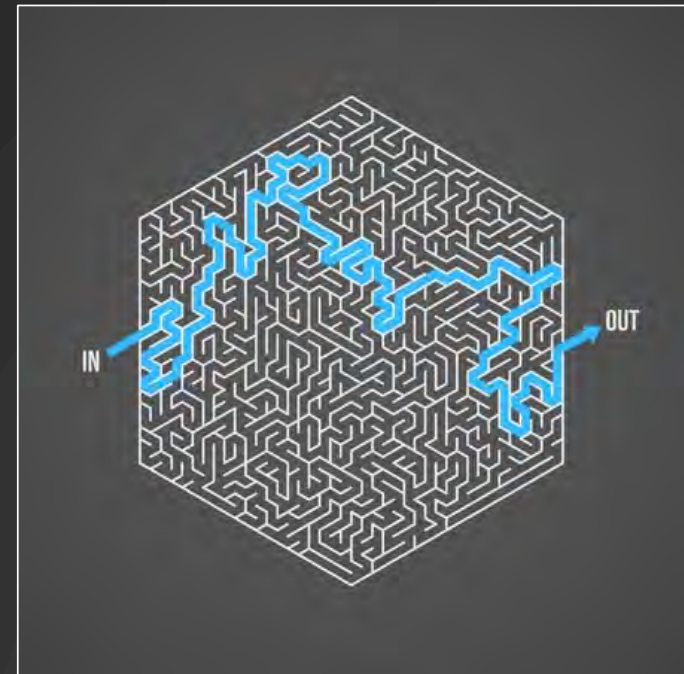
Technique d'interprétation

- Reconstructions
 - Moyen de communiquer un résultat
 - Comprendre les rapports anatomiques
 - ⚠ Choix de l'opérateur ! ⚠
- Reconstructions
 - 3D: choix des structures et de leur représentation
 - Curviligne: plan irrégulier qui suit une structure



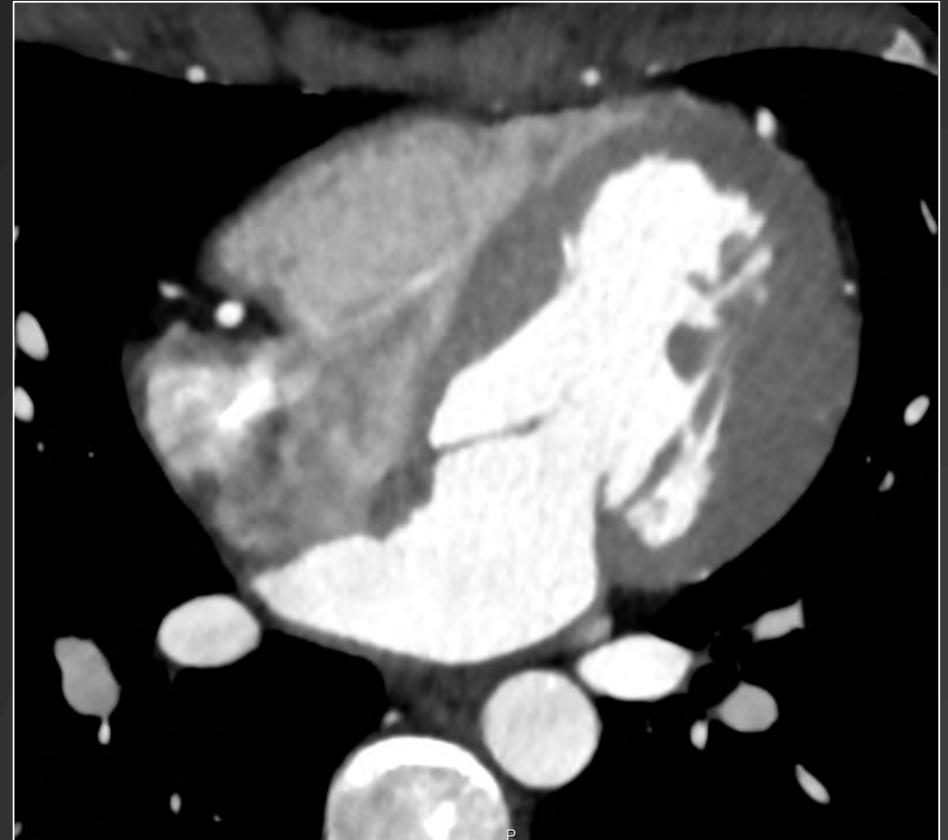
Technique d'interprétation

- Analyse
 - Il suffit de suivre le chemin !
 - Analyse structurée
 - Vaisseaux
 - Cavités cardiaques

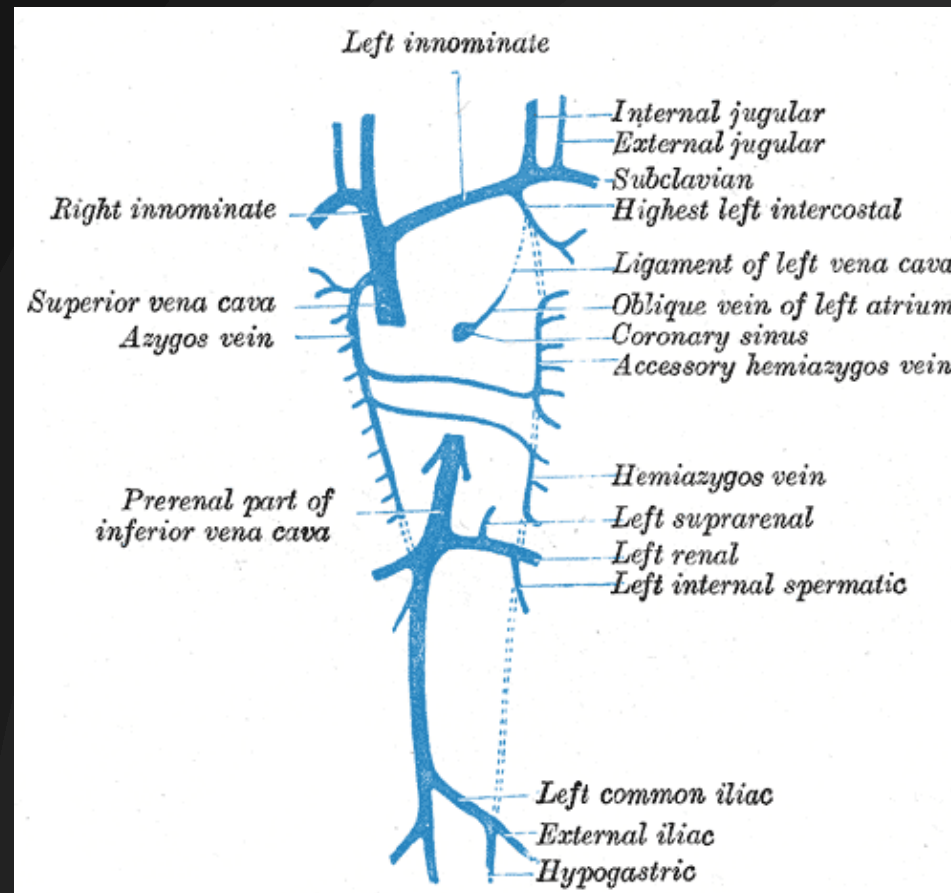


Technique d'interprétation

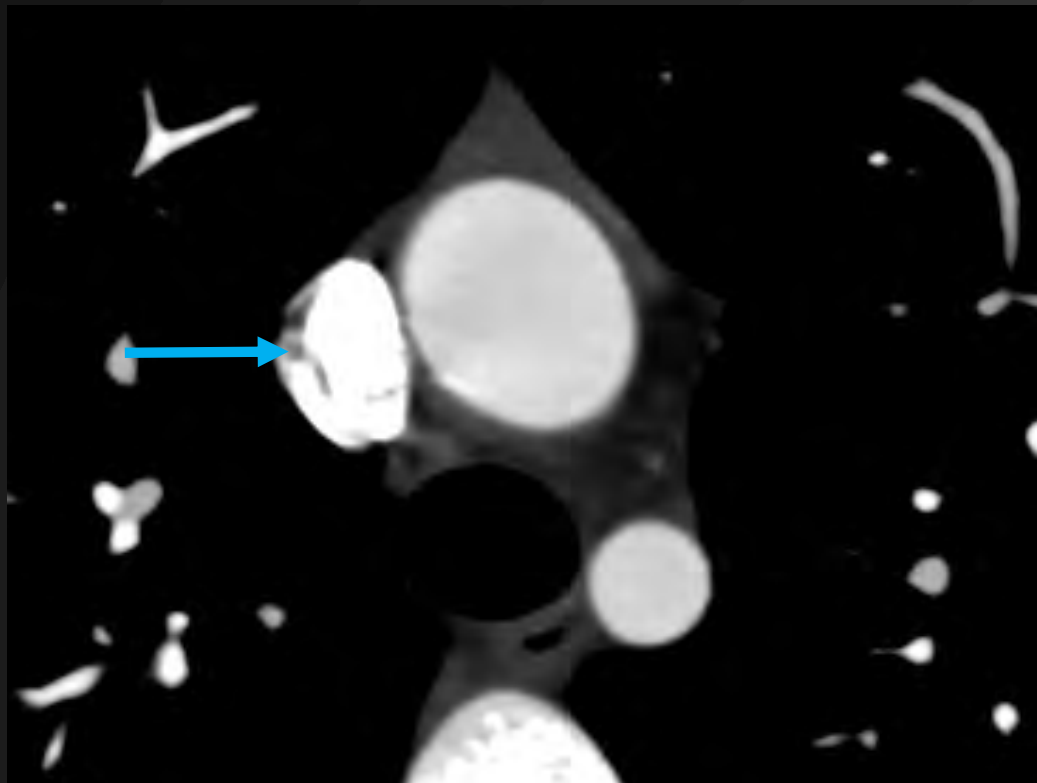
- Analyse
 - Entrées :
 - 2 veines caves (supérieure et inférieure)
 - 4 veines pulmonaires
 - Sorties :
 - Aorte
 - Artère pulmonaire (AP)
 - Vascularisation :
 - 2 artères coronaires
 - Sinus coronaire
 - Cavités :
 - 2 atria
 - 2 ventricules



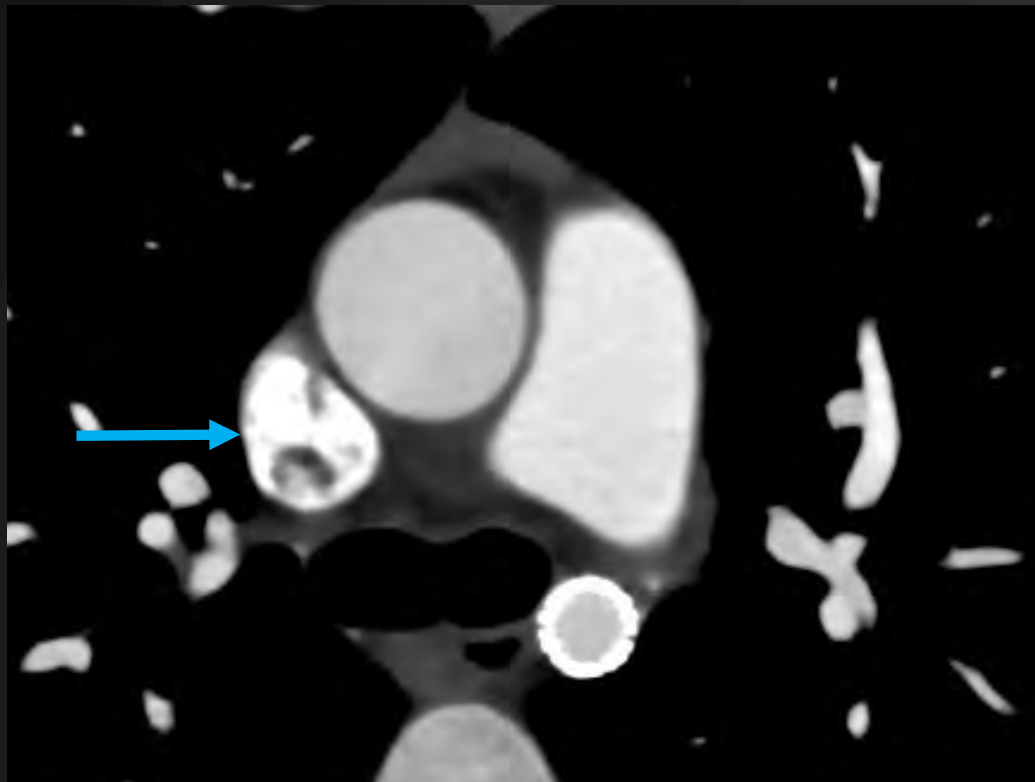
Veines caves



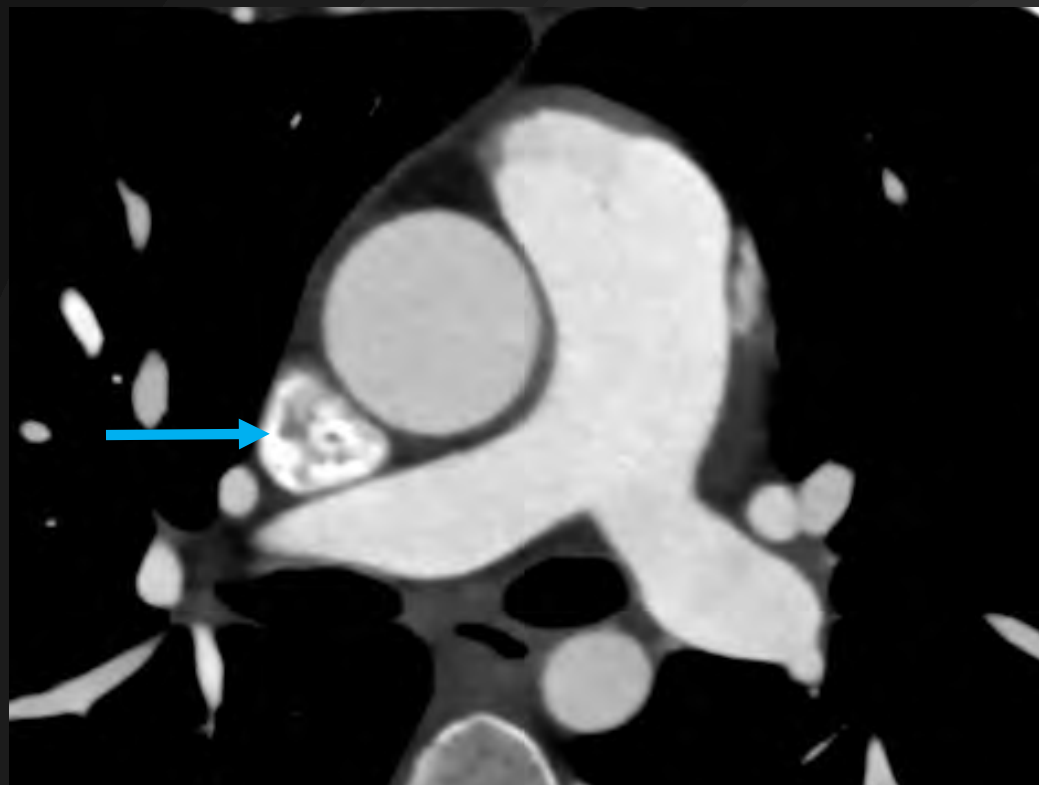
Veines caves



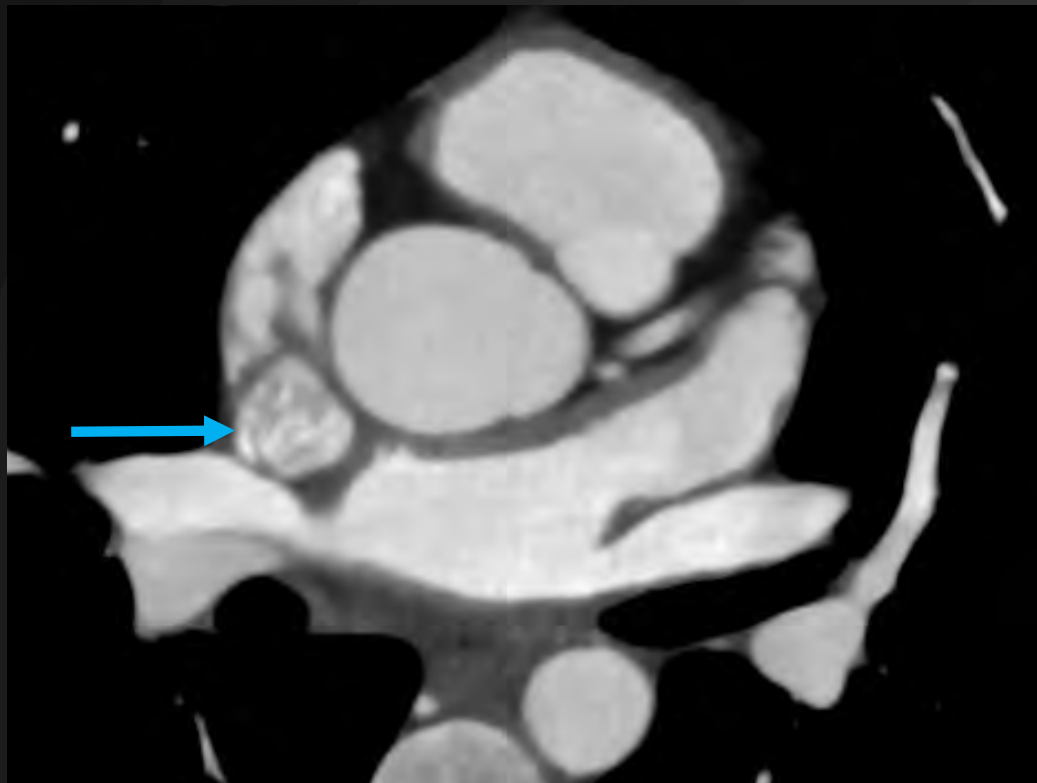
Veines caves



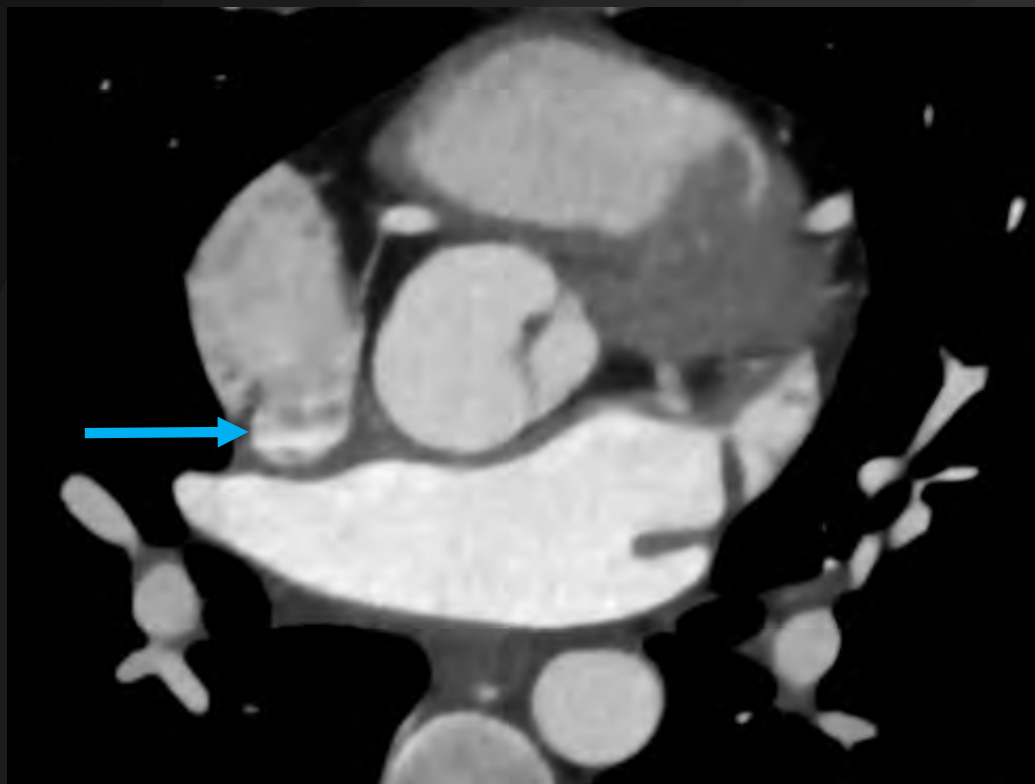
Veines caves



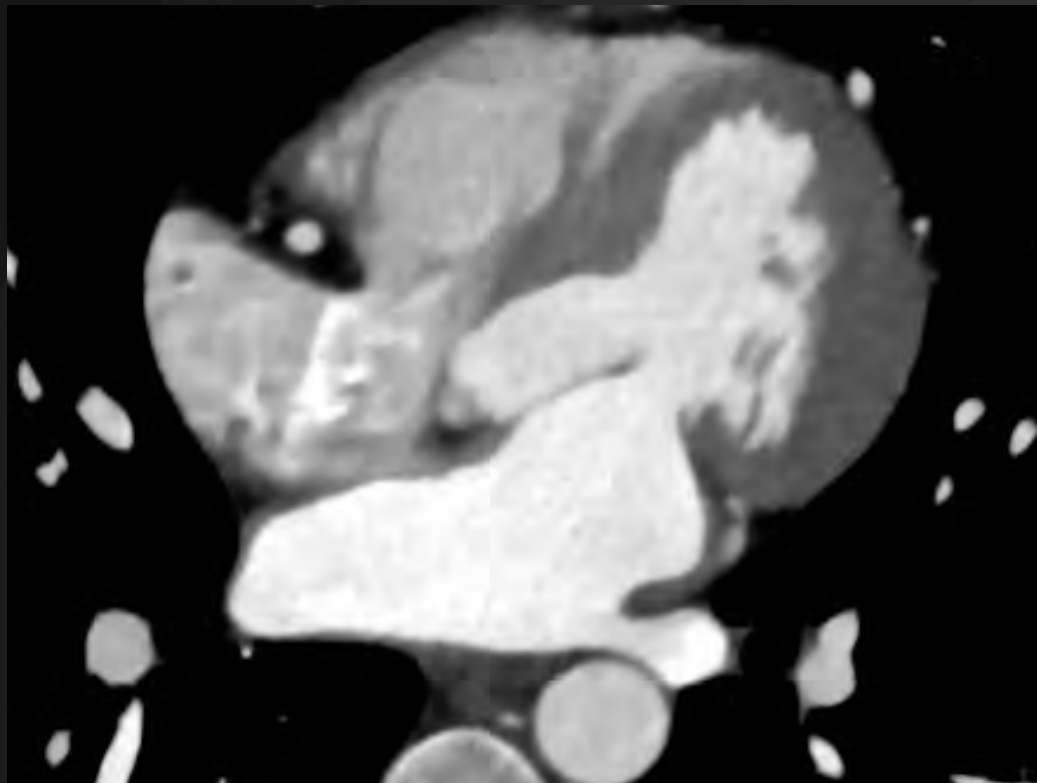
Veines caves



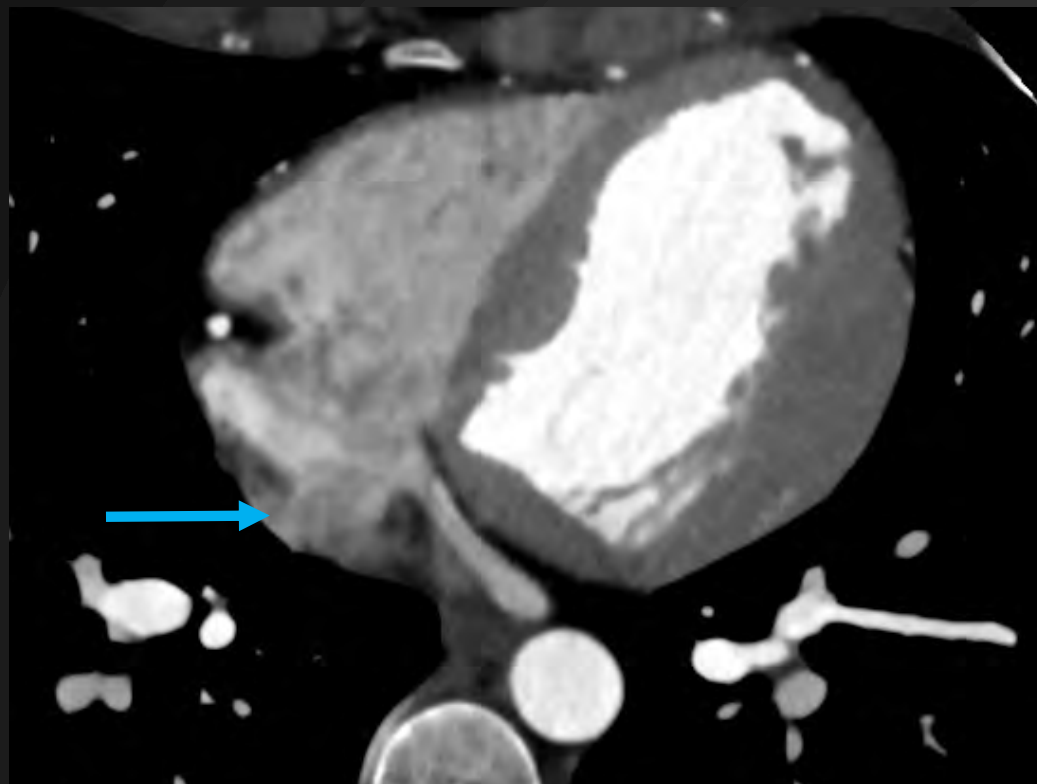
Veines caves



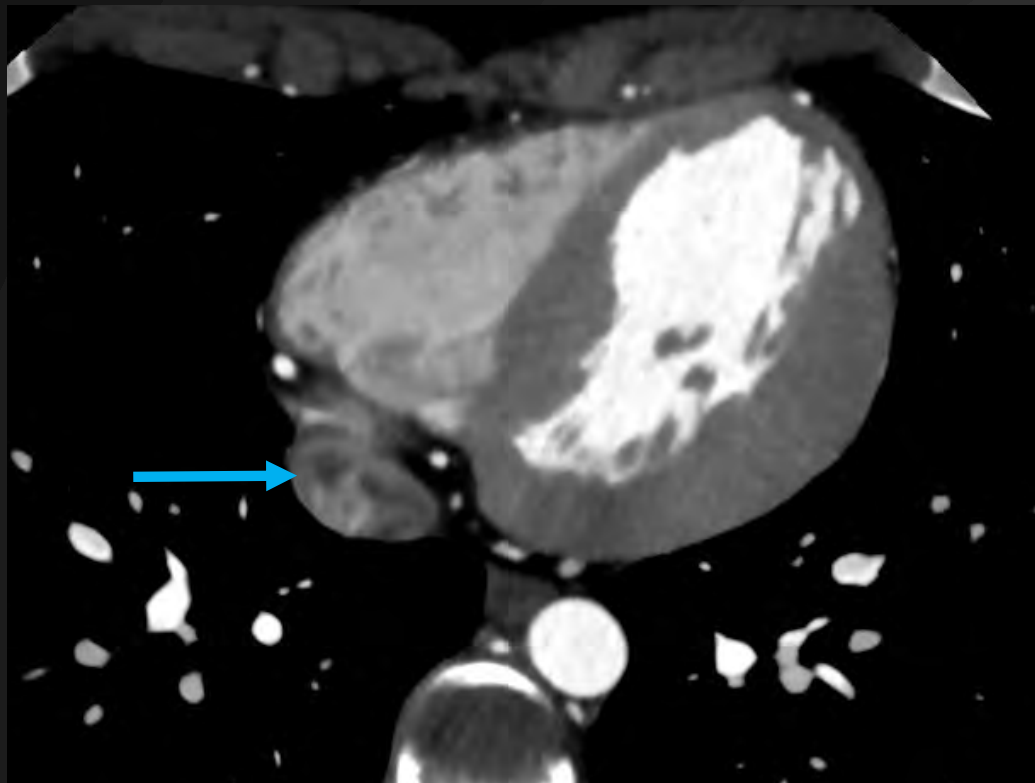
Veines caves



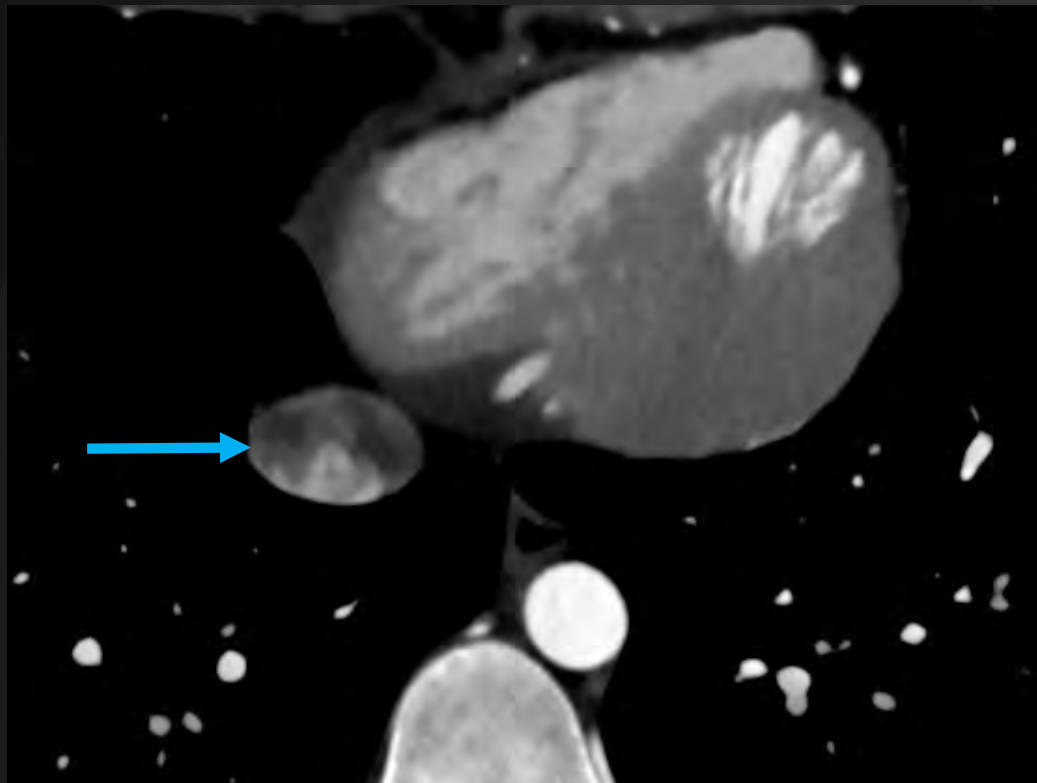
Veines caves



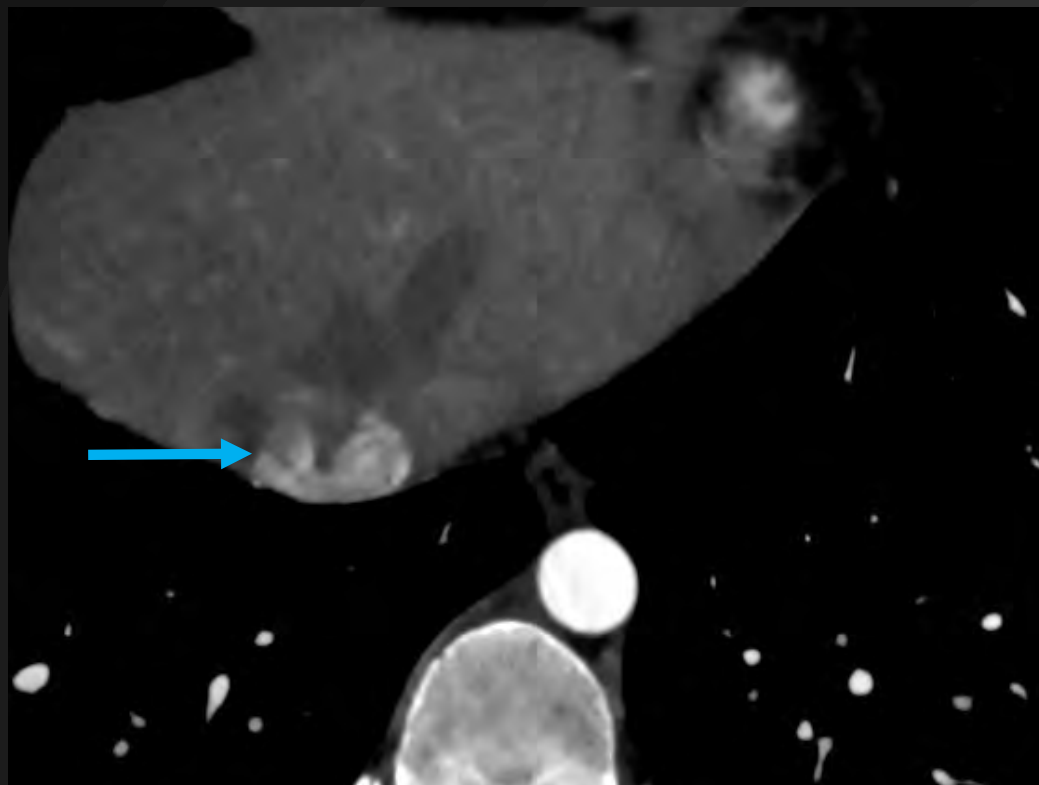
Veines caves



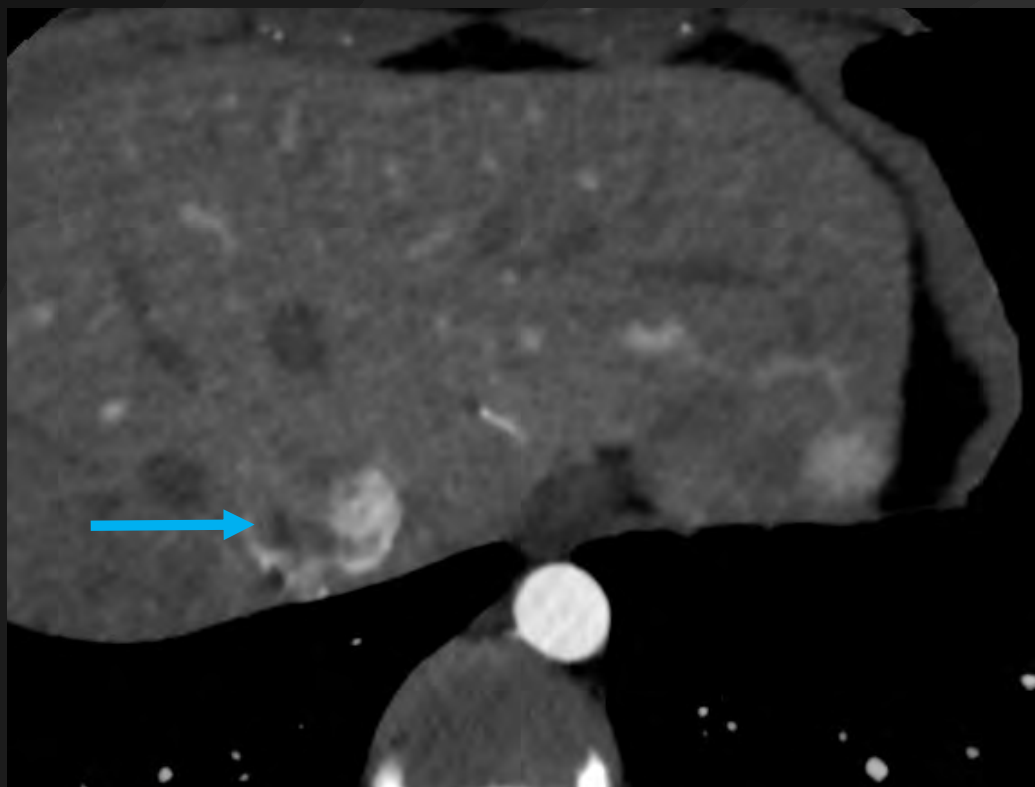
Veines caves



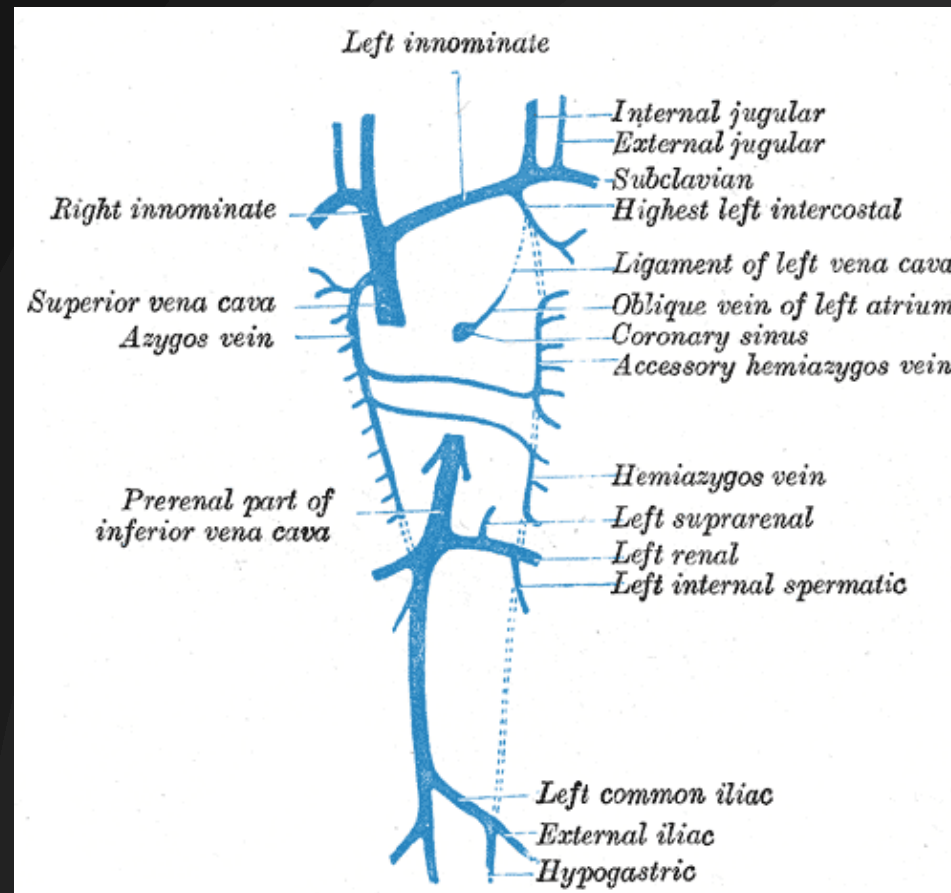
Veines caves



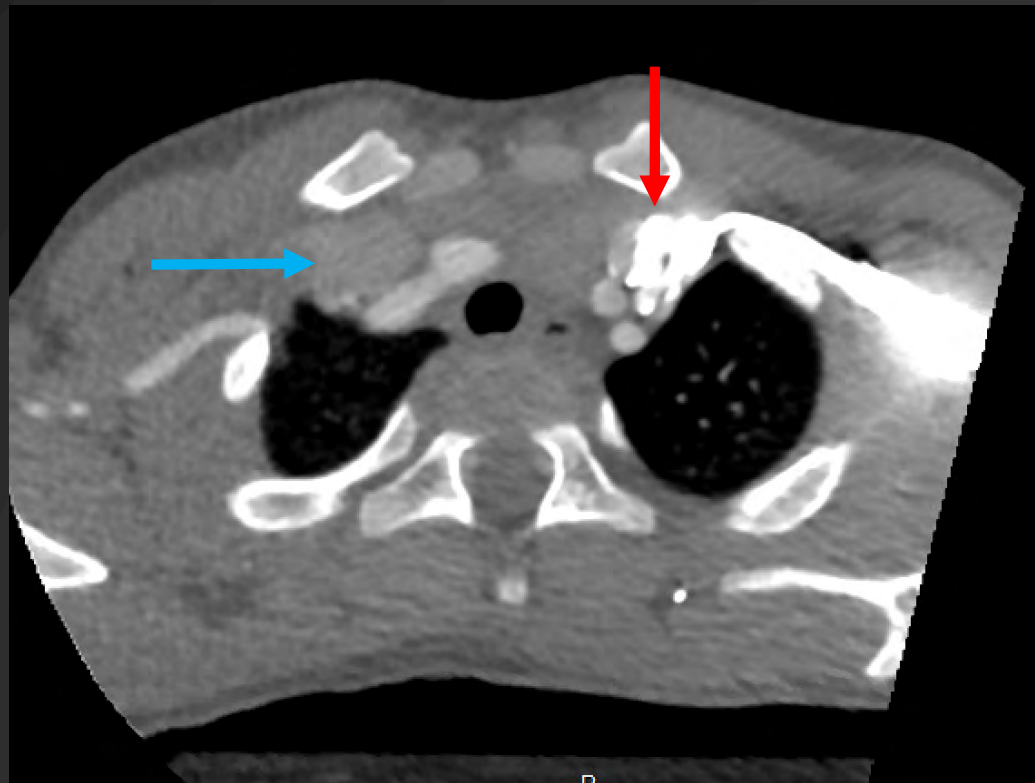
Veines caves



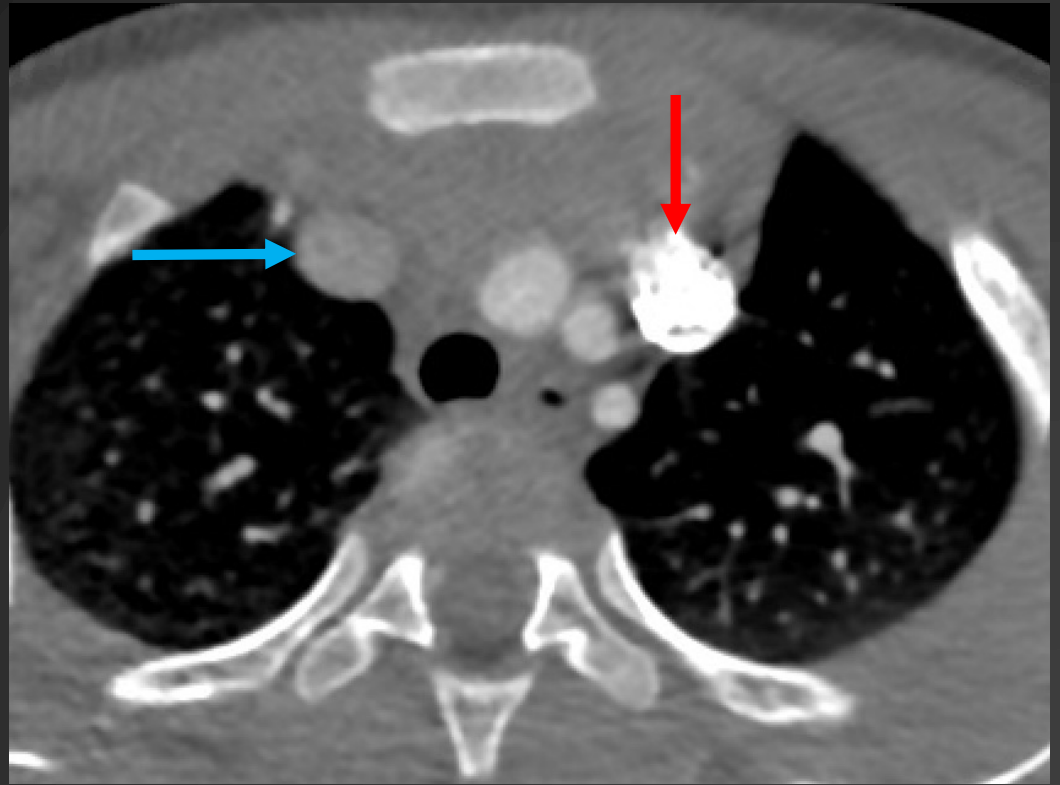
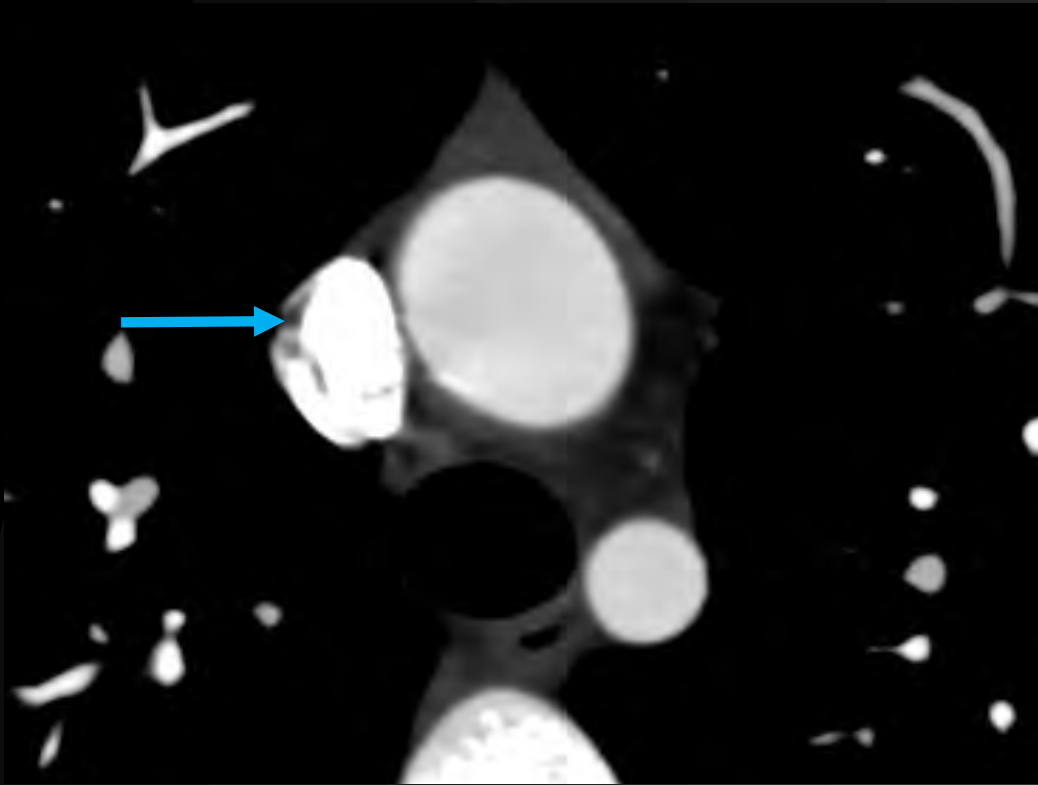
Veines caves



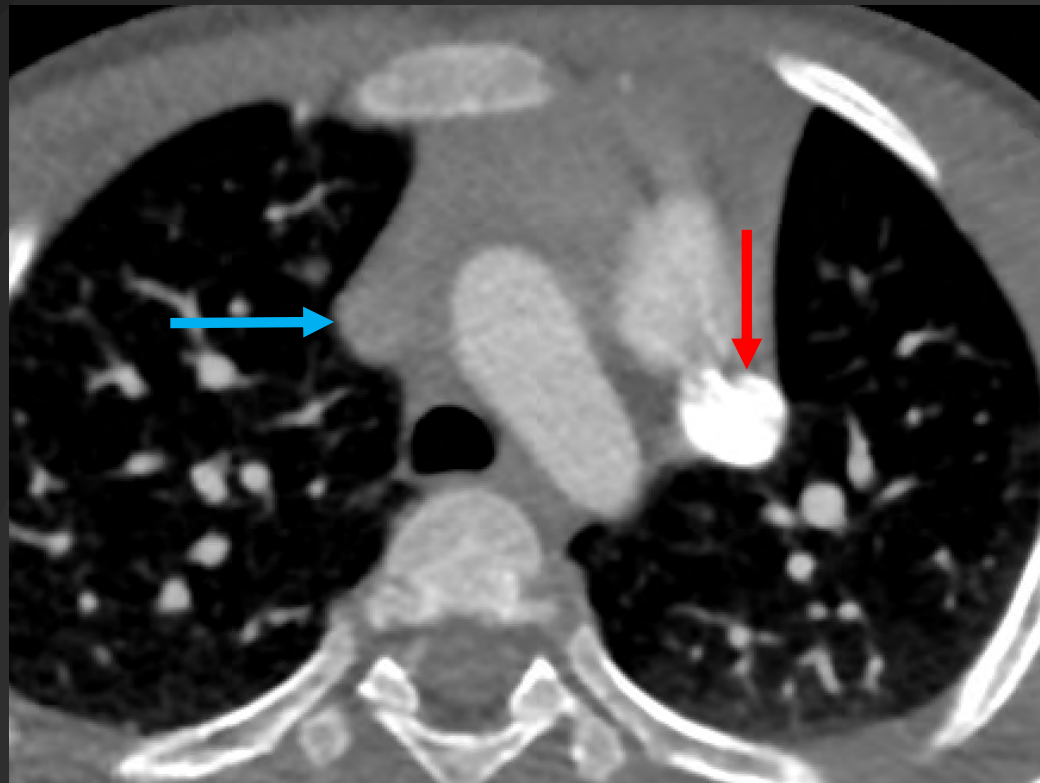
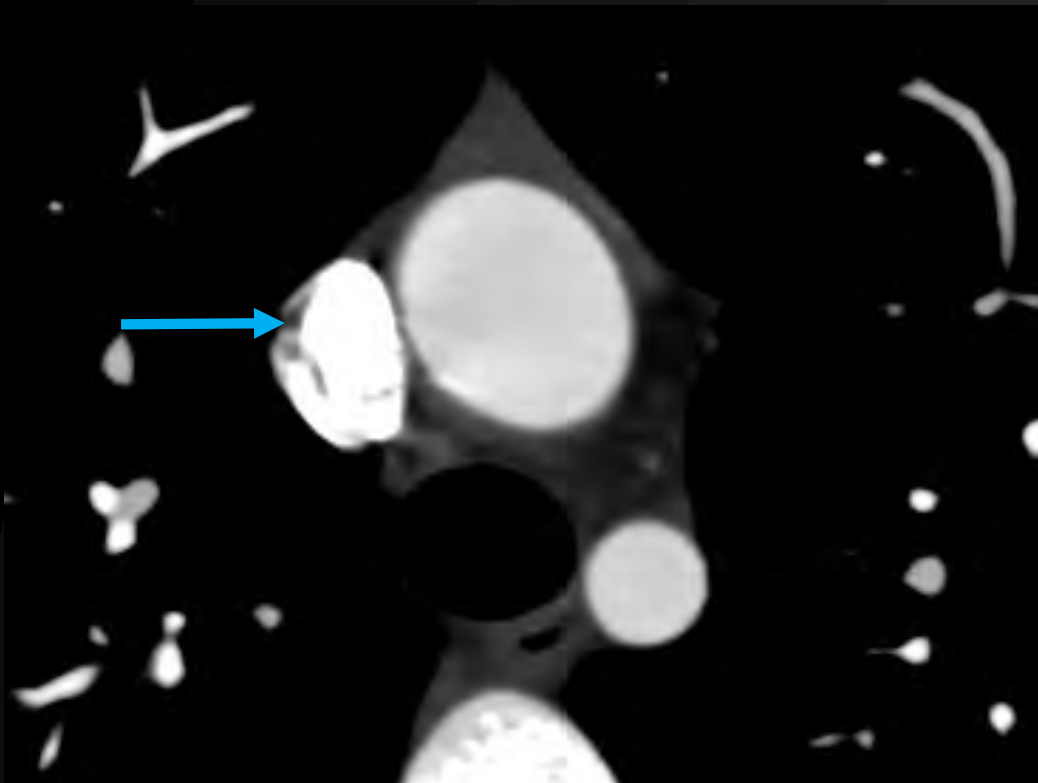
Veines caves



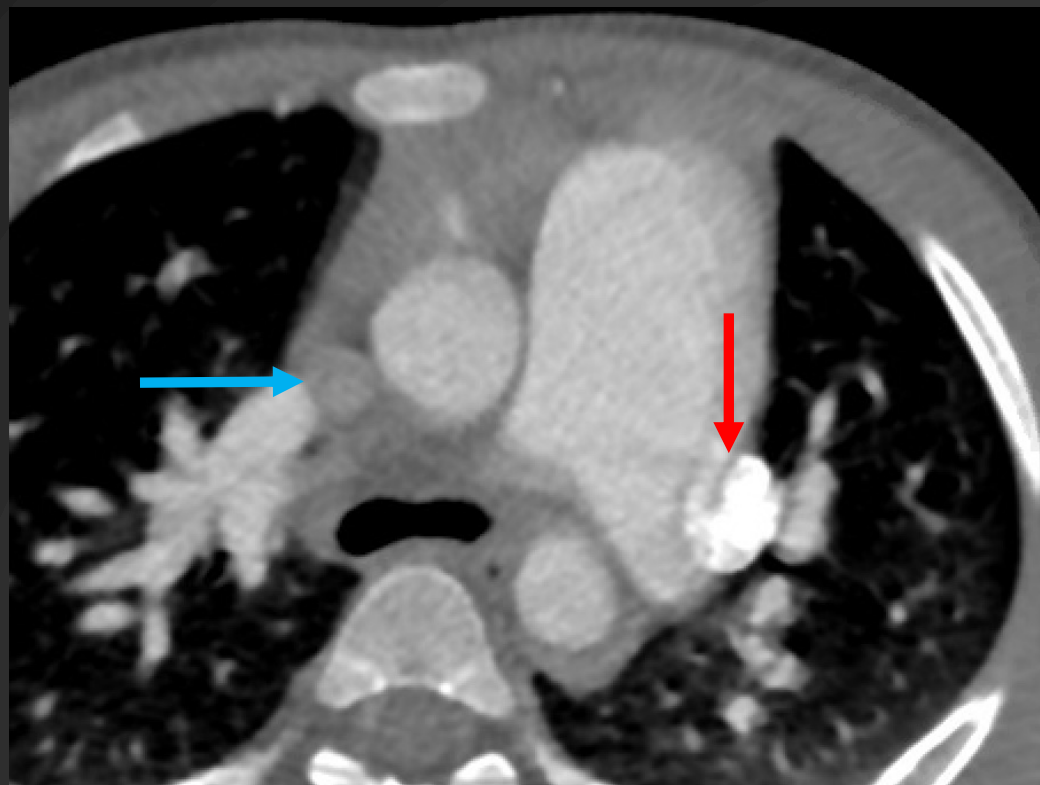
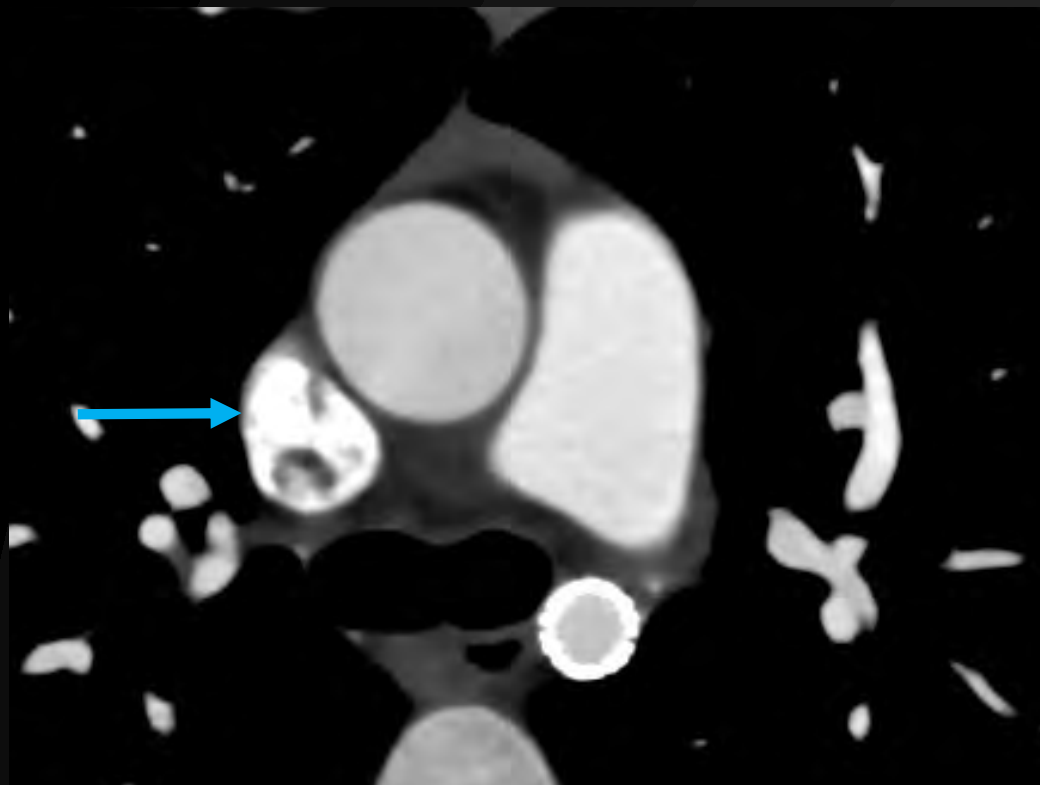
Veines caves



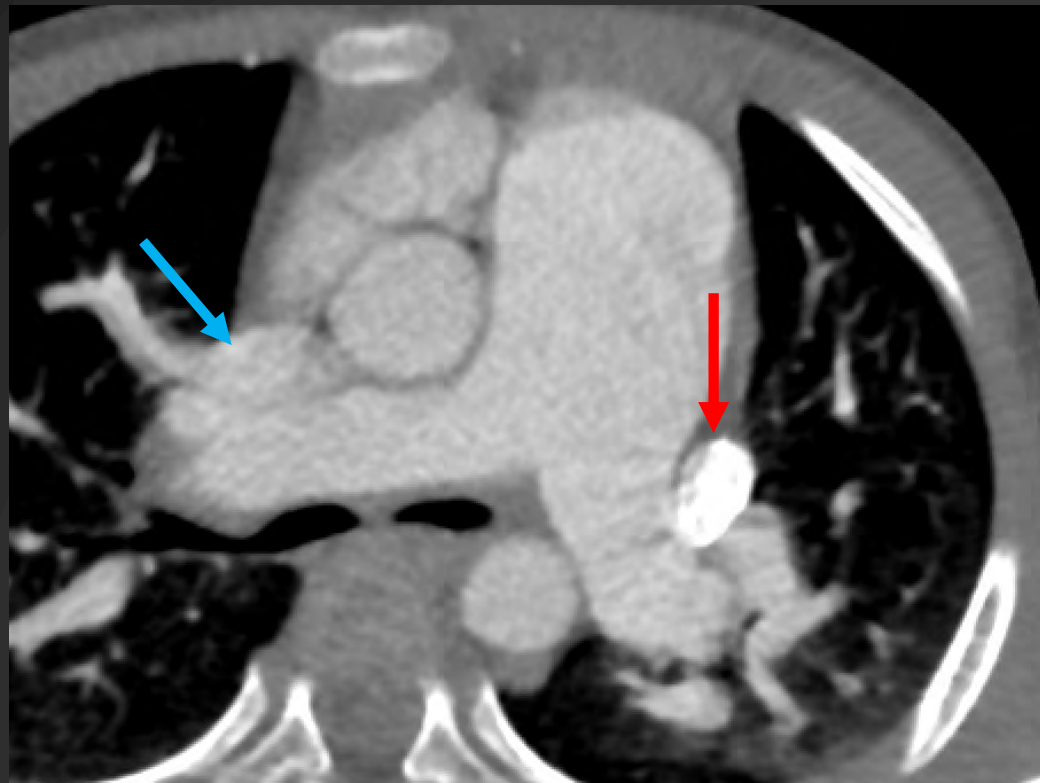
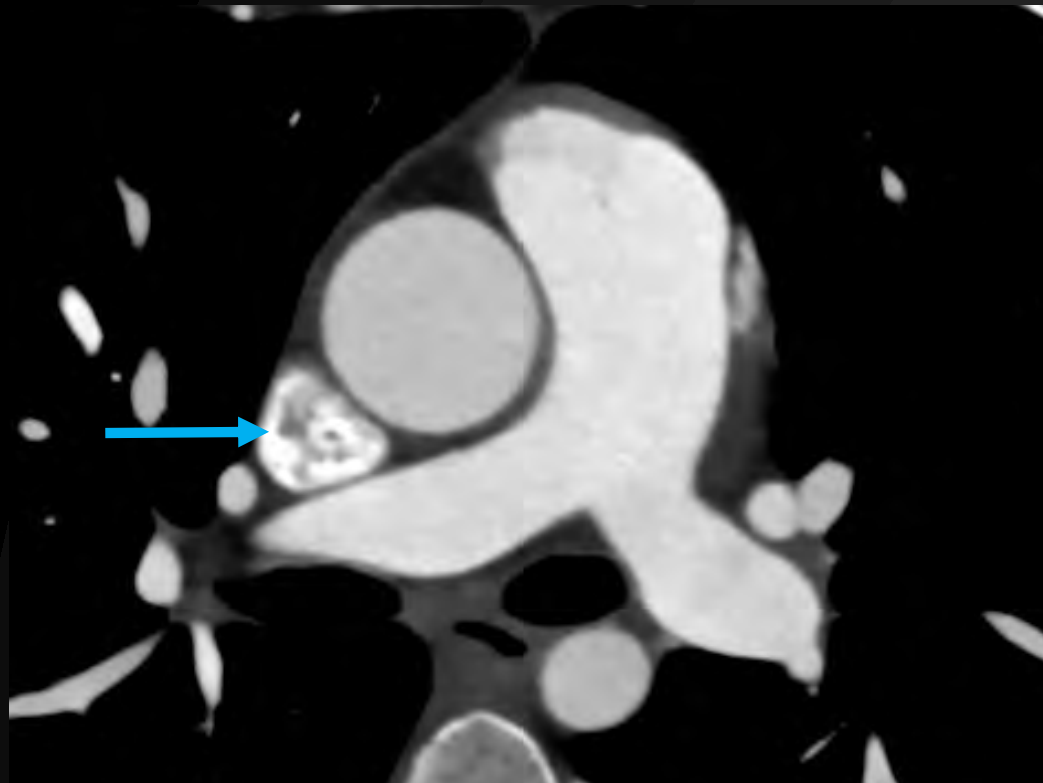
Veines caves



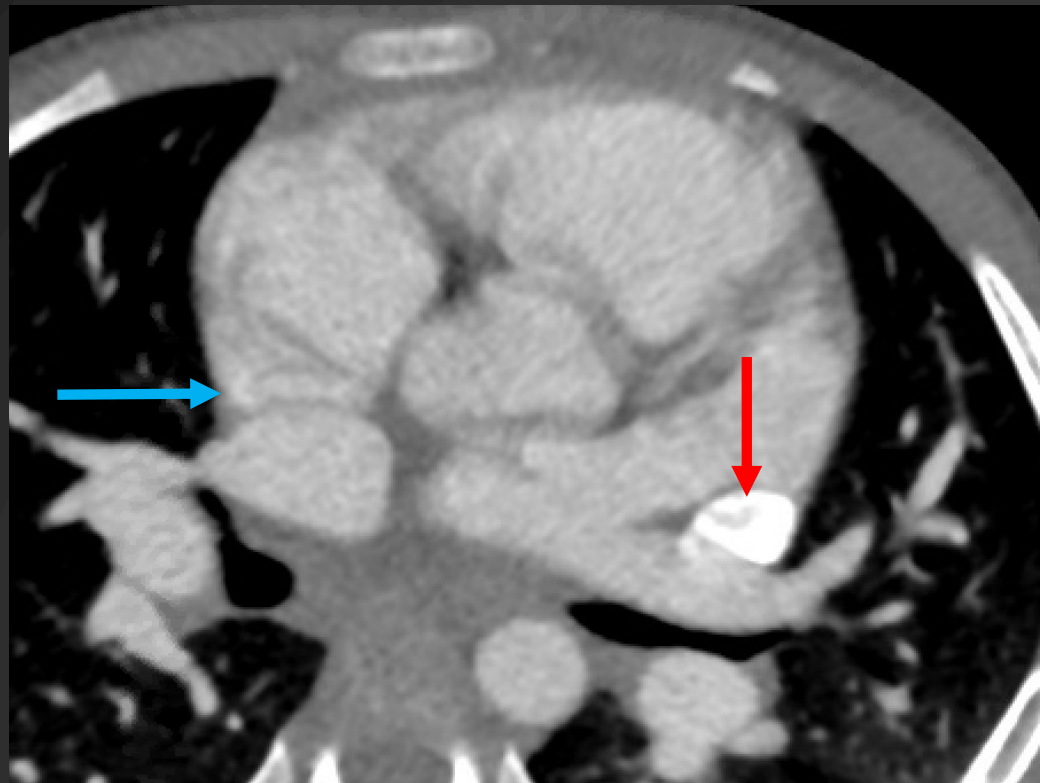
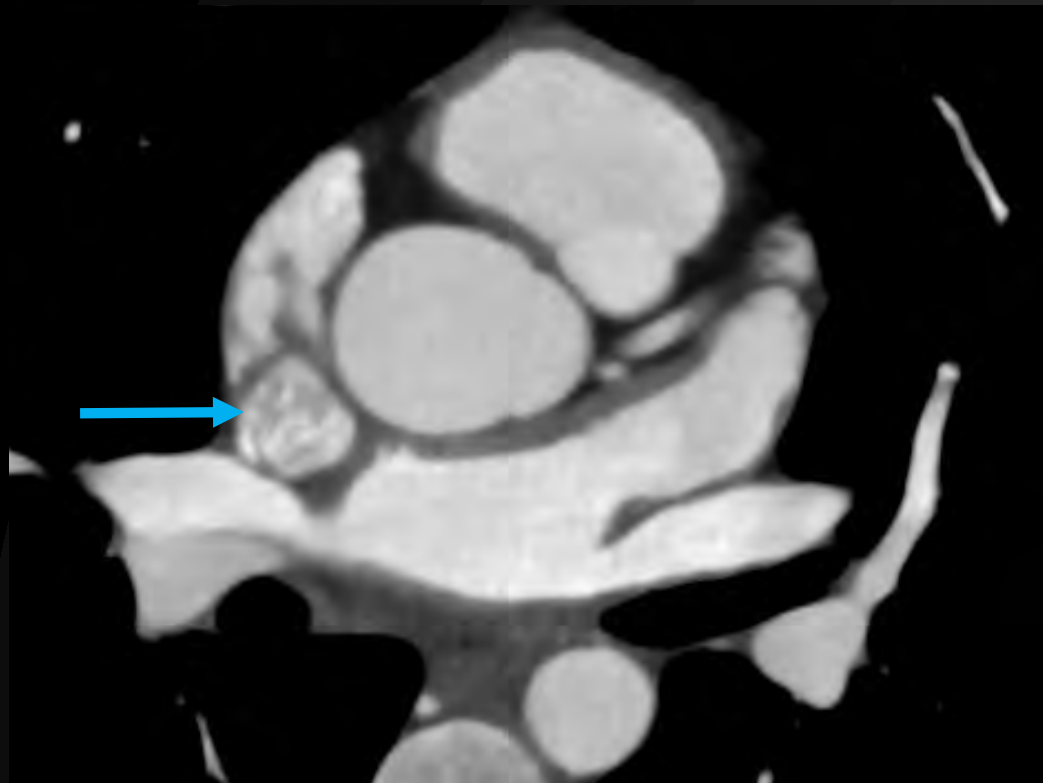
Veines caves



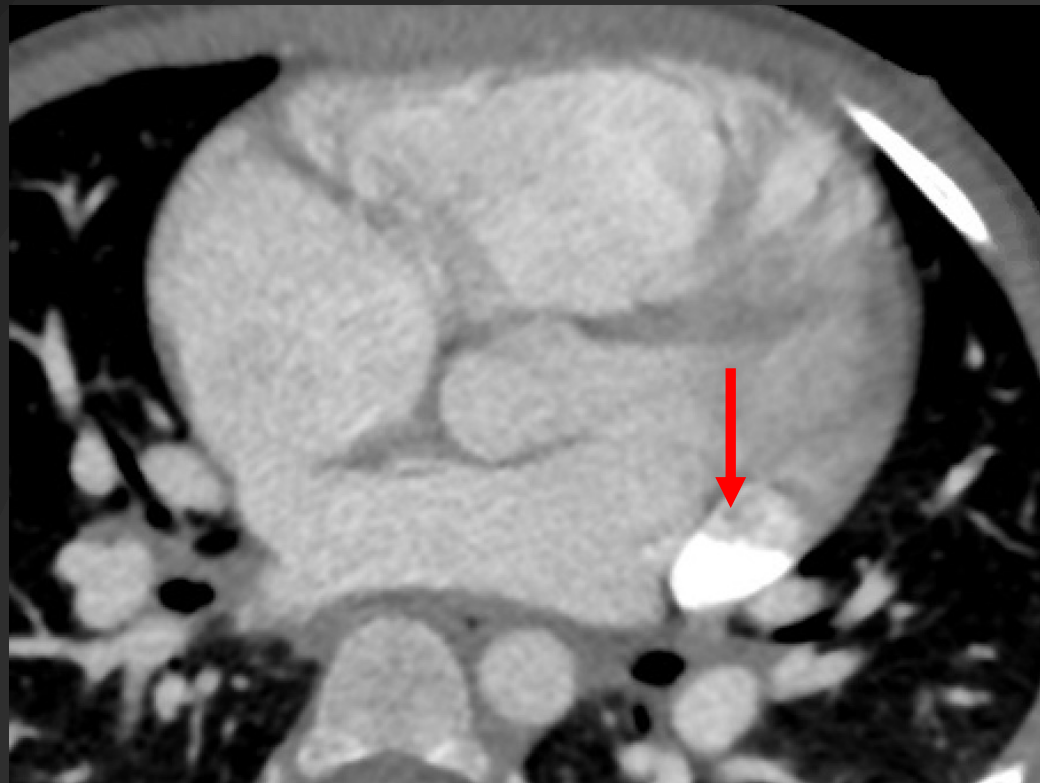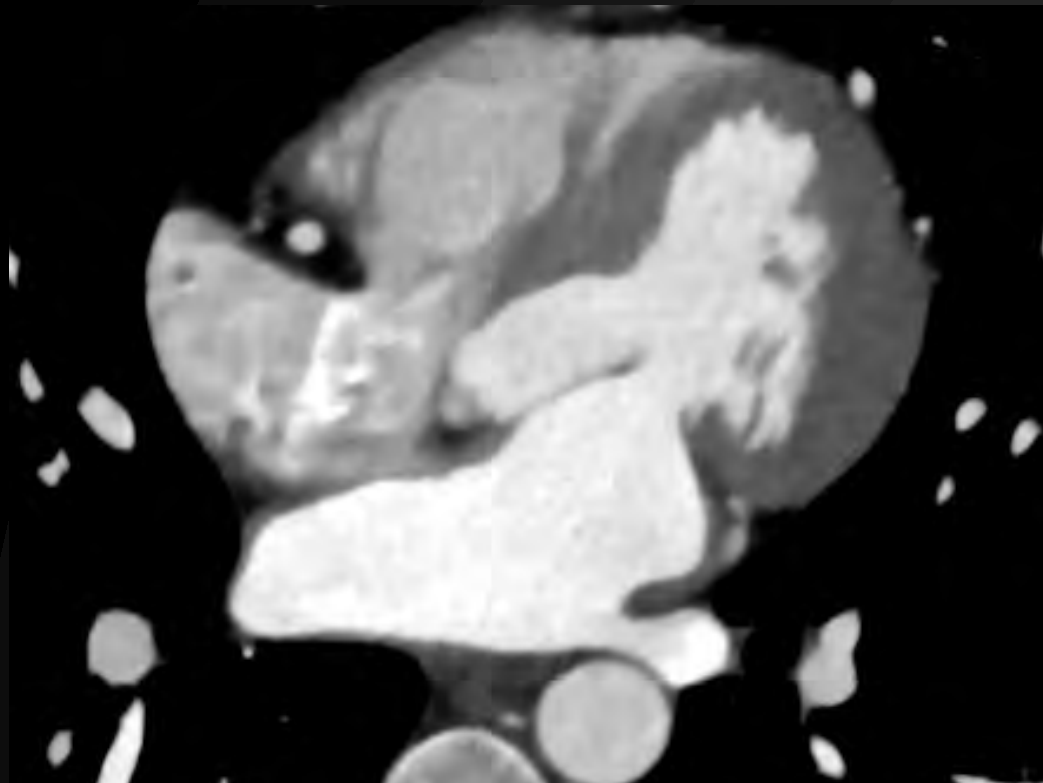
Veines caves



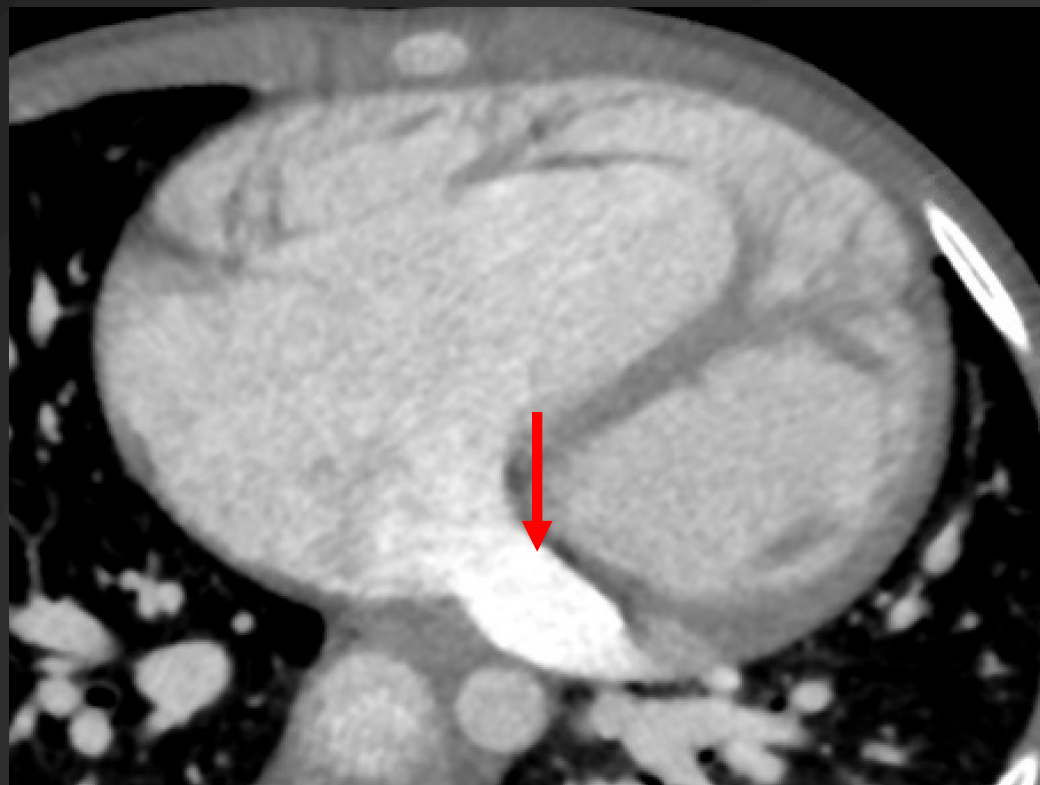
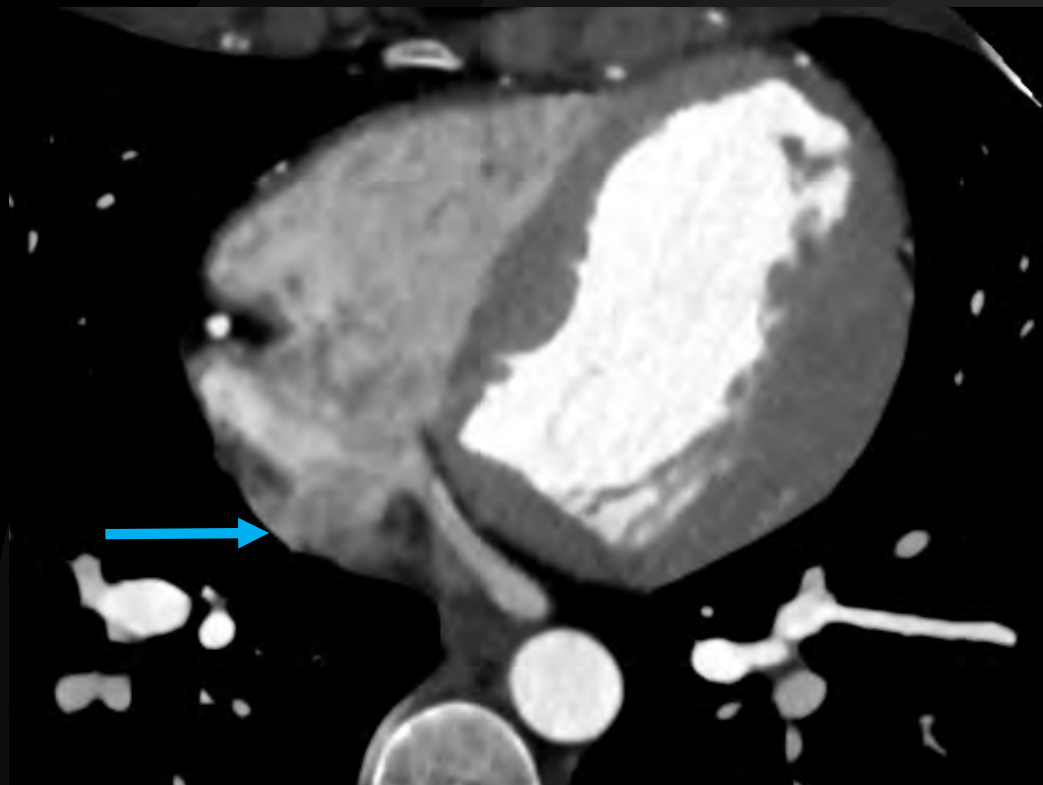
Veines caves



Veines caves

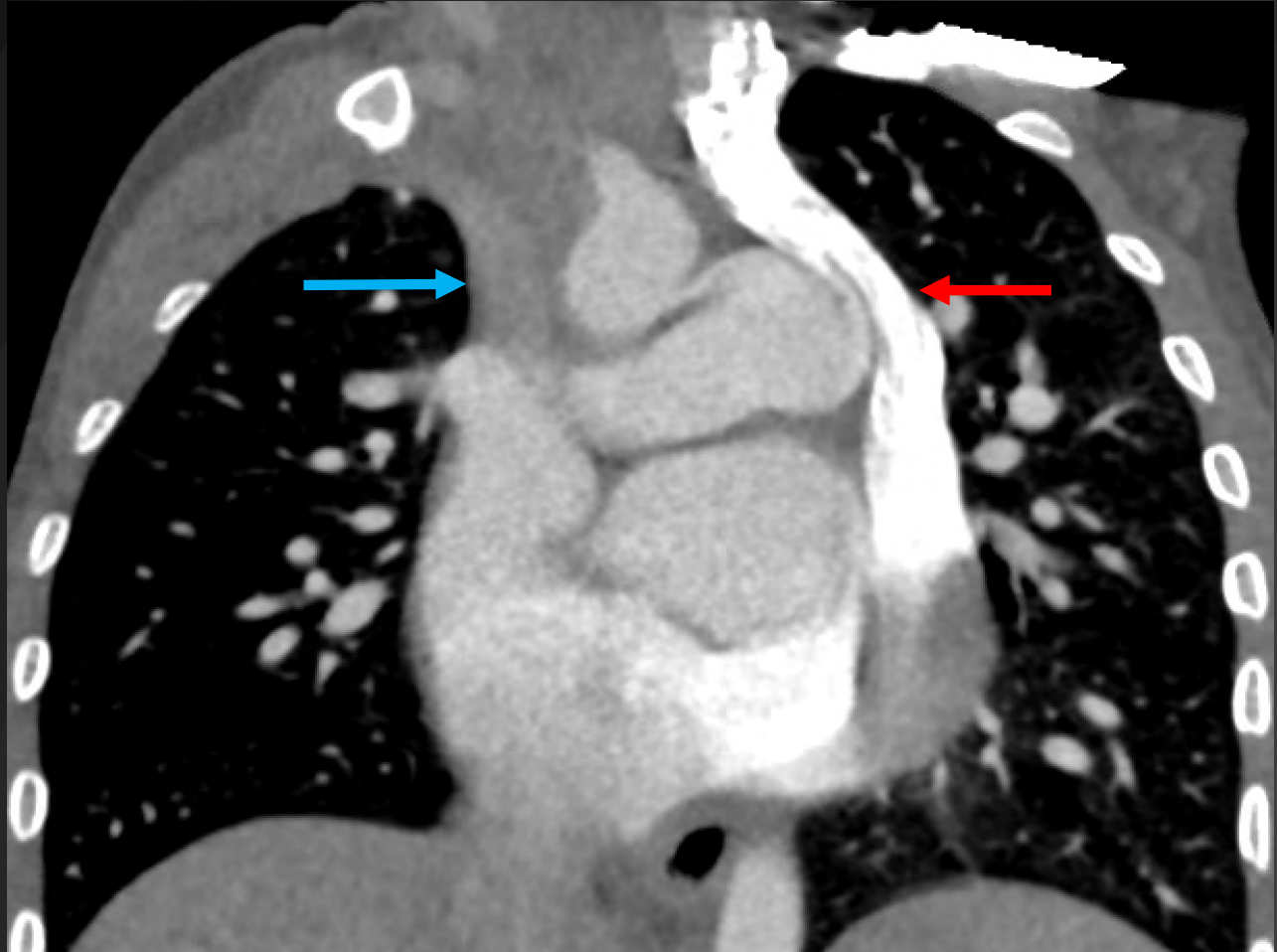


Veines caves

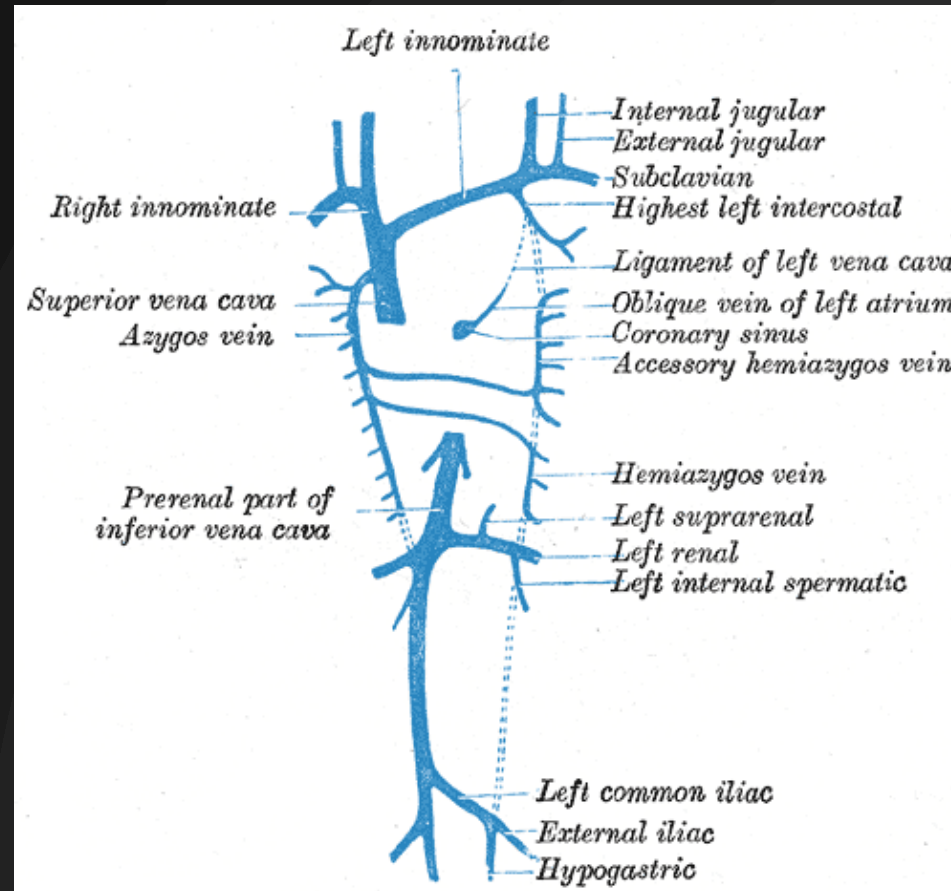


Veines caves

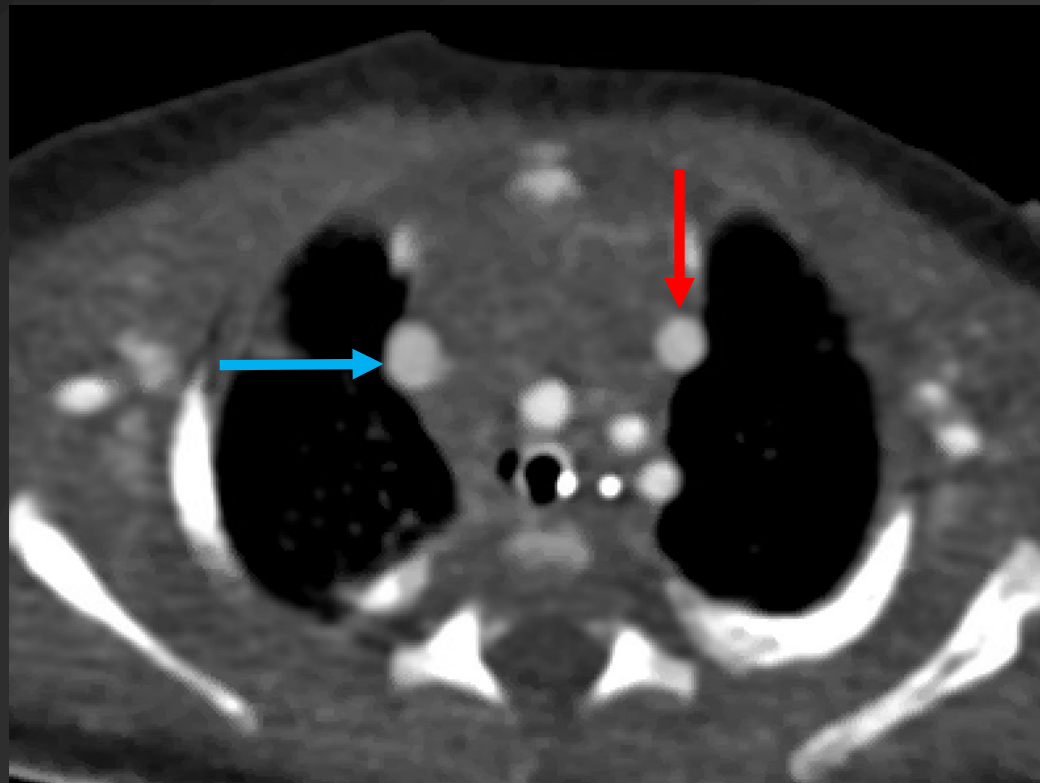

Veine cave
supérieure gauche
(CIA sinus venosus)



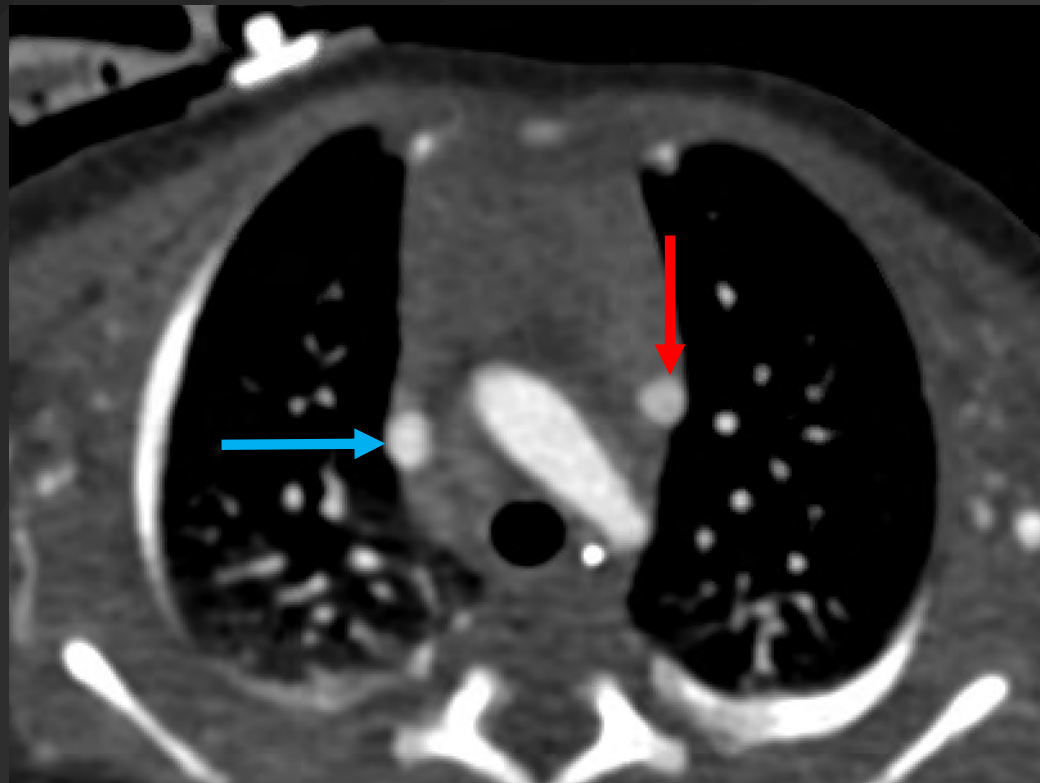

Veines caves



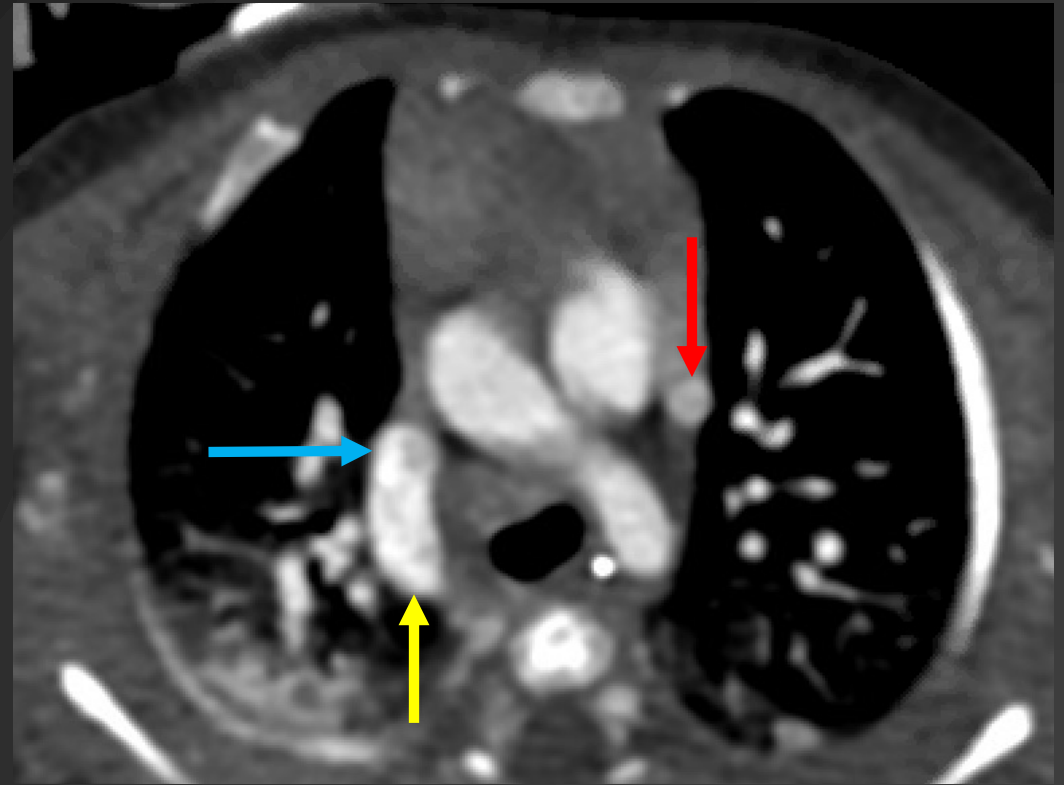
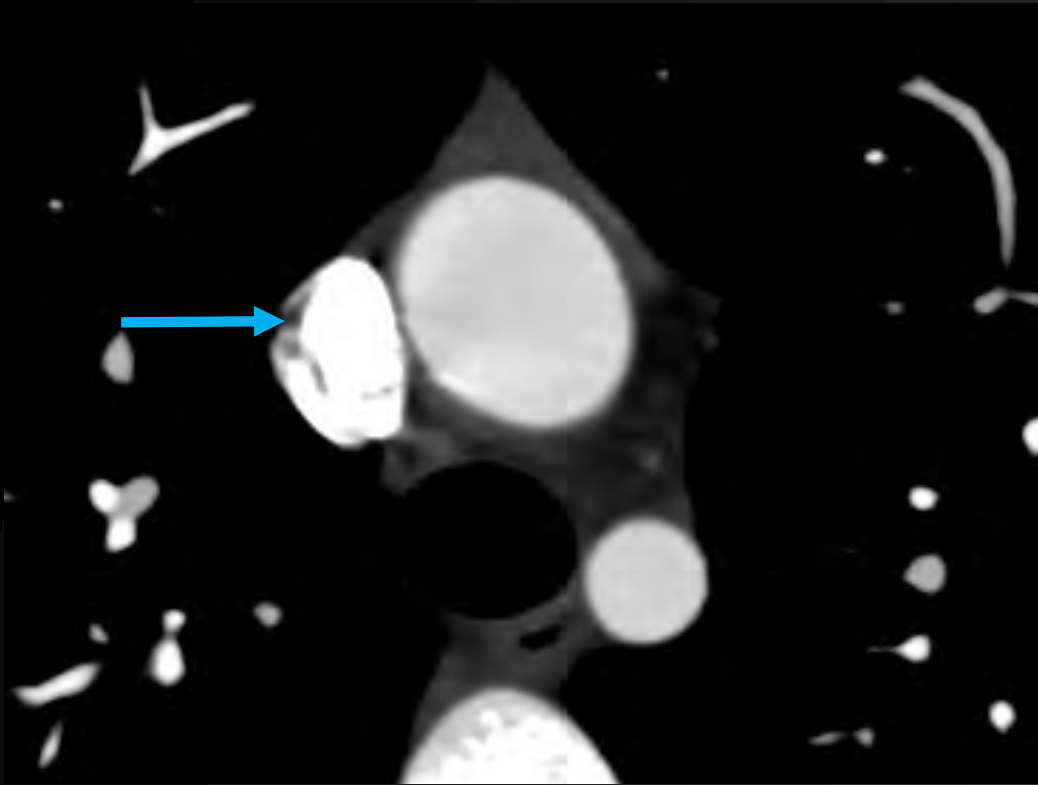
Veines caves



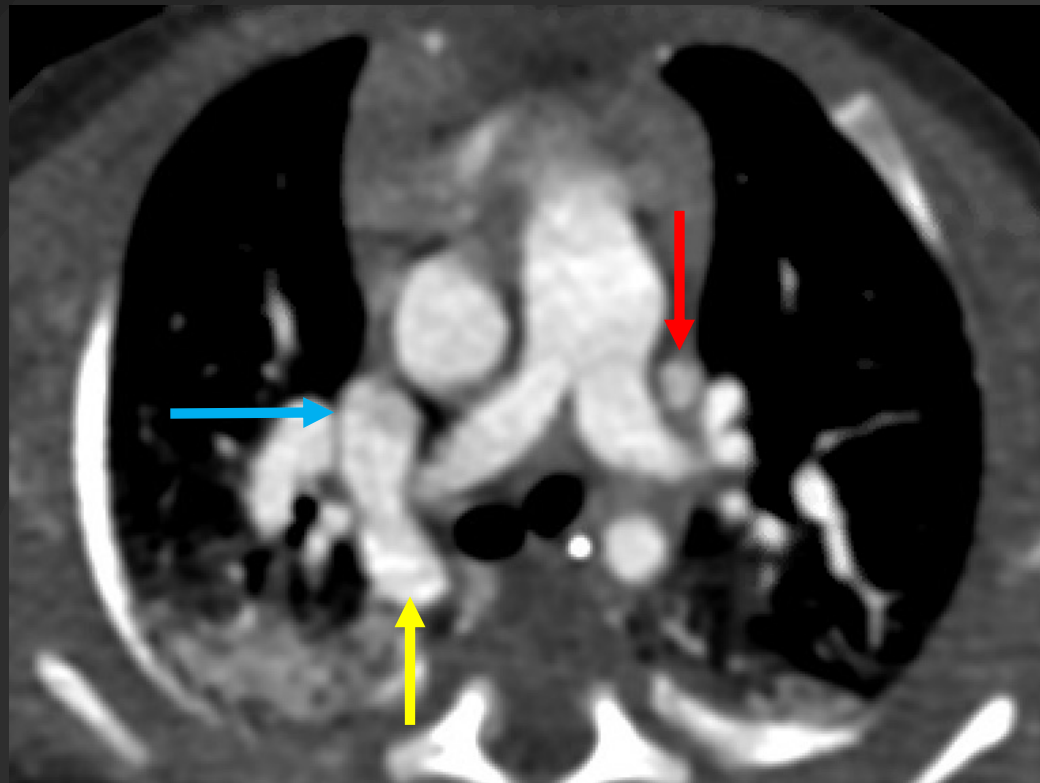
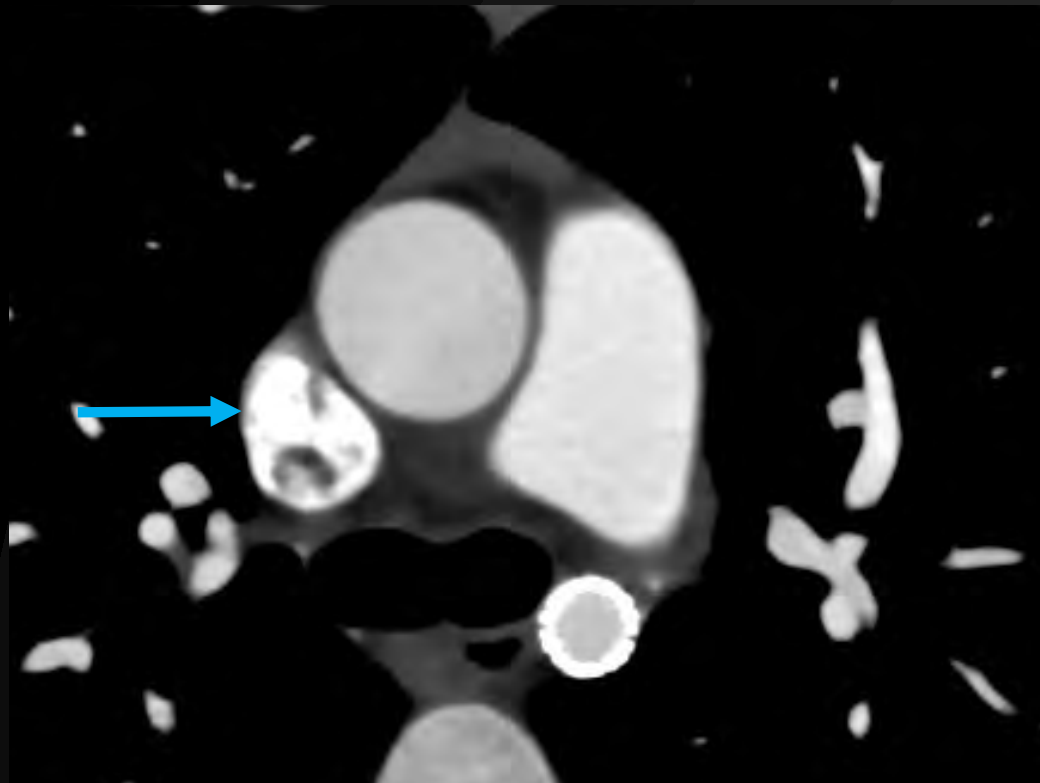
Veines caves



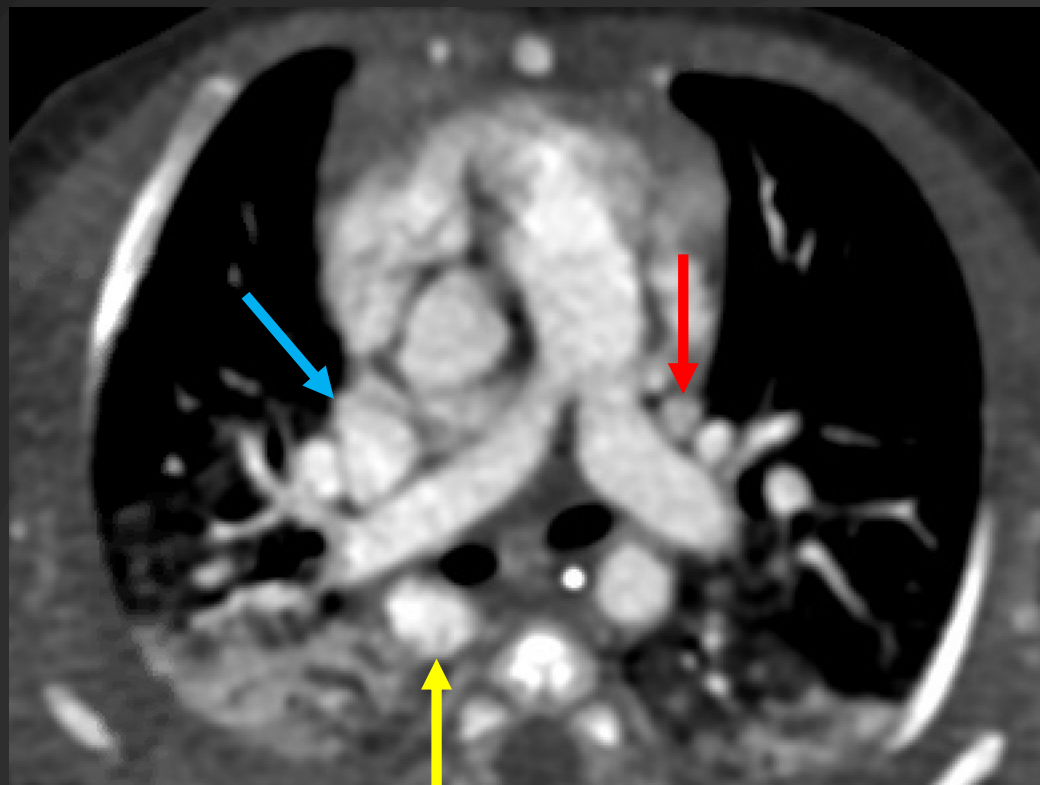
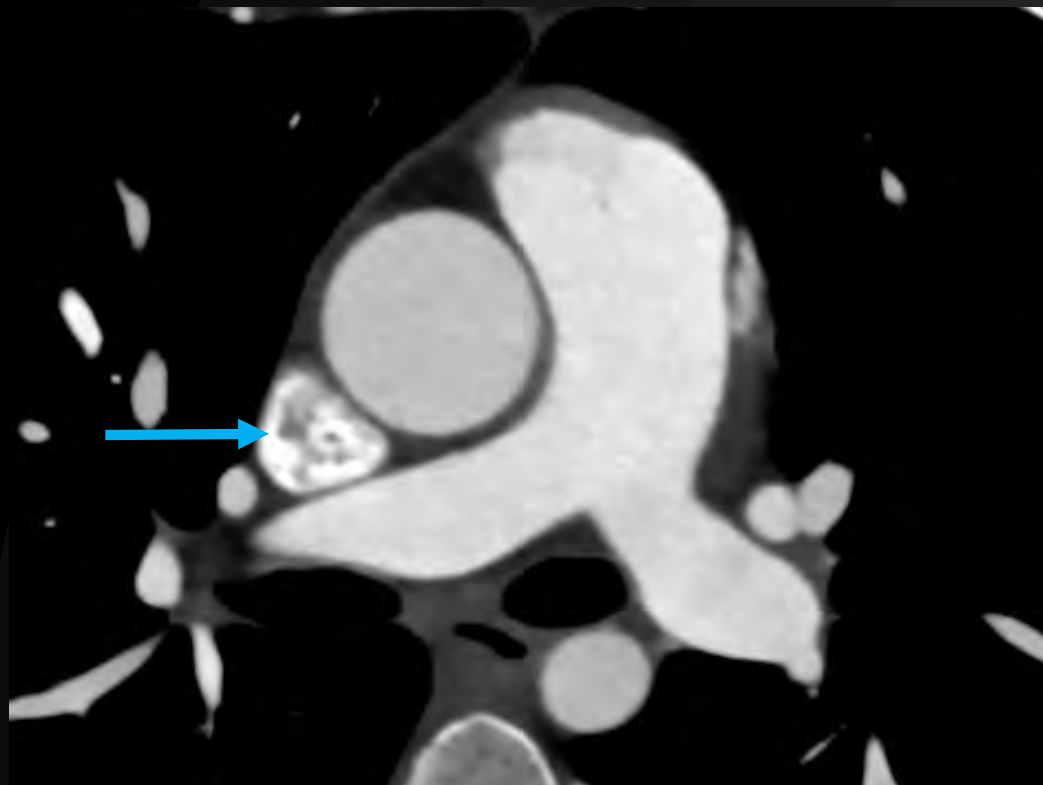
Veines caves



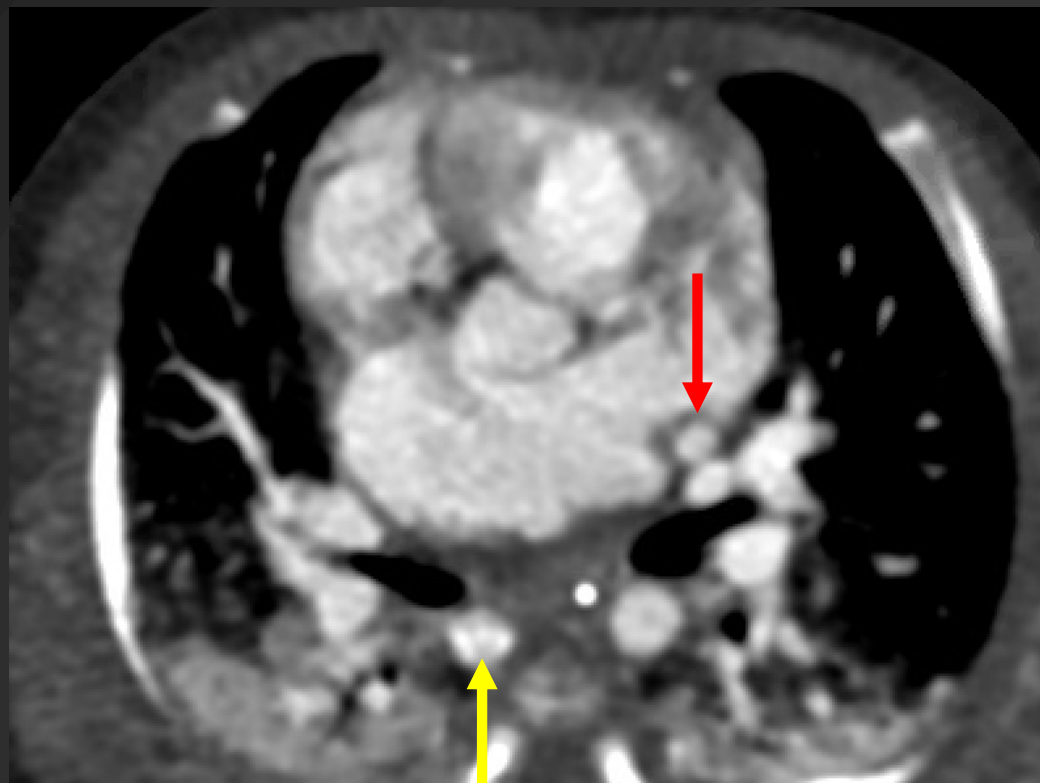
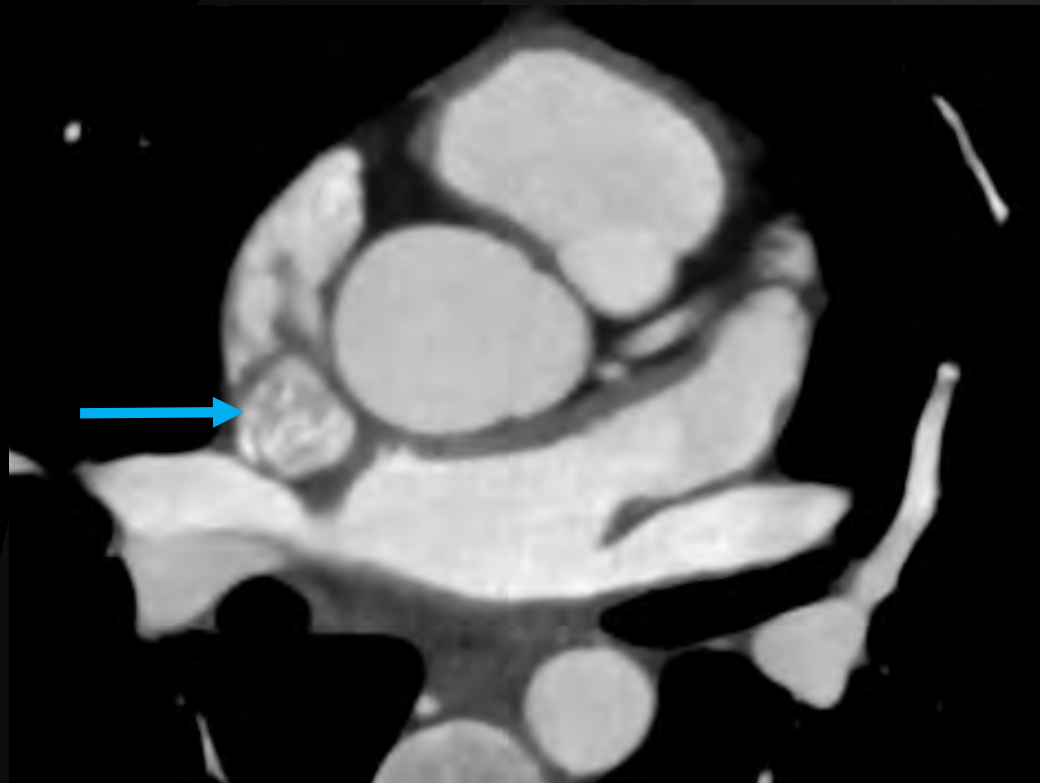
Veines caves



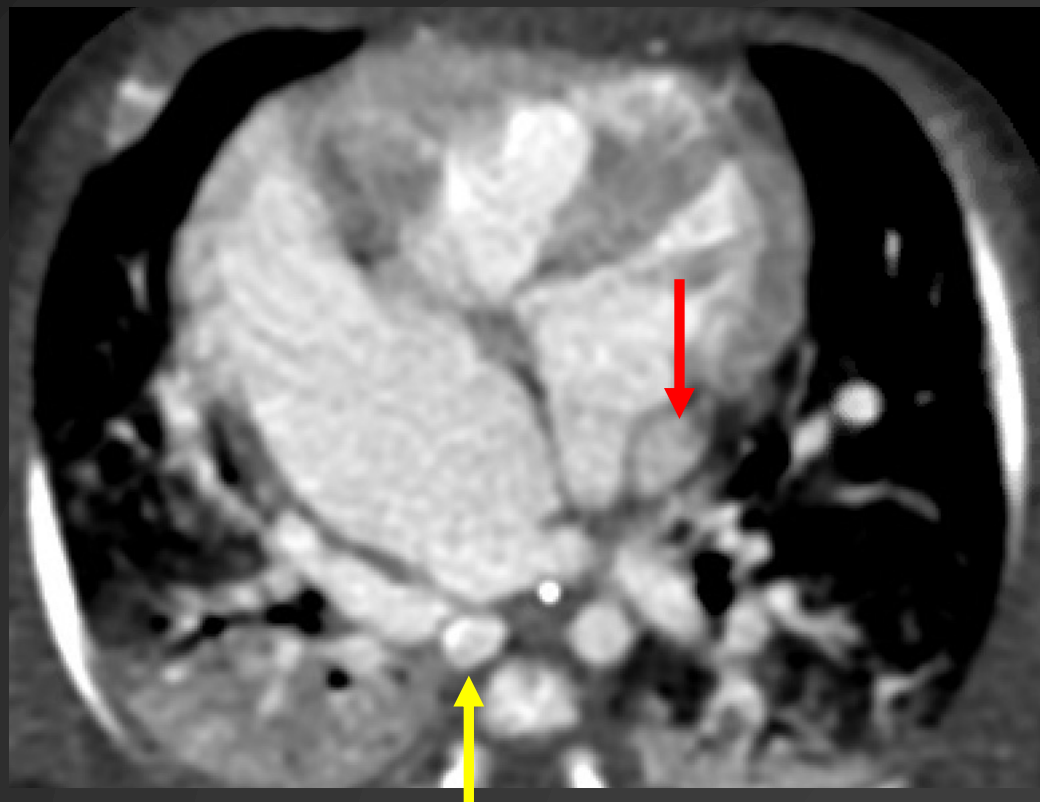
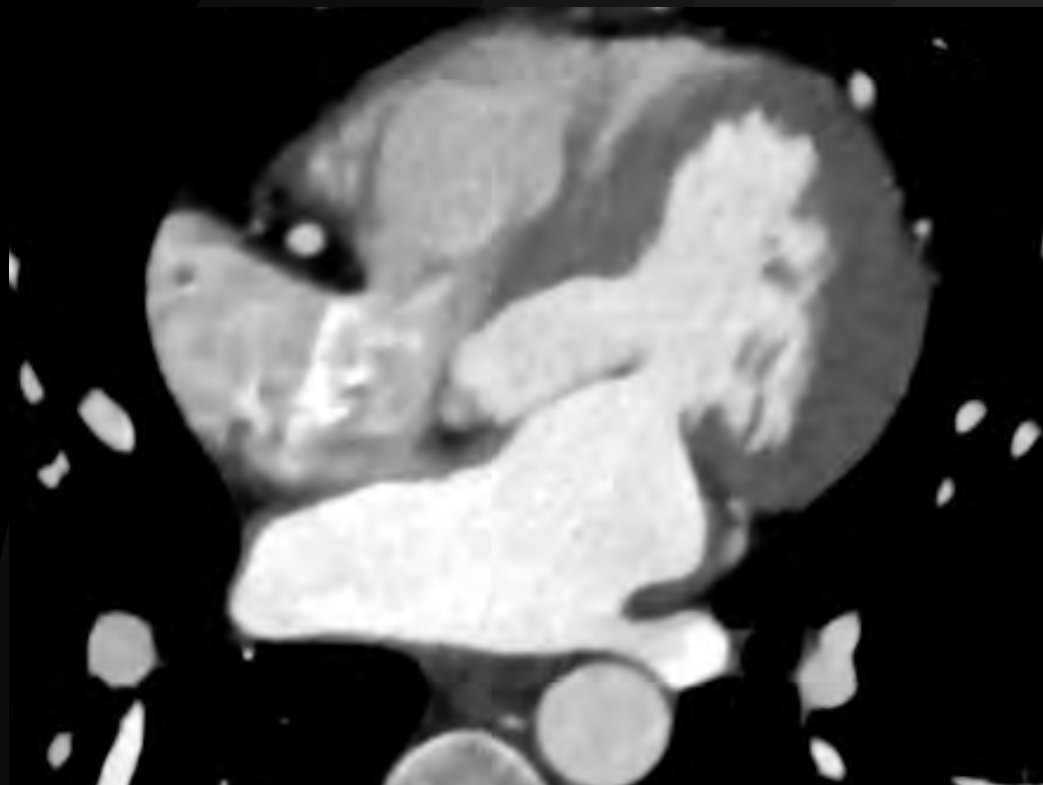
Veines caves



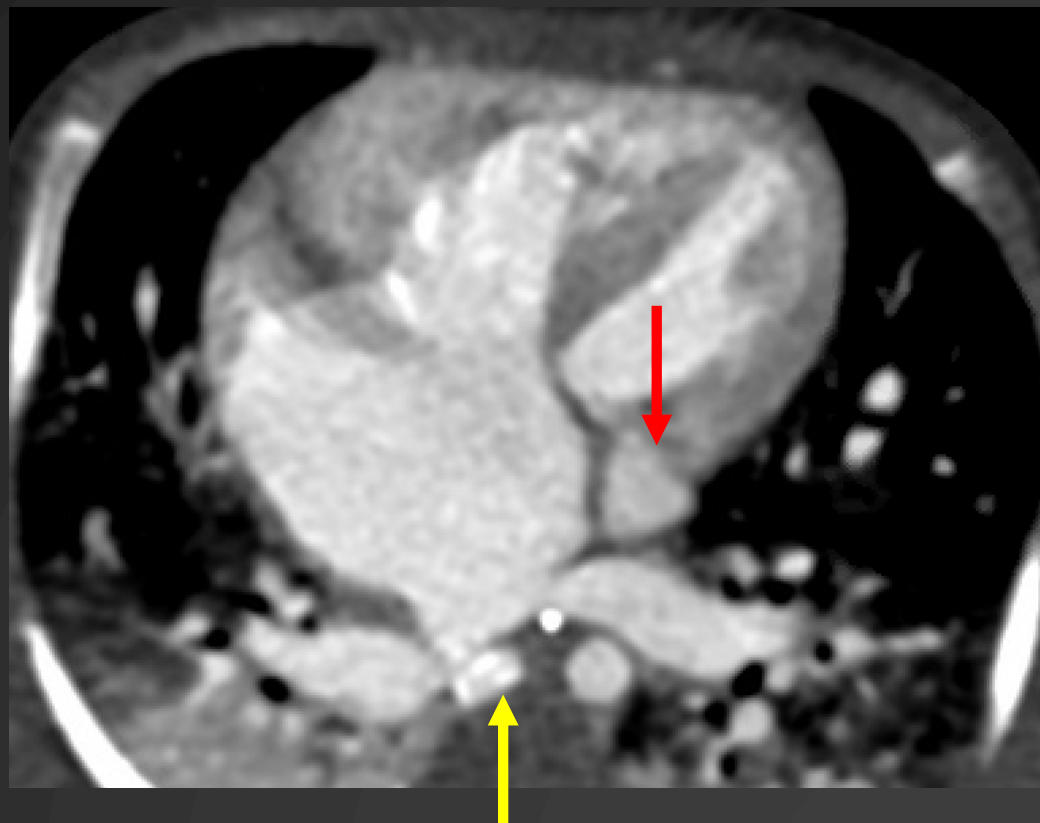
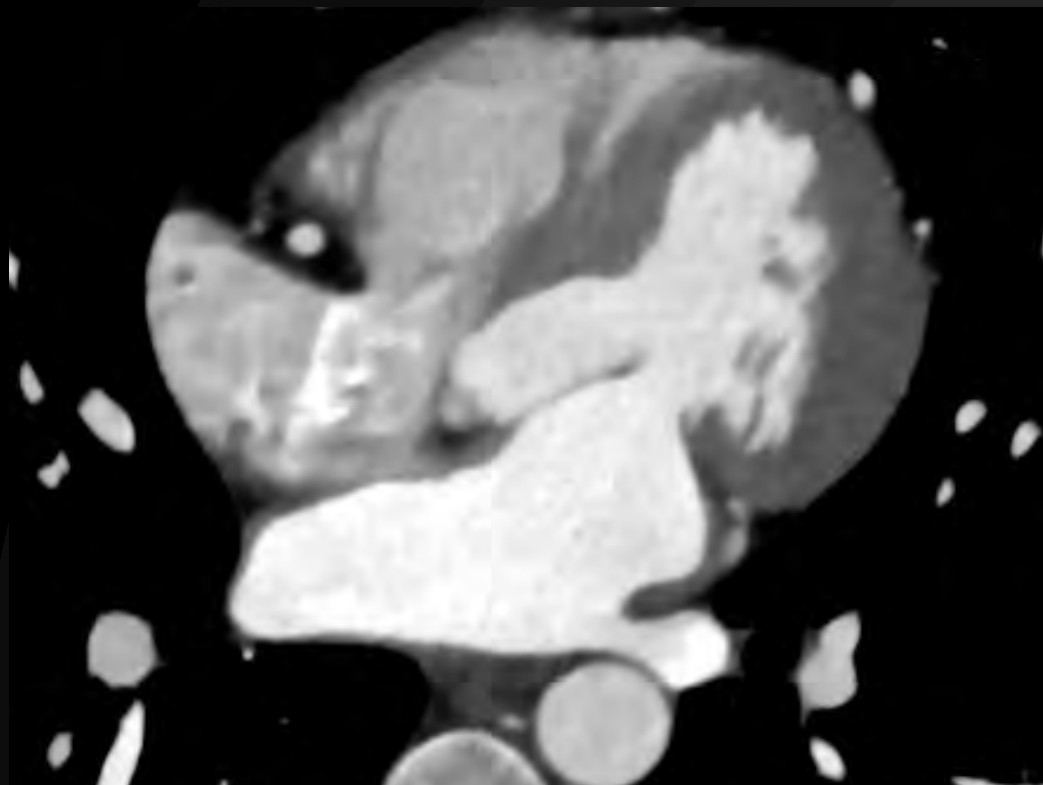
Veines caves



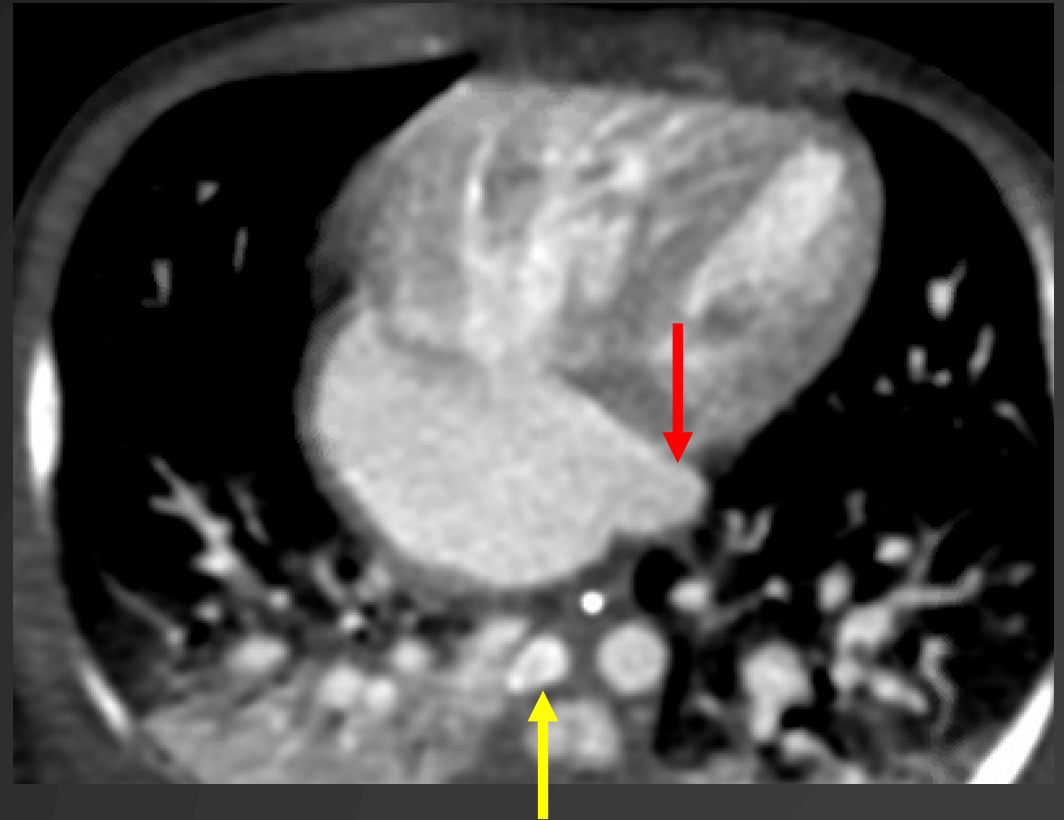
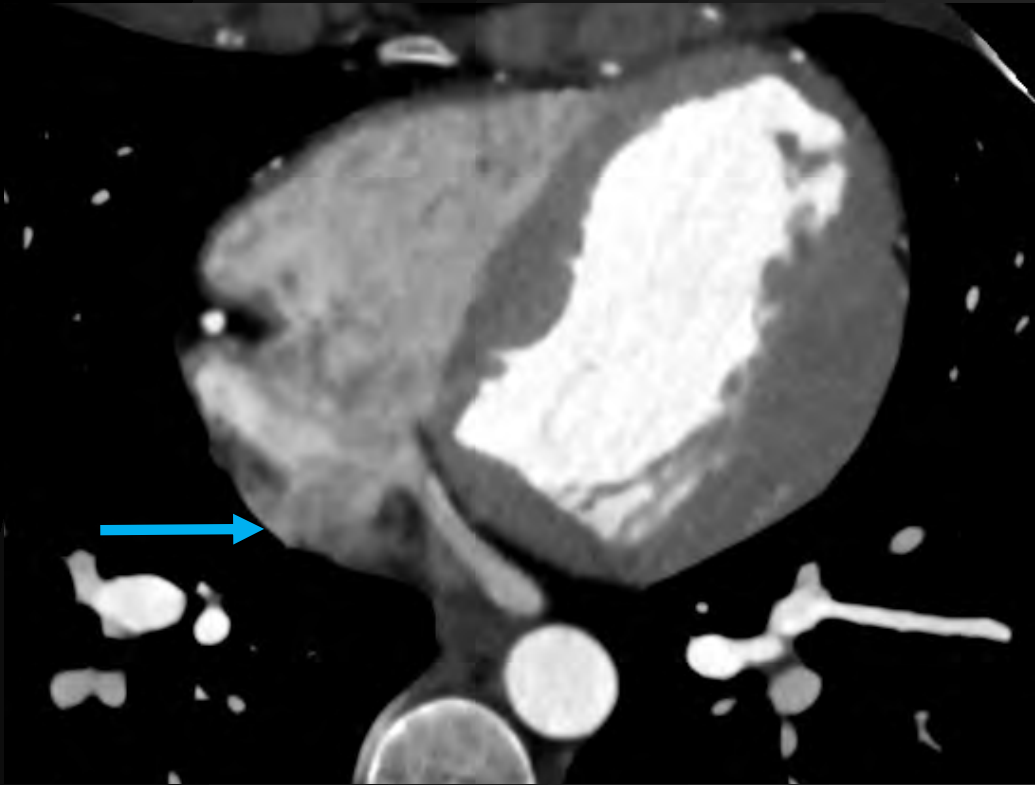
Veines caves



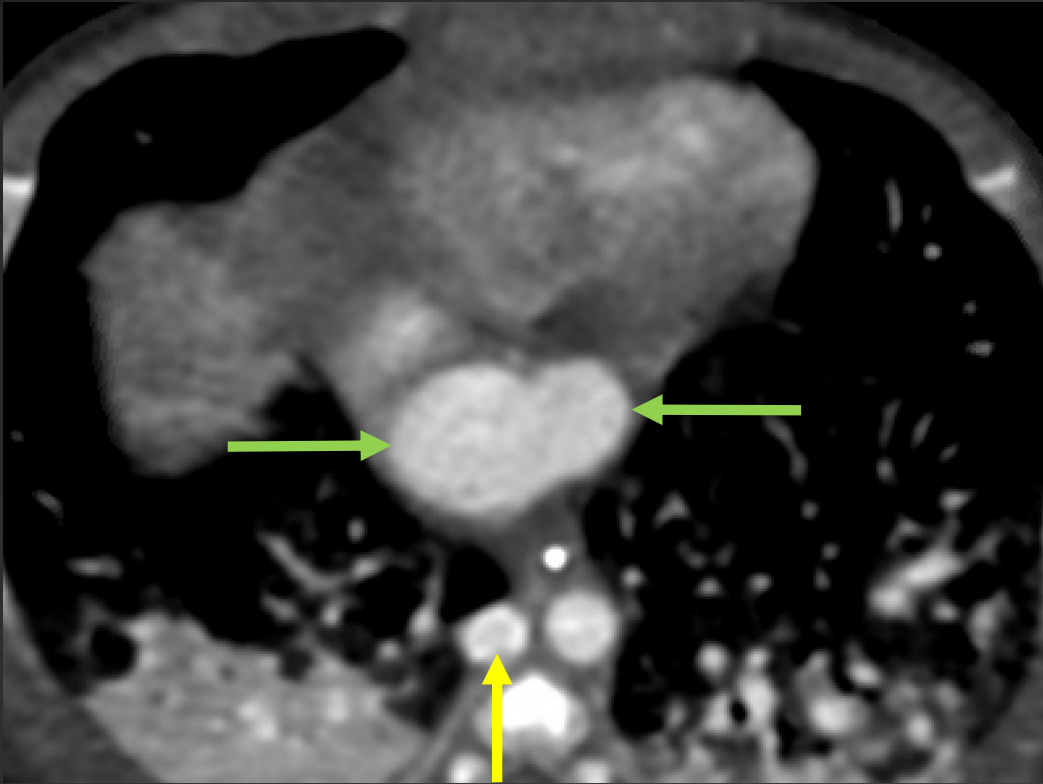
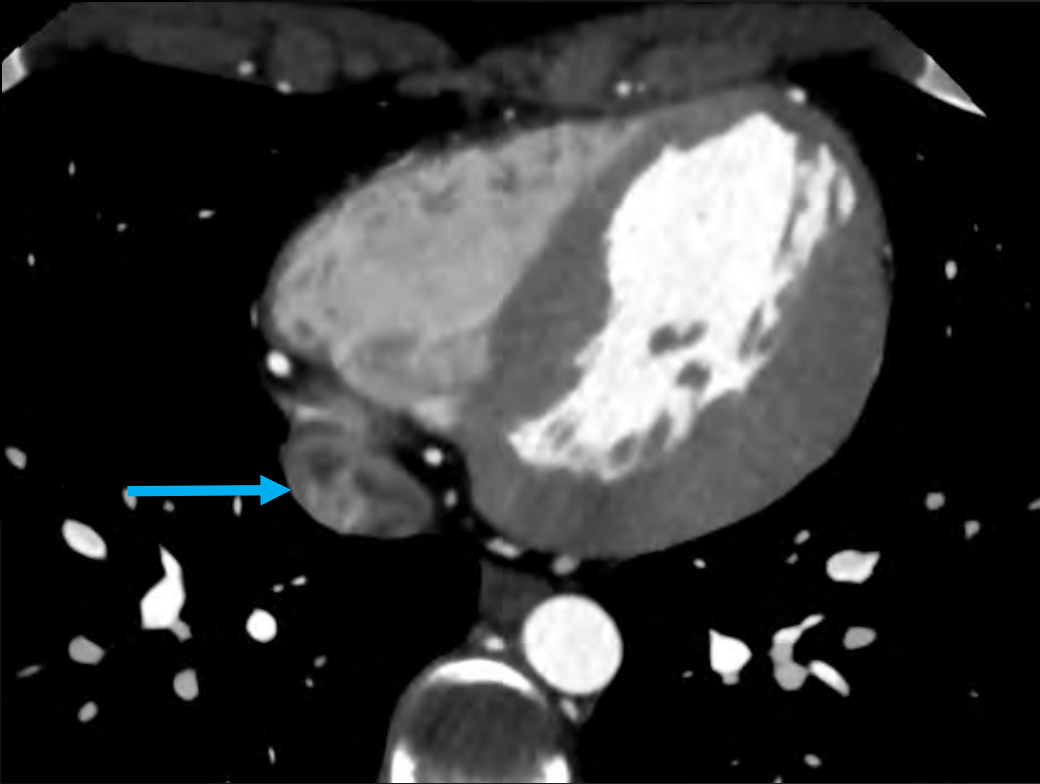
Veines caves



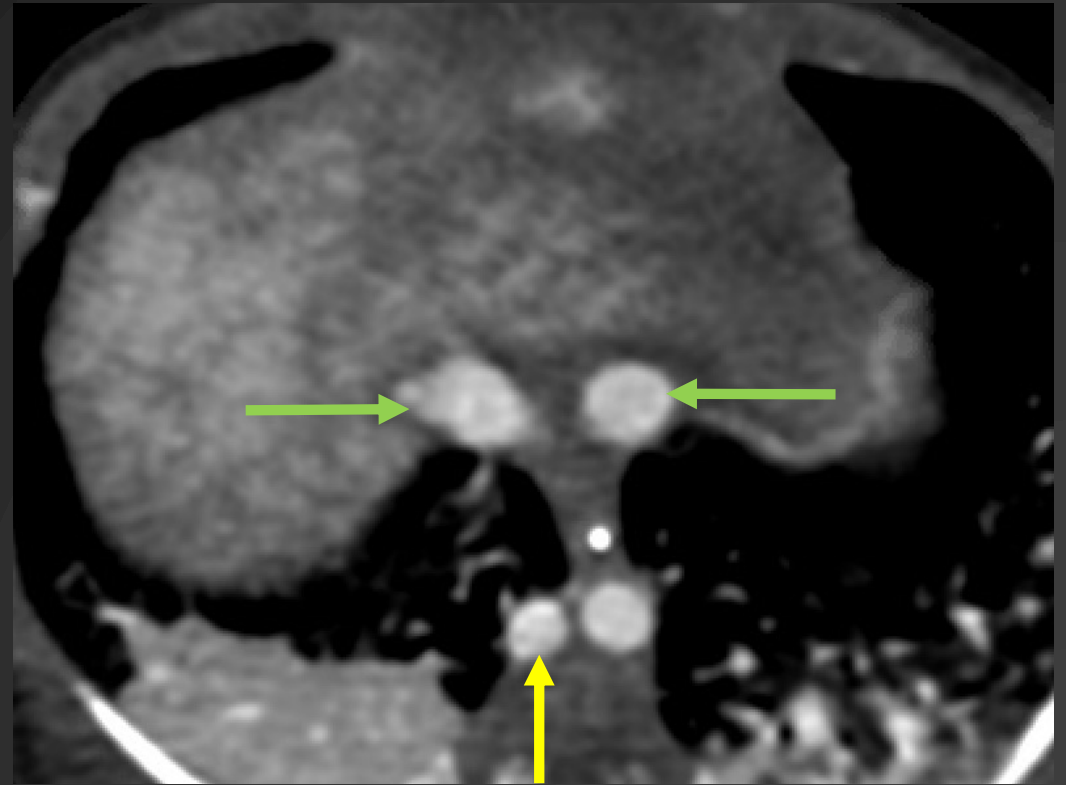
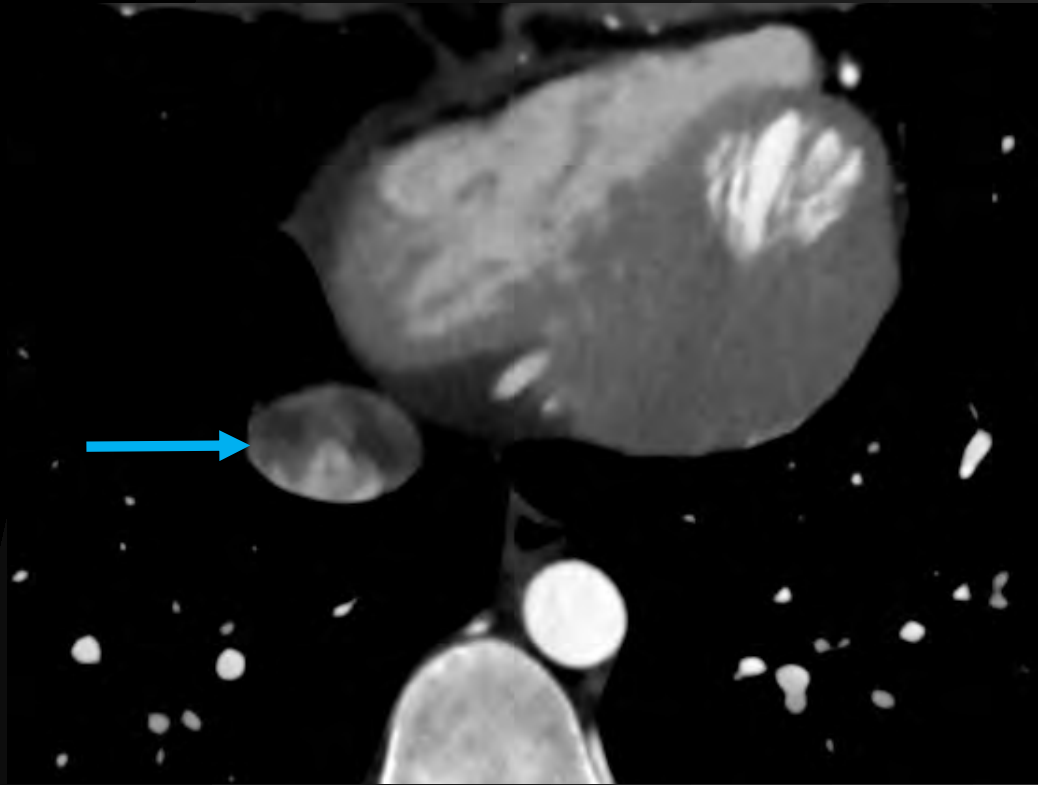
Veines caves



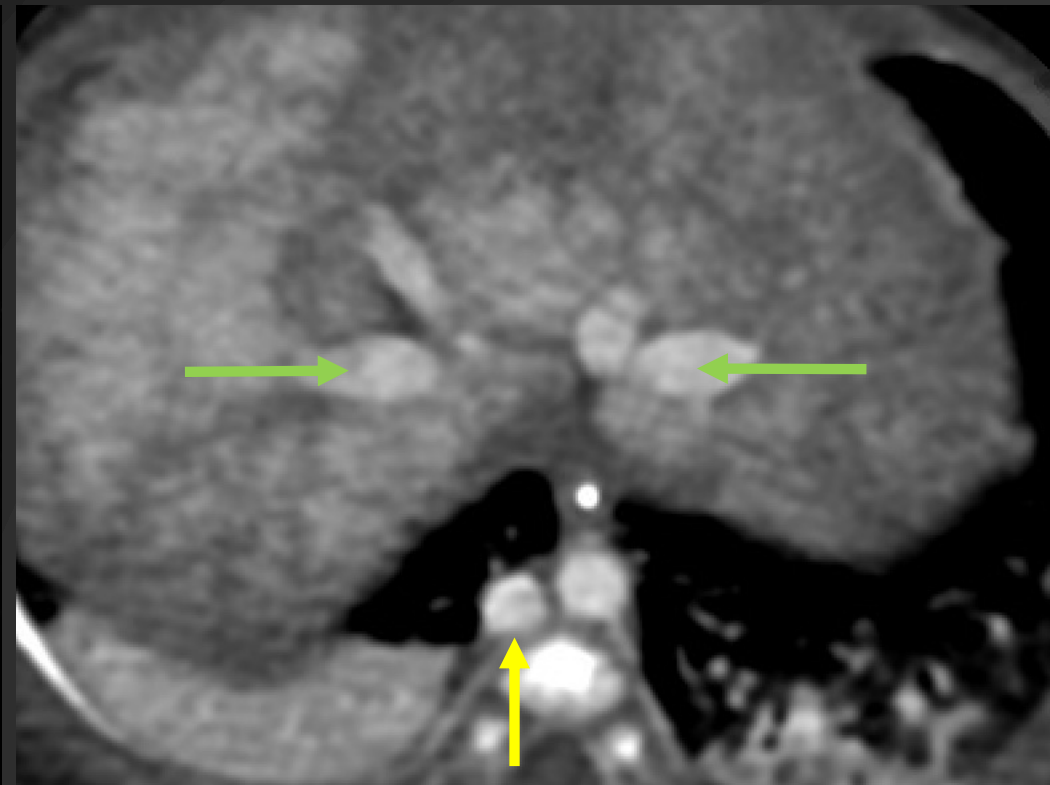
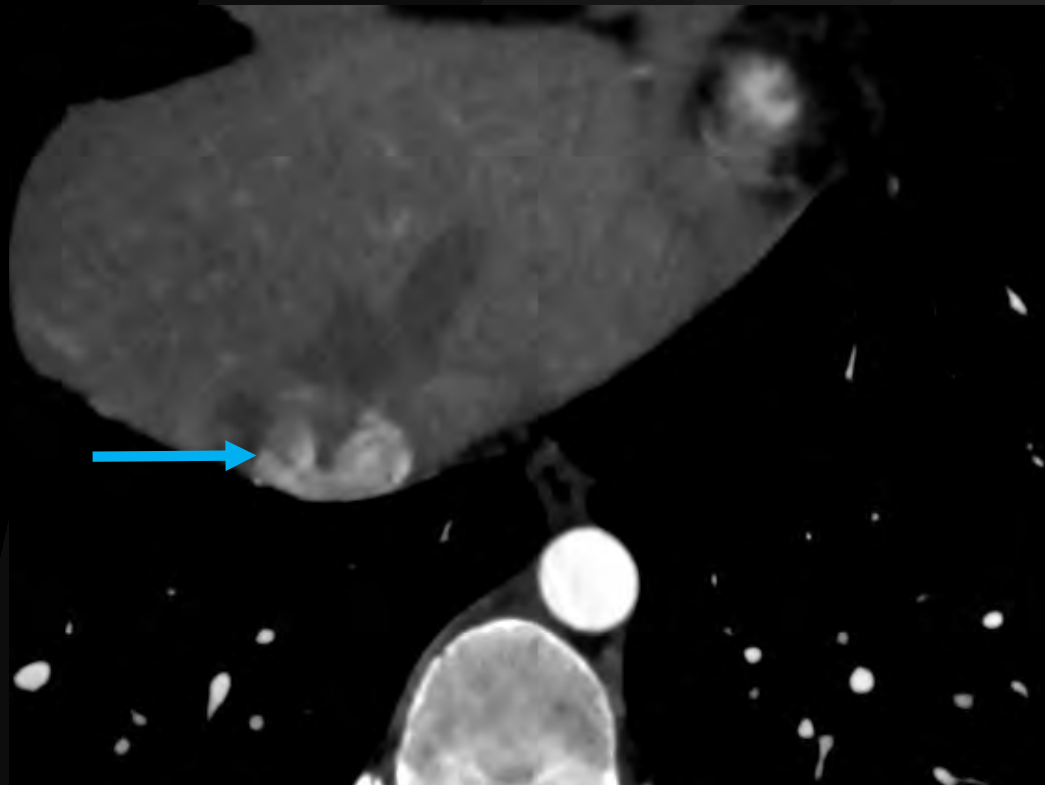
Veines caves



Veines caves



Veines caves

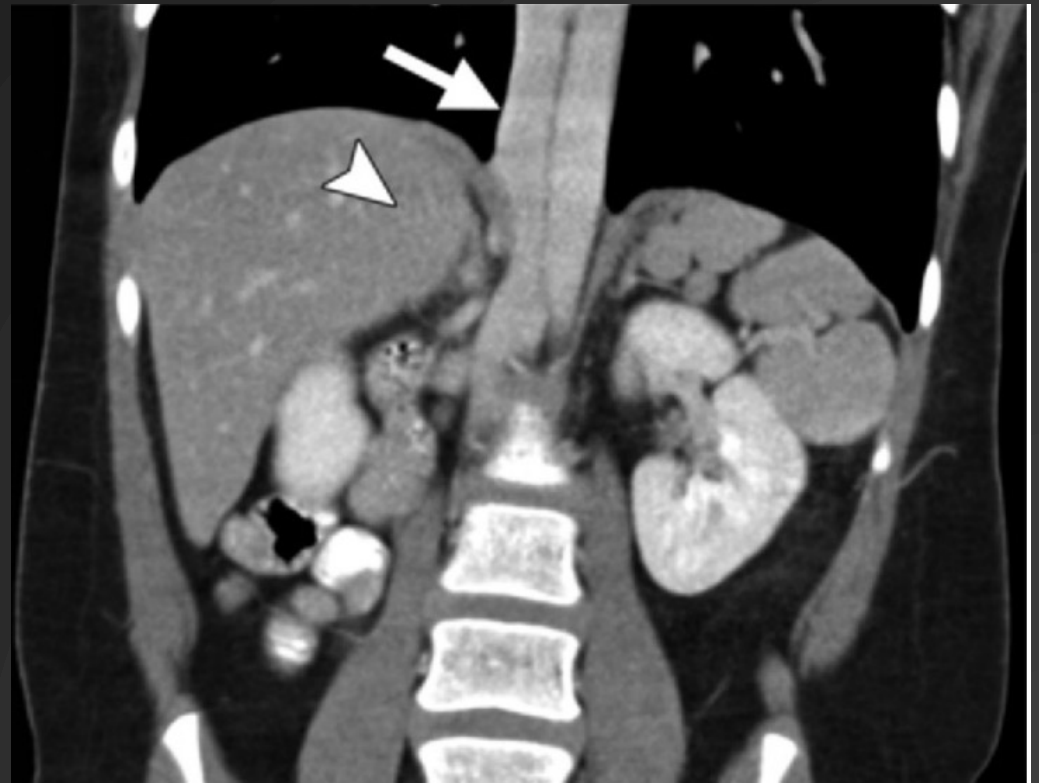


Veines caves

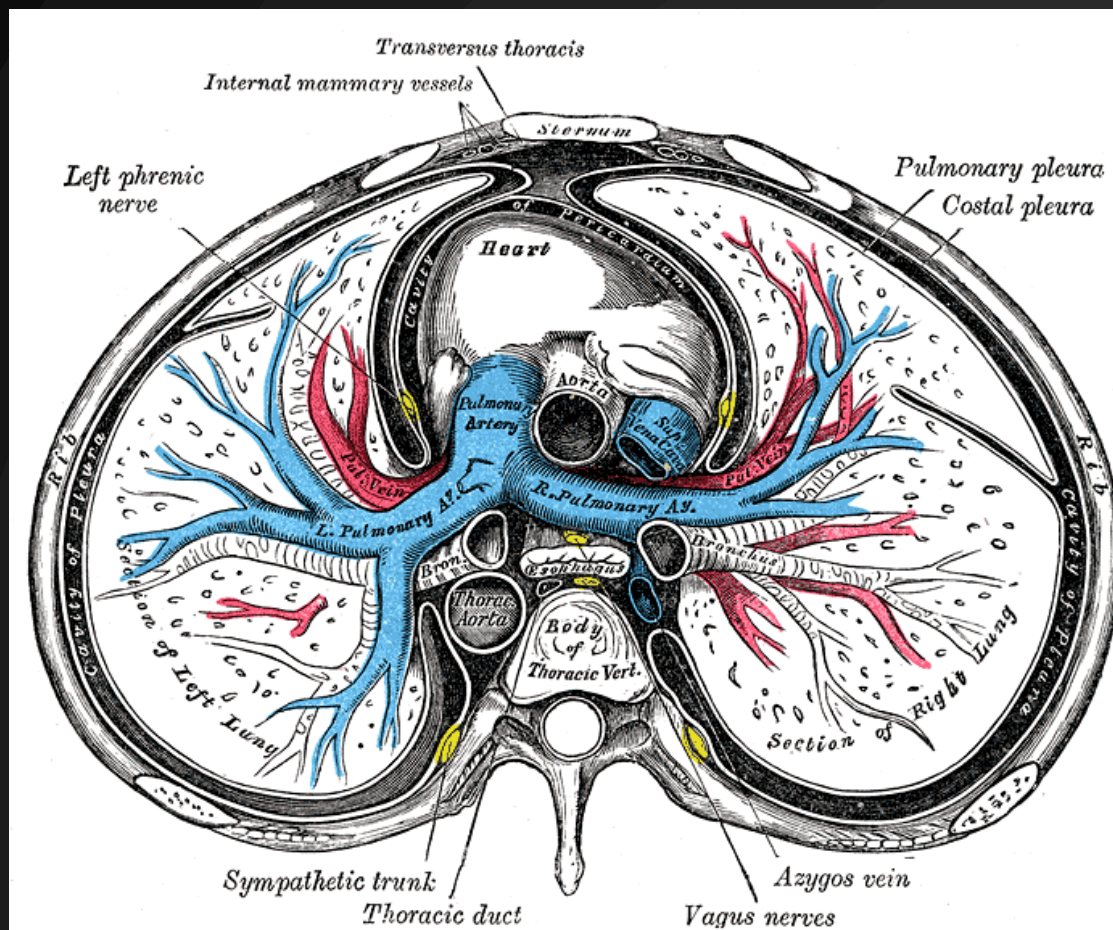
Retour veineux azygos

- Agénésie de la VCI rétro-hépatique
- Veines hépatiques se drainent dans l'oreillette
- Dilatation azygos

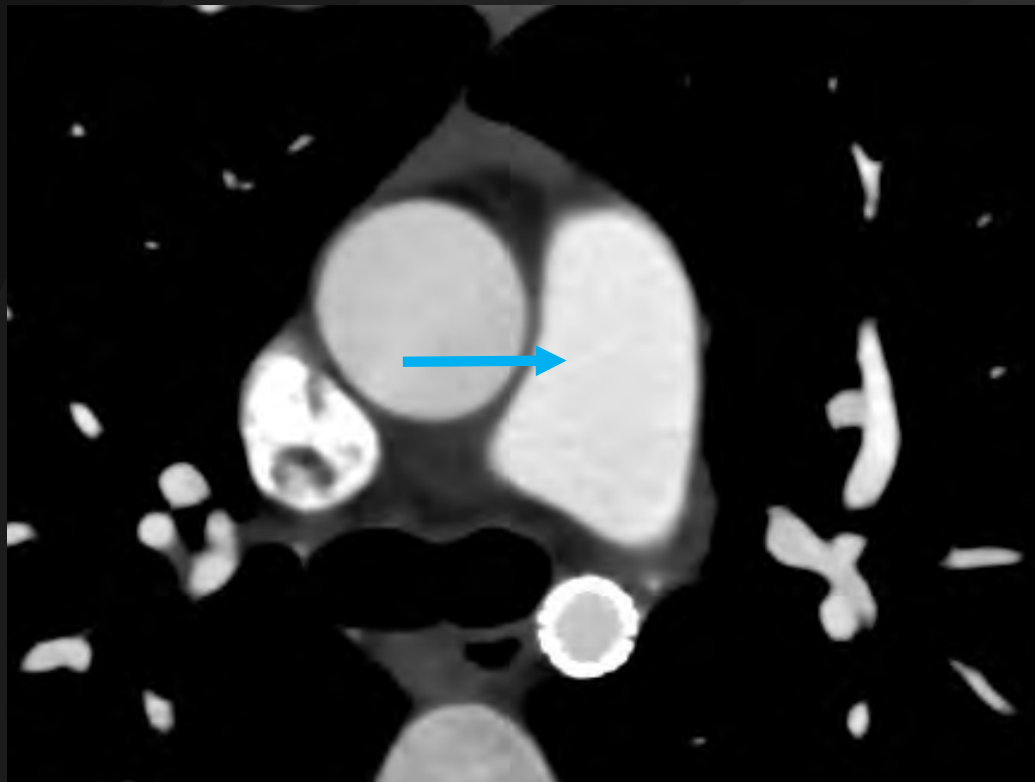
(Isomérisme gauche)



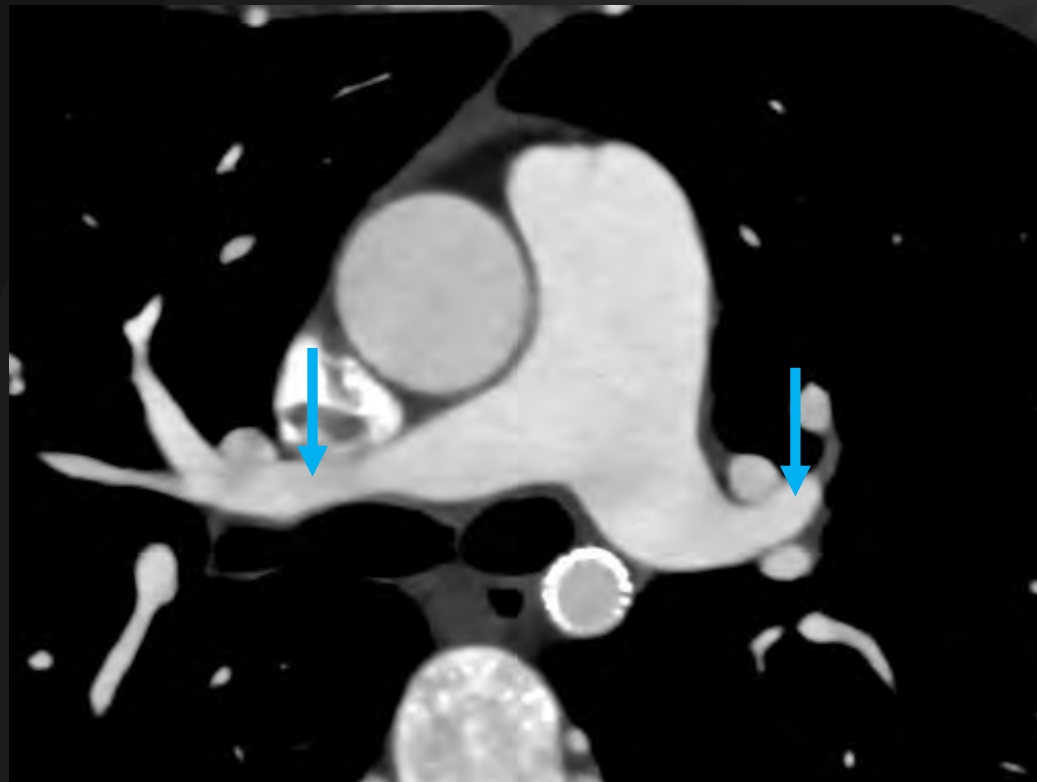
Artères pulmonaires



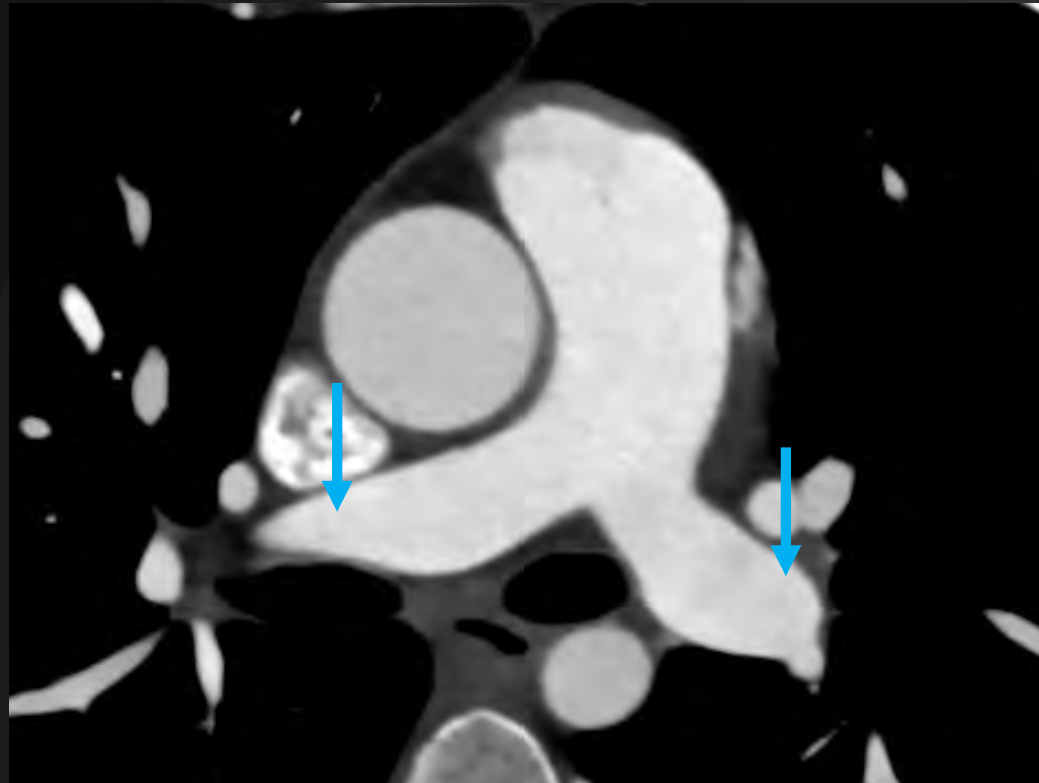
Artères pulmonaires



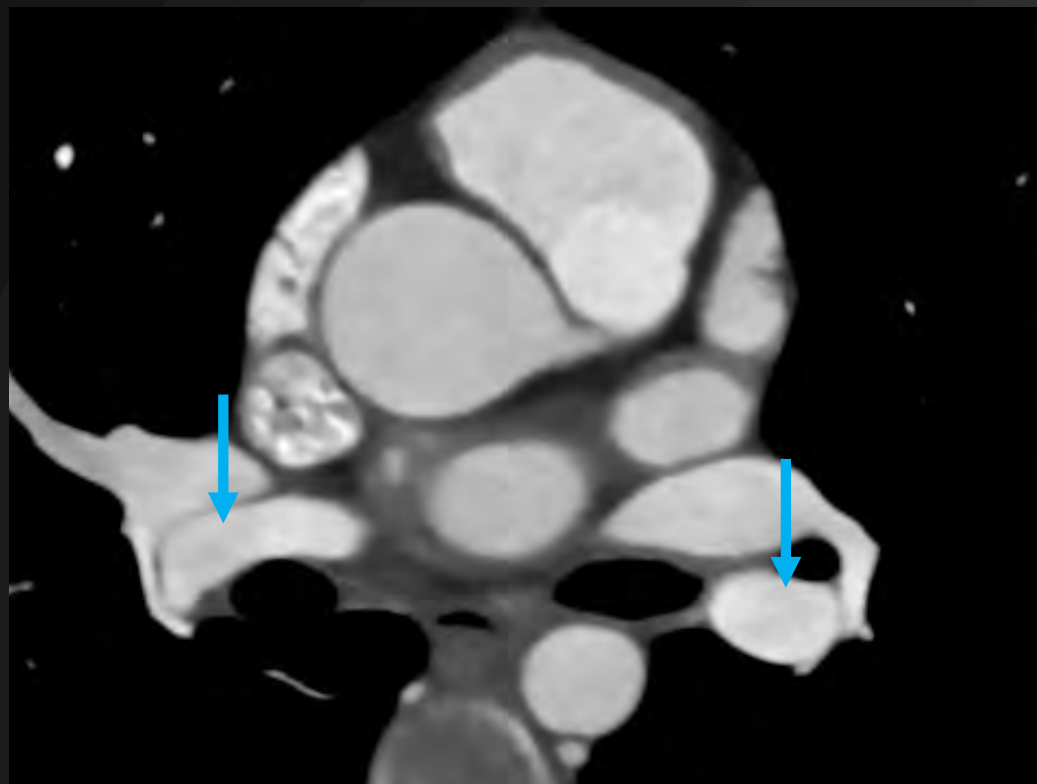
Artères pulmonaires



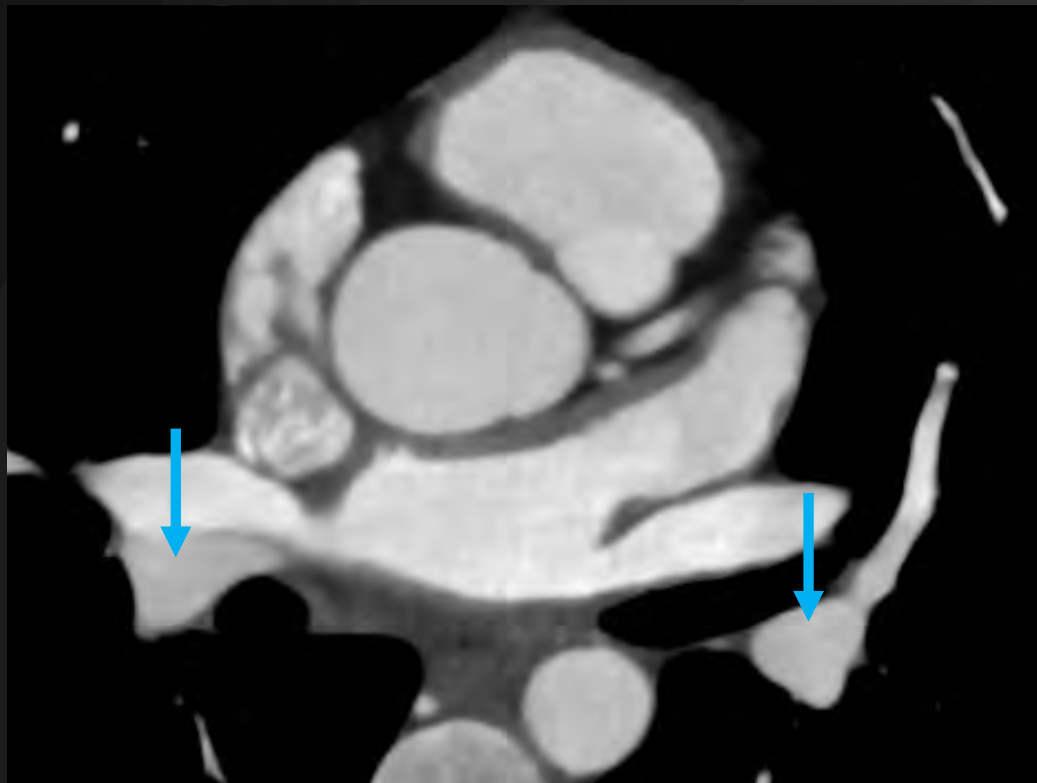
Artères pulmonaires



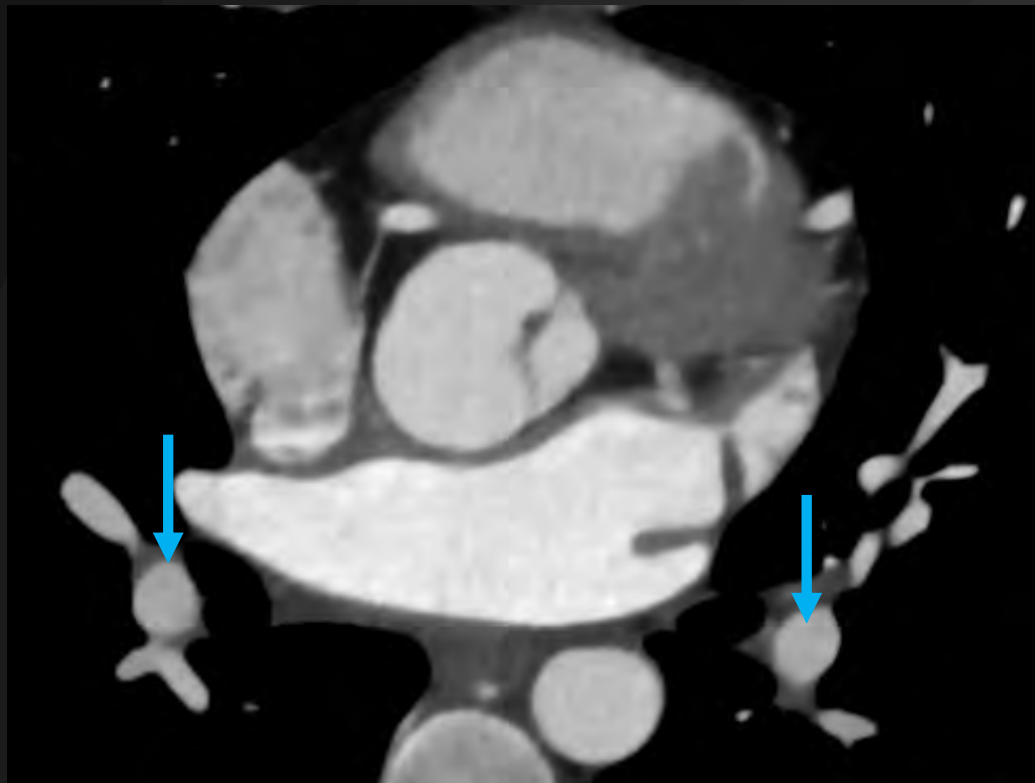
Artères pulmonaires



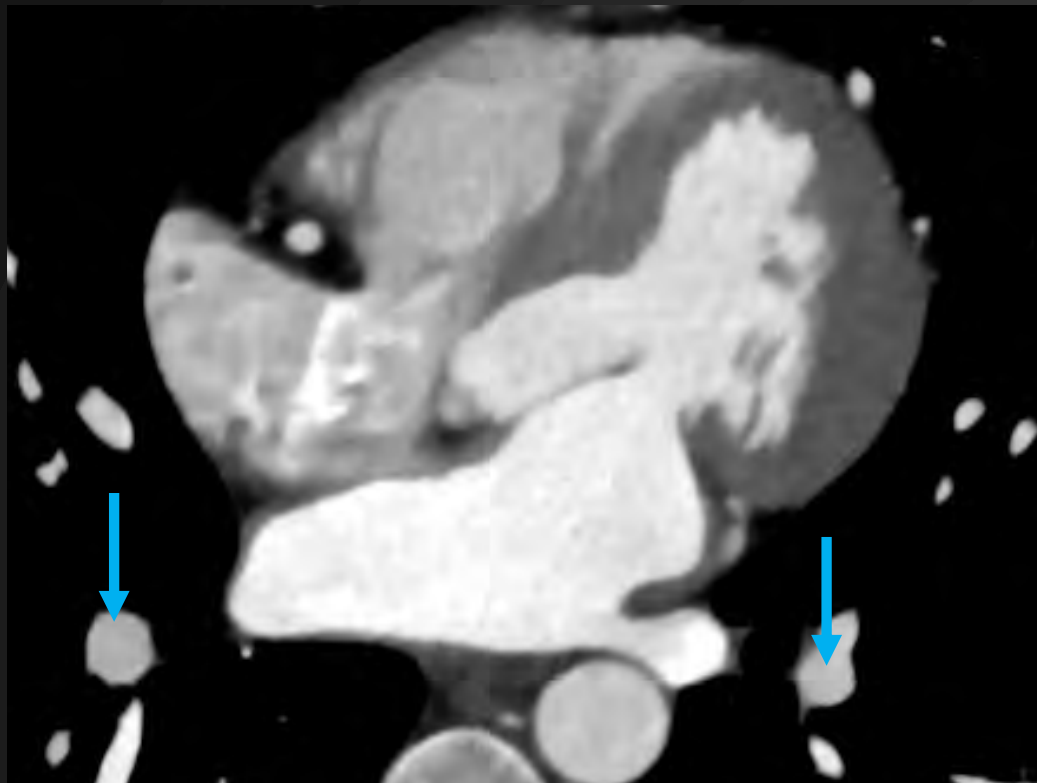
Artères pulmonaires



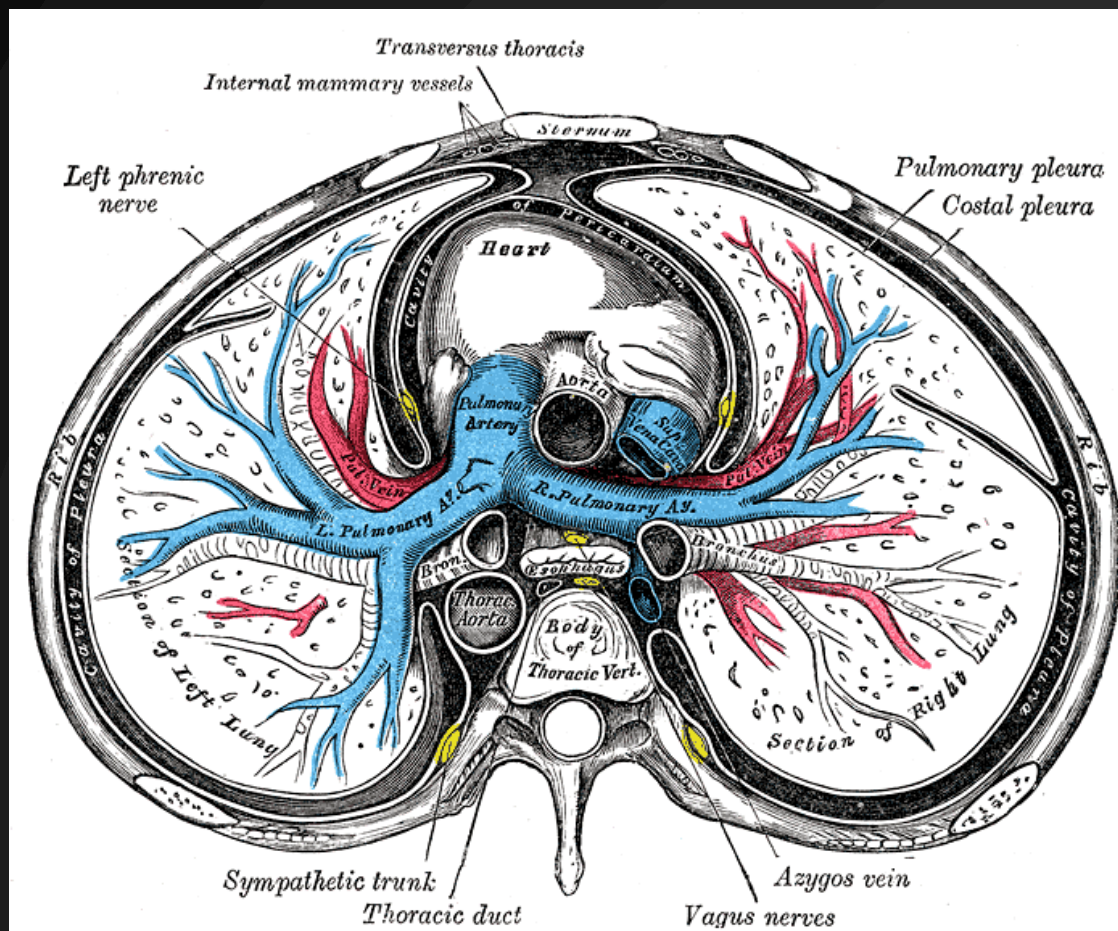
Artères pulmonaires



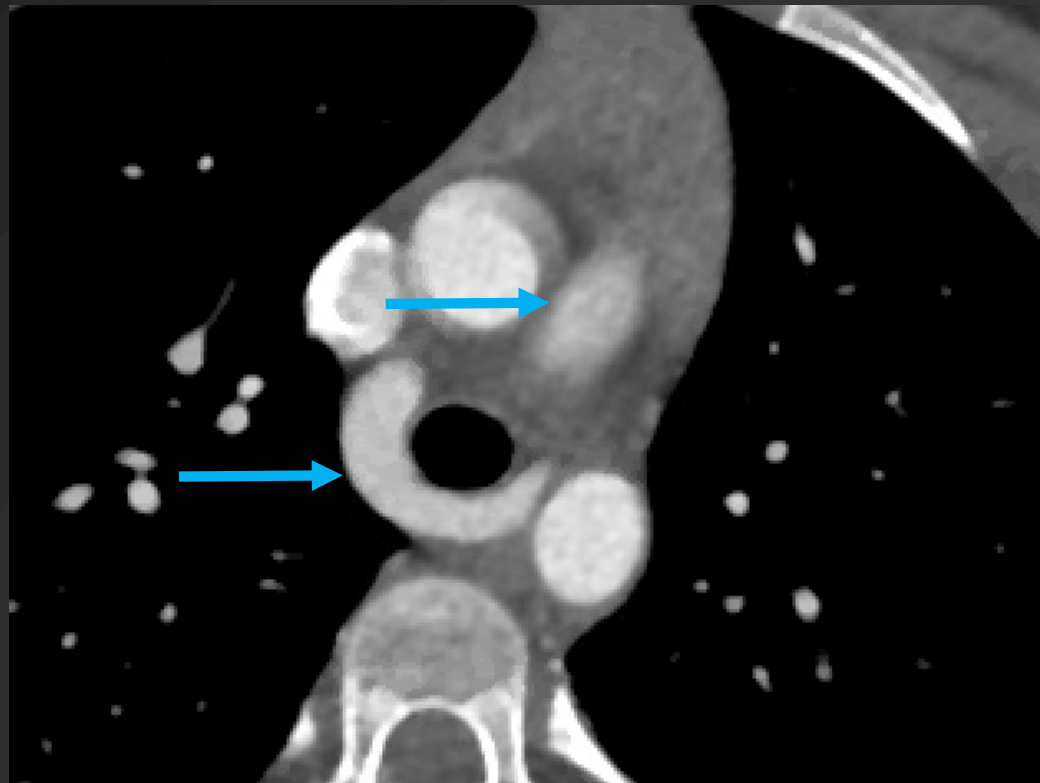
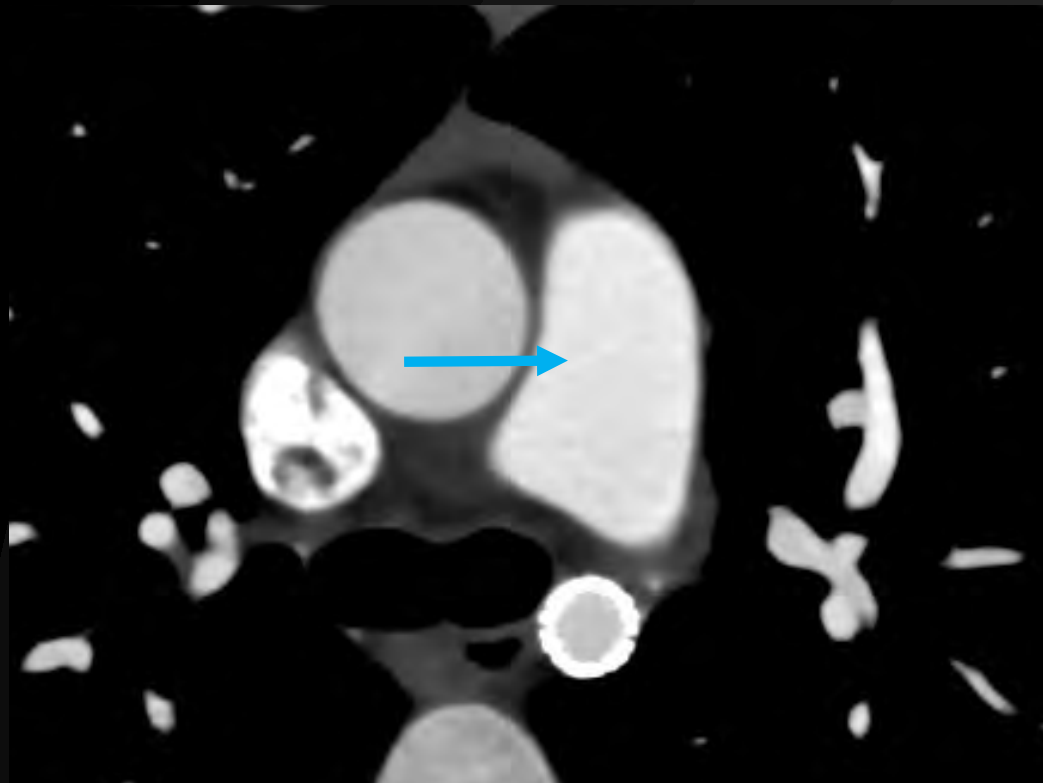
Artères pulmonaires



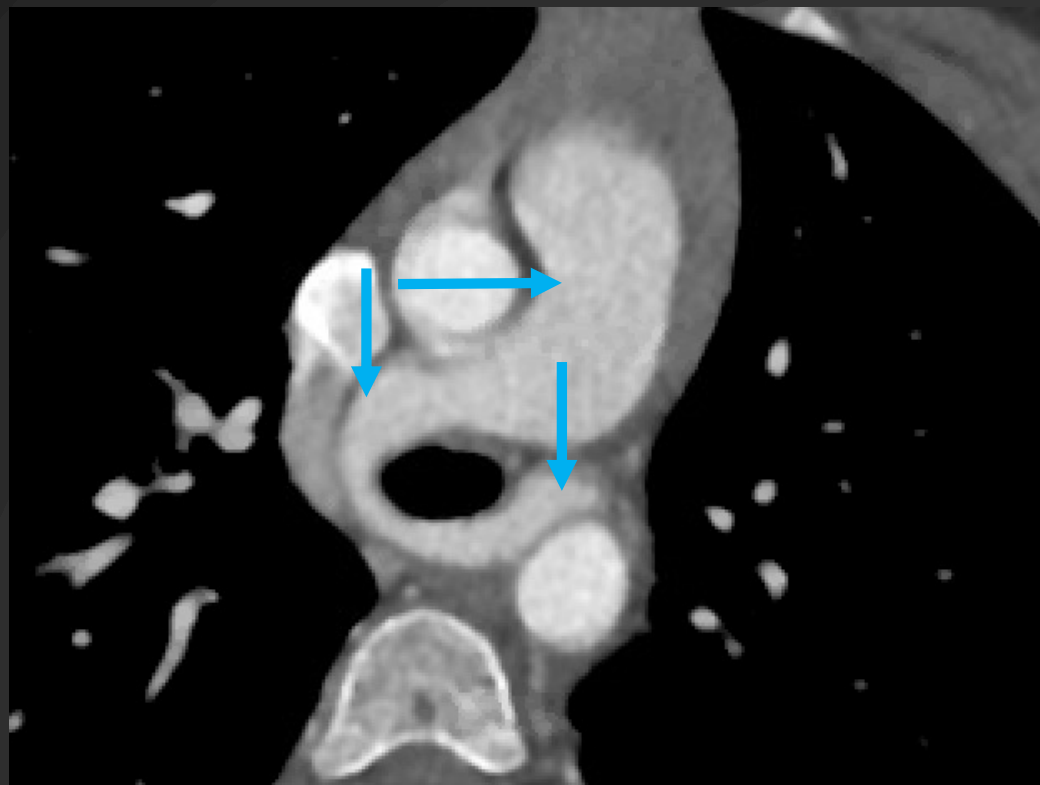
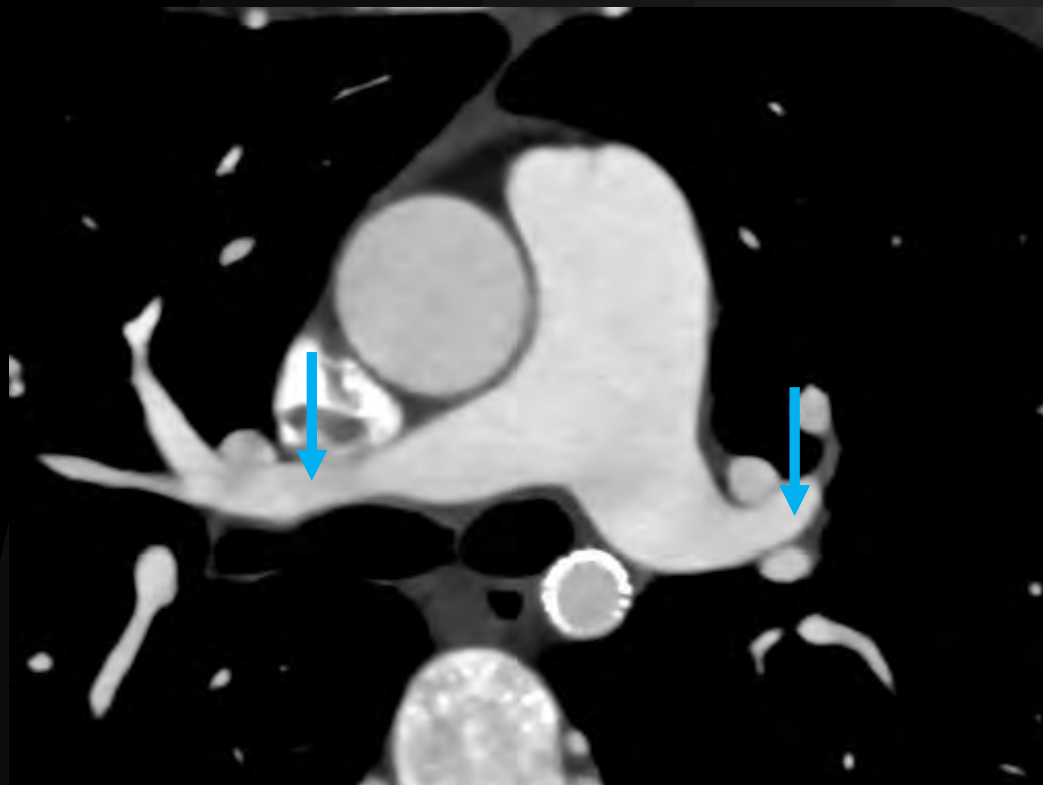
Artères pulmonaires



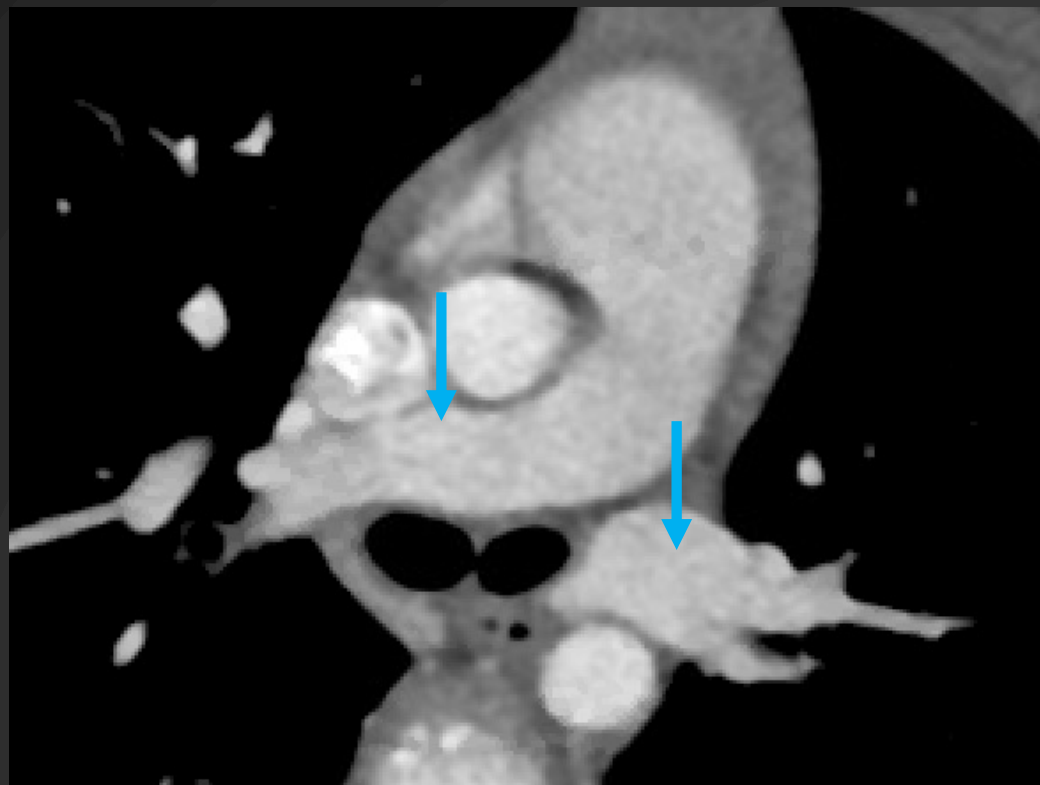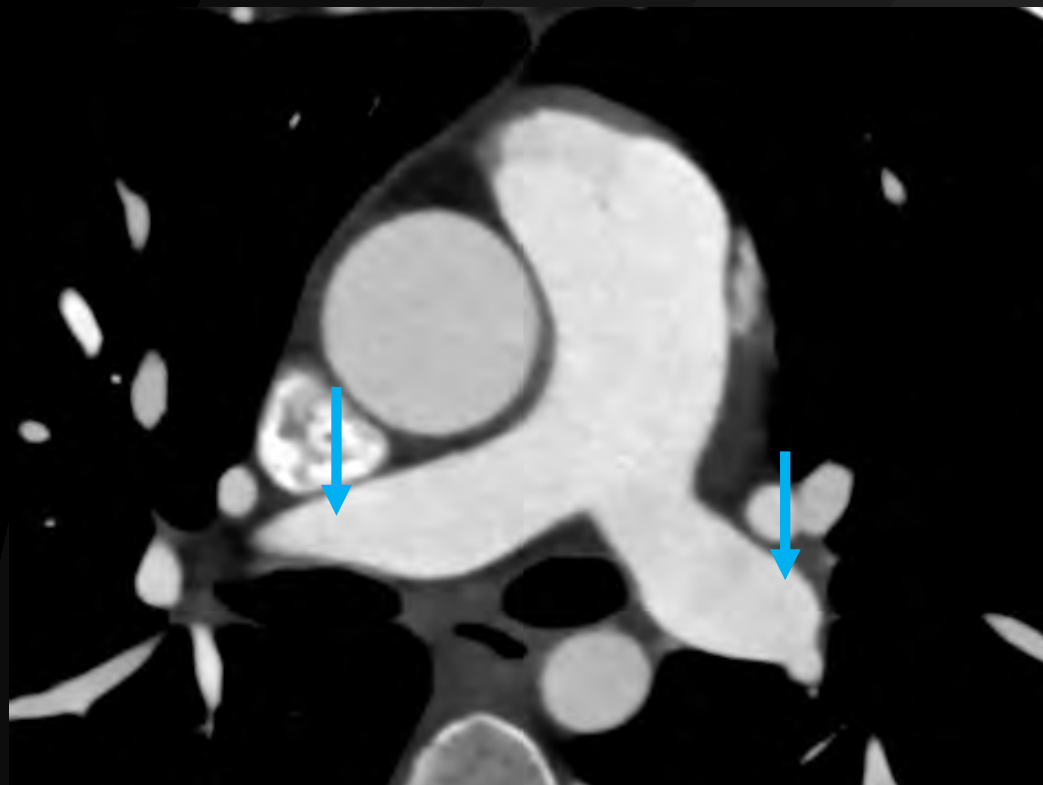
Artères pulmonaires



Artères pulmonaires

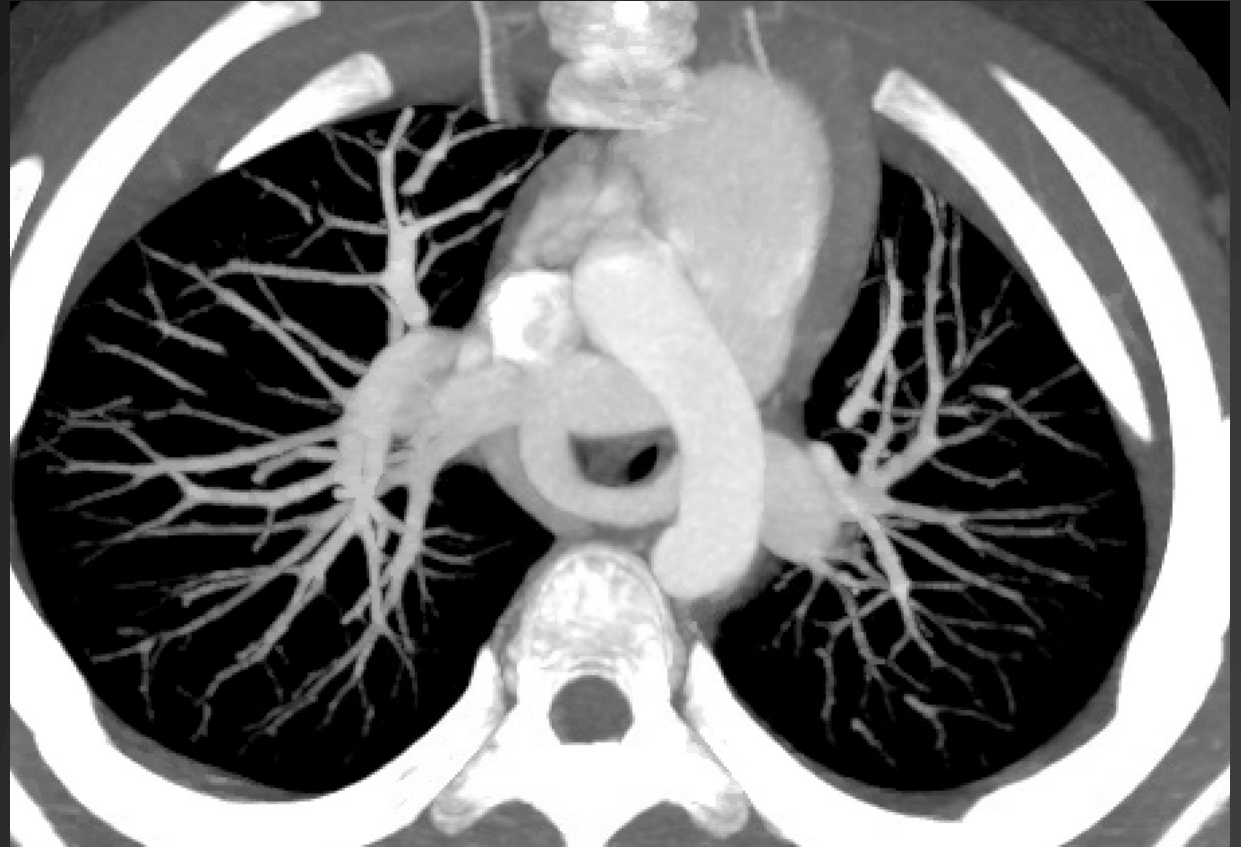


Artères pulmonaires

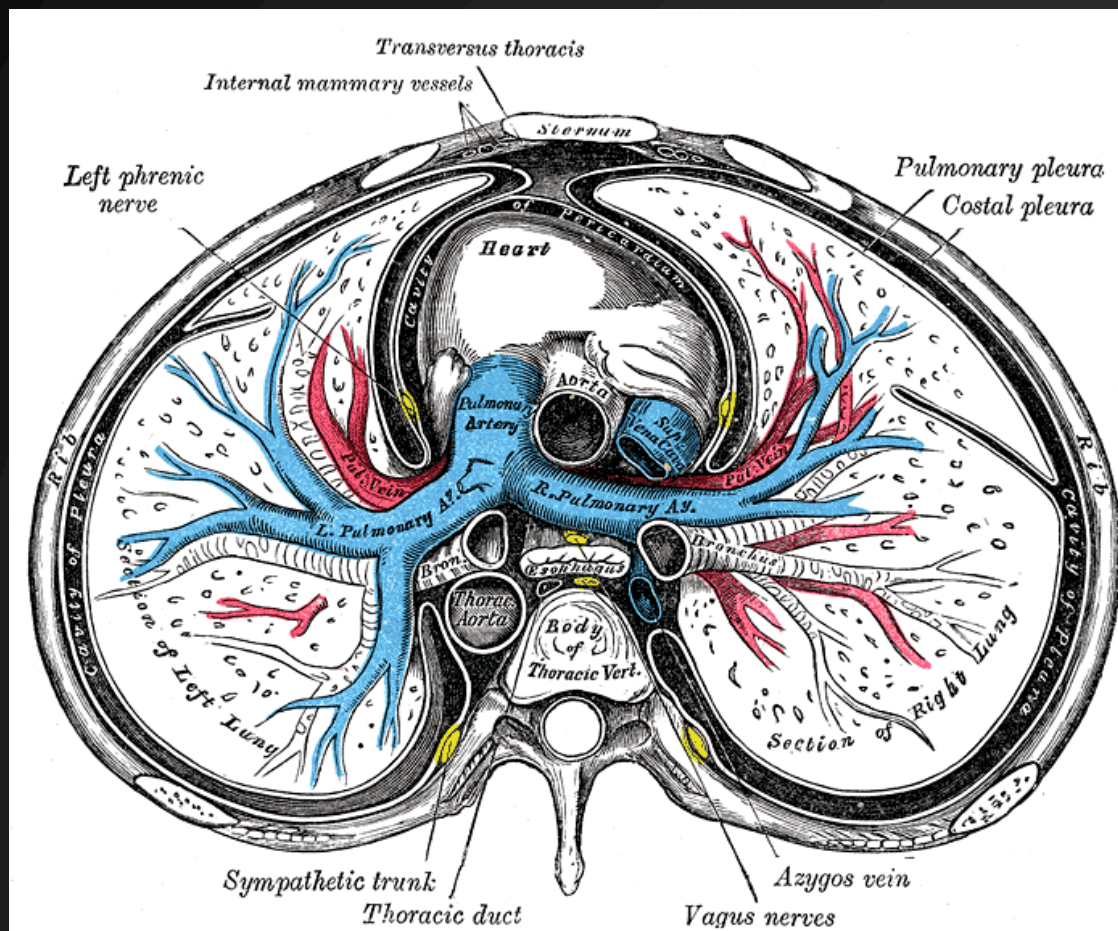


Artères pulmonaires

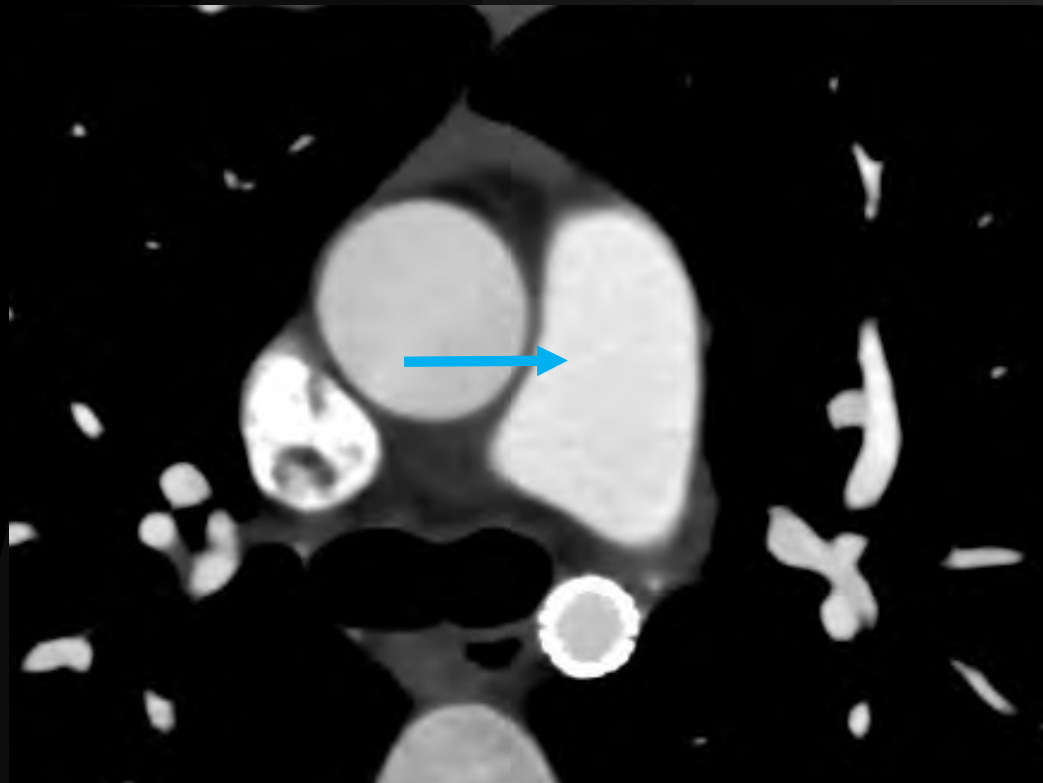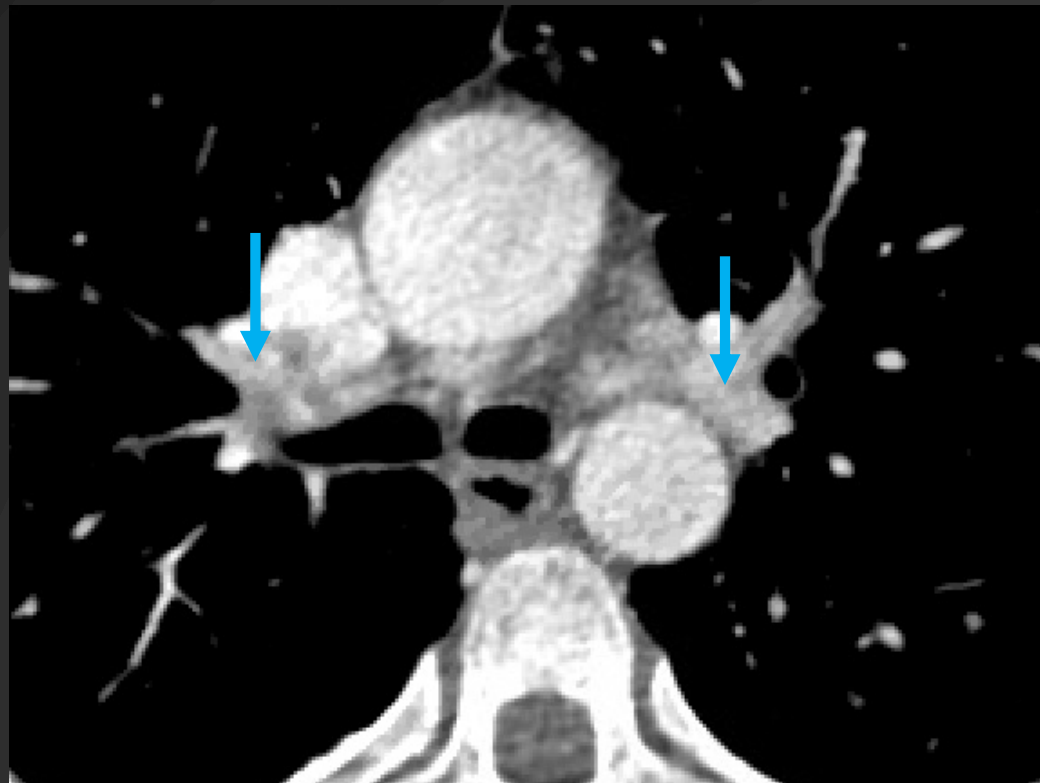
Sling de l'artère pulmonaire gauche



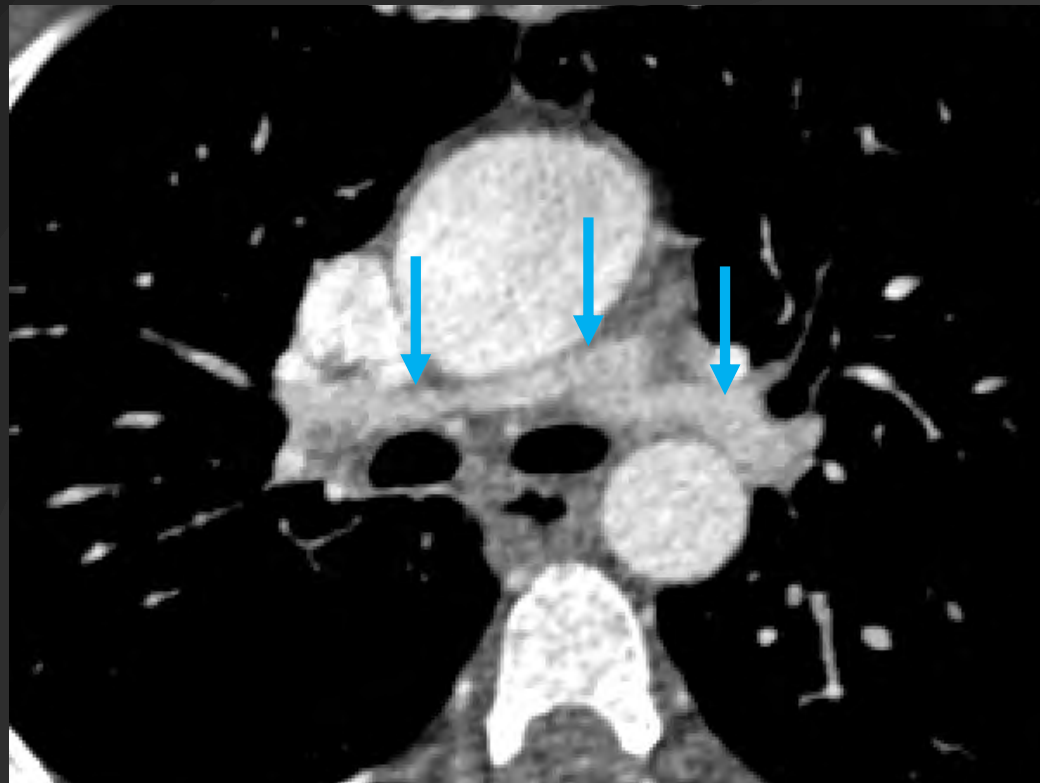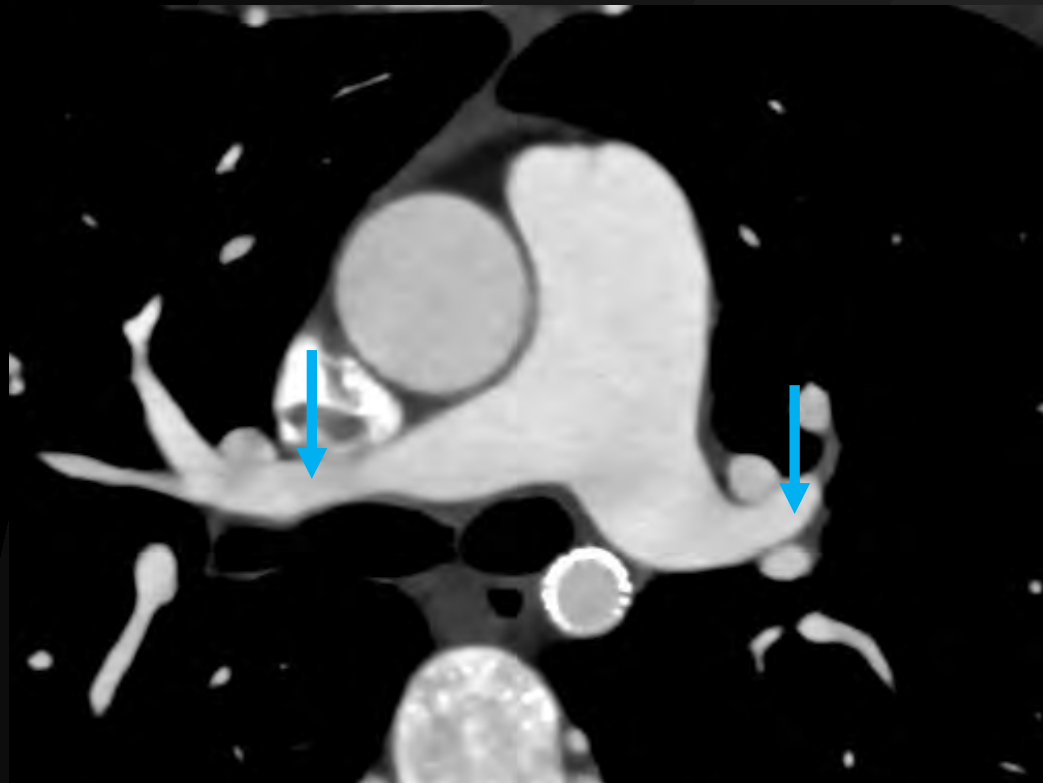
Artères pulmonaires



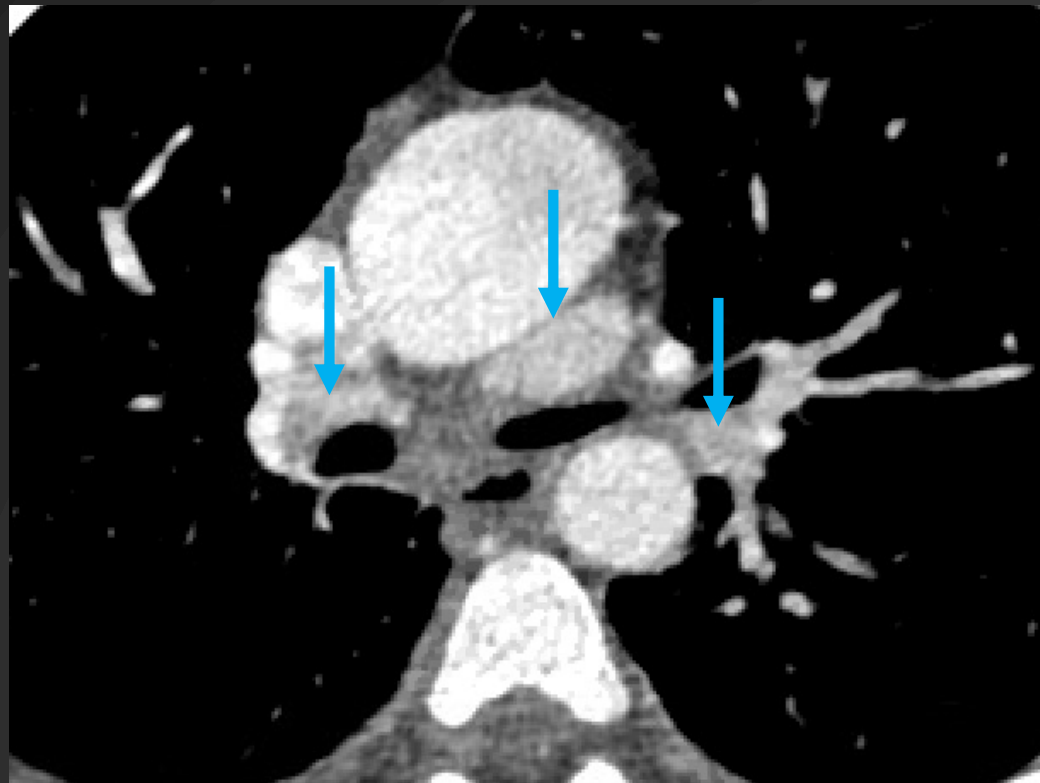
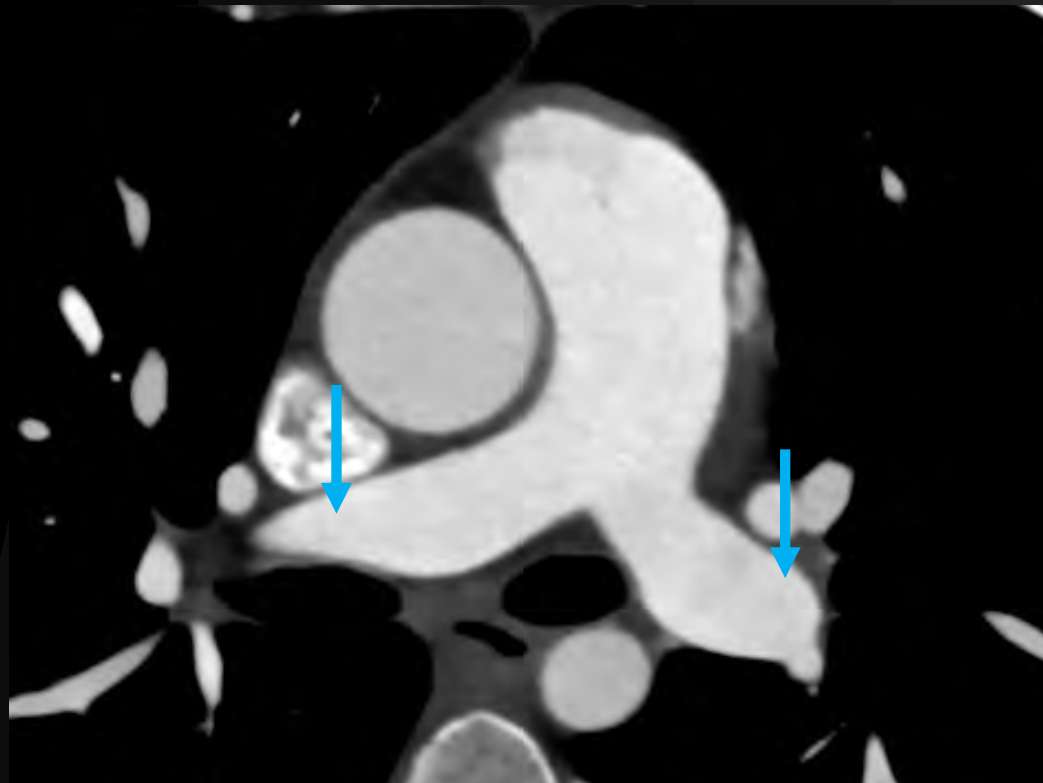
Artères pulmonaires



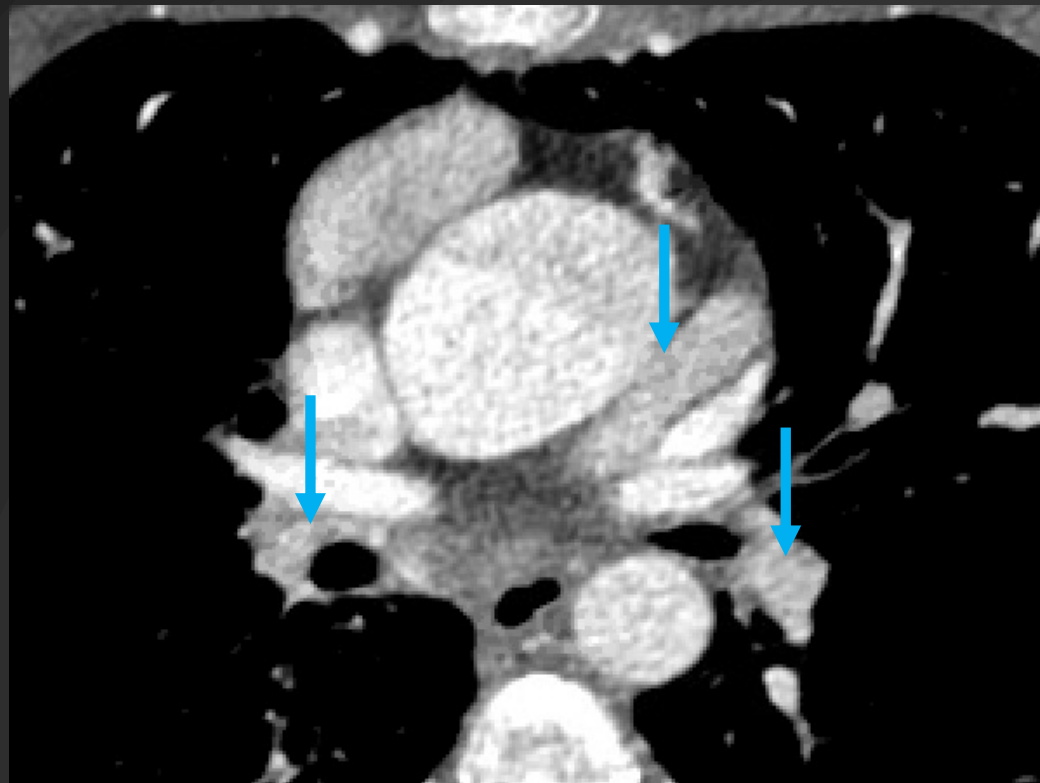
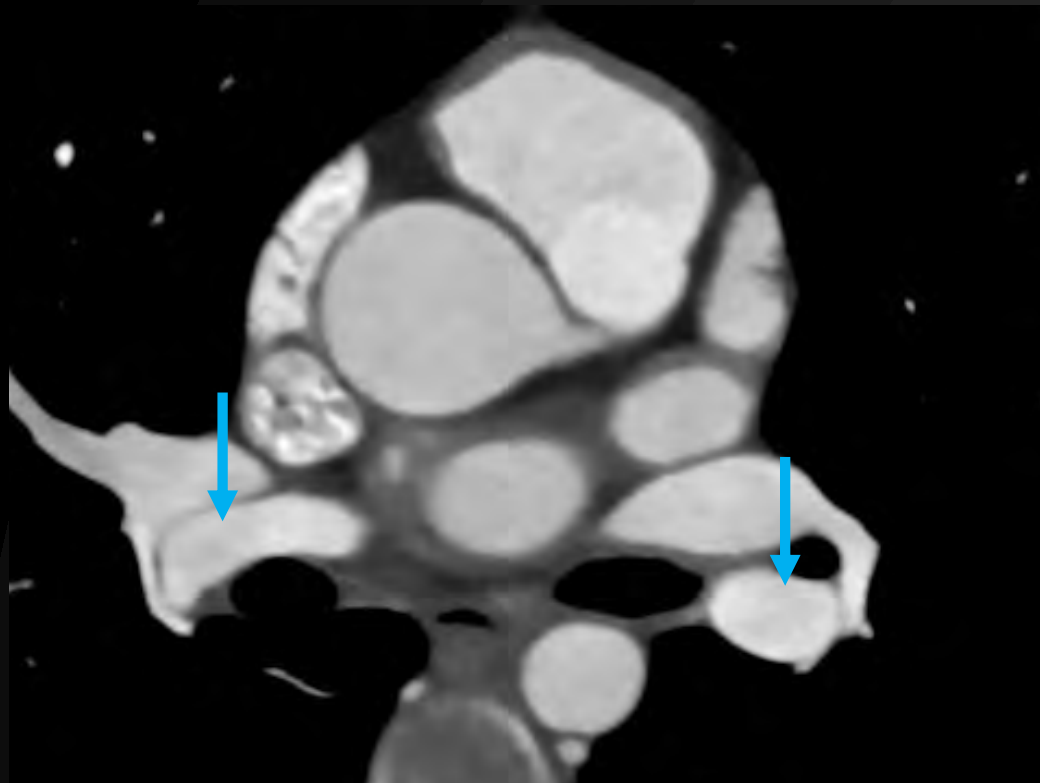
Artères pulmonaires



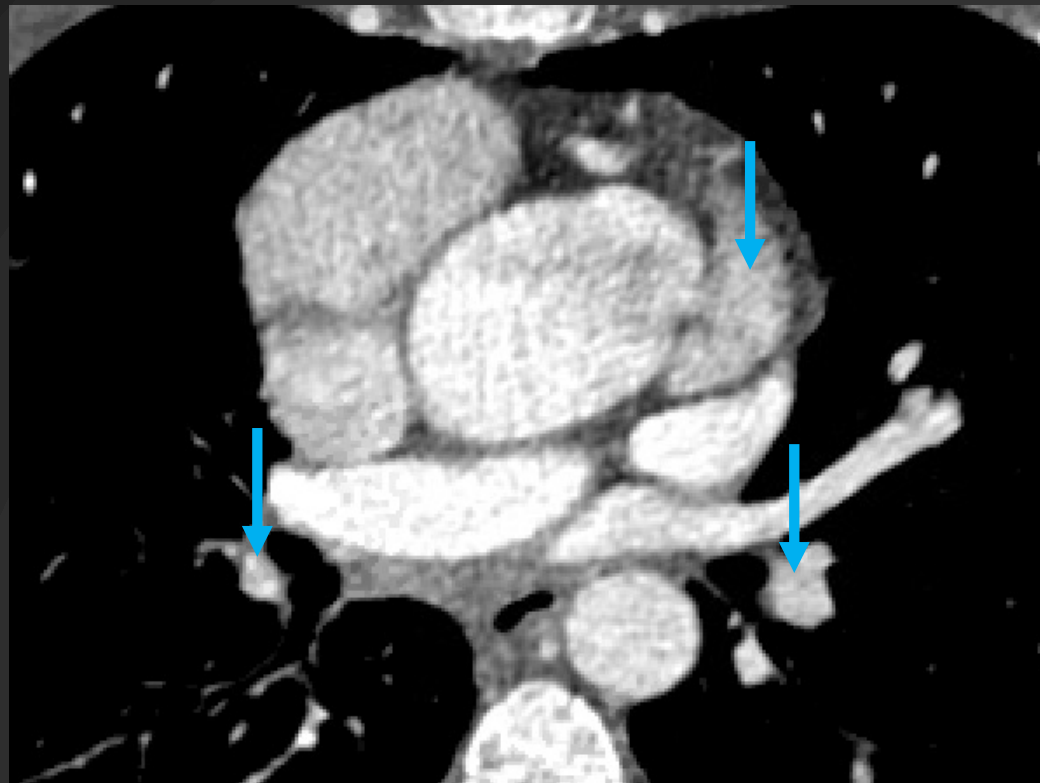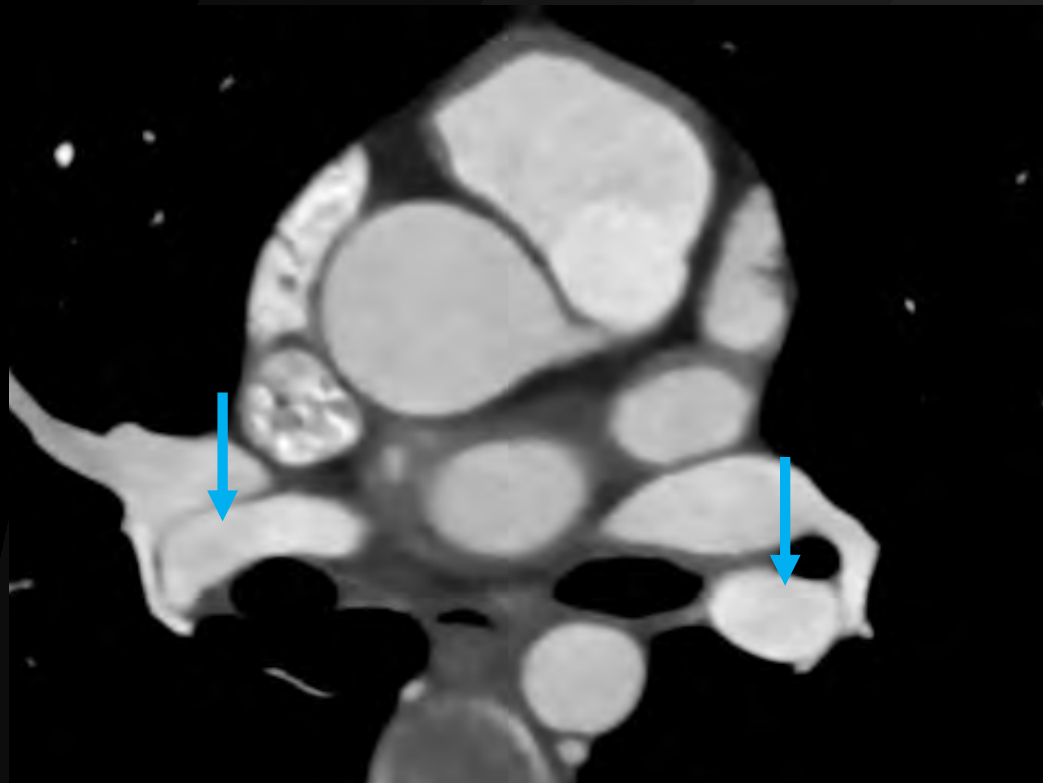
Artères pulmonaires



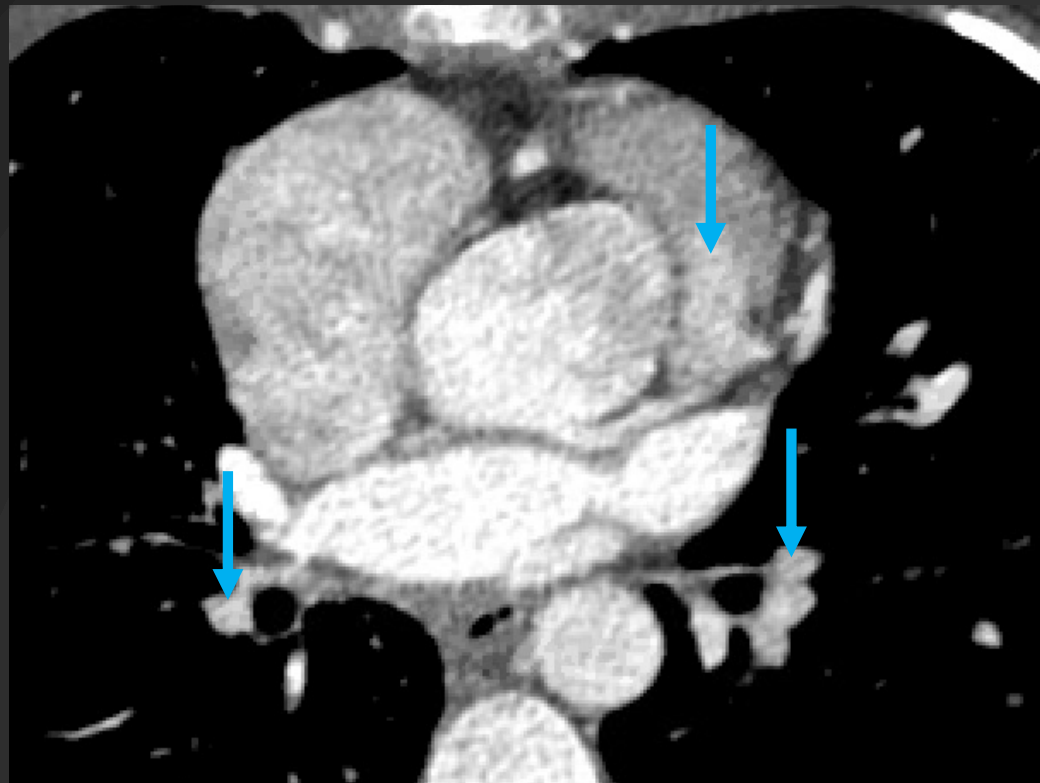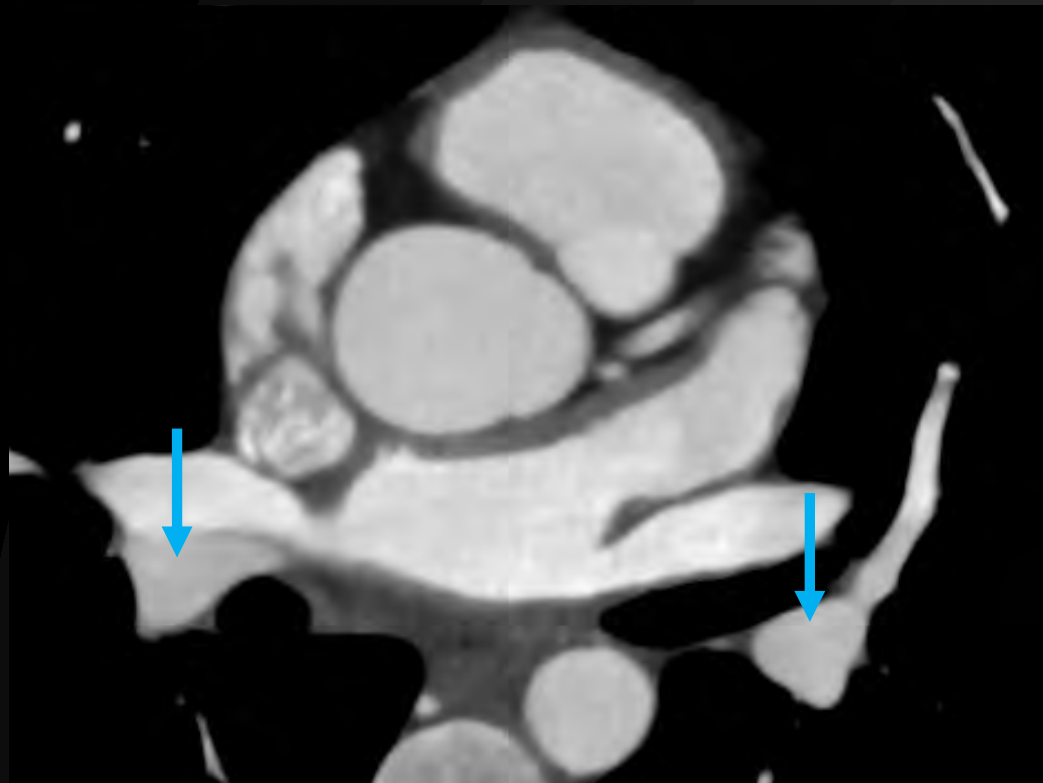
Artères pulmonaires



Artères pulmonaires

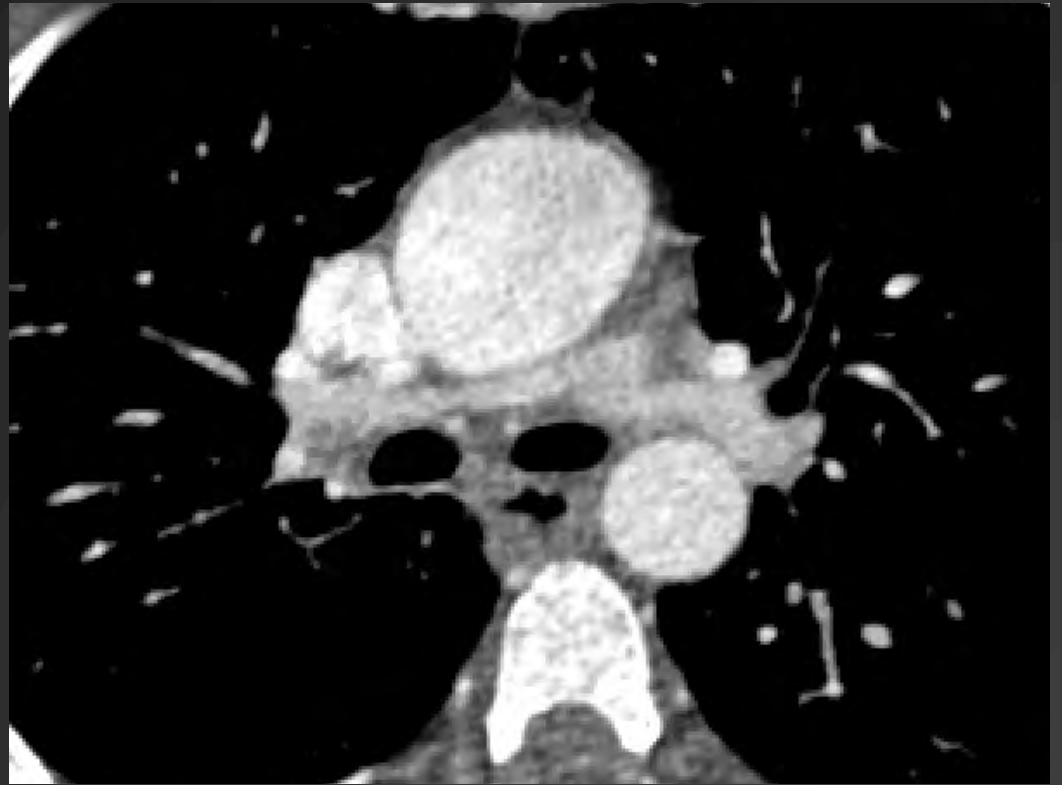

Artères pulmonaires

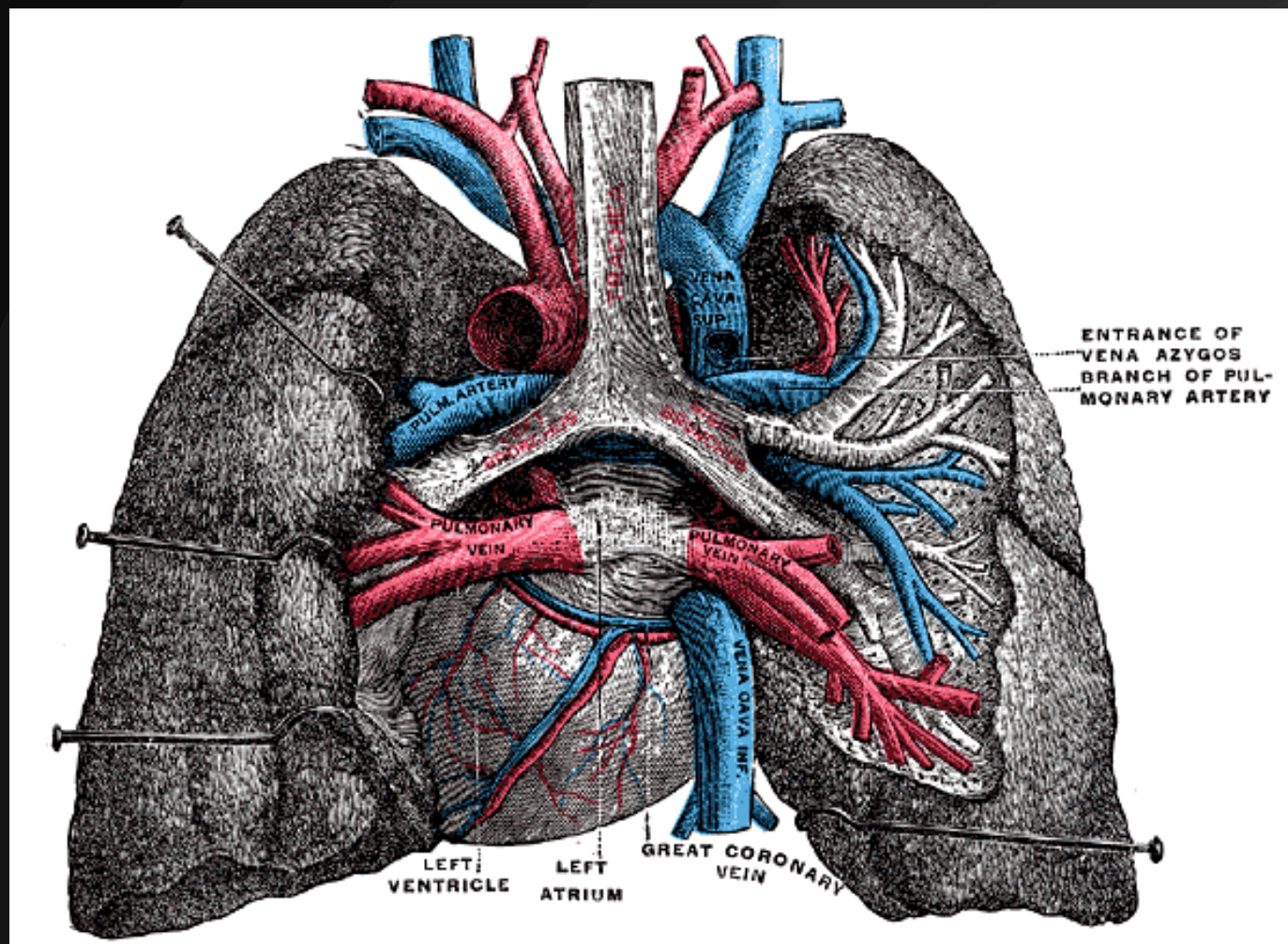


Artères pulmonaires

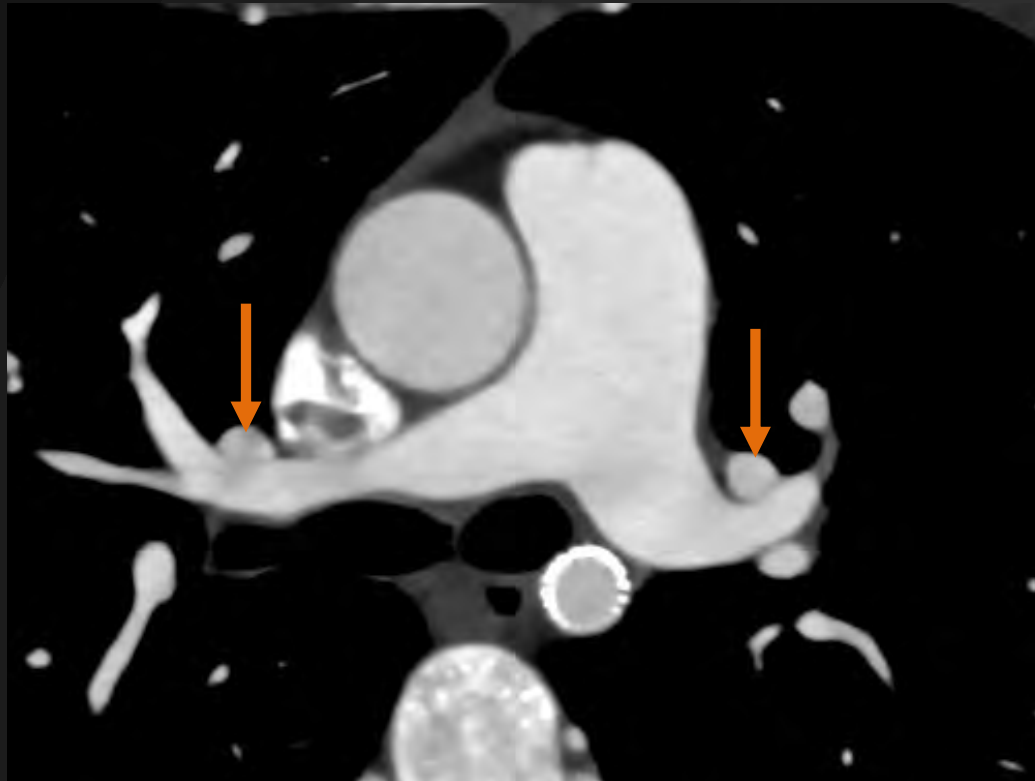
Atrésie pulmonaire à septum ouvert opérée



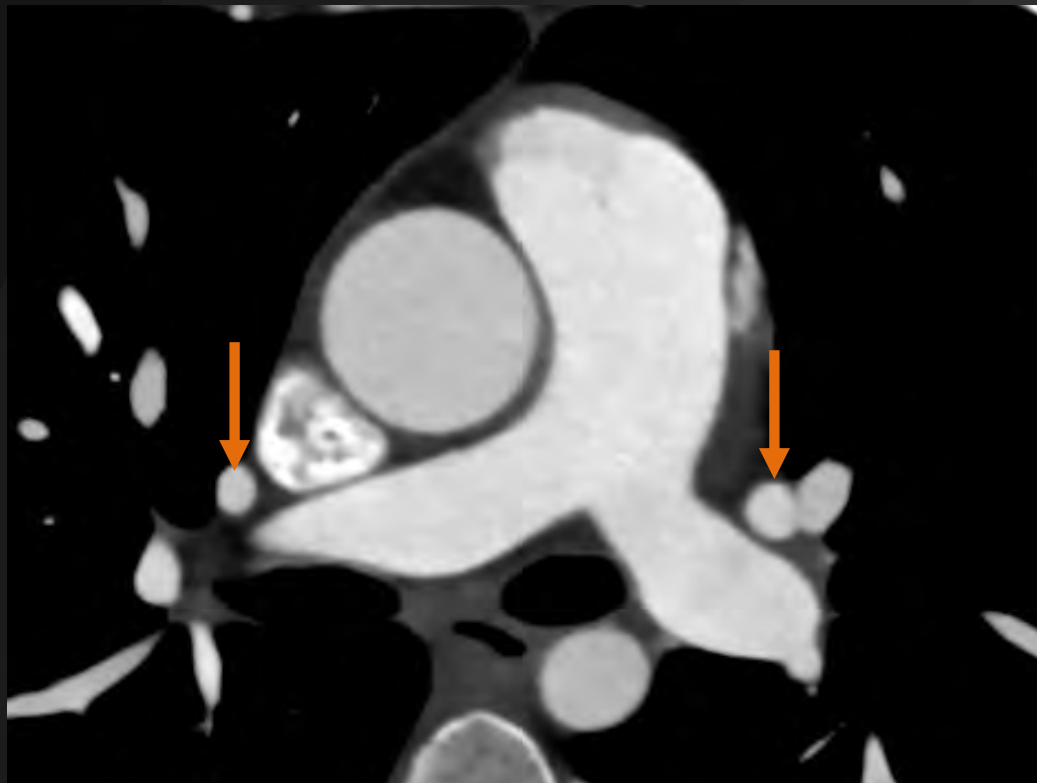
Veines pulmonaires



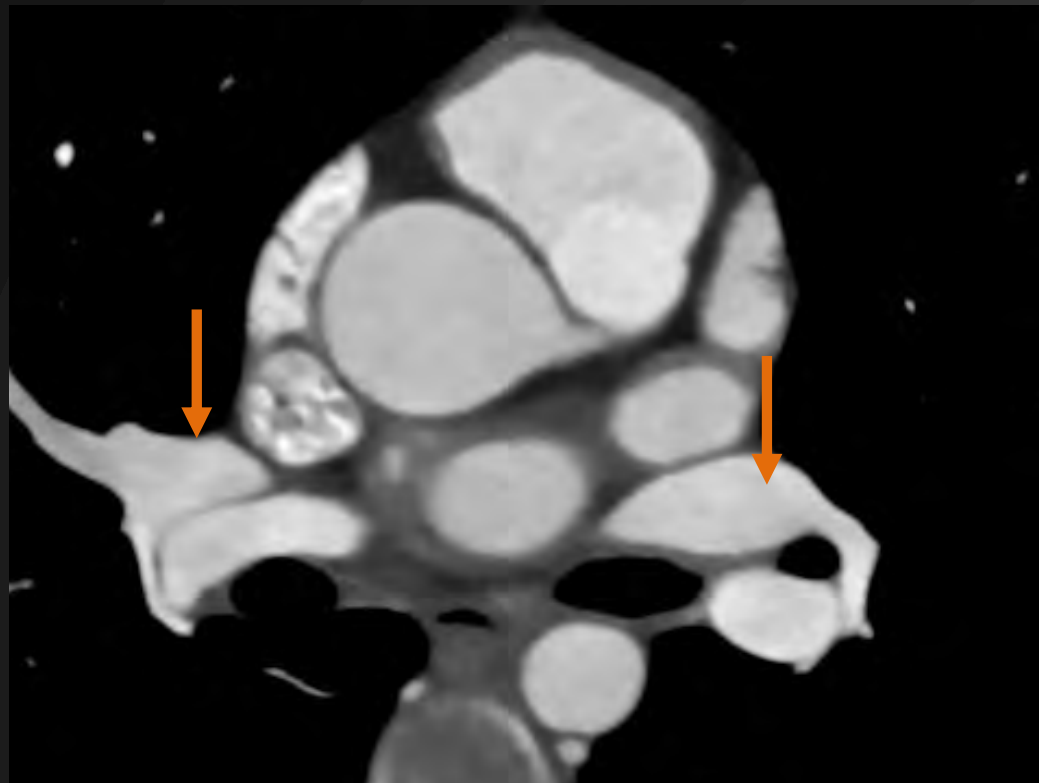
Veines pulmonaires



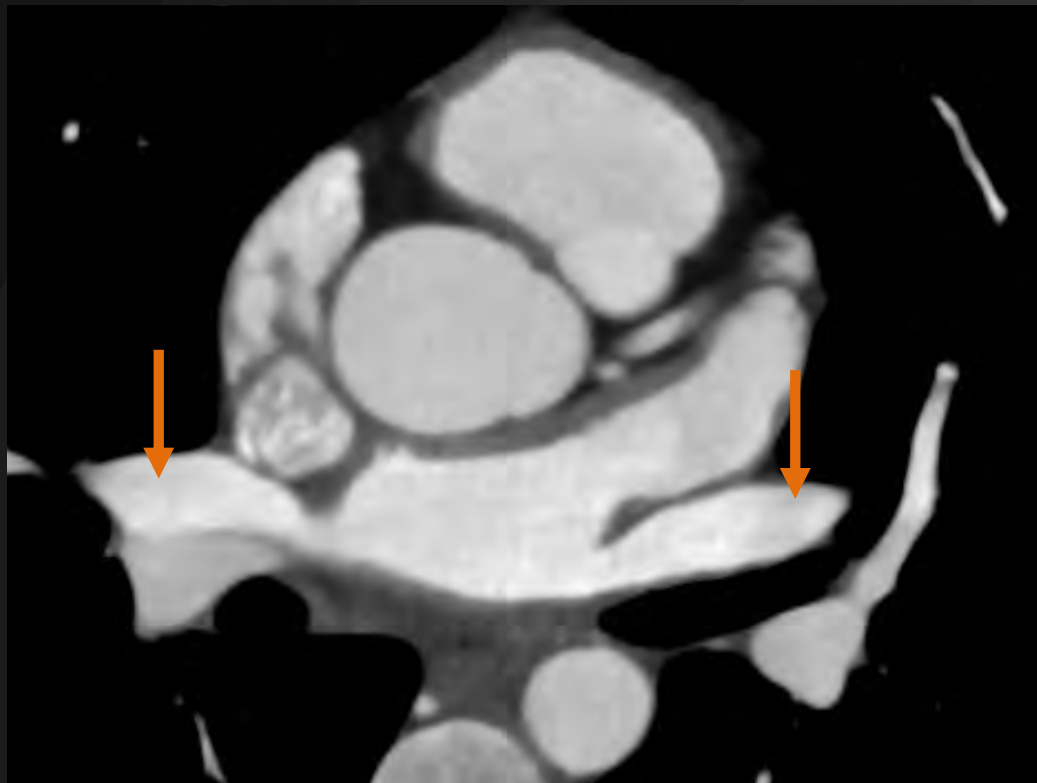
Veines pulmonaires



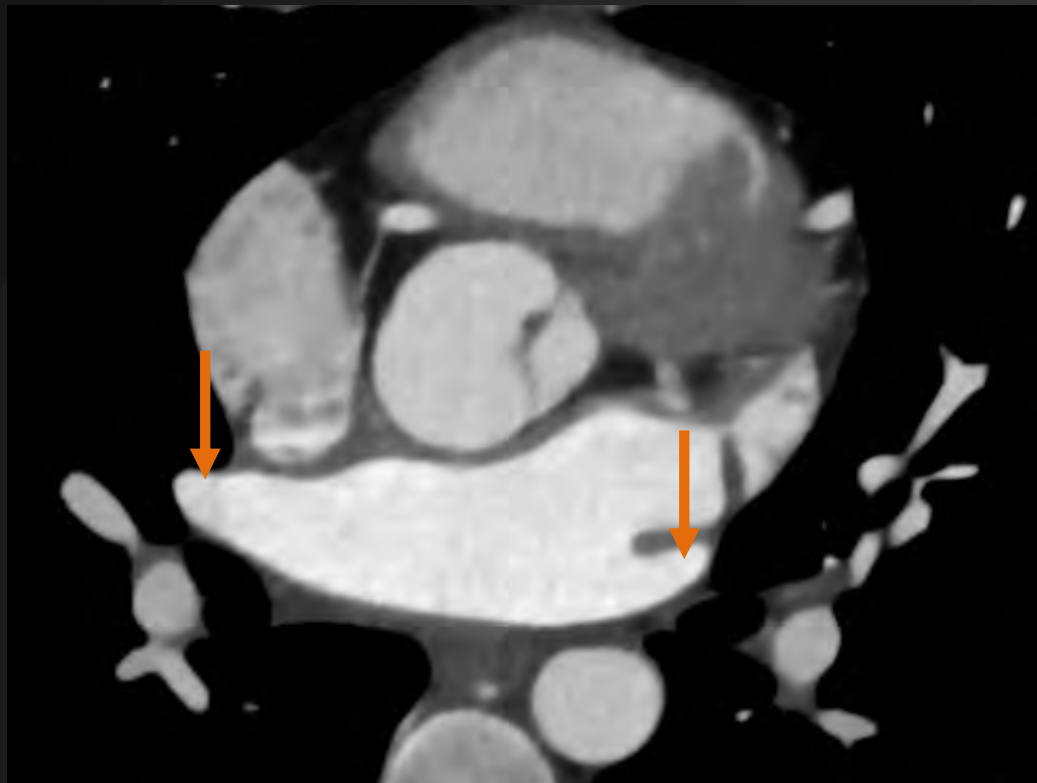
Veines pulmonaires



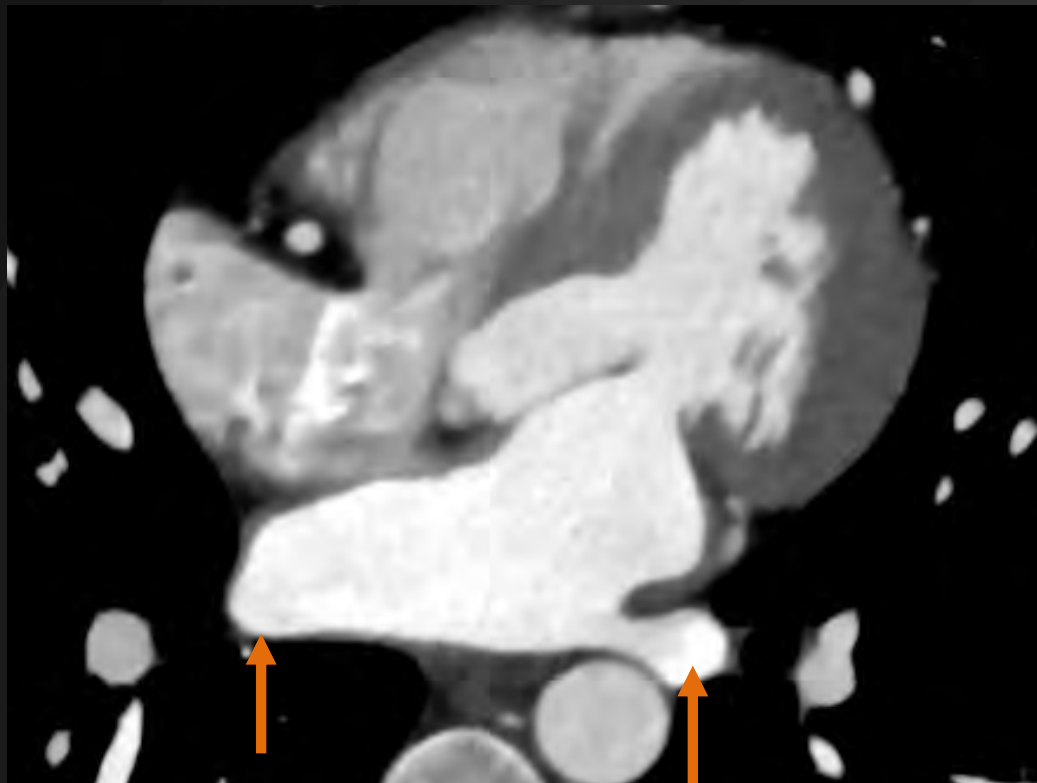Veines pulmonaires



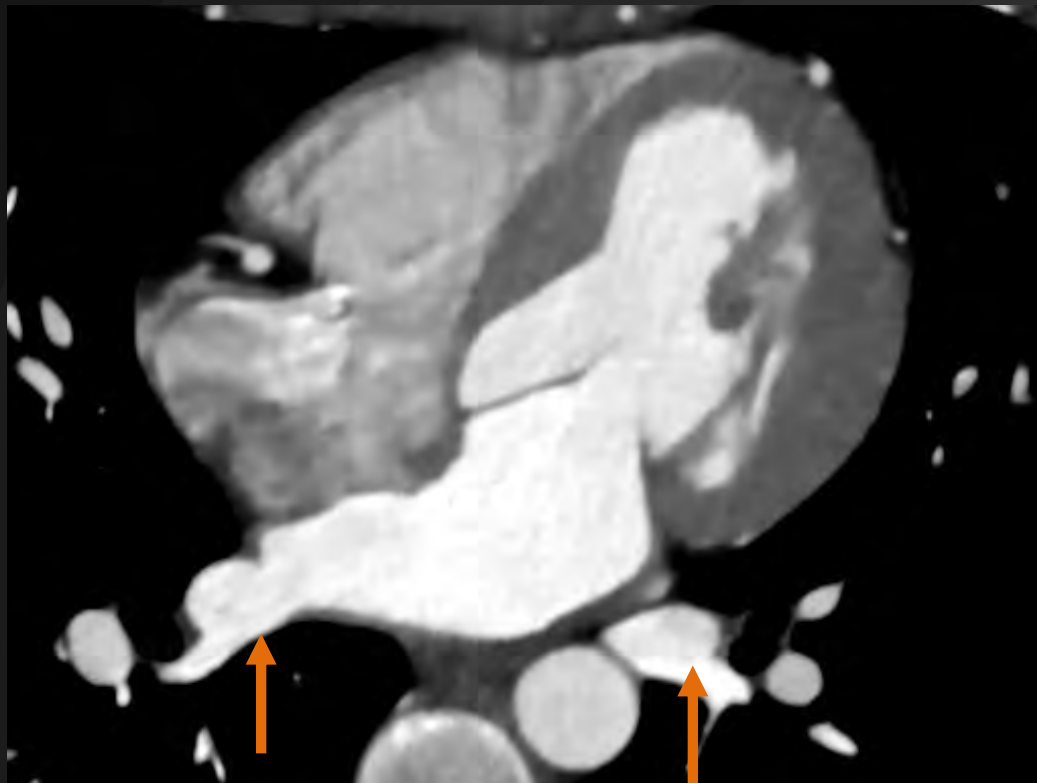Veines pulmonaires



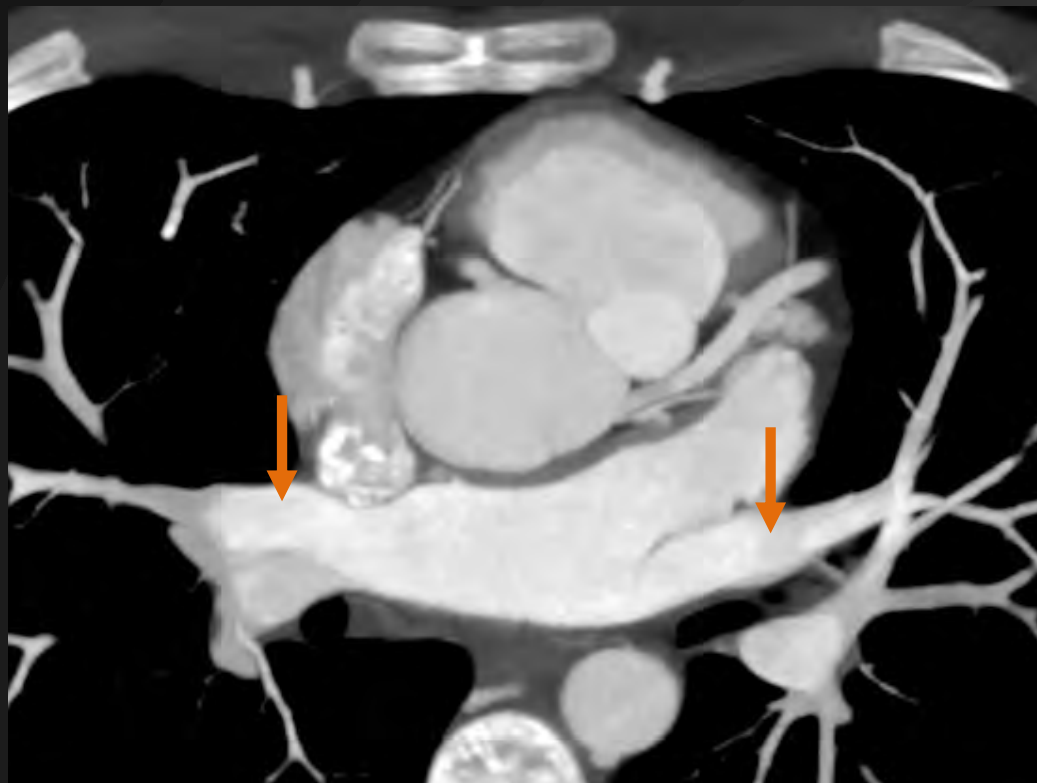
Veines pulmonaires



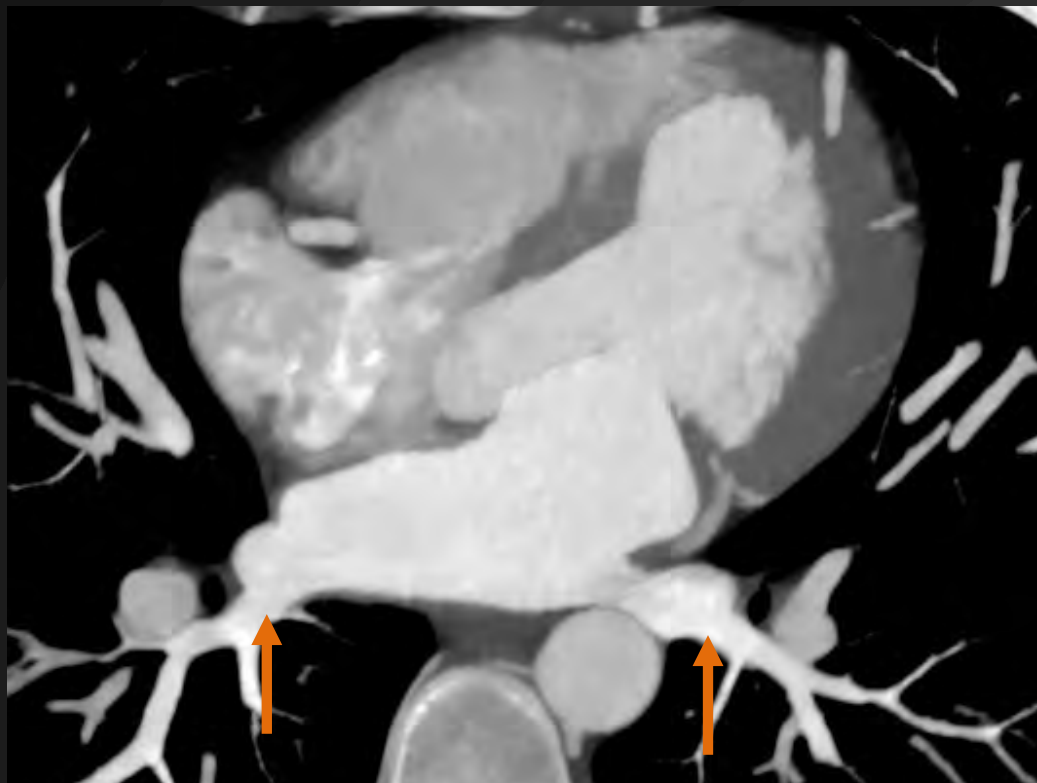Veines pulmonaires



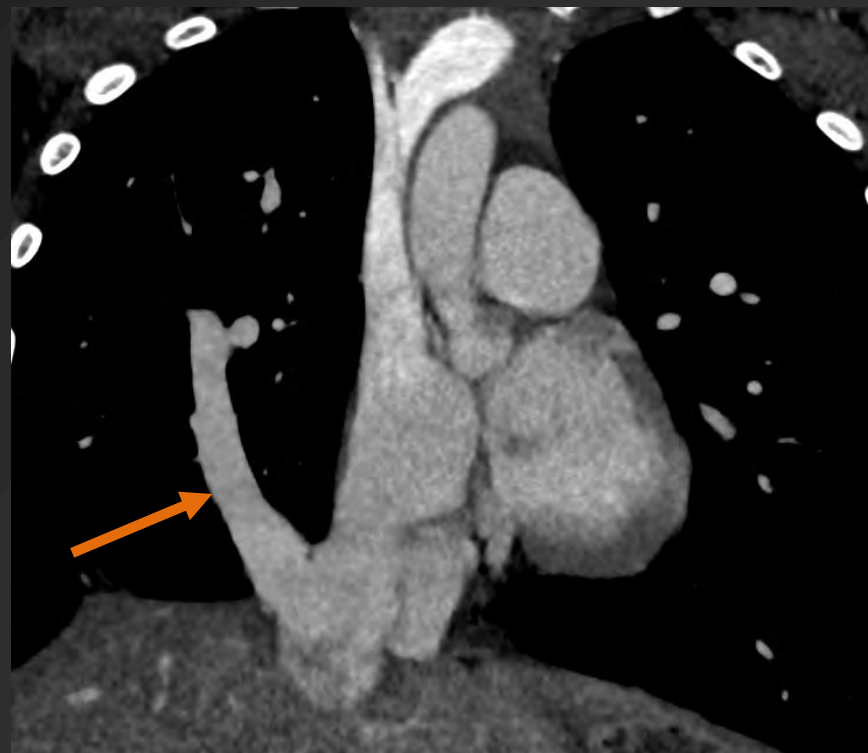
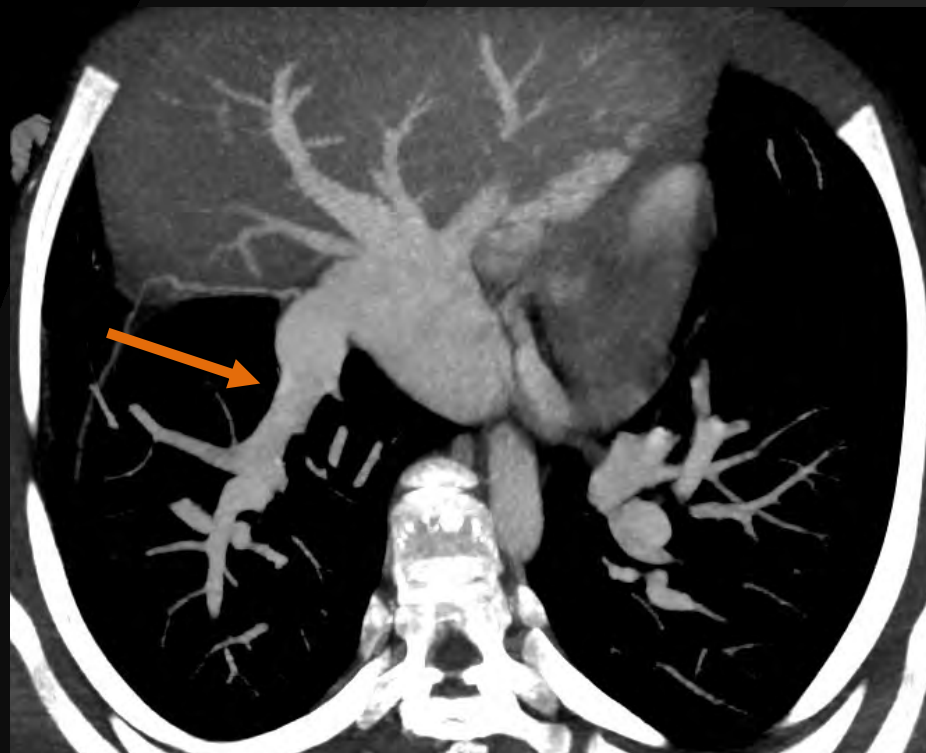
Veines pulmonaires



Veines pulmonaires

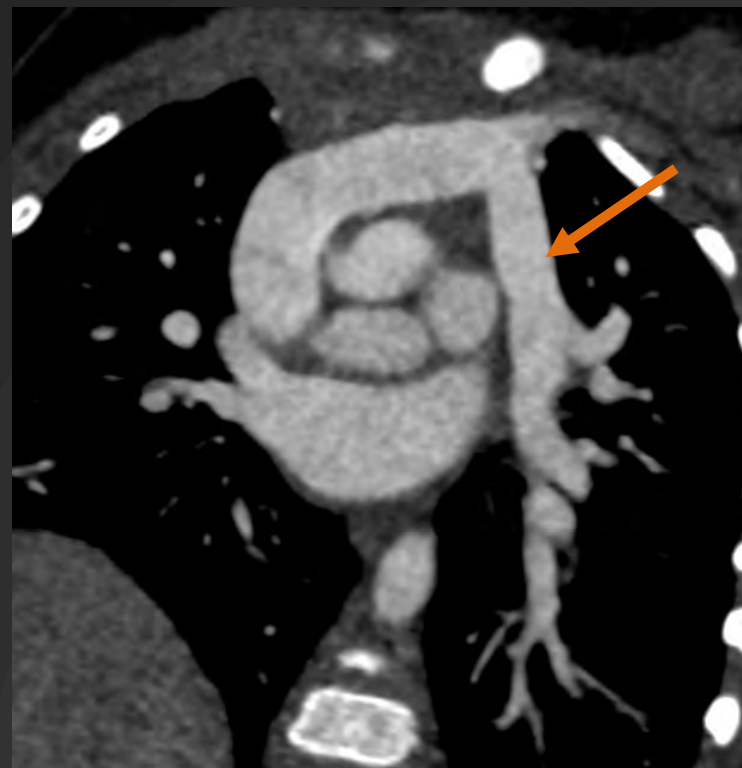
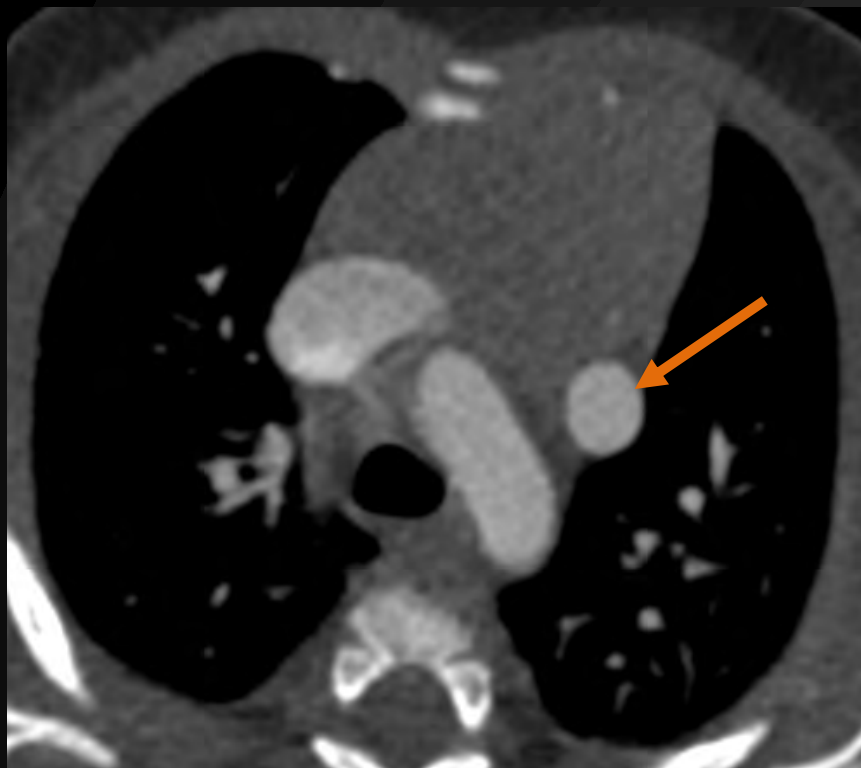


Veines pulmonaires



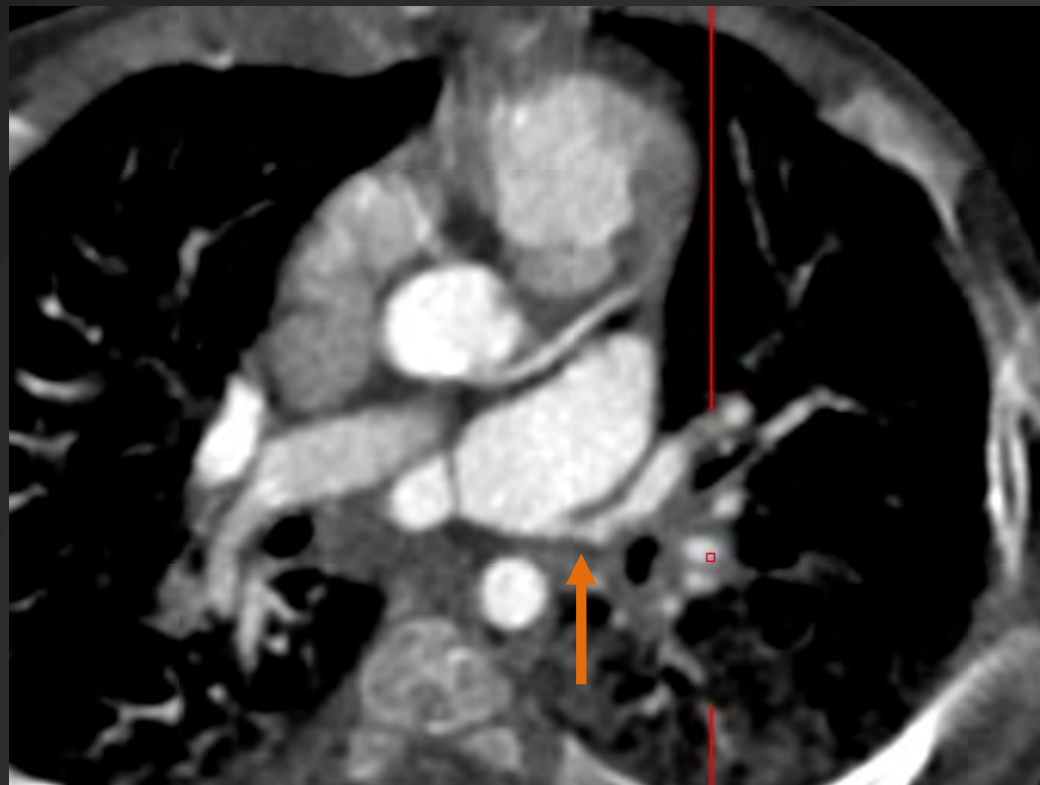
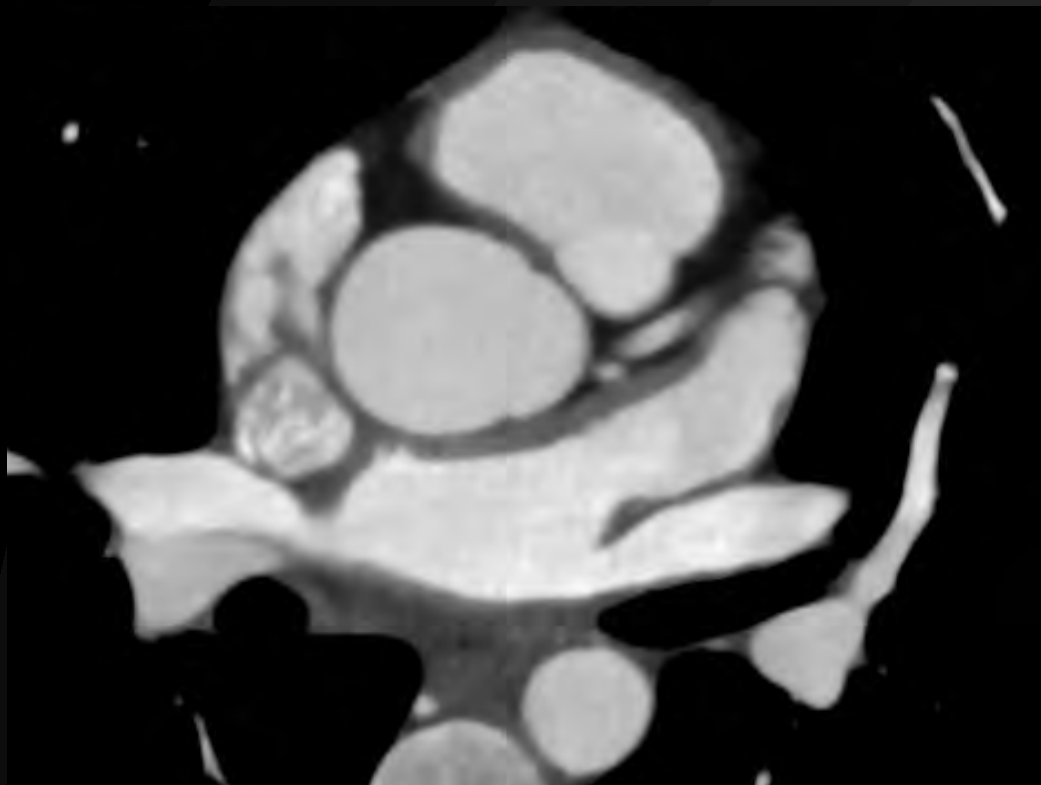
RVPA partiel

Veines pulmonaires



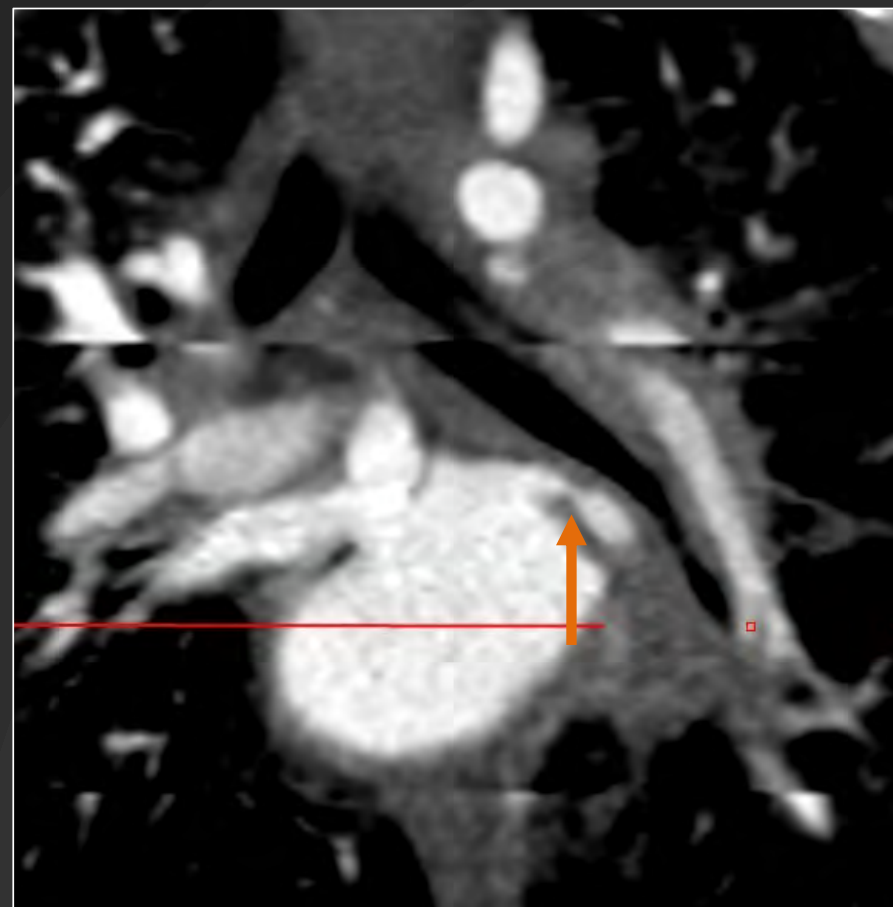
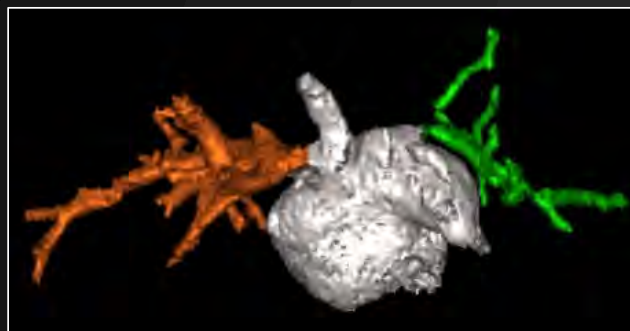
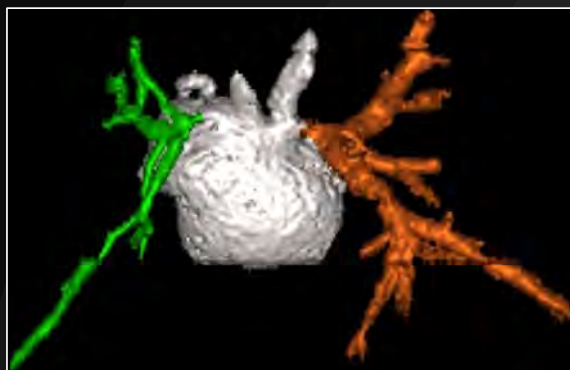
RVPA partiel

Veines pulmonaires

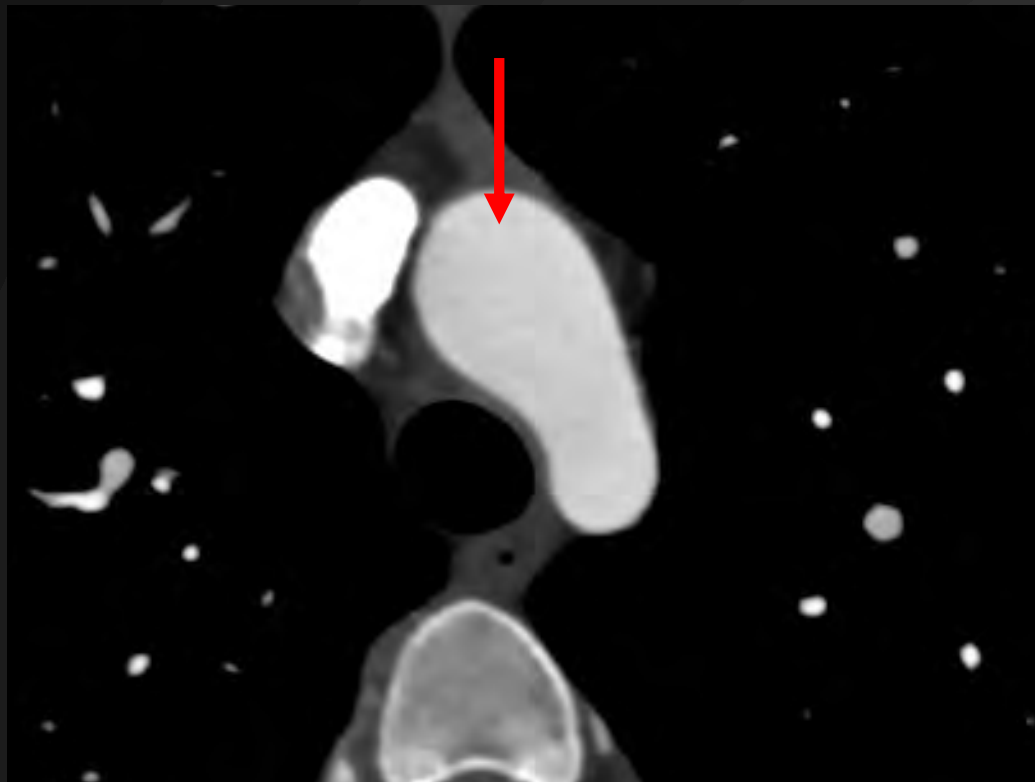


Veines pulmonaires

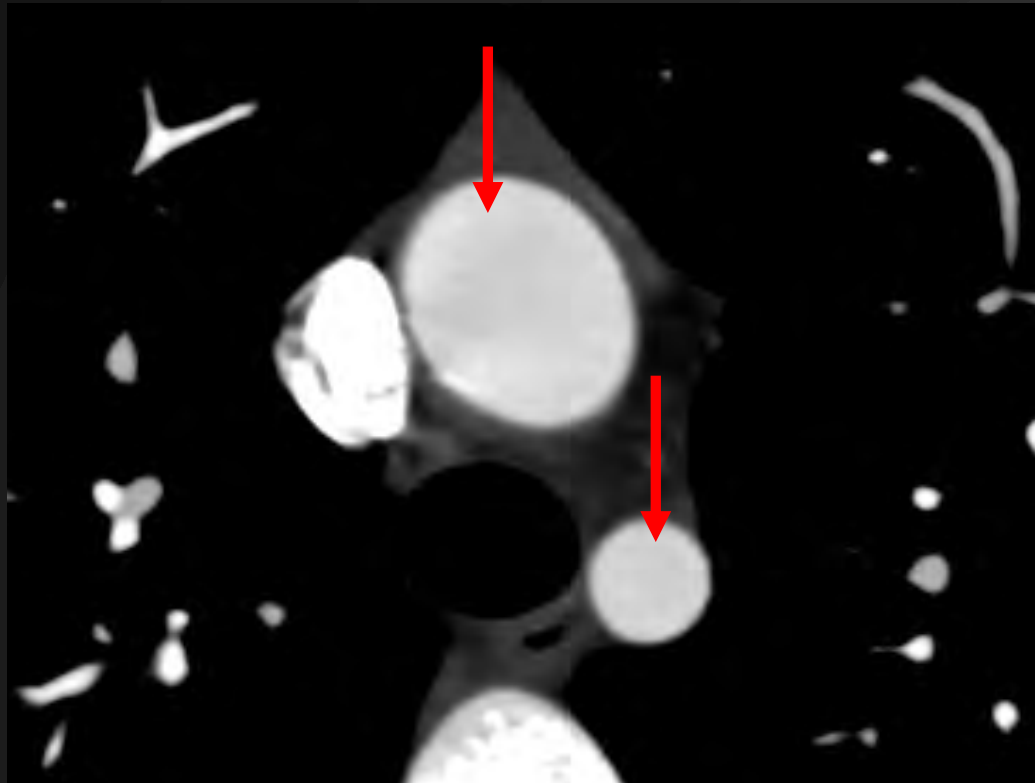
Sténose de veine pulmonaire



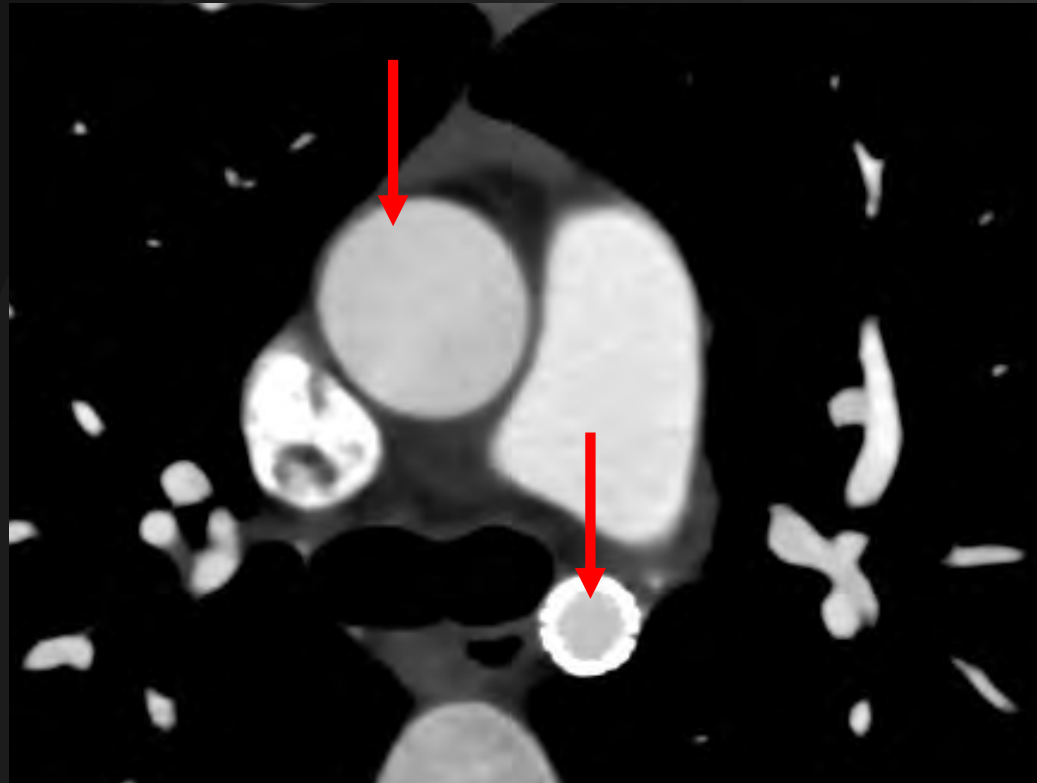
Aorte



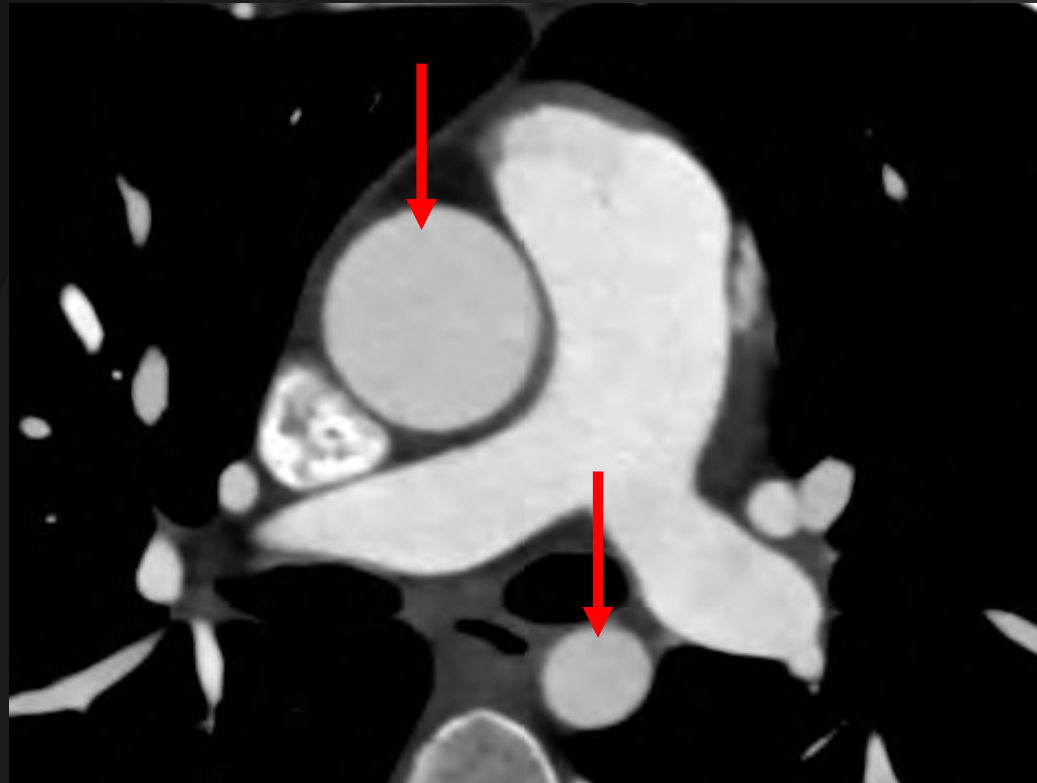
Aorte



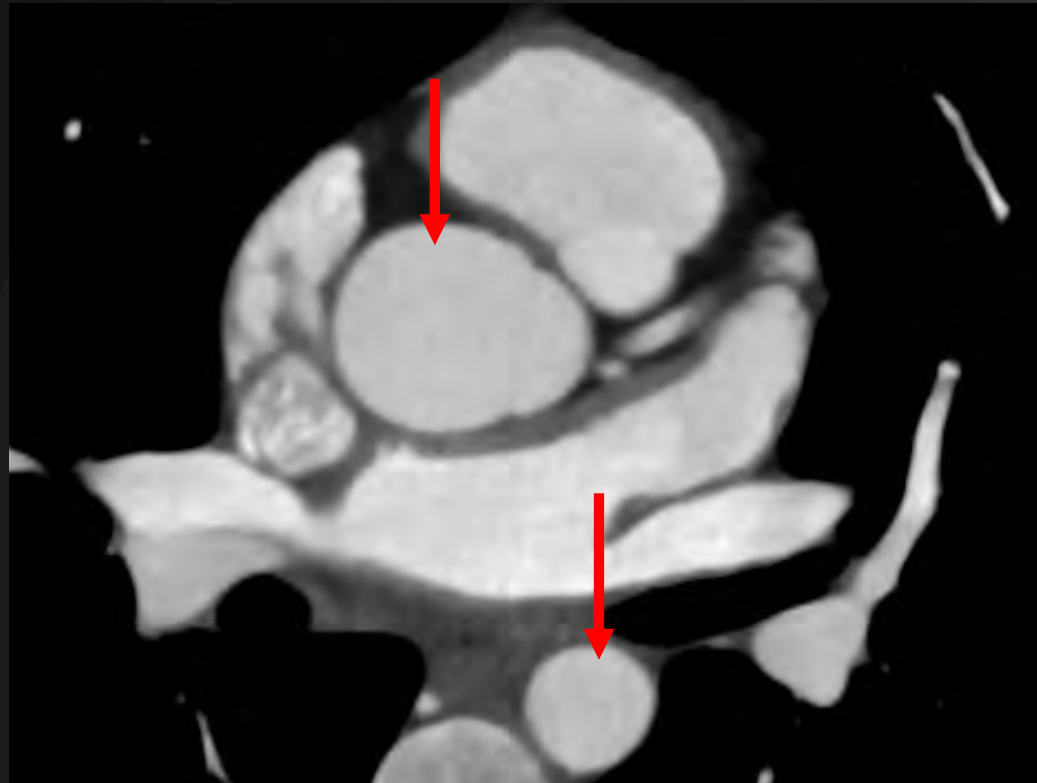
Aorte



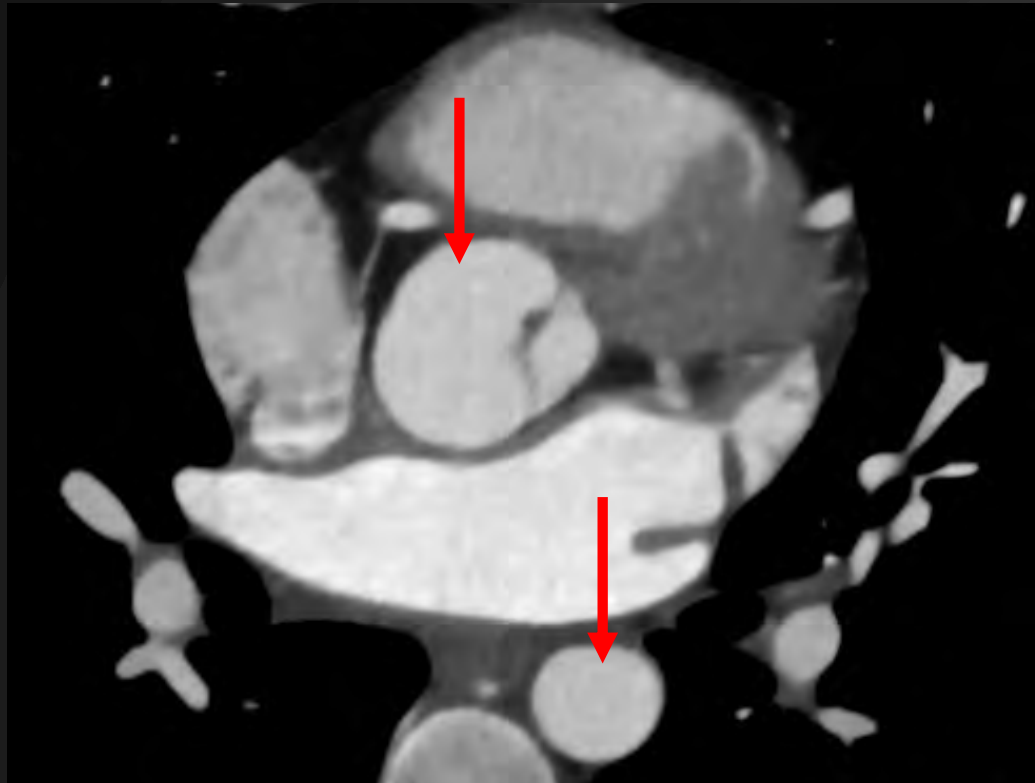
Aorte



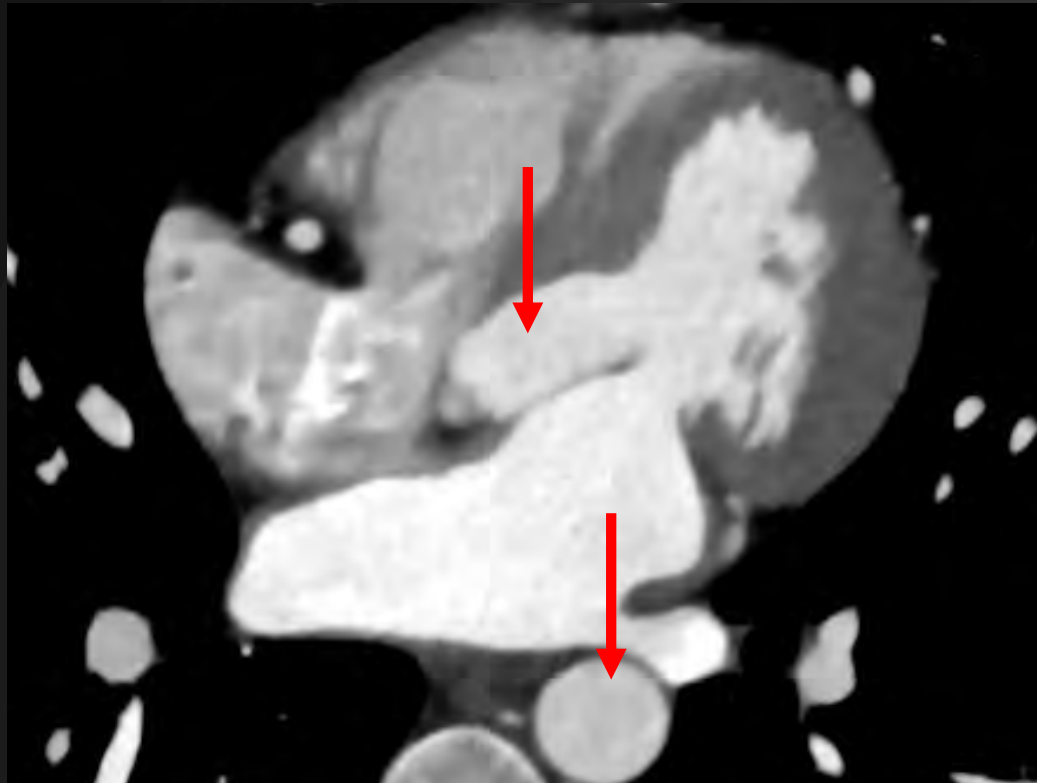
Aorte



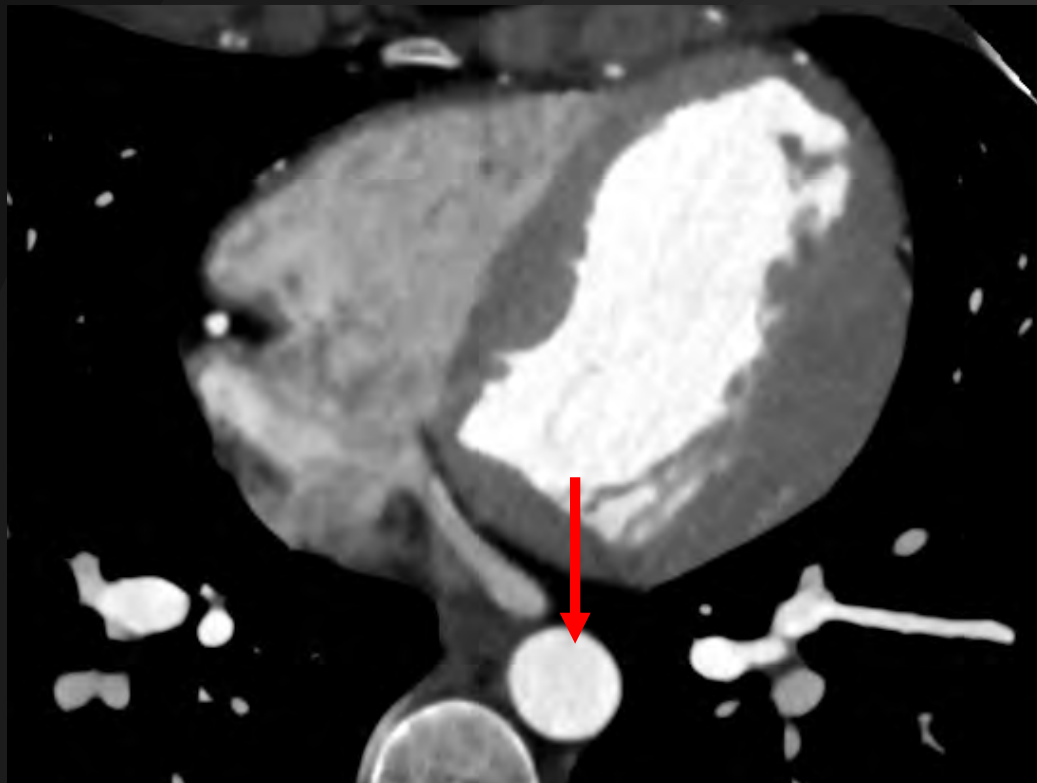
Aorte



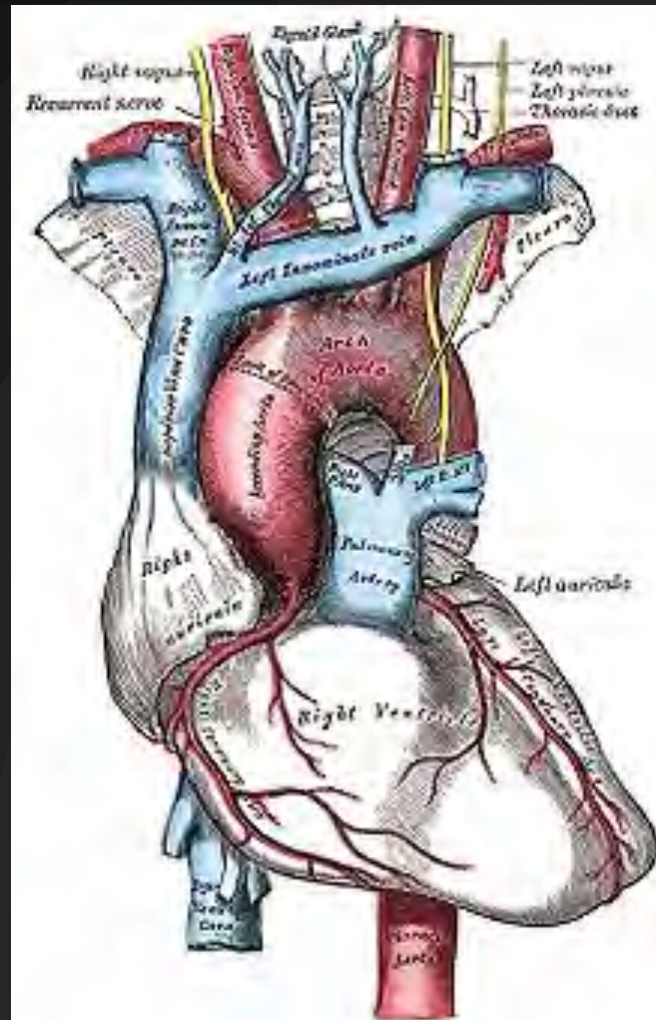
Aorte



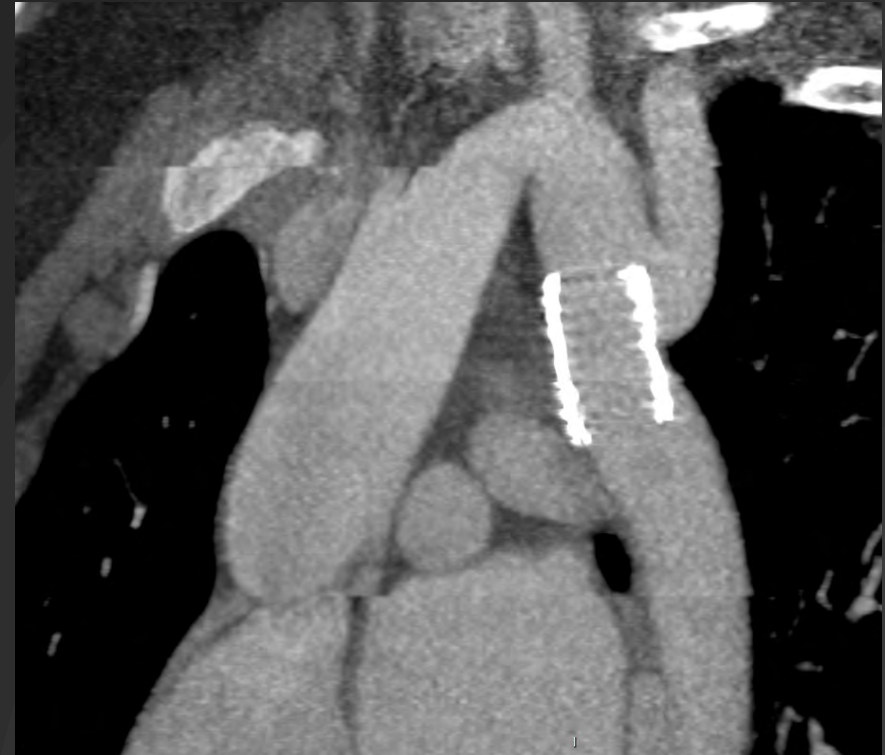
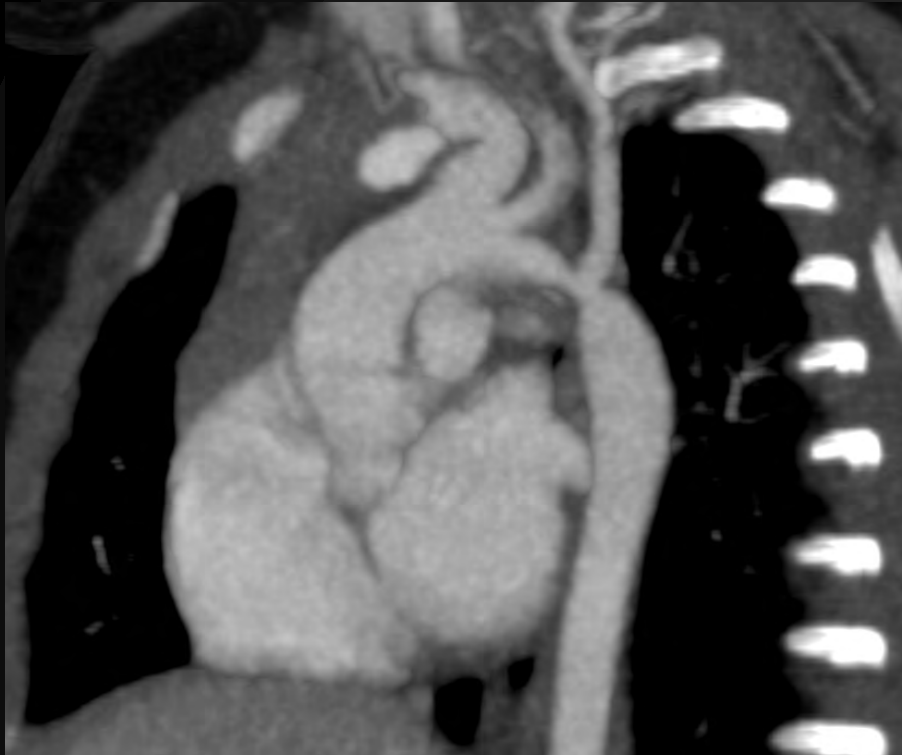Aorte



Aorte

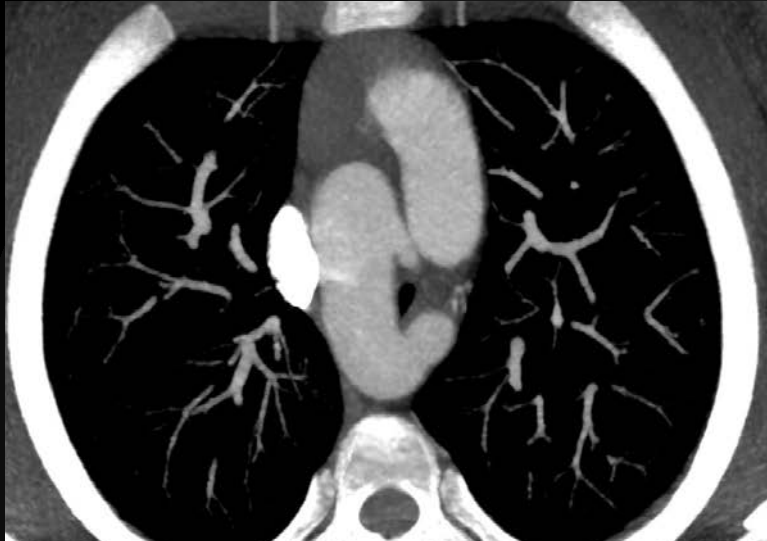

Aorte

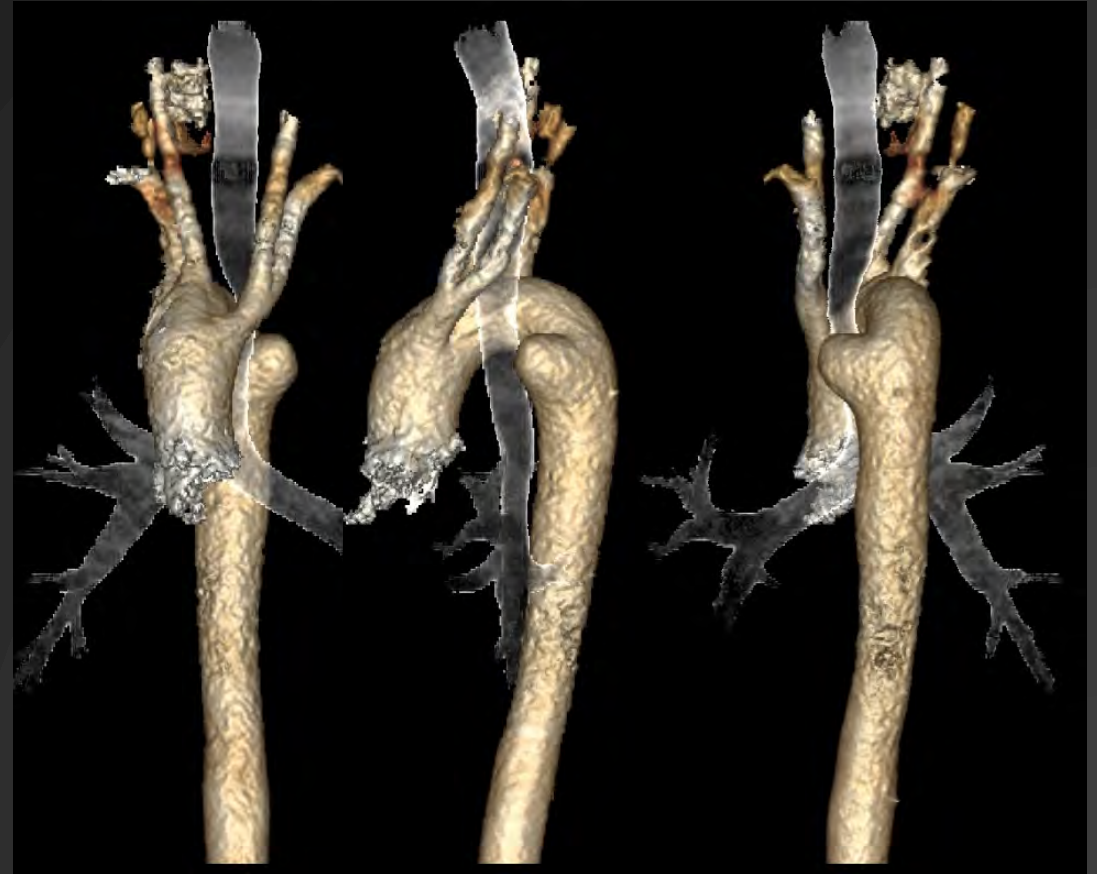


Coarctation aortique

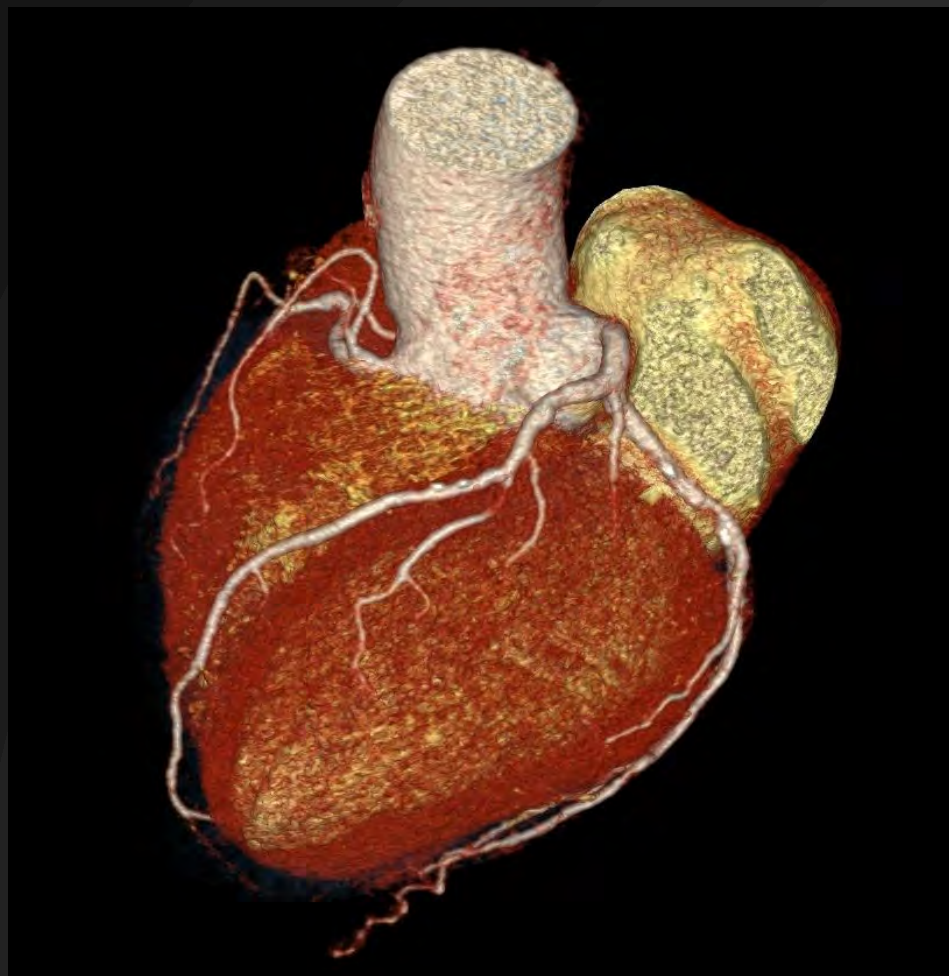
Aorte



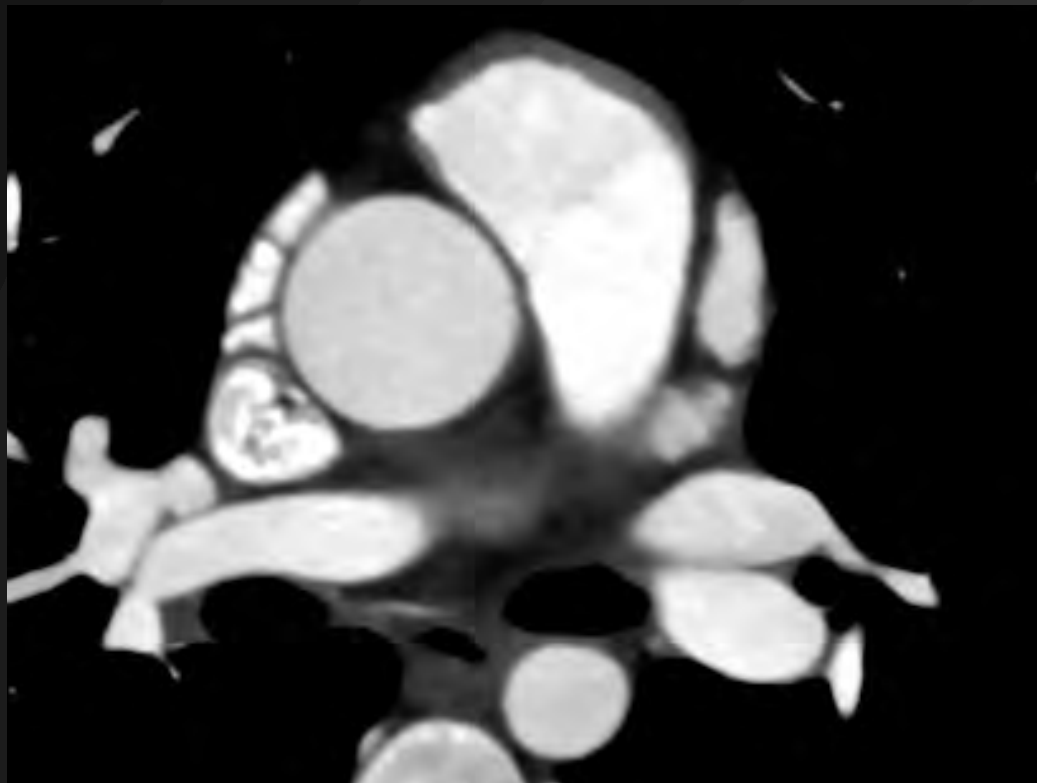
Anomalies d'arcs aortiques



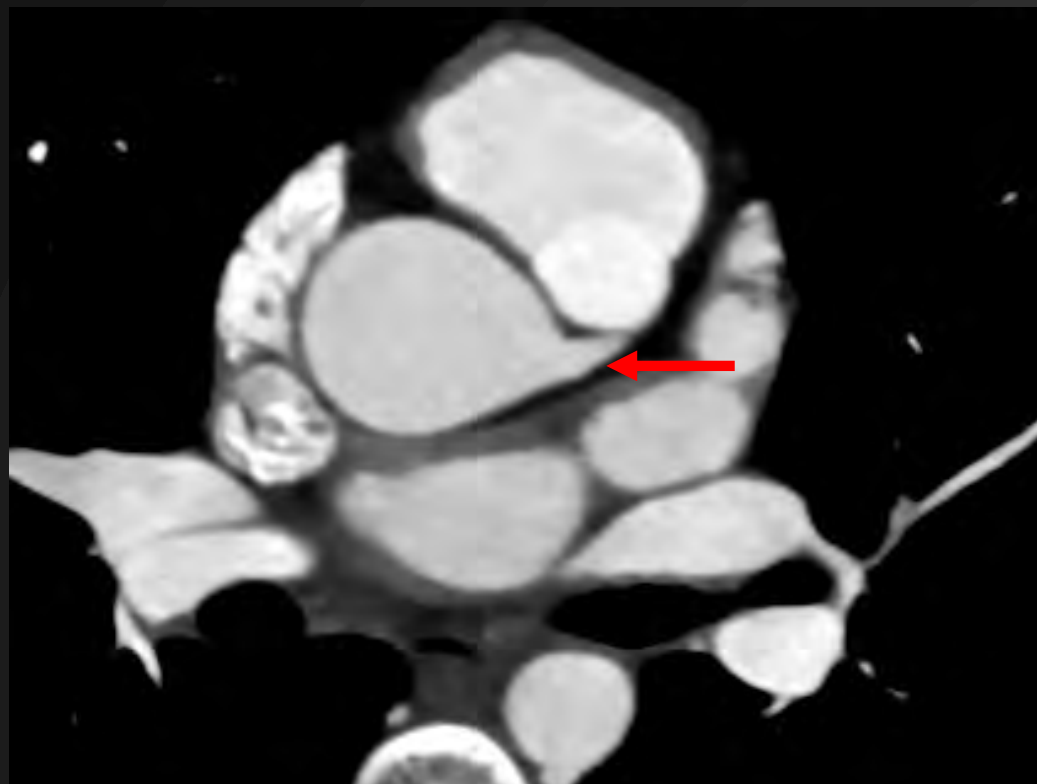
Coronaires



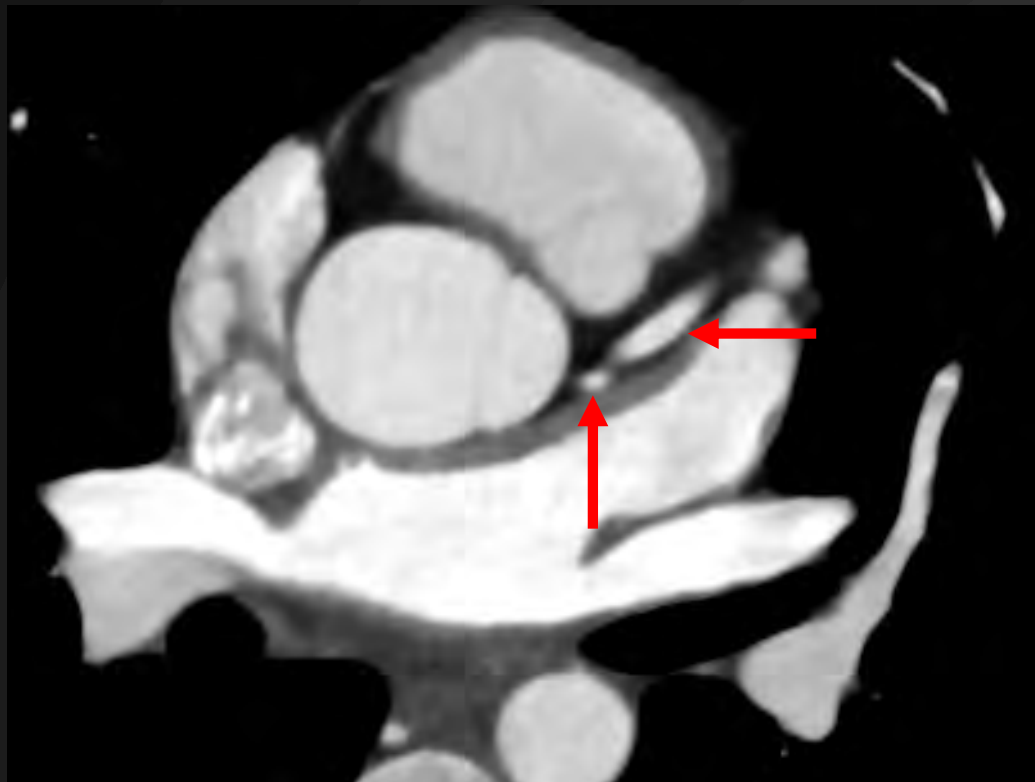Coronaires



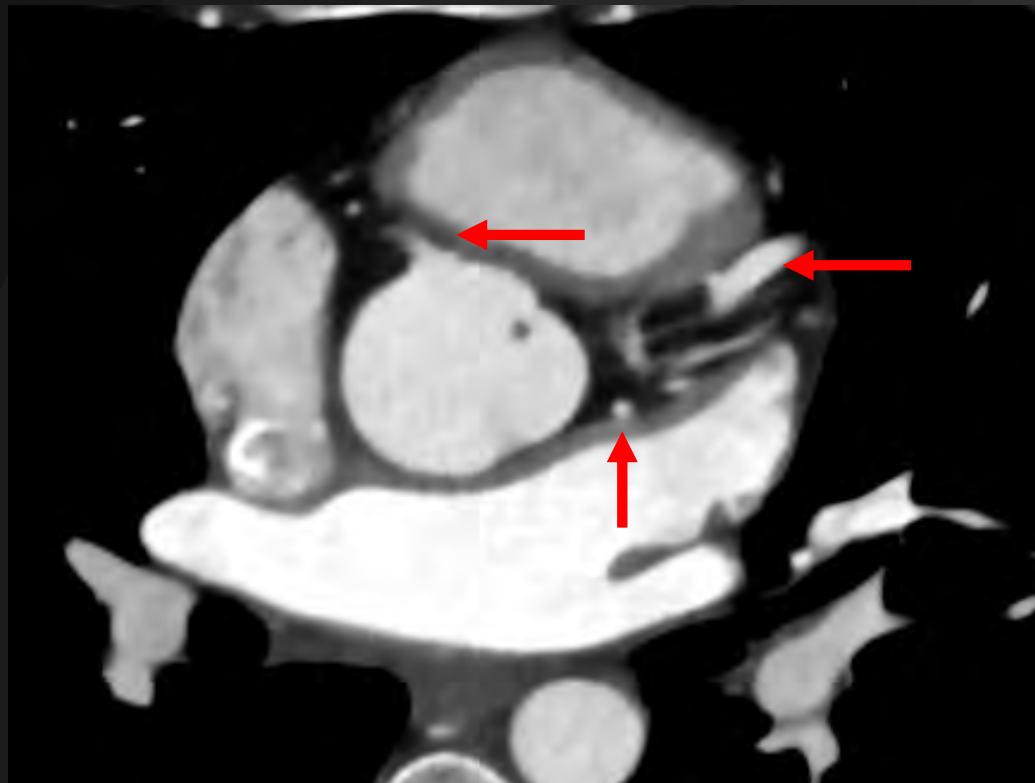
Coronaires



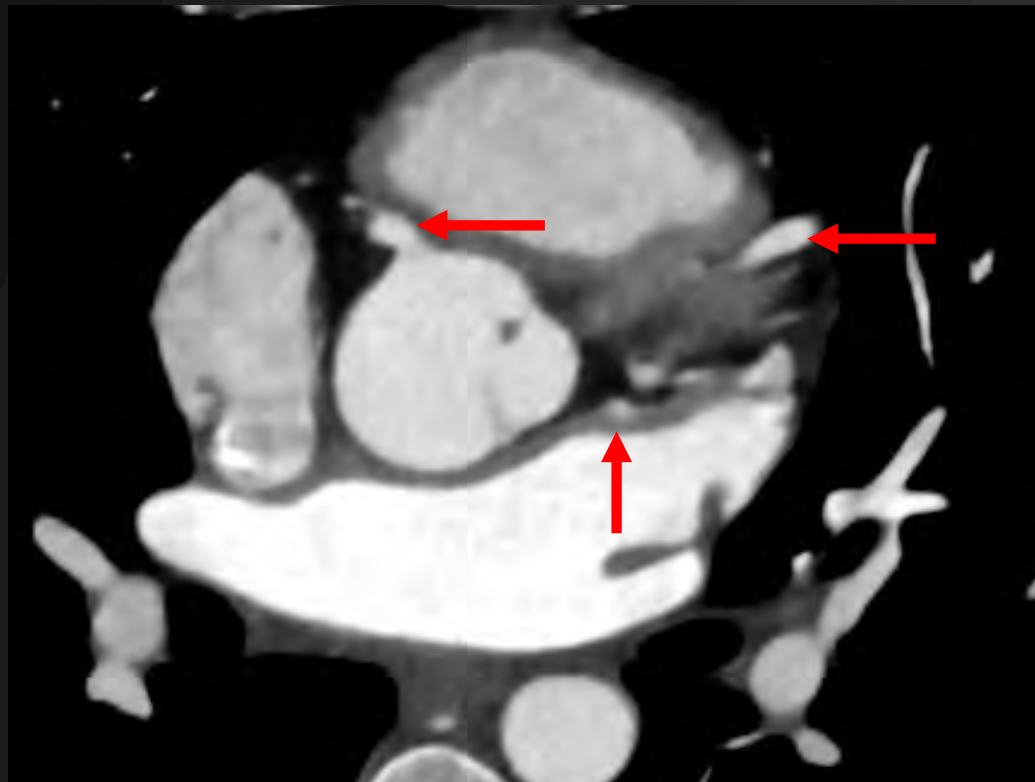
Coronaires



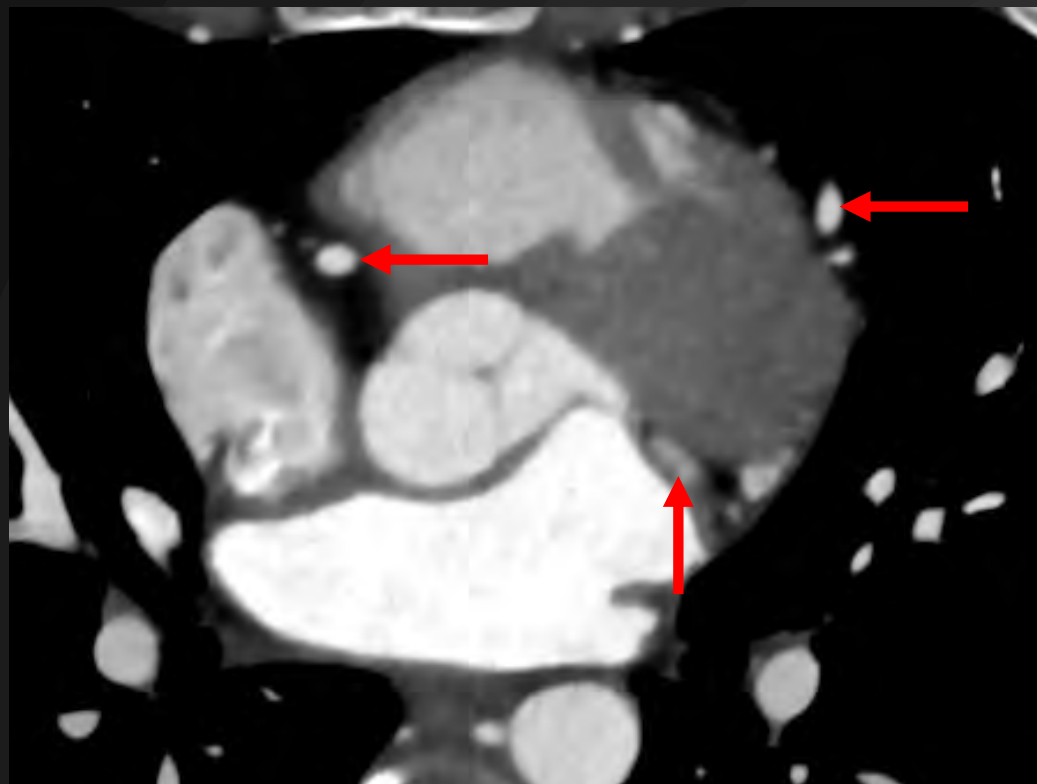
Coronaires



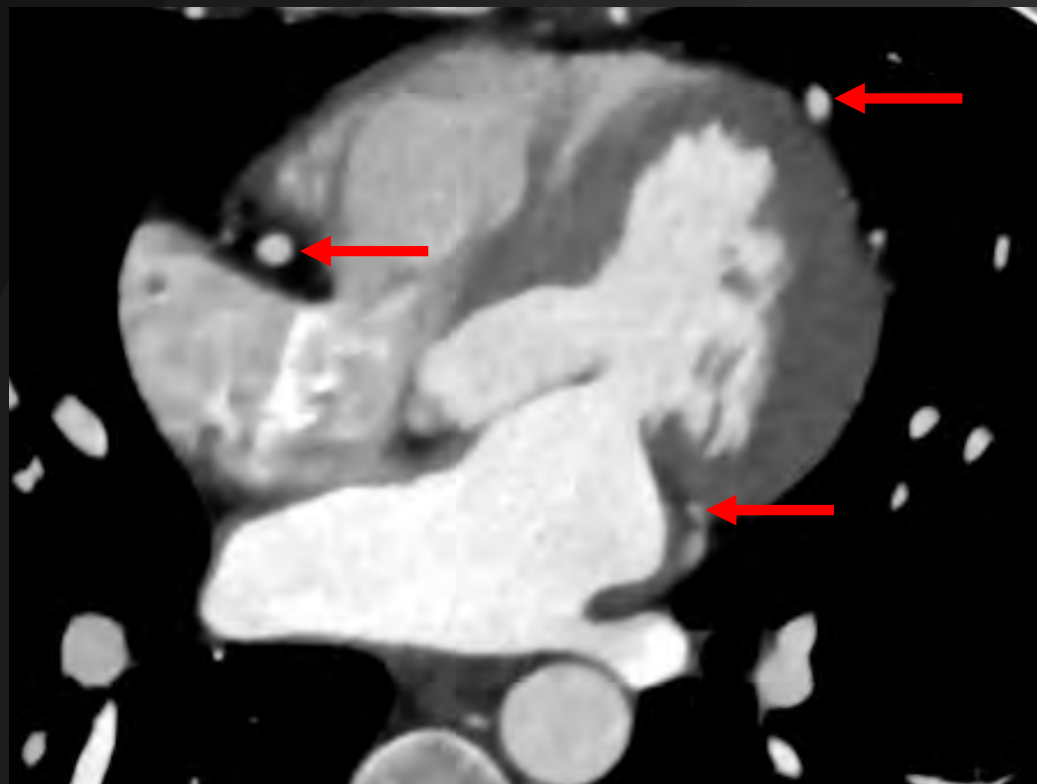
Coronaires



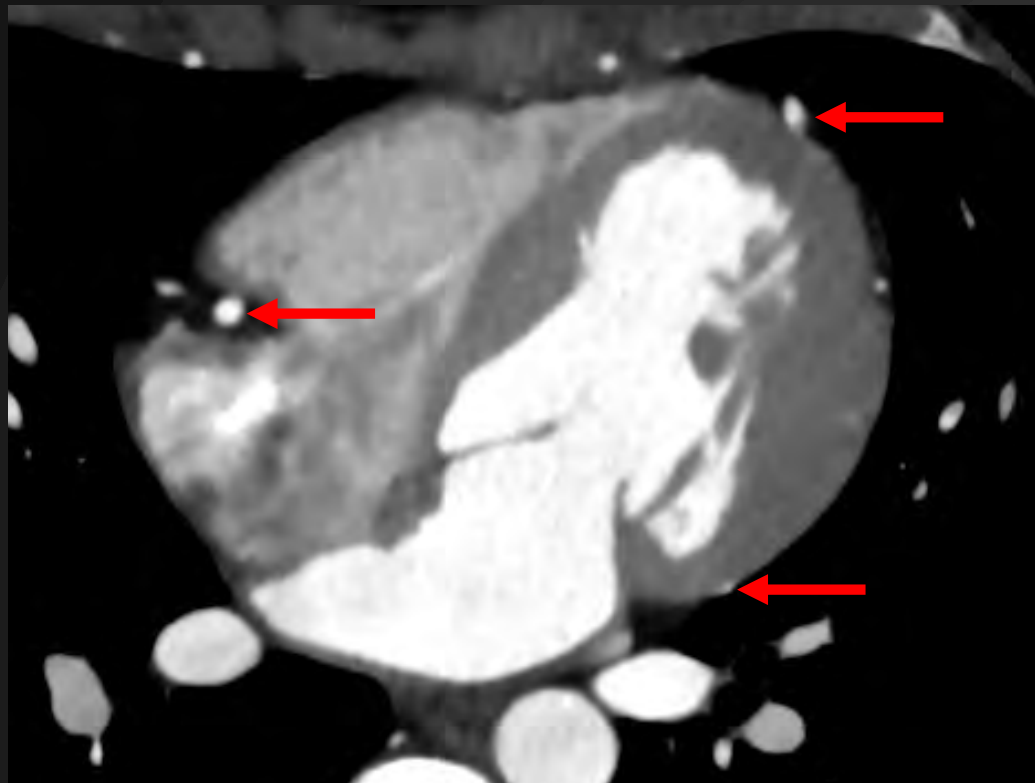
Coronaires



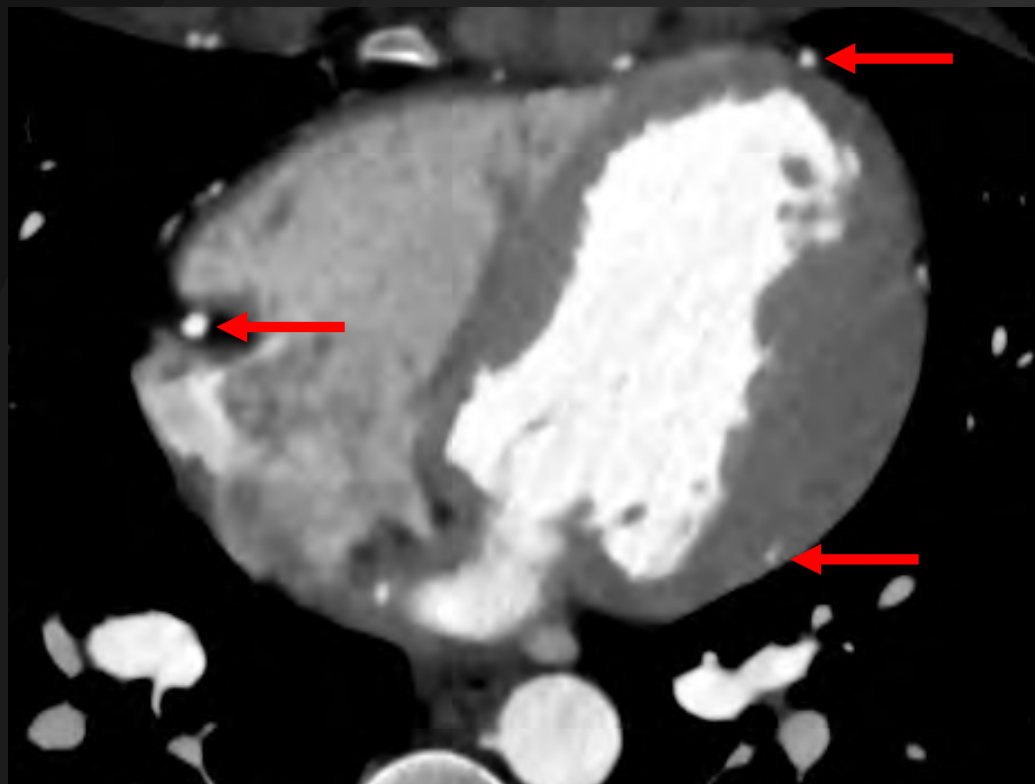
Coronaires



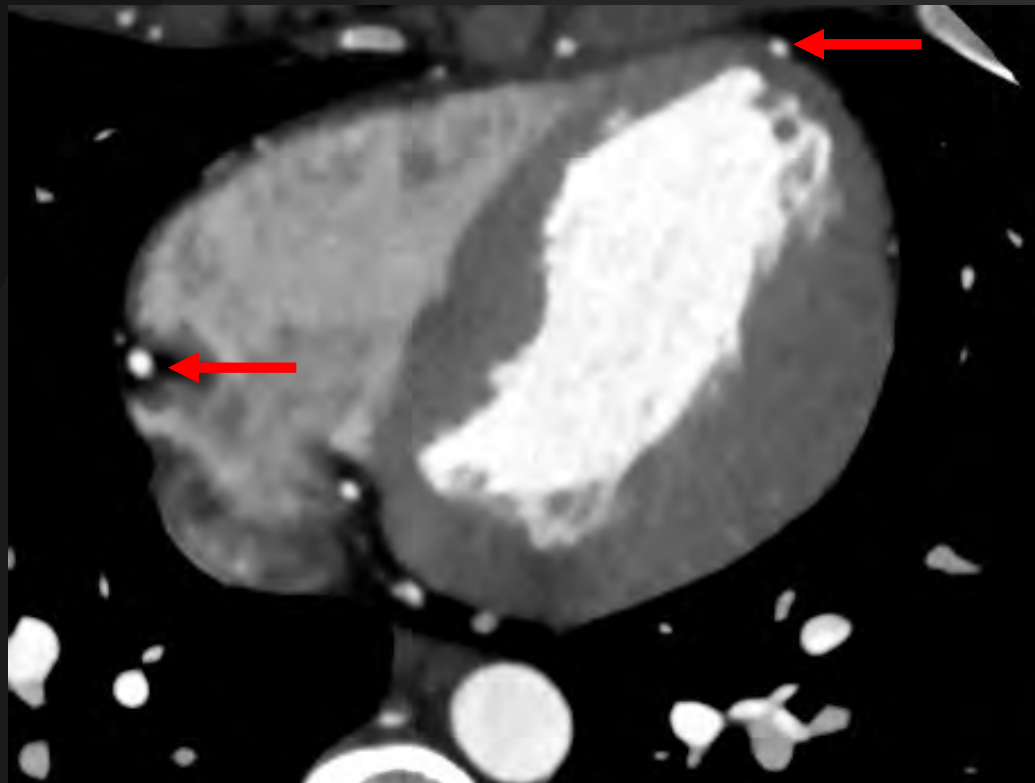
Coronaires



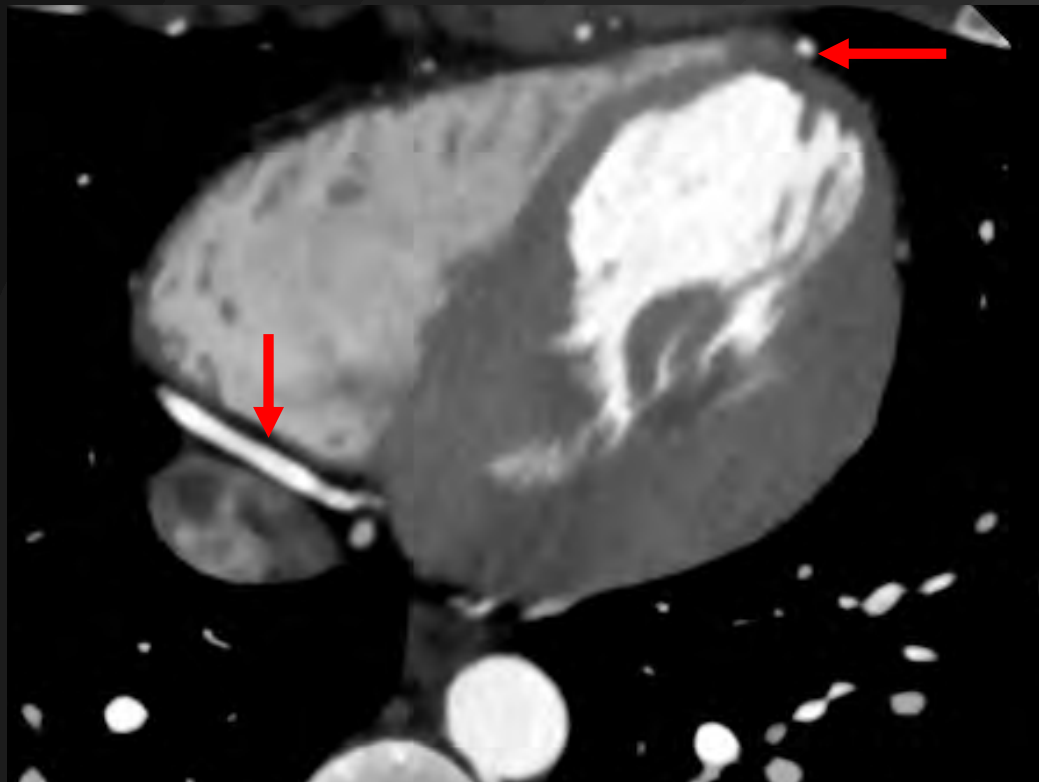
Coronaires



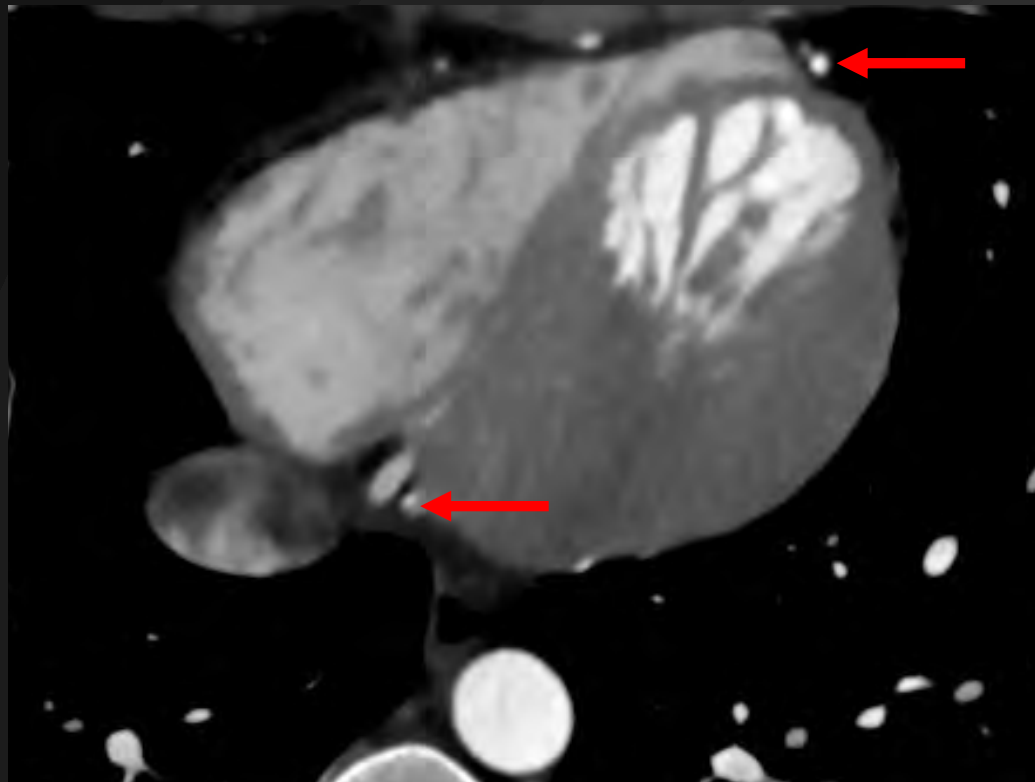
Coronaires



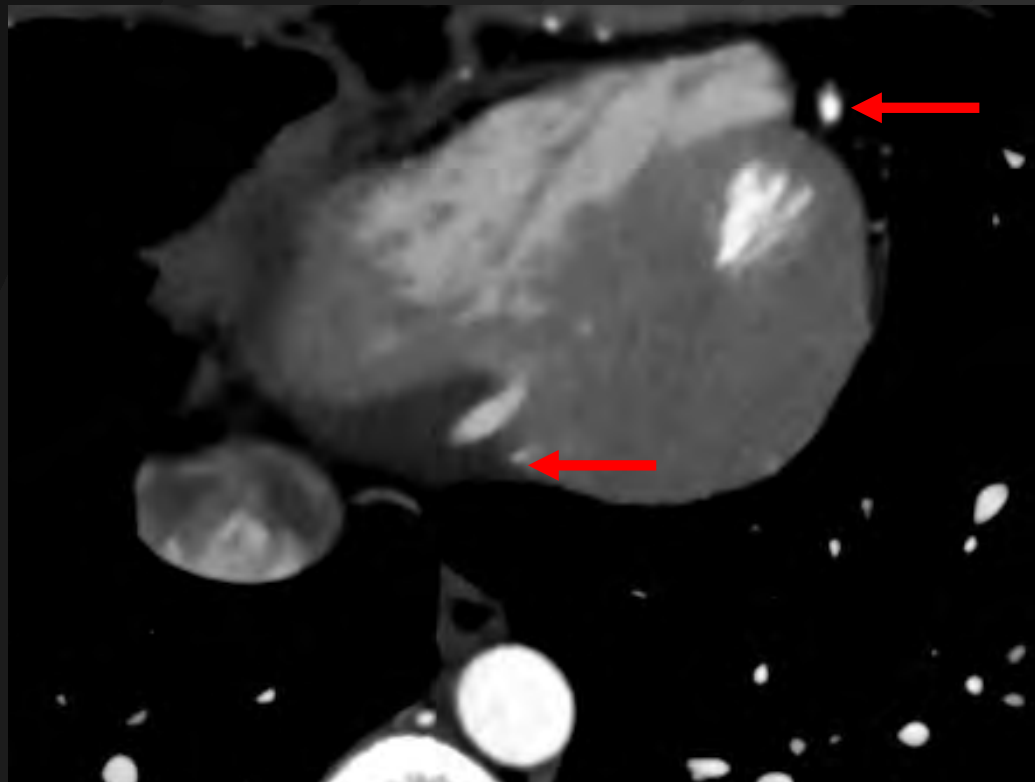
Coronaires



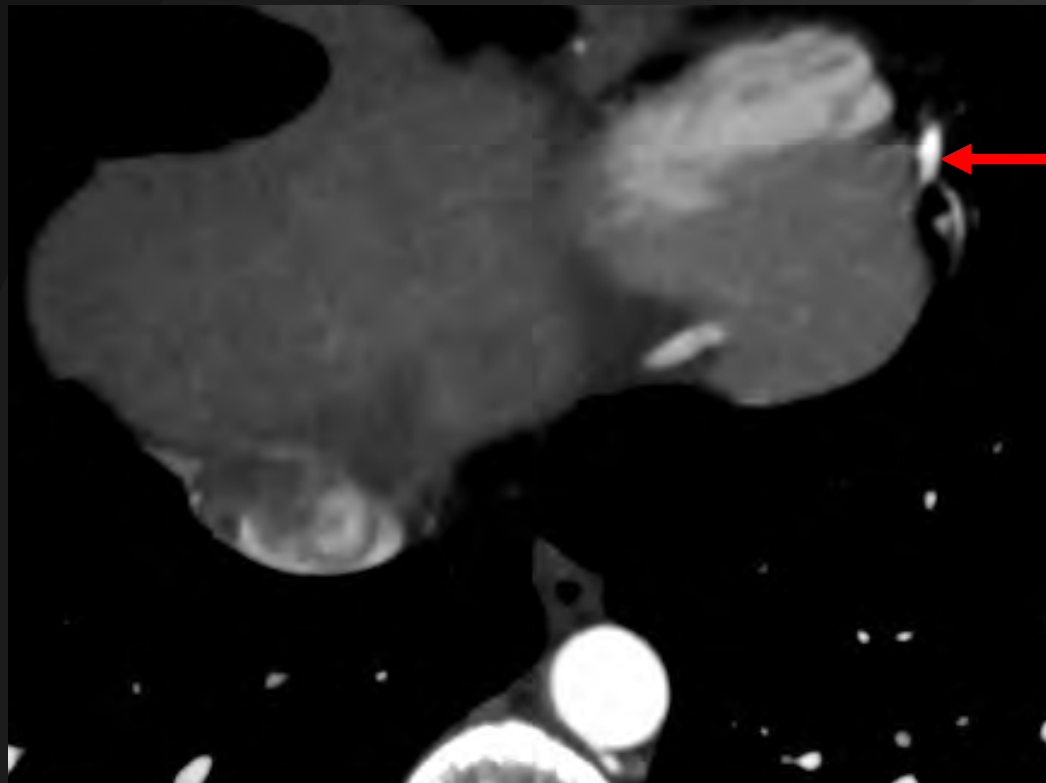
Coronaires



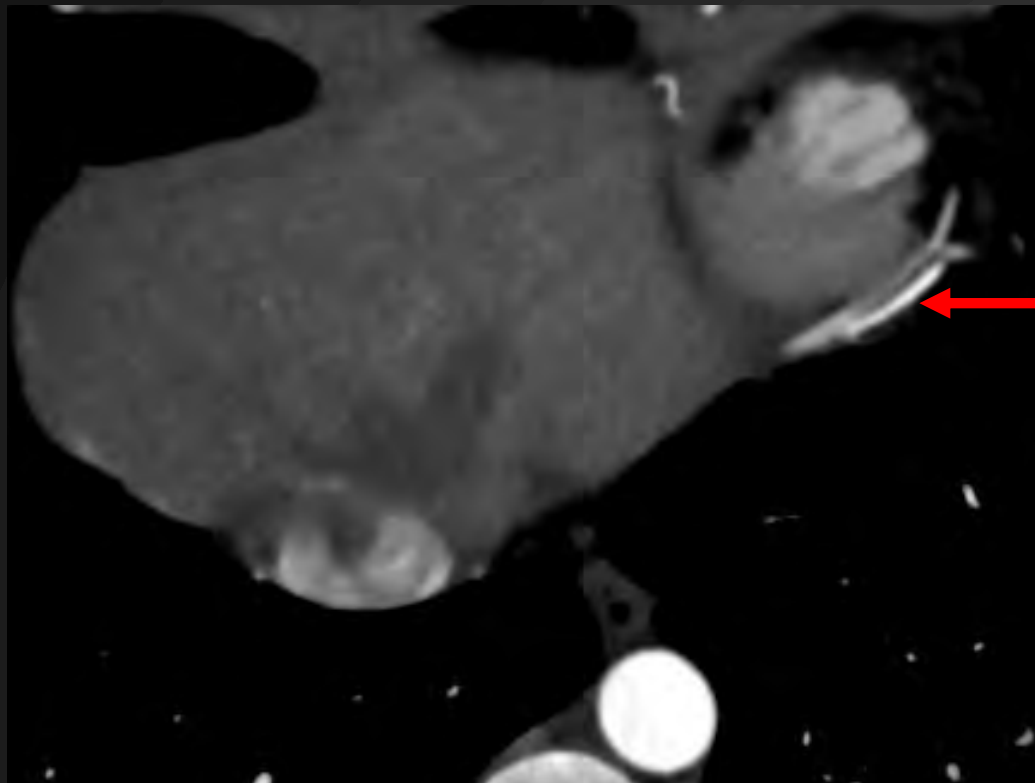
Coronaires



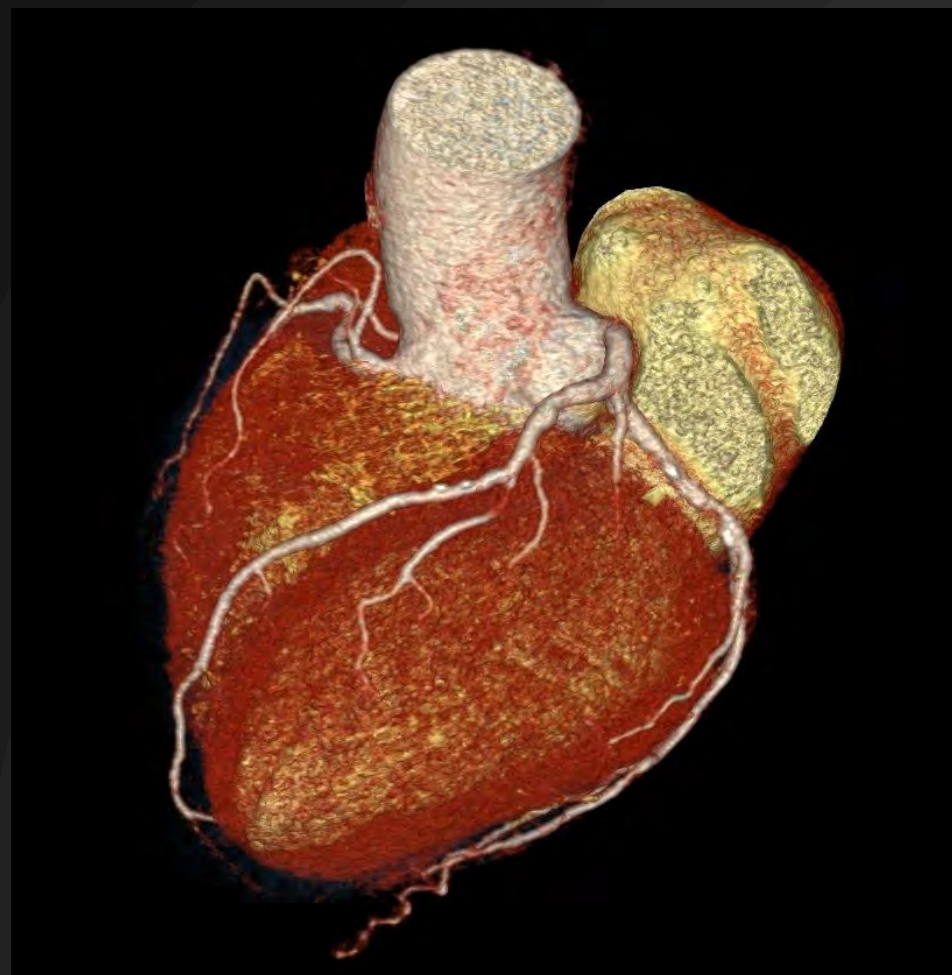
Coronaires



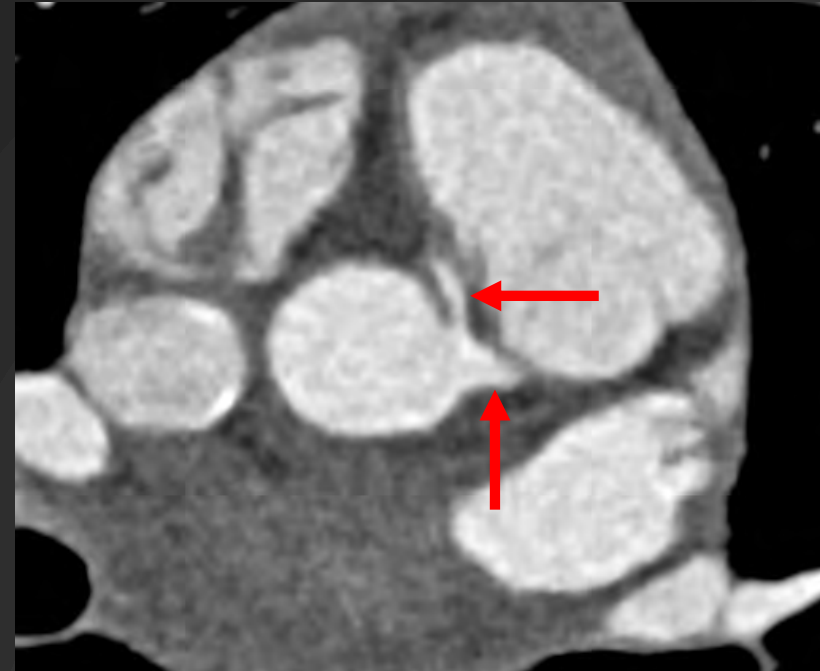
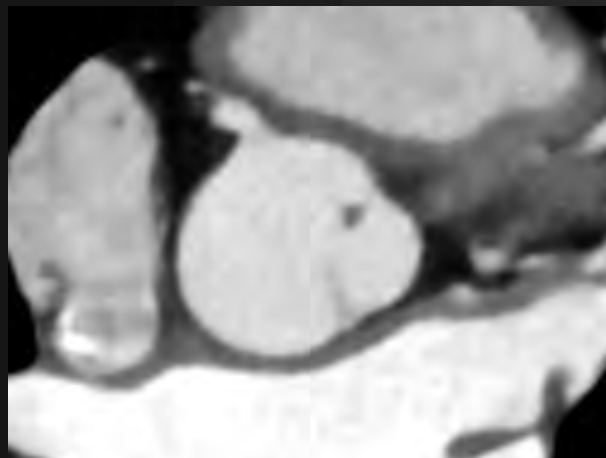
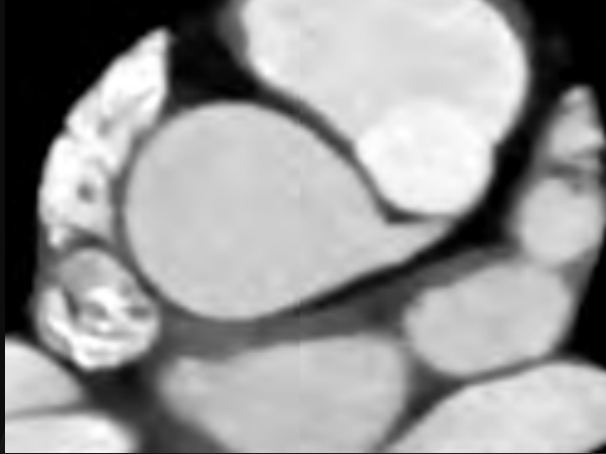
Coronaires



Coronaires

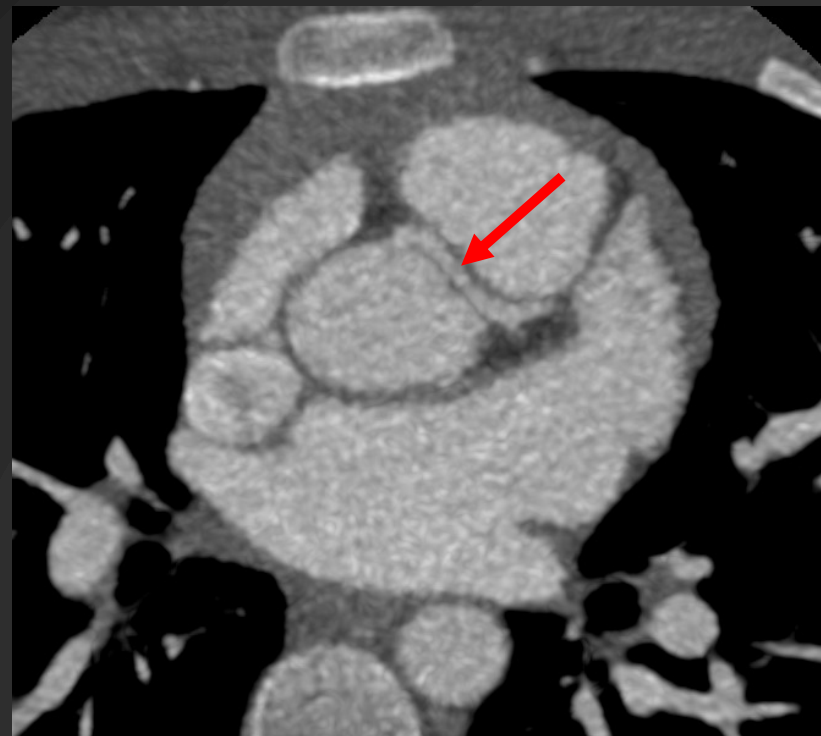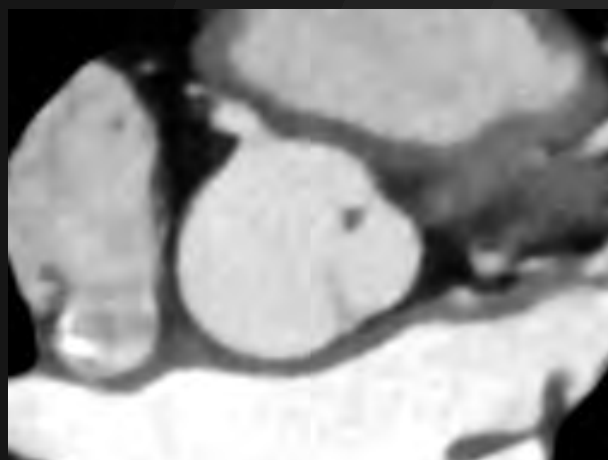
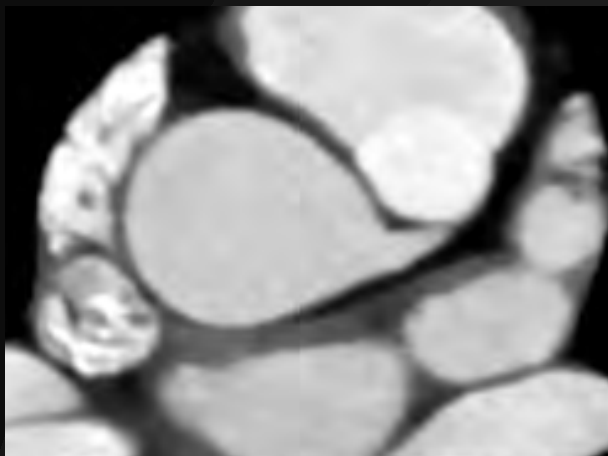


Coronaires



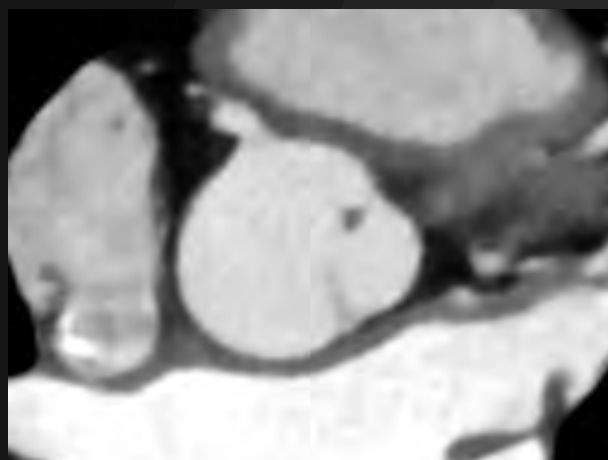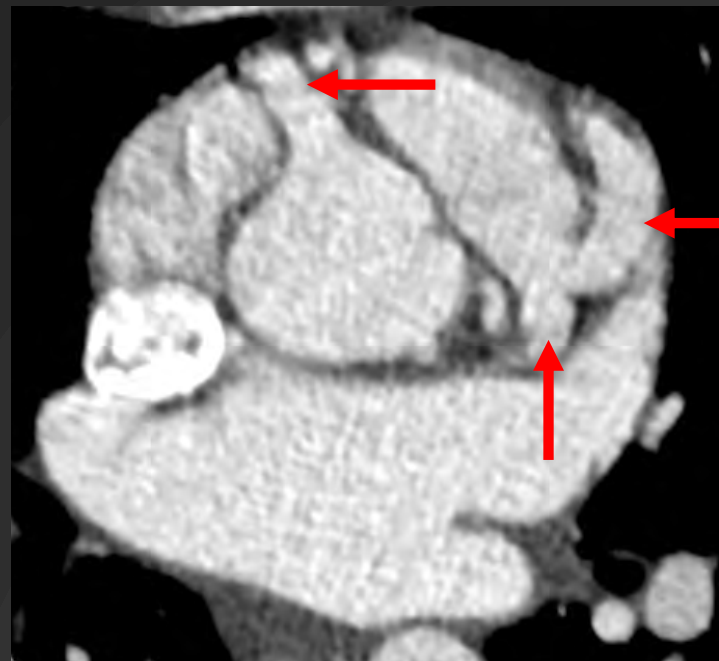
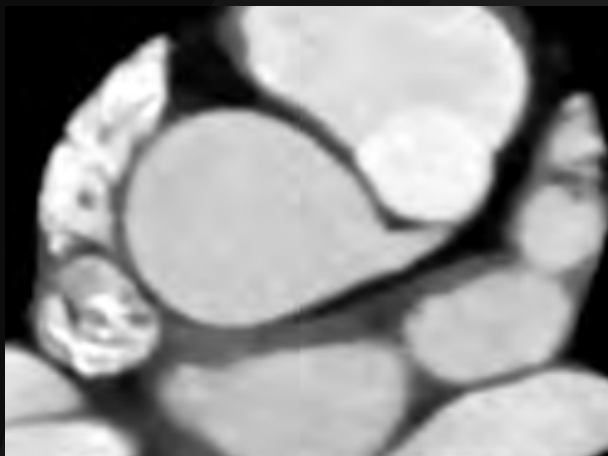
Coronaire D naissant de l'ostium gauche

Coronaires



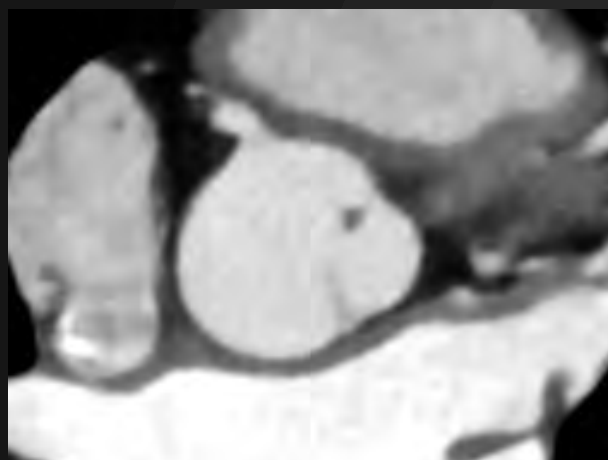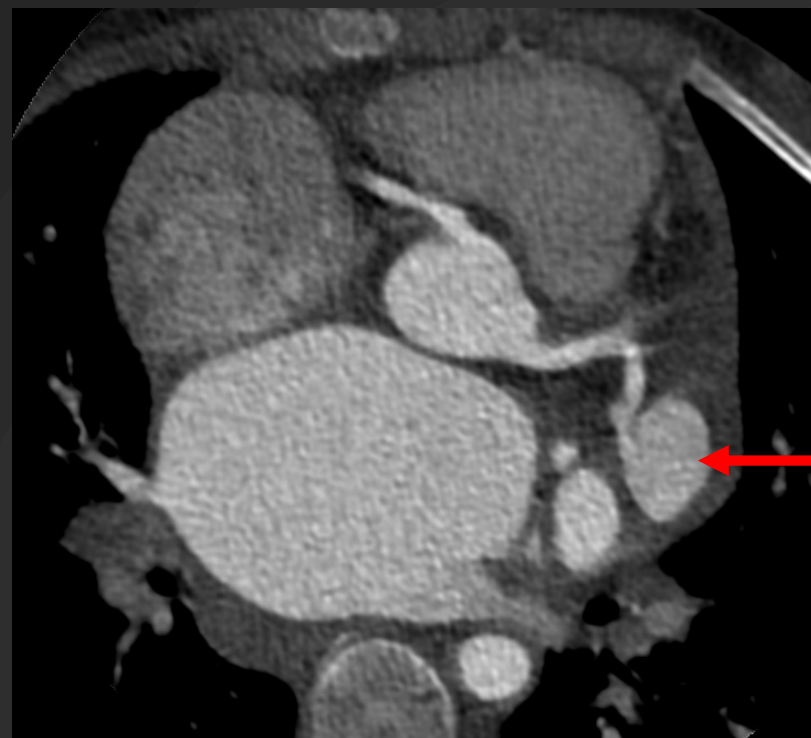
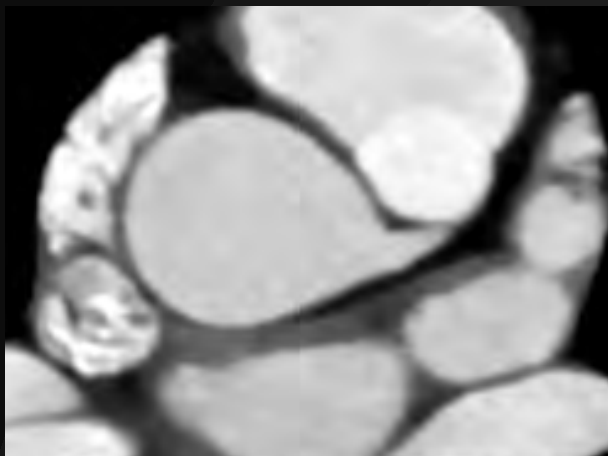
Coronaire G naissant de l'ostium droit

Coronaires



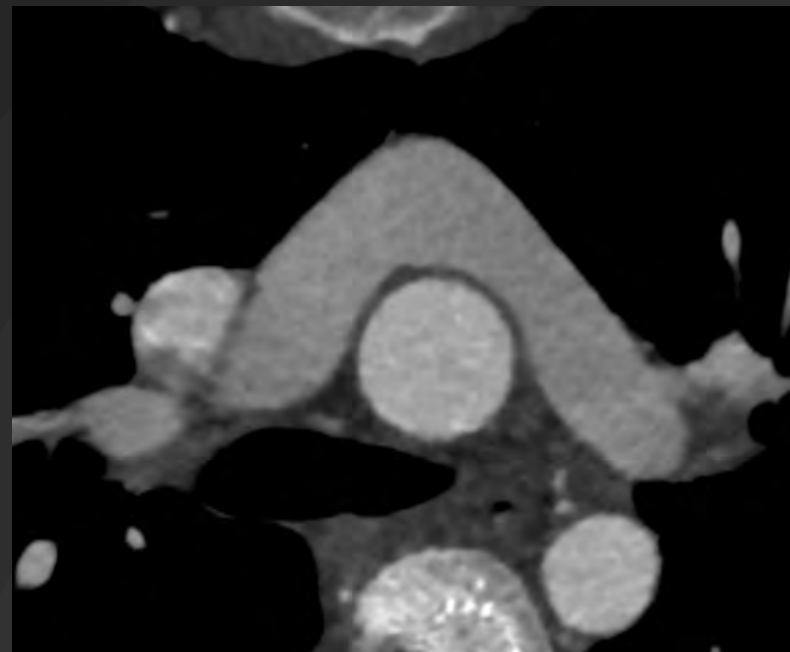
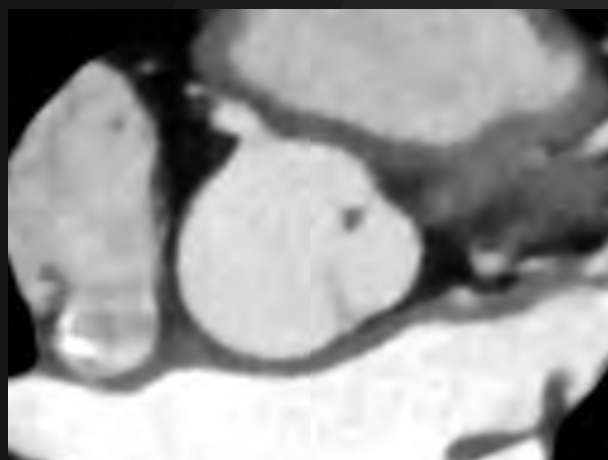
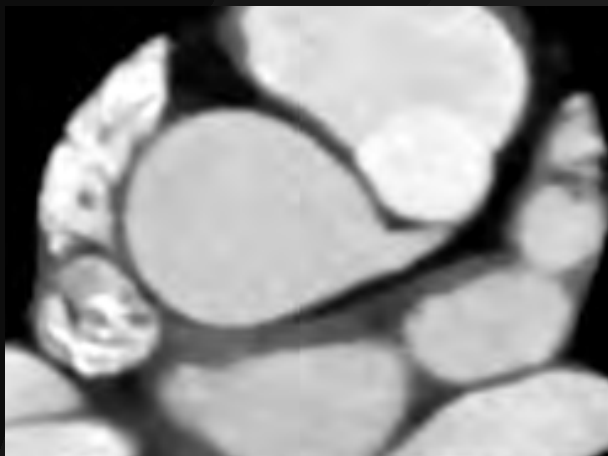
ALCAPA

Coronaires



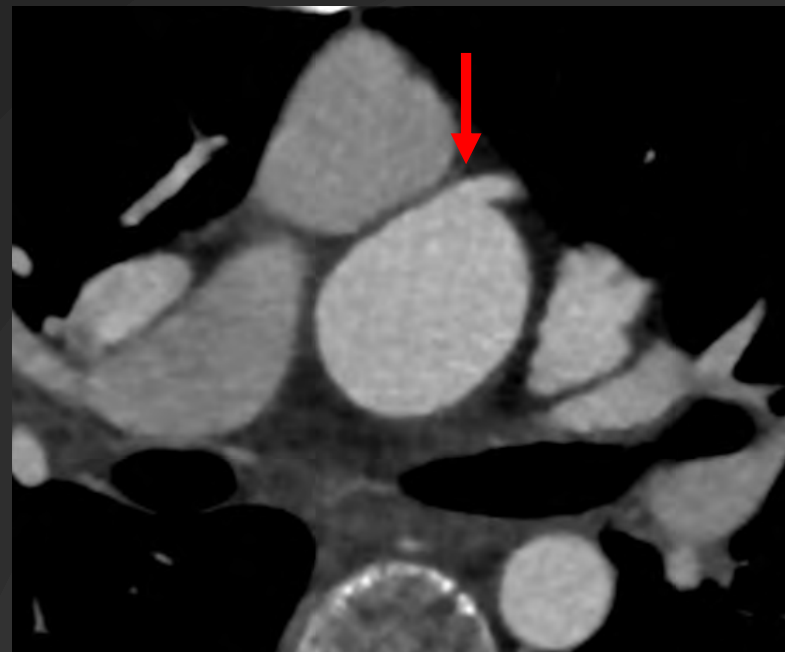
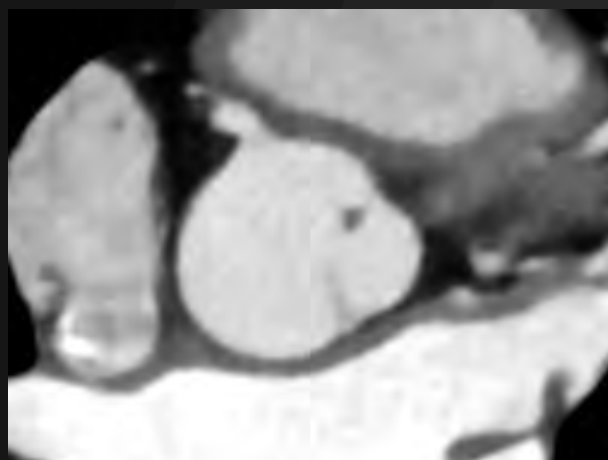
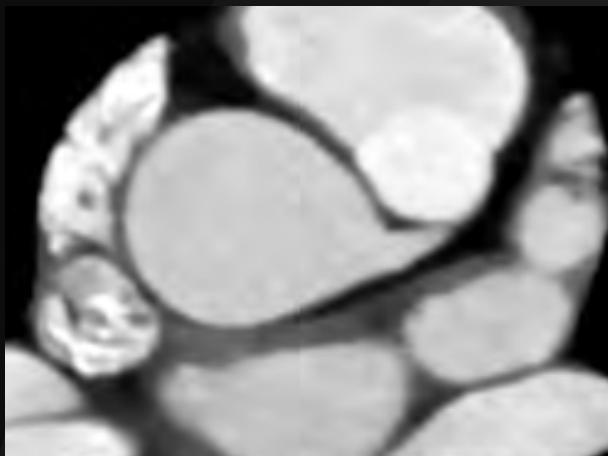
Anévrisme coronaire

Coronaires



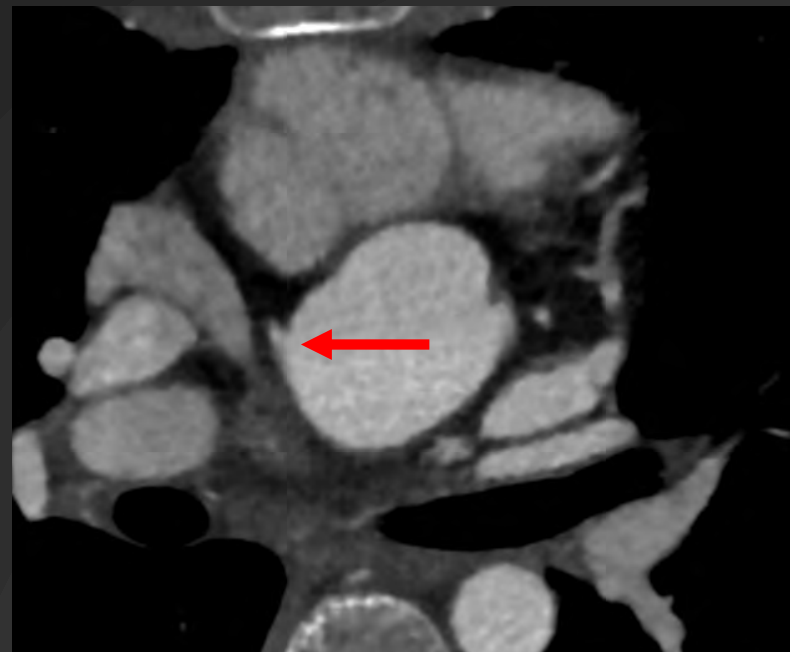
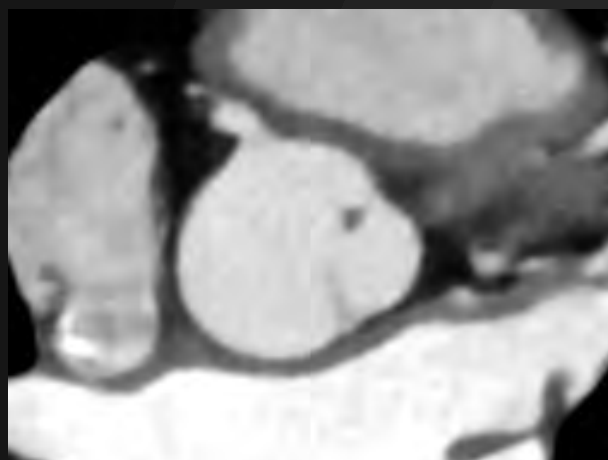
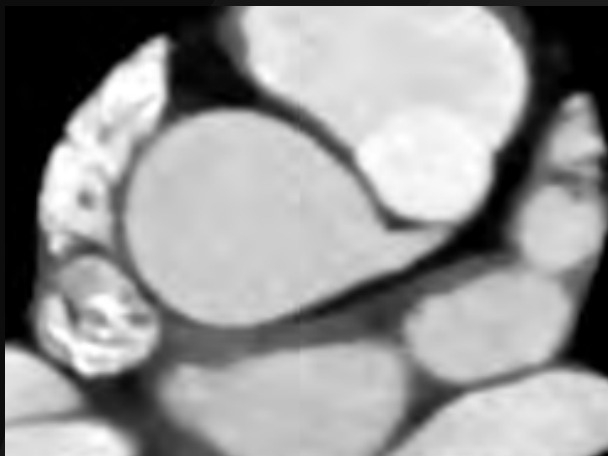
TGV opérée

Coronaires



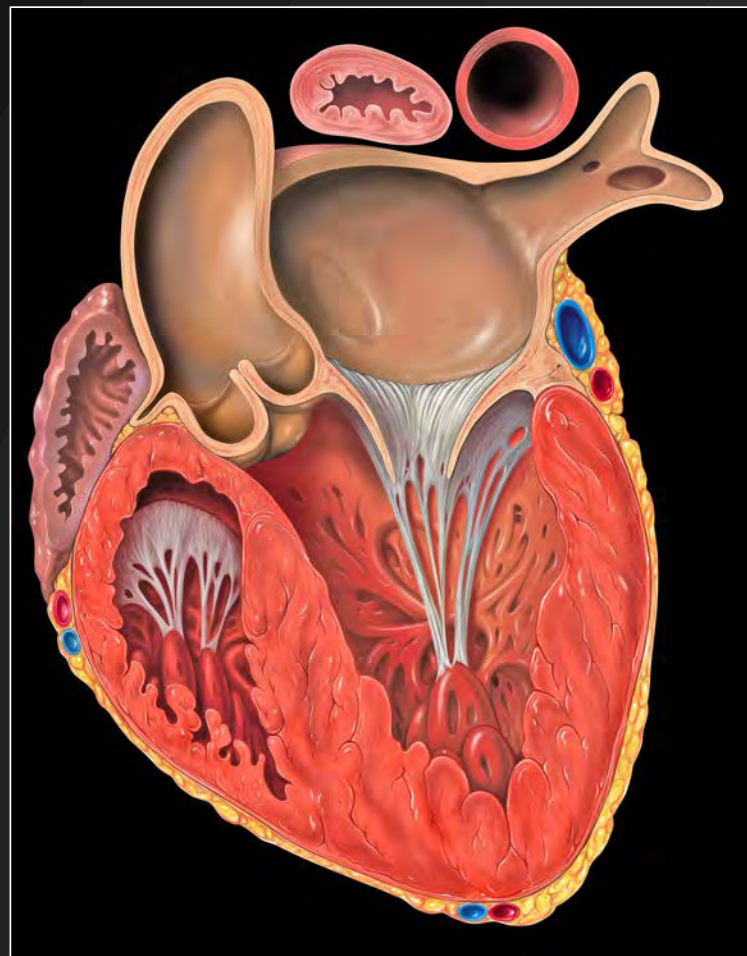
TGV opérée

Coronaires



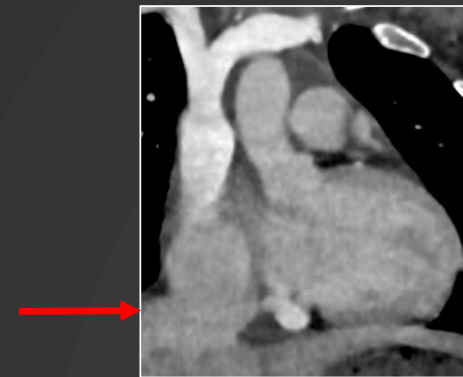
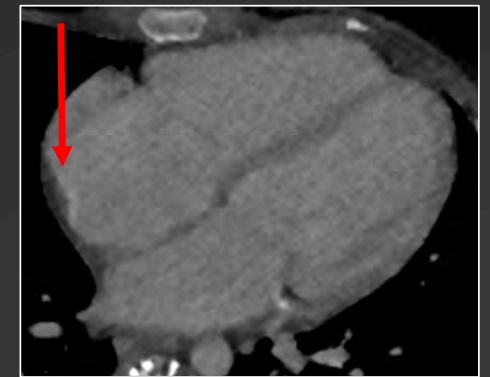
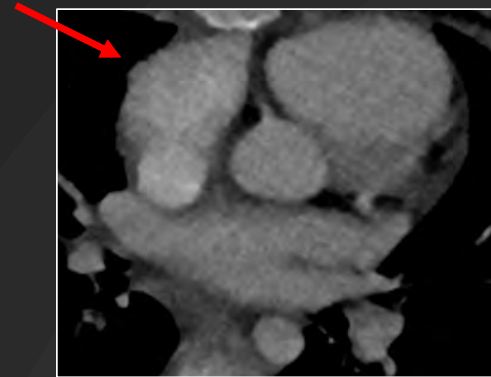
TGV opérée

Cavités cardiaques



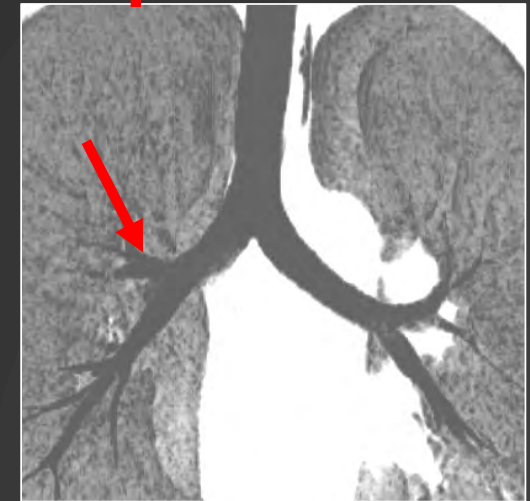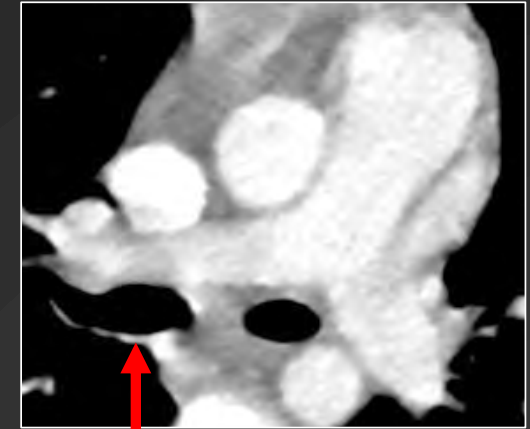
Cavités cardiaques

- Atrium droit *morphologique* :
 - Auricule large, triangulaire
 - Crista terminalis
 - Concordance veino-atriale



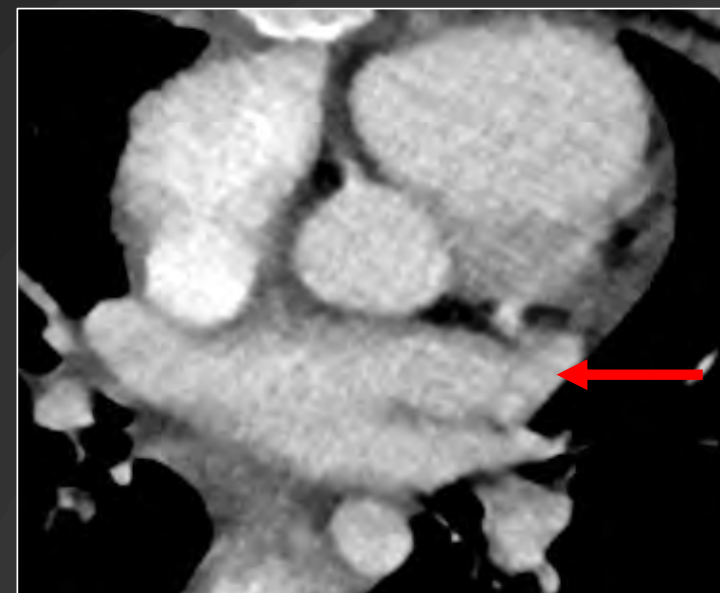
Cavités cardiaques

- Atrium droit *morphologique* :
 - Auricule large, triangulaire
 - Crista terminalis
 - Concordance veino-atriale
 - Du côté de la bronche et de l'AP droite :
 - Bronche en arrière de l'AP, 3 lobes
 - Naissance précoce de la bronche du LSD



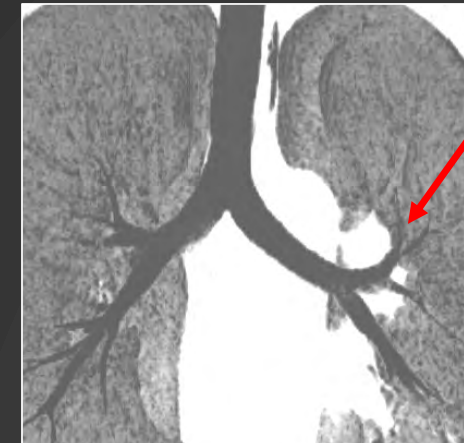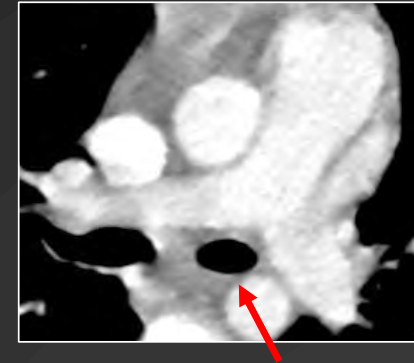
Cavités cardiaques

- Atrium gauche *morphologique* :
 - Auricule fin, tubulaire, en doigt de gant



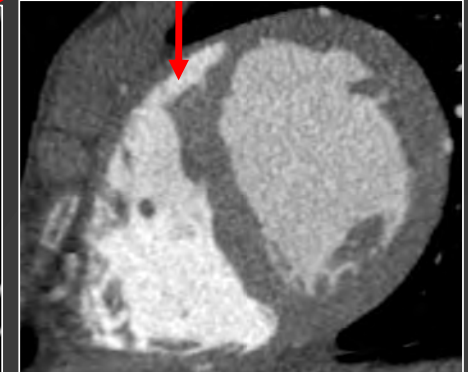
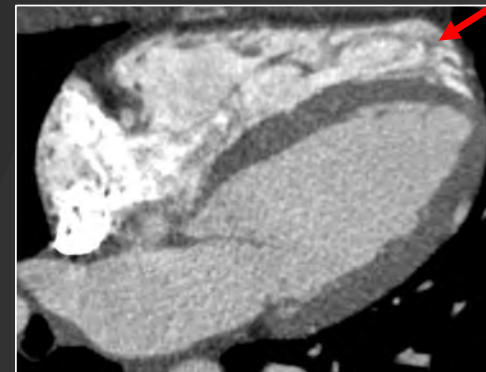
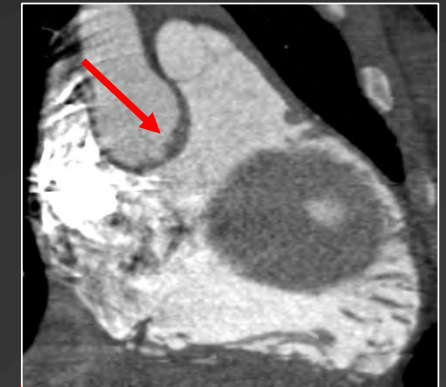
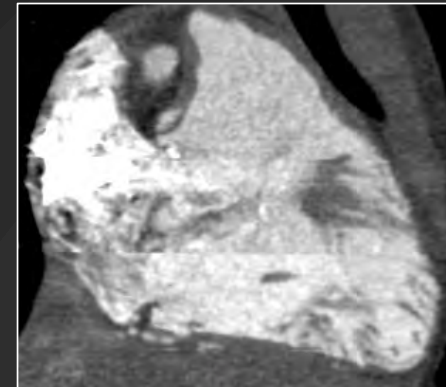
Cavités cardiaques

- Atrium gauche *morphologique* :
 - Auricule fin, tubulaire, en doigt de gant
 - Du côté de la bronche et de l'AP gauche :
 - Bronche sous l'AP, 2 lobes
 - Naissance tardive de la bronche du LSG



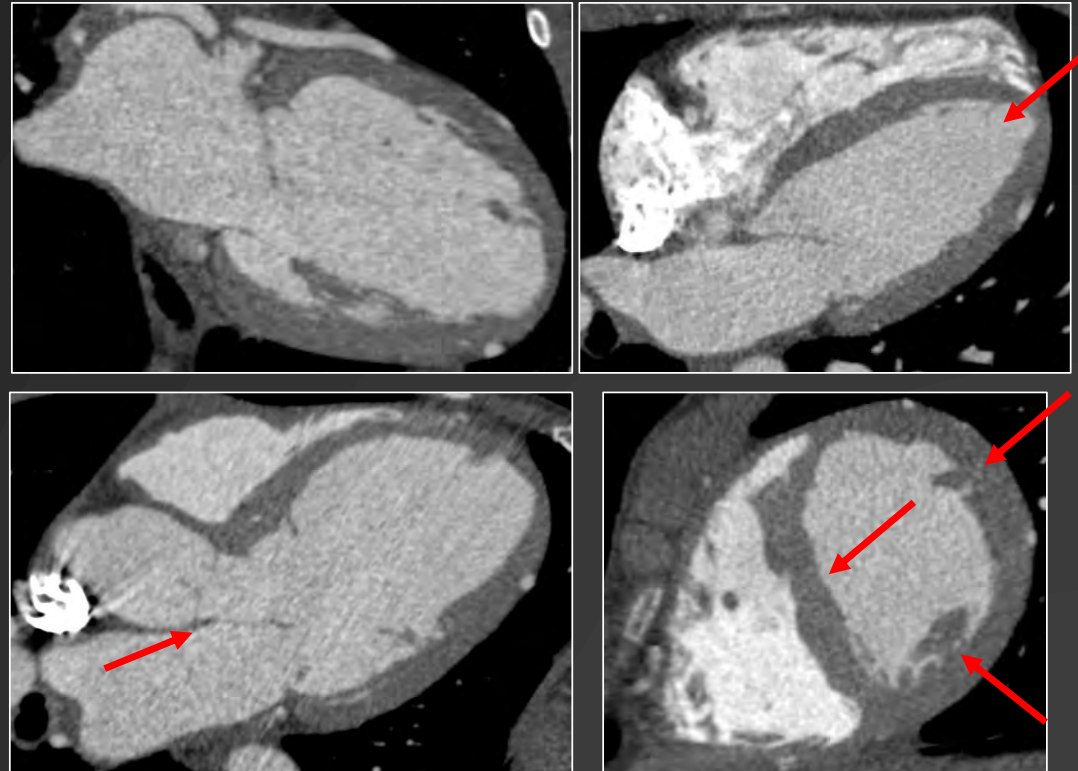
Cavités cardiaques

- Ventricule droit *morphologique*
 - Bande modératrice
 - Trabéculations épaisses
 - Muscles papillaires sur mur libre et septum
 - Valve tricuspide
 - Discontinuité tricuspide-pulmonaire (infundibulum)



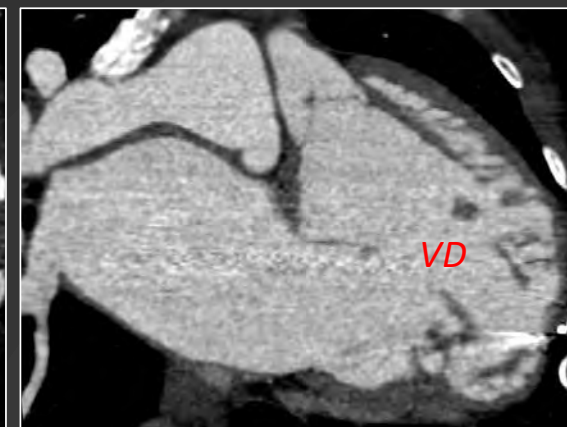
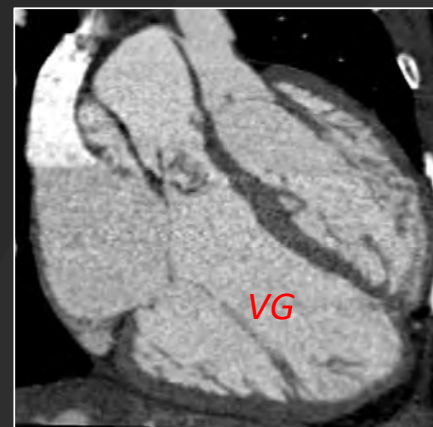
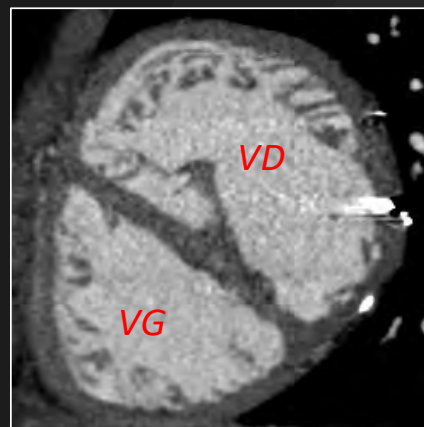
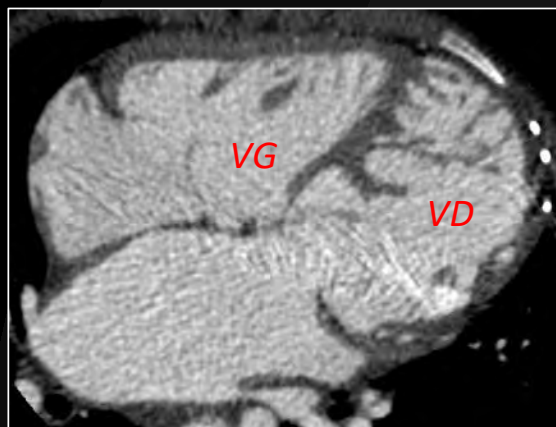
Cavités cardiaques

- **Ventricule gauche *morphologique***
 - Trabéculations fines
 - Muscles papillaires uniquement sur paroi libre
 - Septum lisse
 - Valve mitrale bicuspide
 - Continuité mitro-aortique

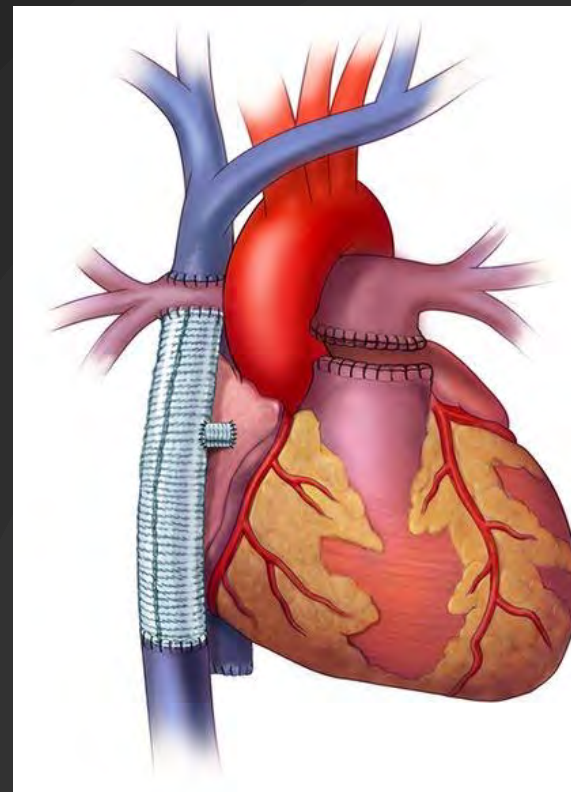
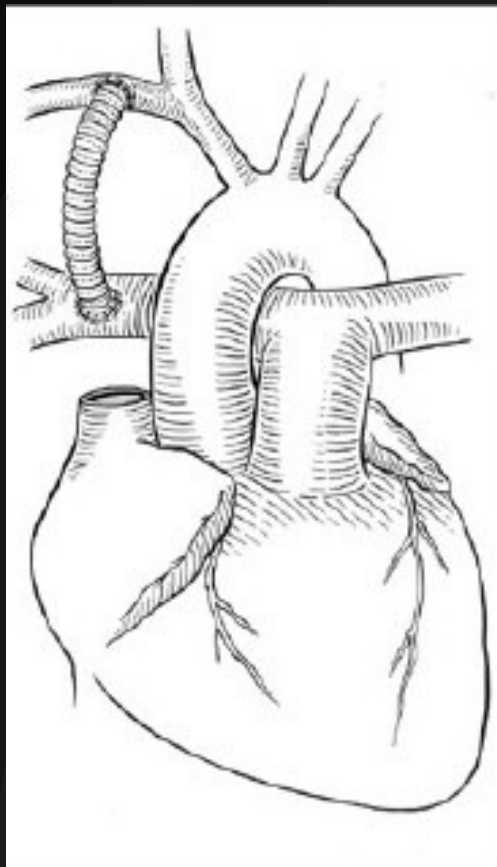


Cavités cardiaques

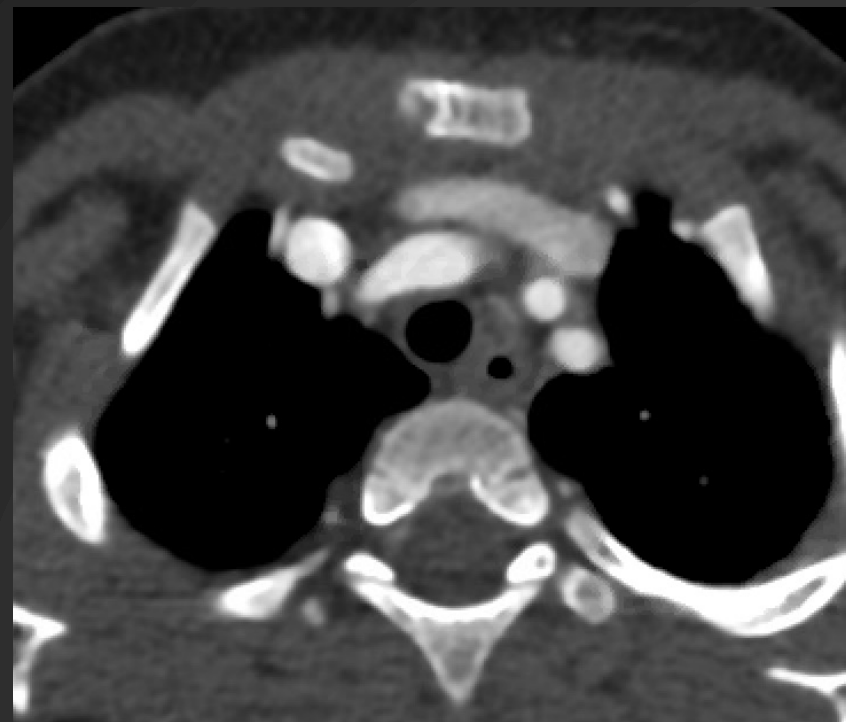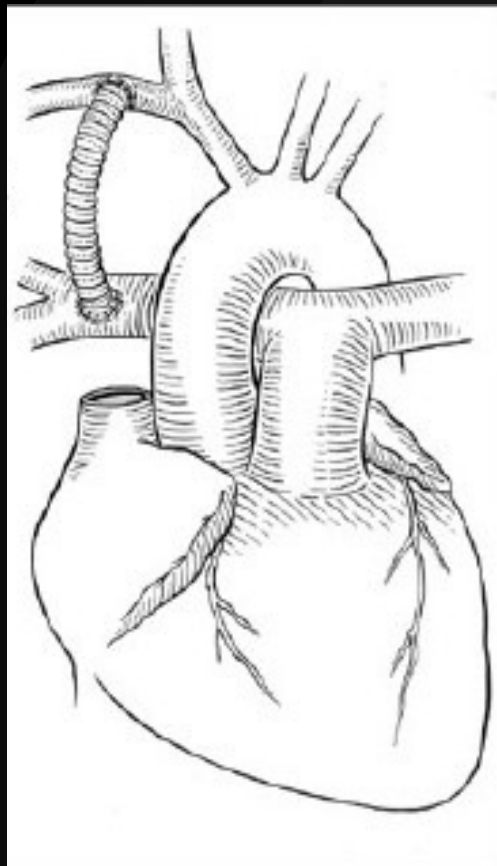
- Double discordance



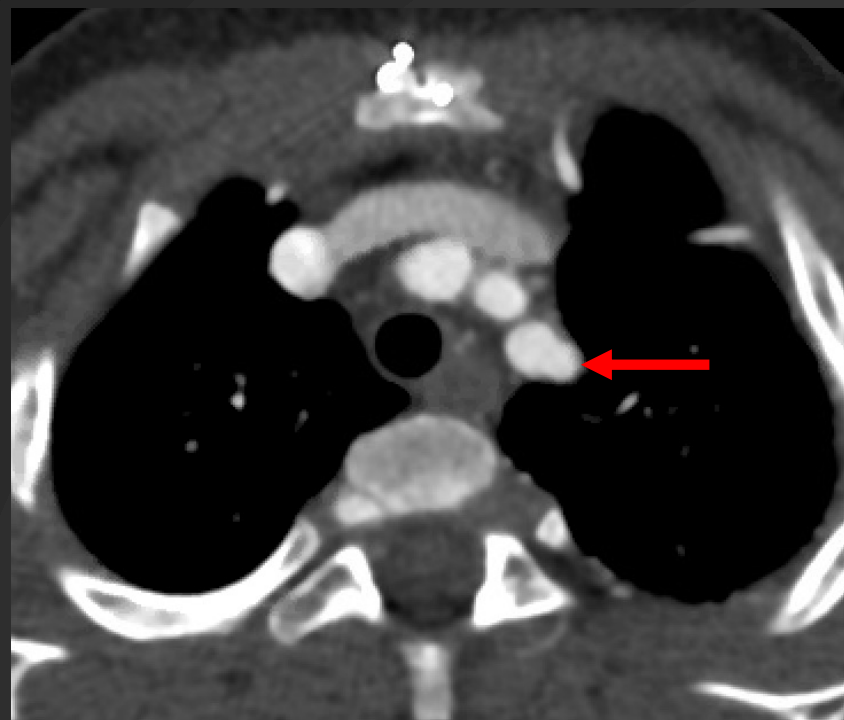
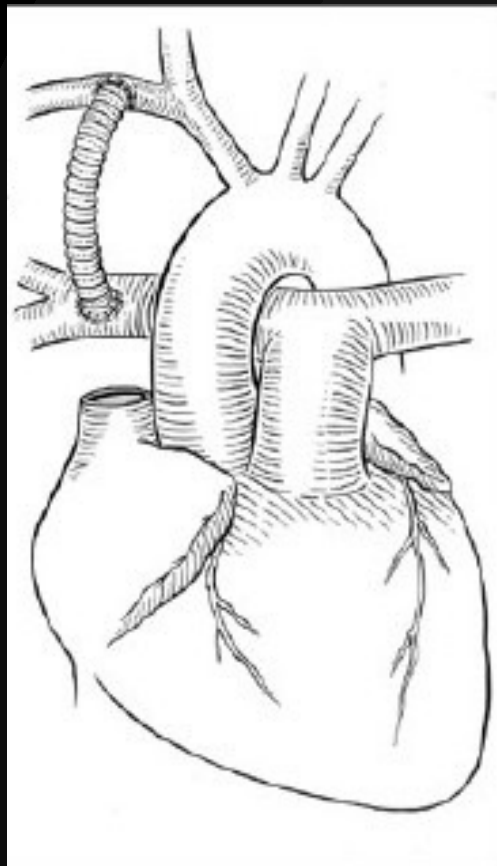
Montages chirurgicaux



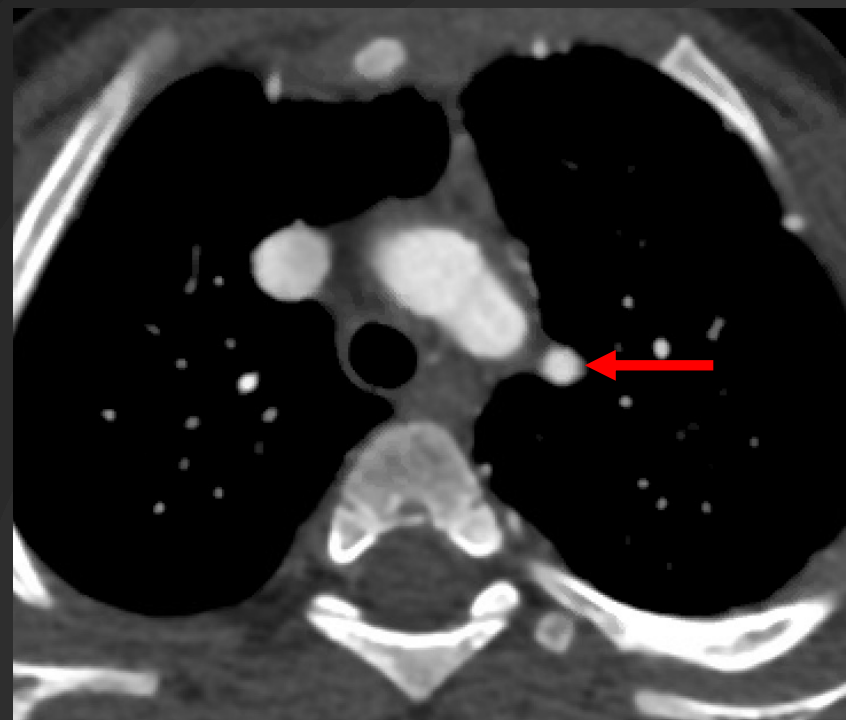
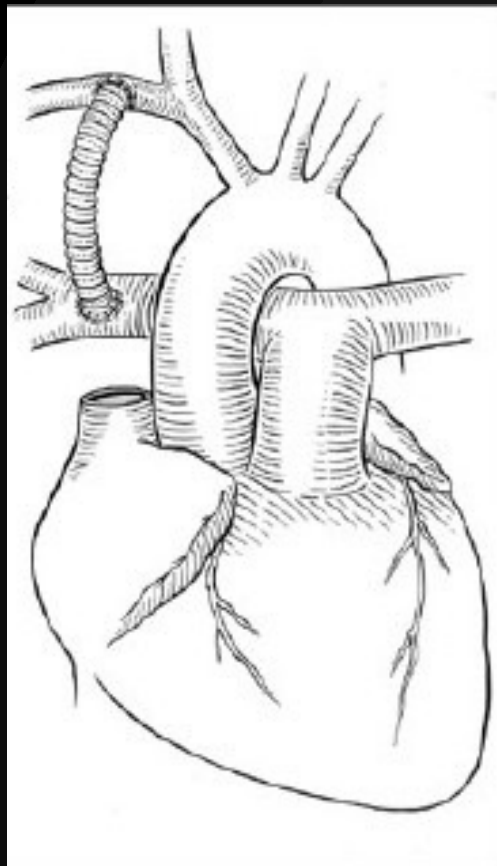
Montages chirurgicaux



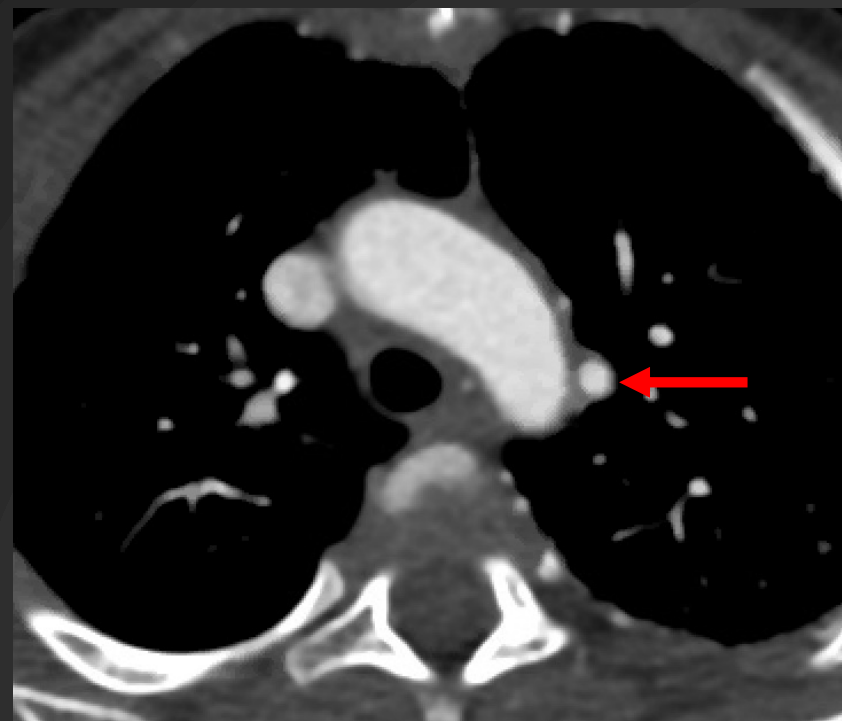
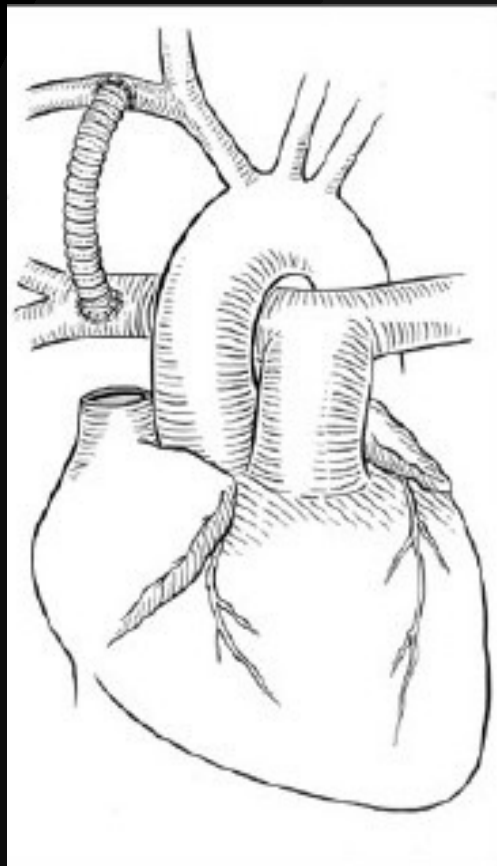
Montages chirurgicaux



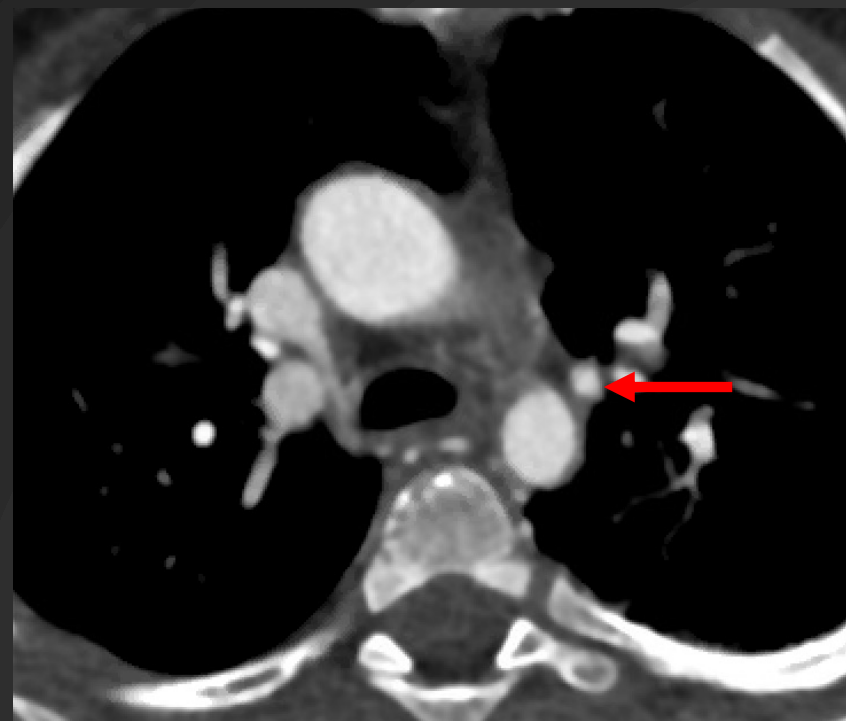
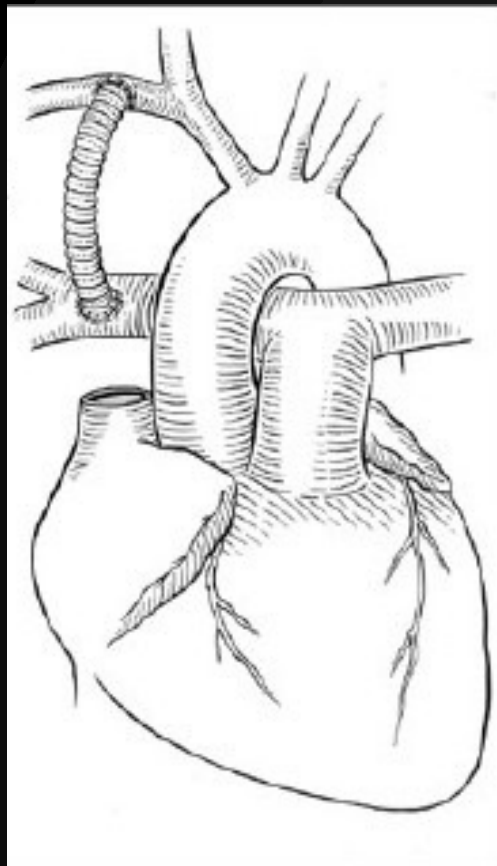
Montages chirurgicaux



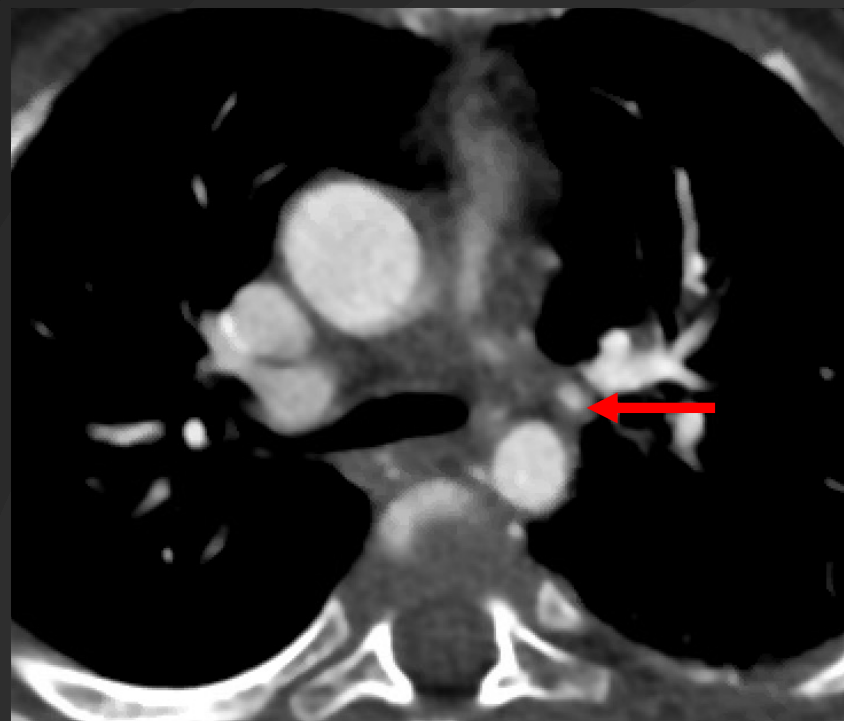
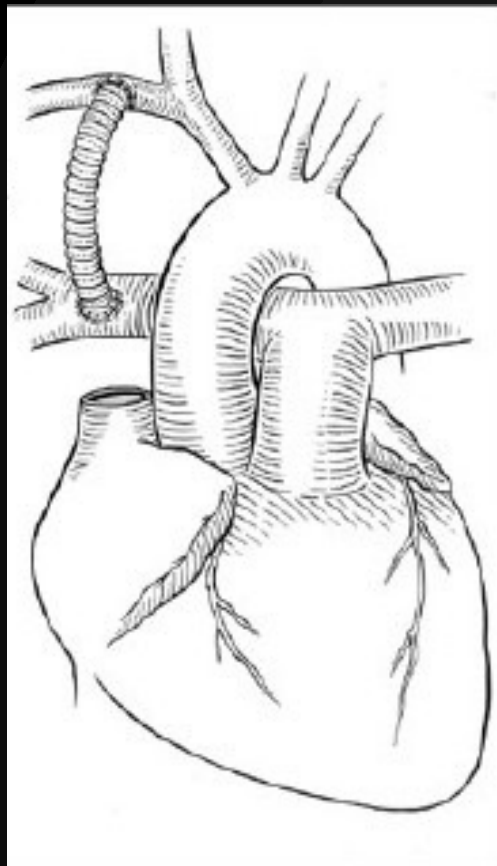
Montages chirurgicaux



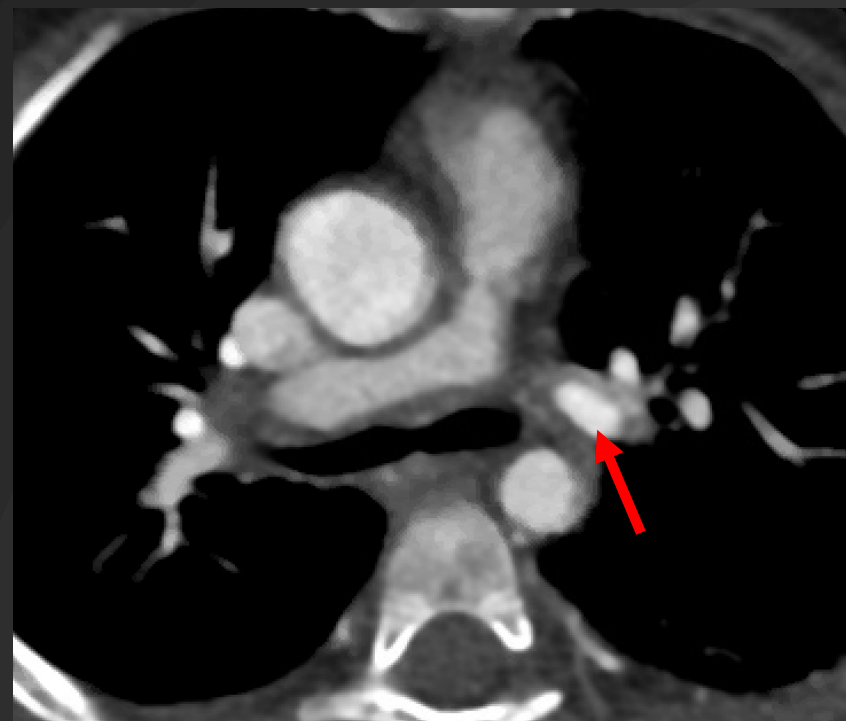
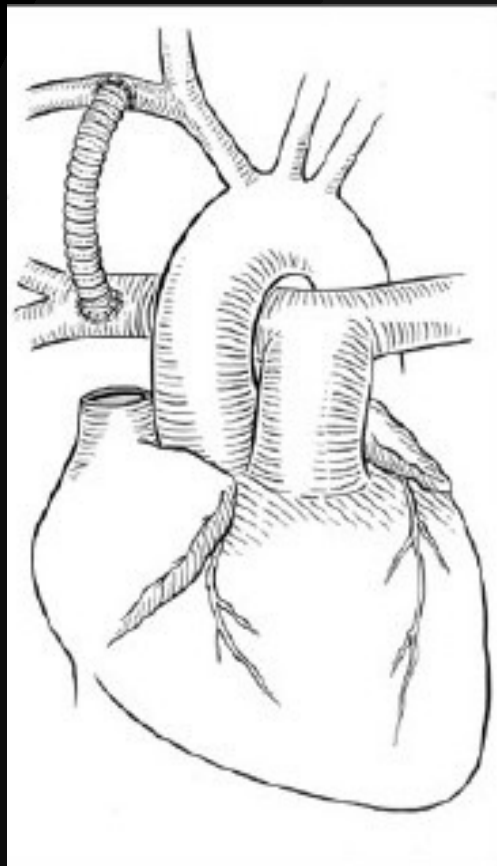
Montages chirurgicaux



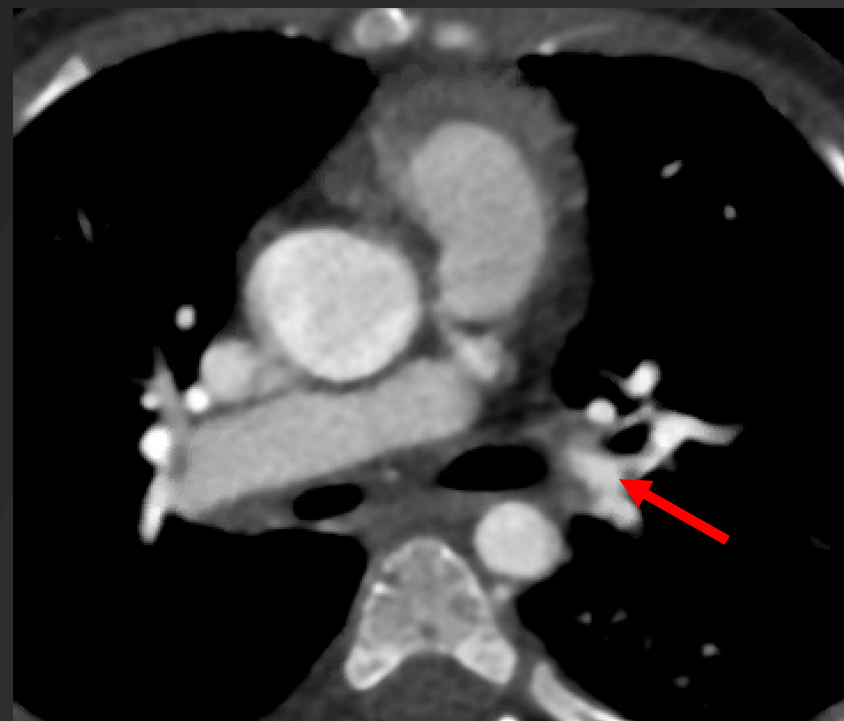
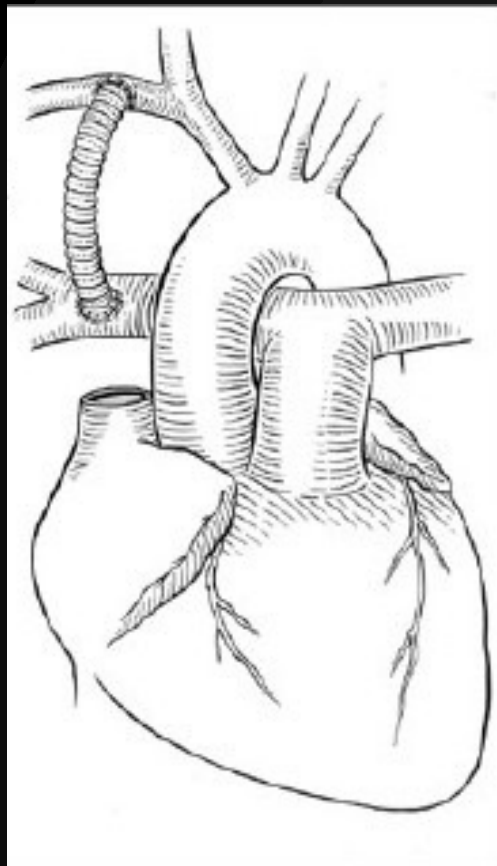
Montages chirurgicaux



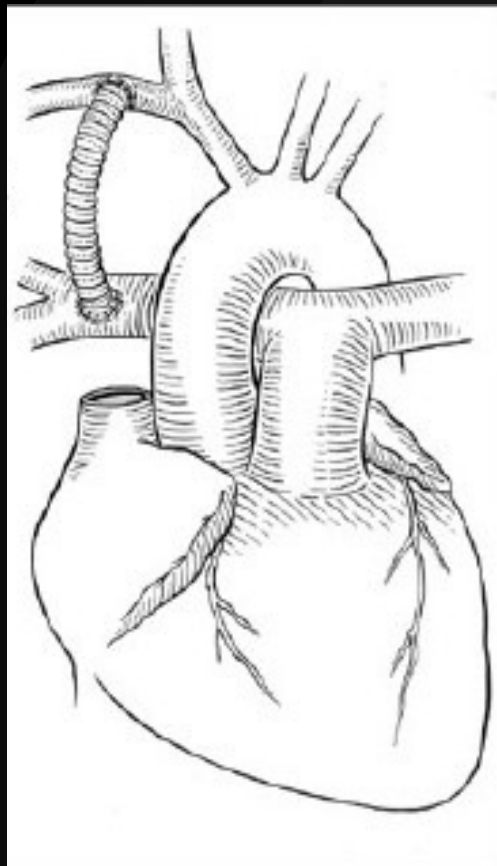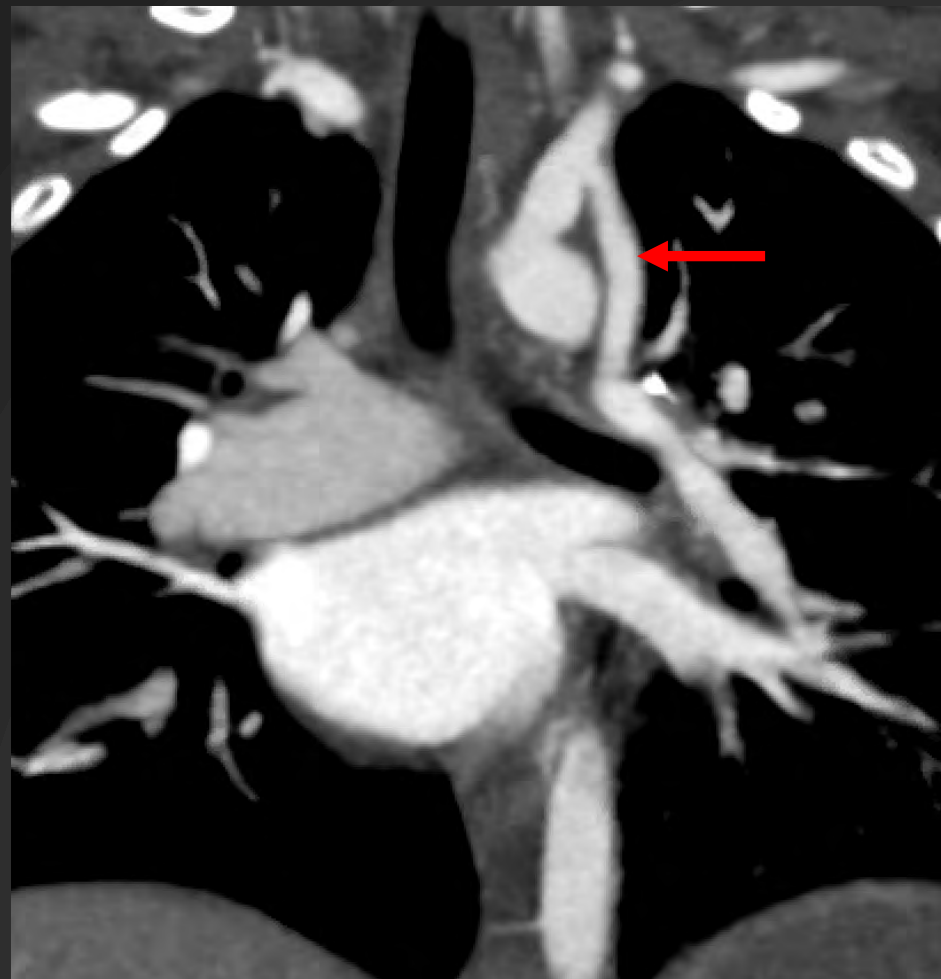
Montages chirurgicaux



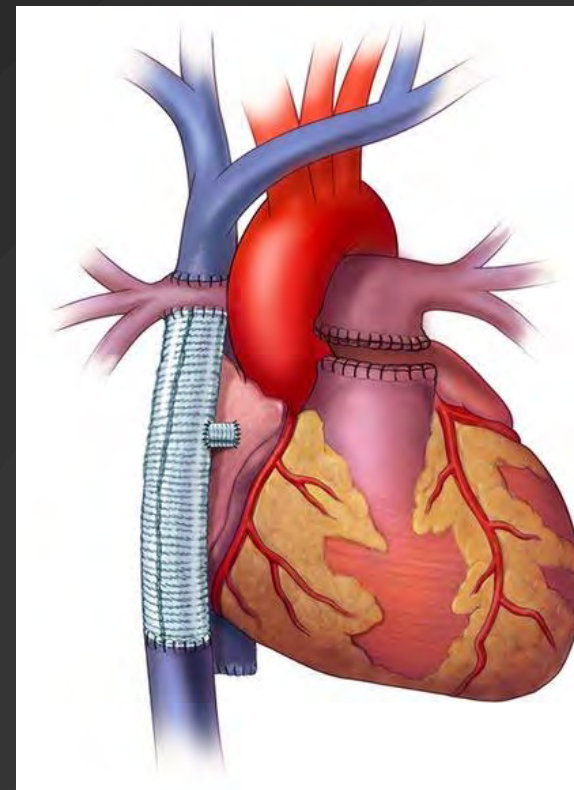
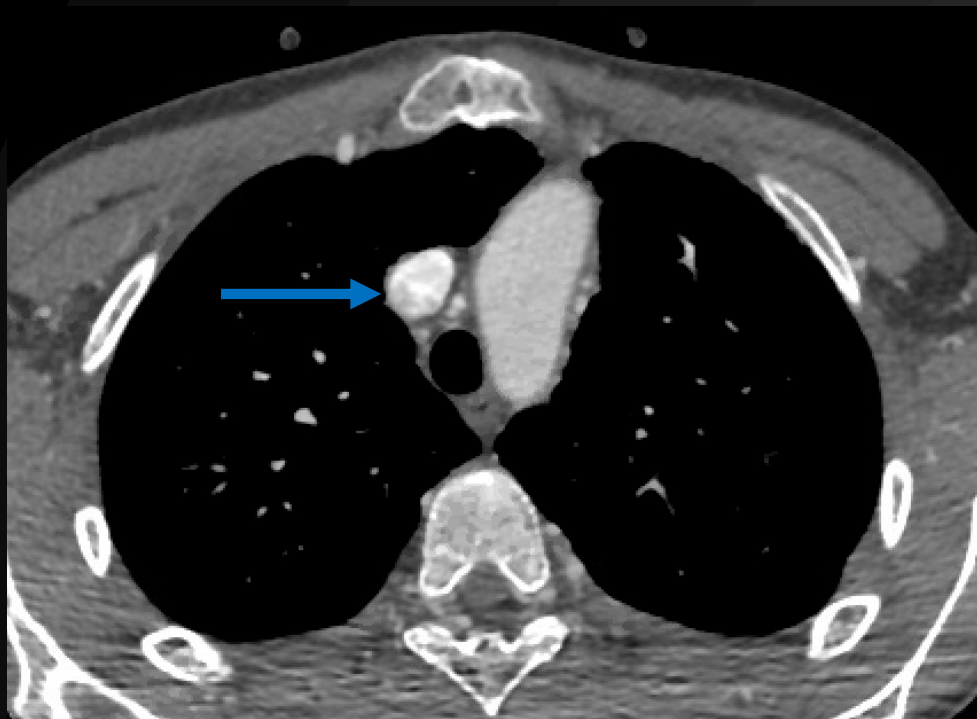
Montages chirurgicaux



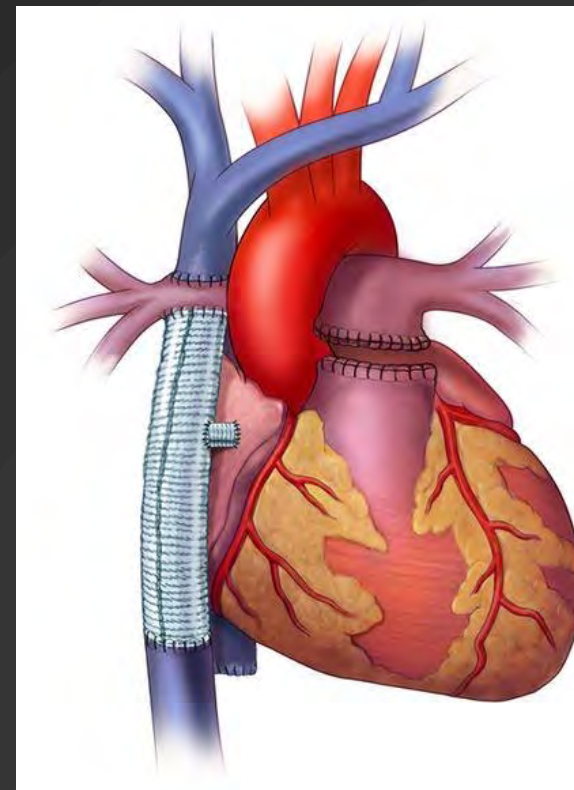
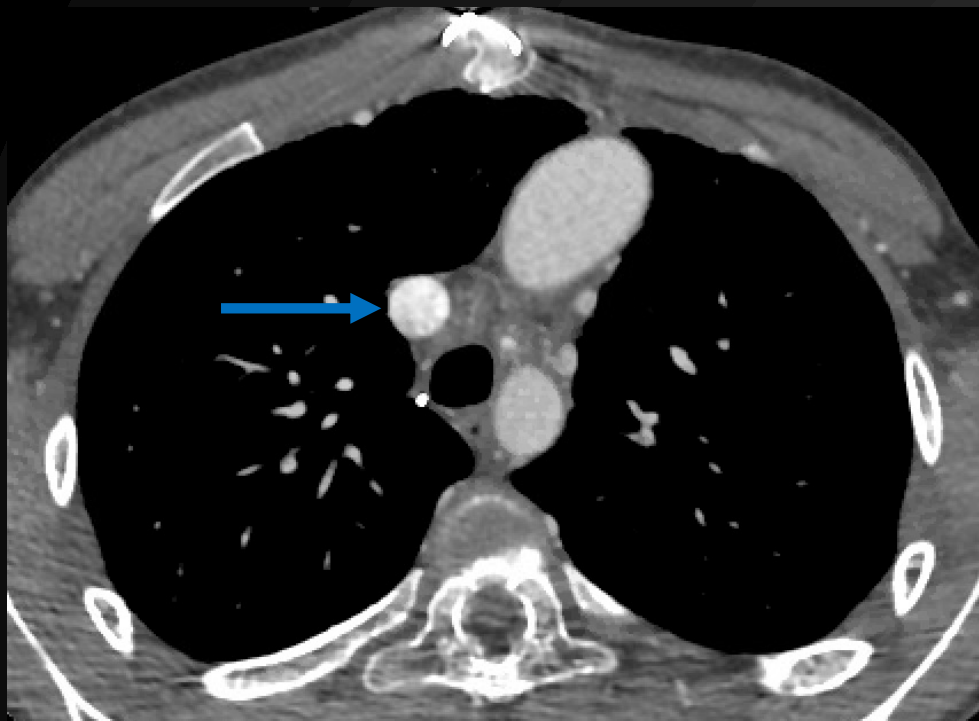
Montages chirurgicaux



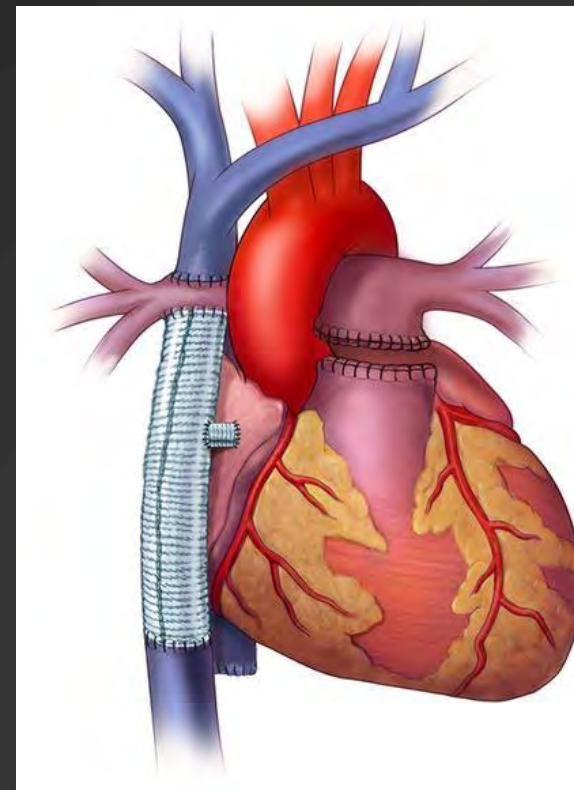
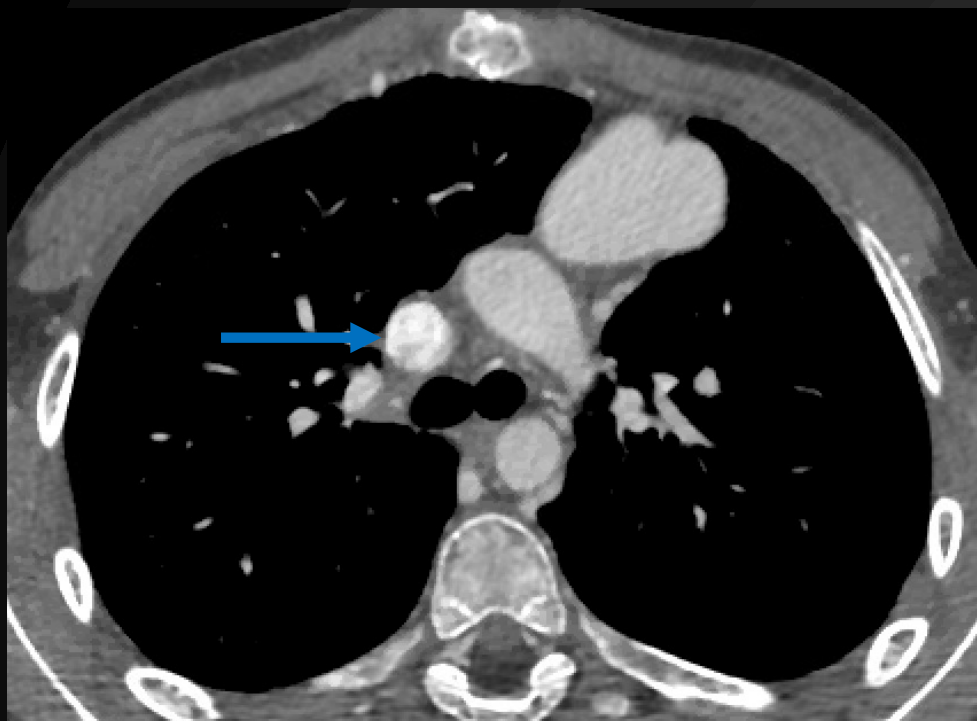
Montages chirurgicaux



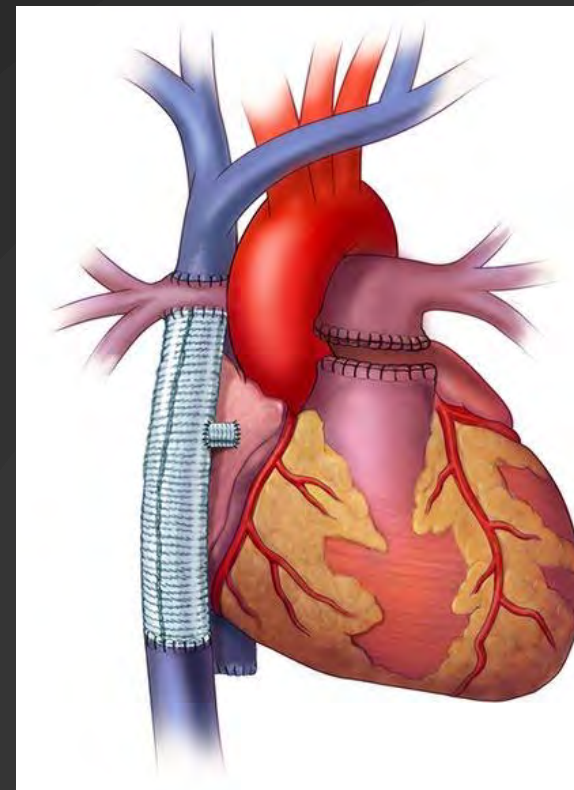
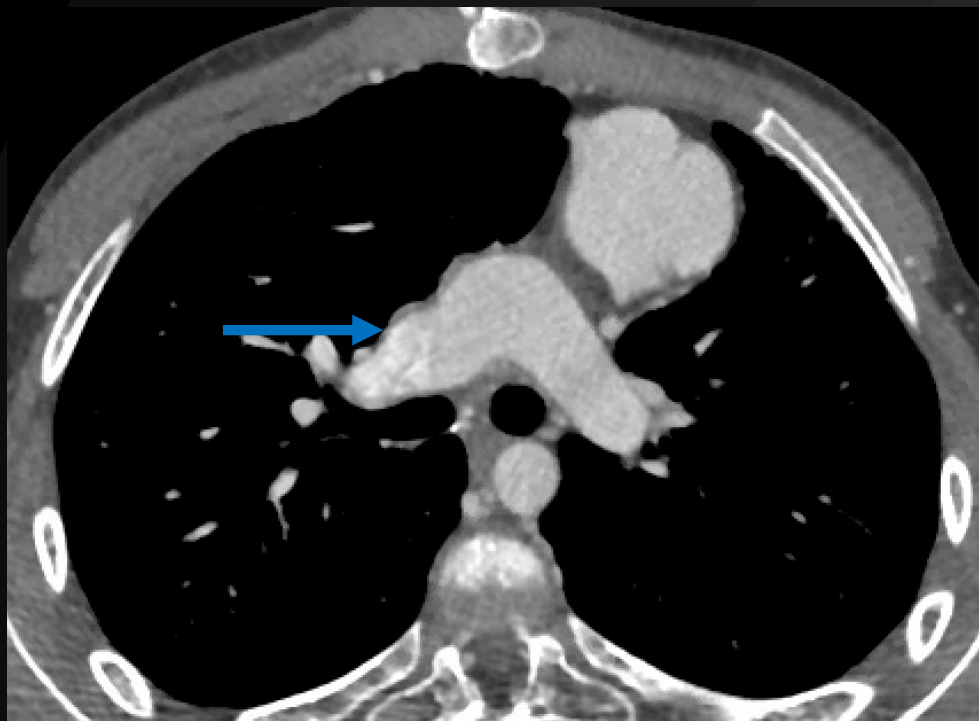
Montages chirurgicaux



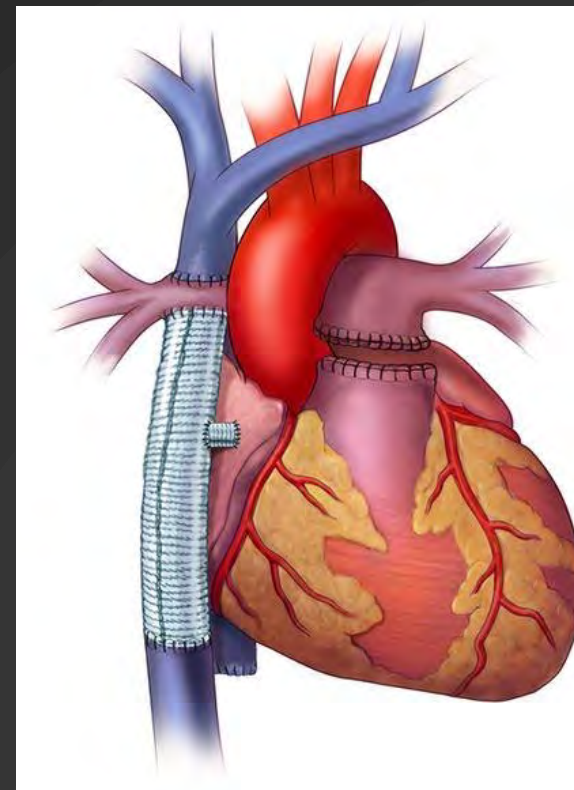
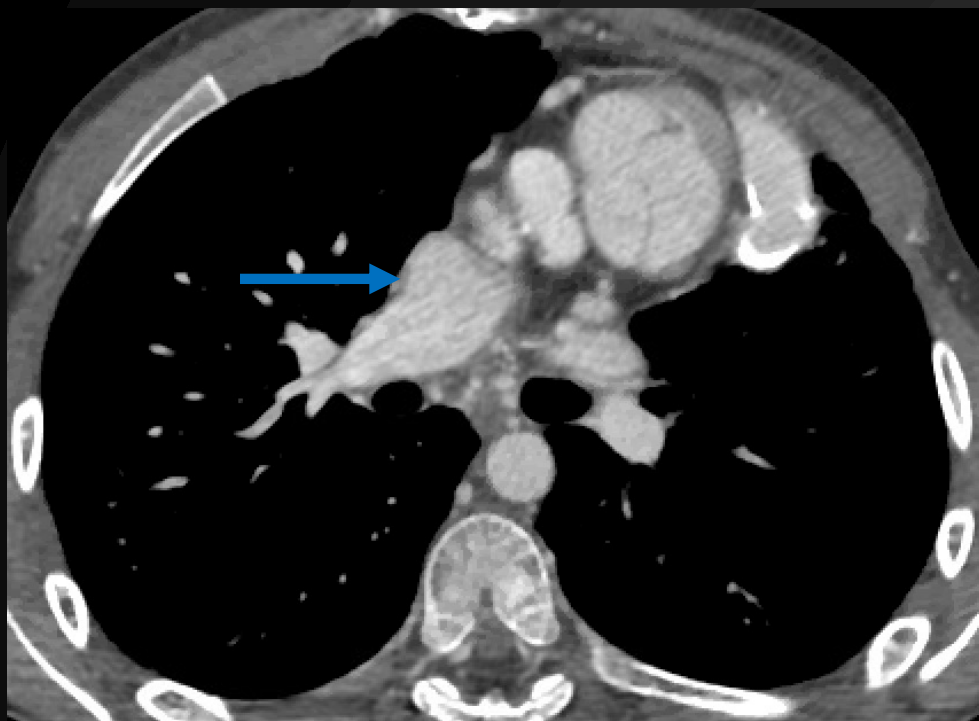
Montages chirurgicaux



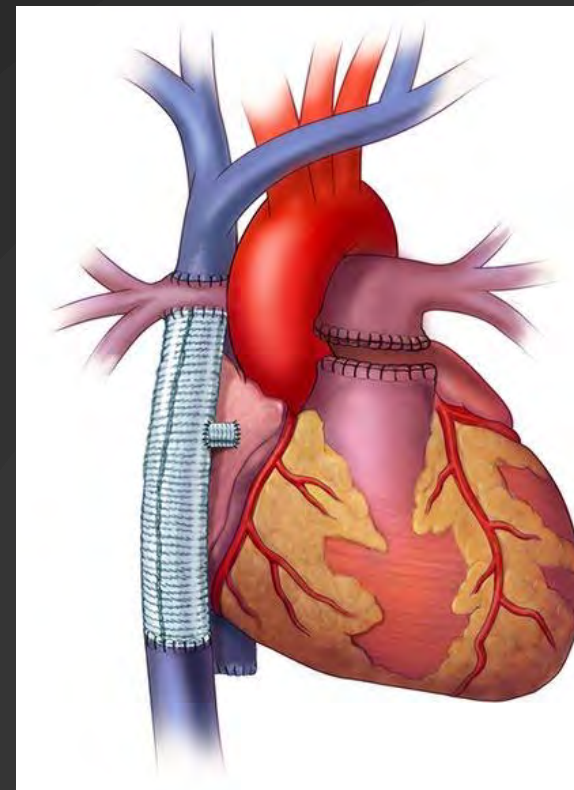
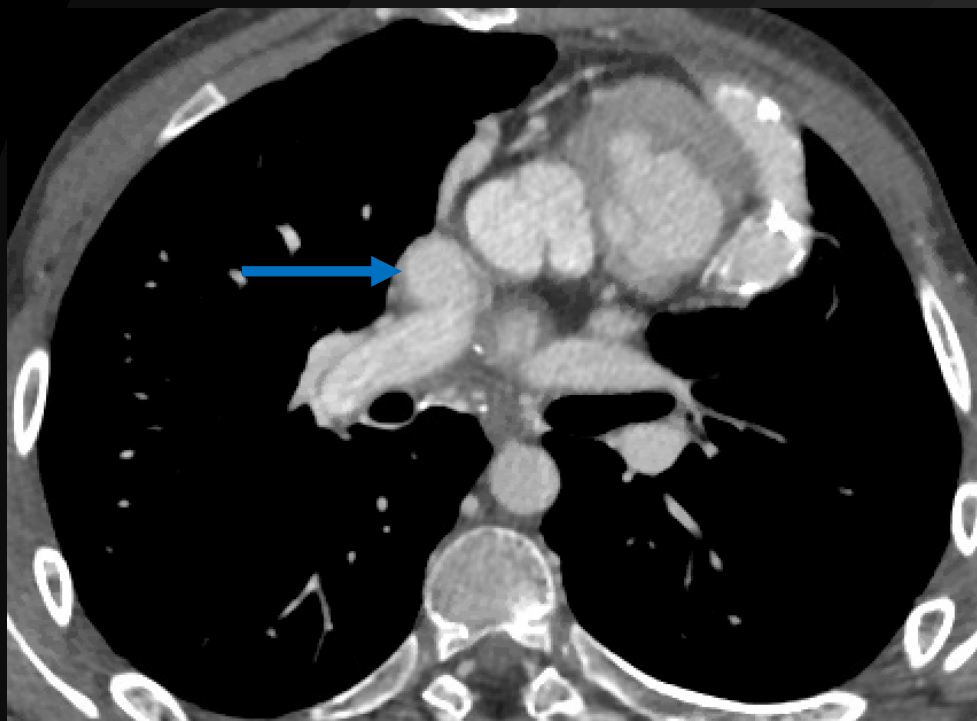
Montages chirurgicaux



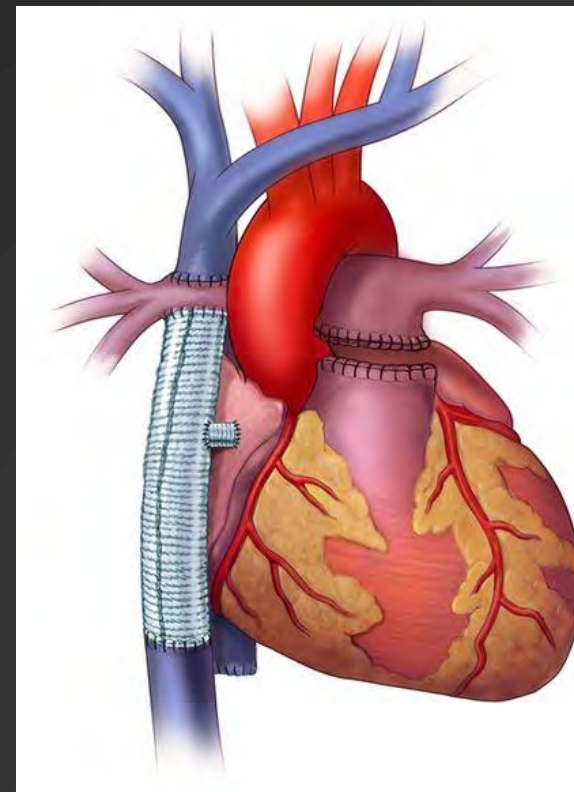
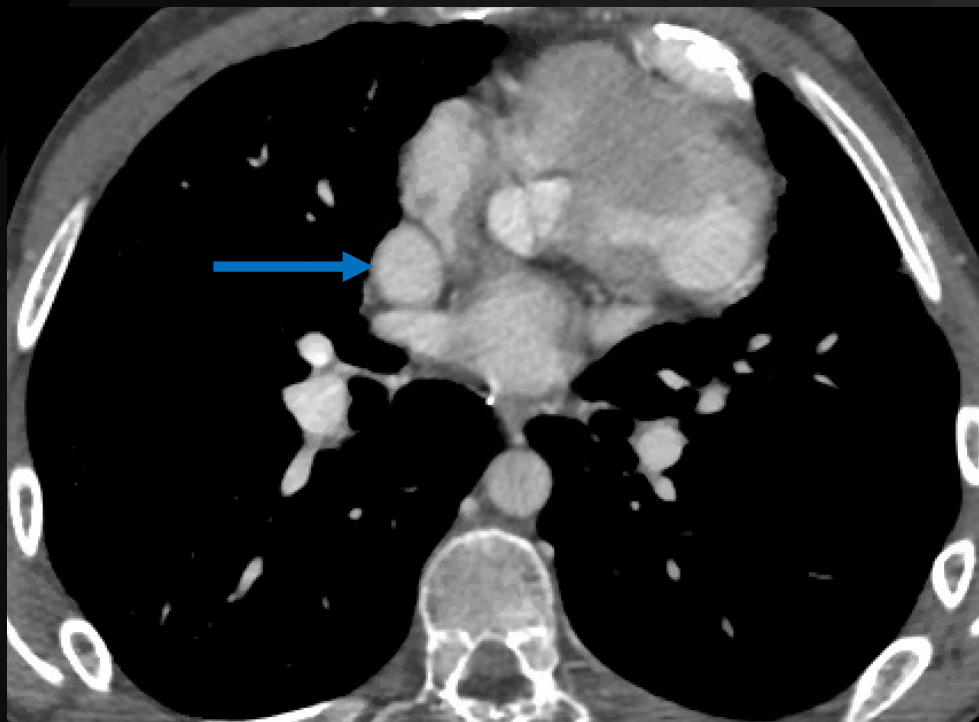
Montages chirurgicaux



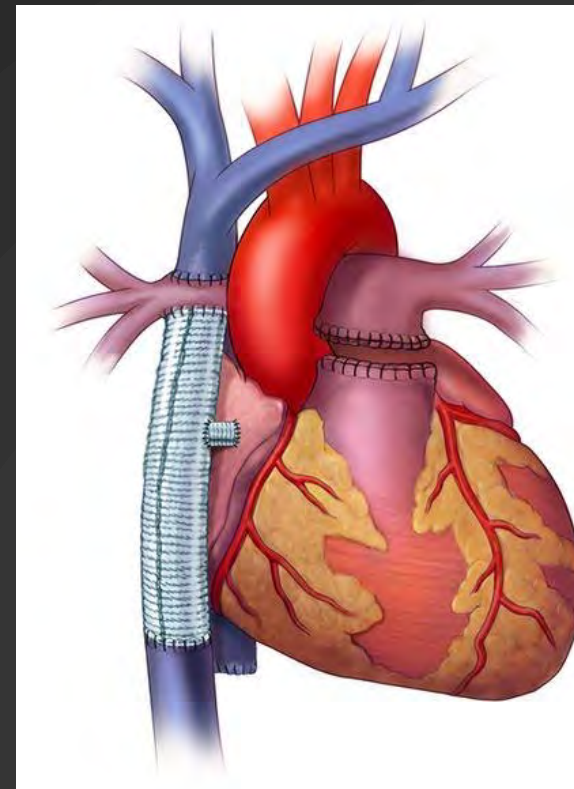
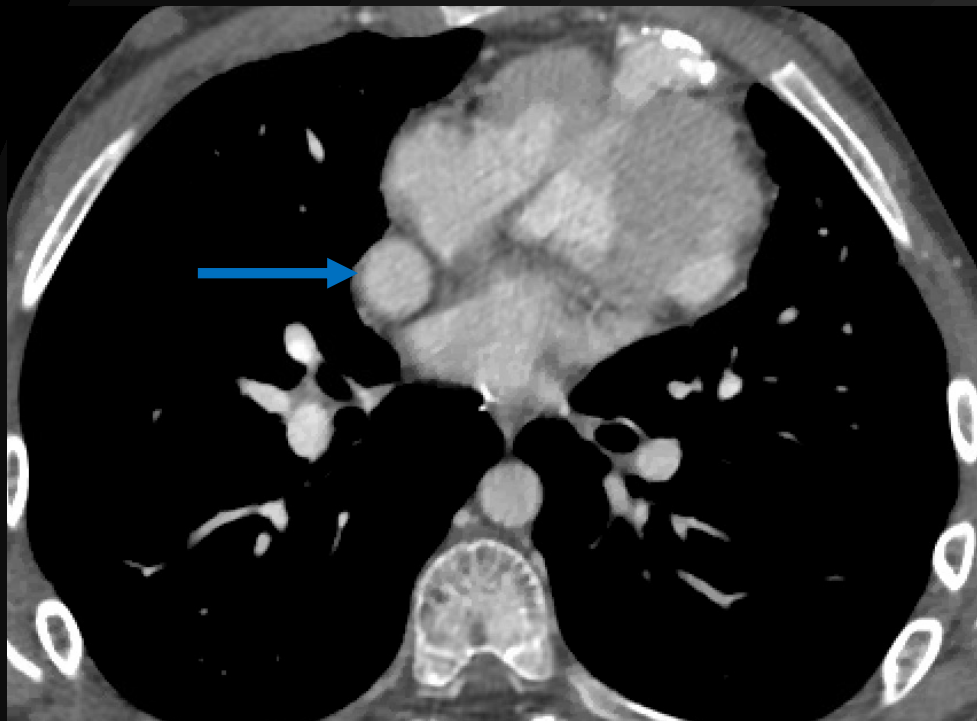
Montages chirurgicaux



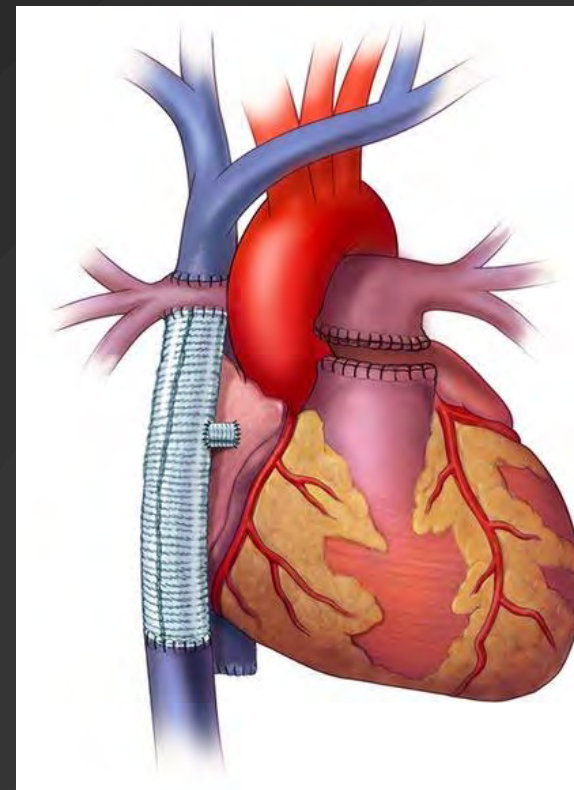
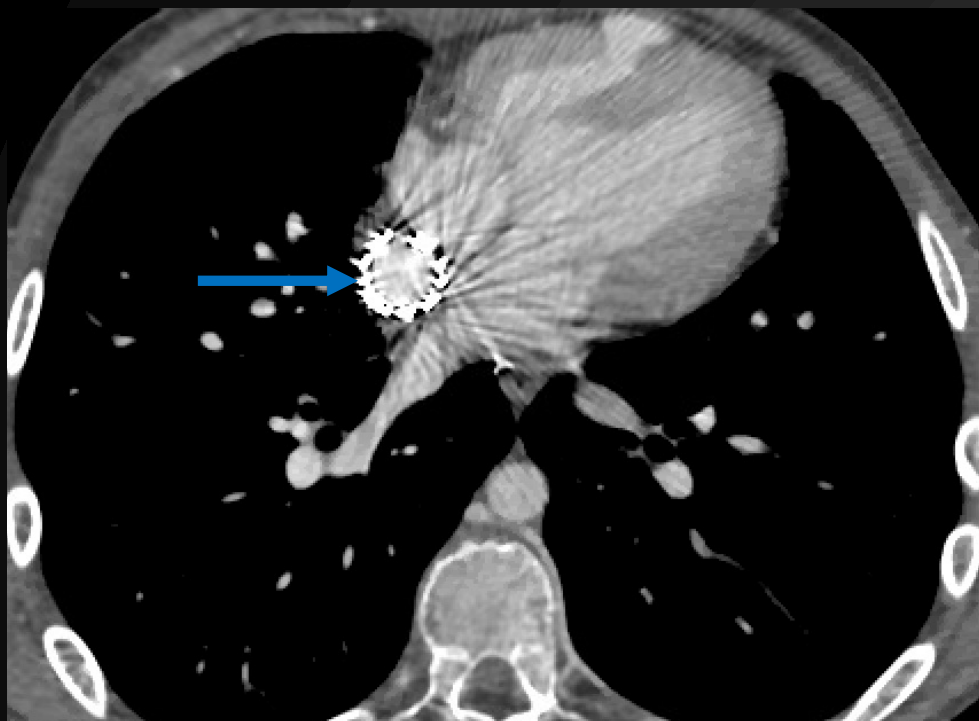
Montages chirurgicaux



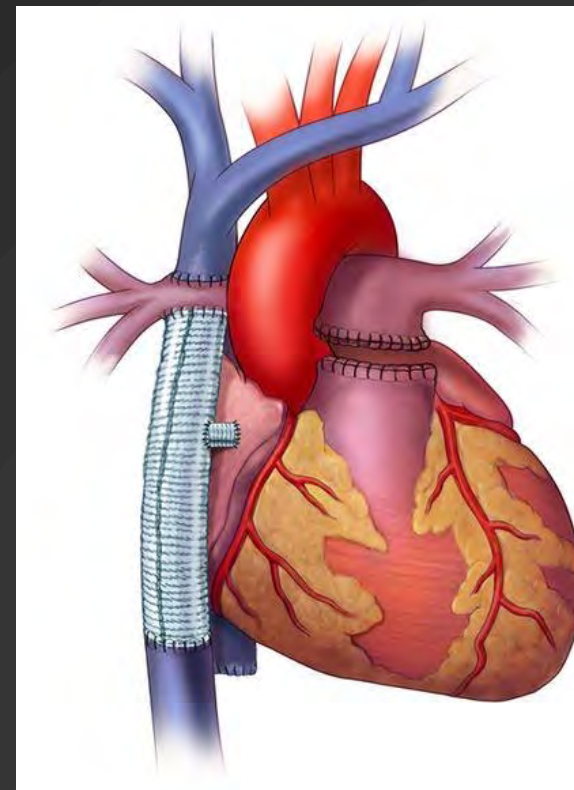
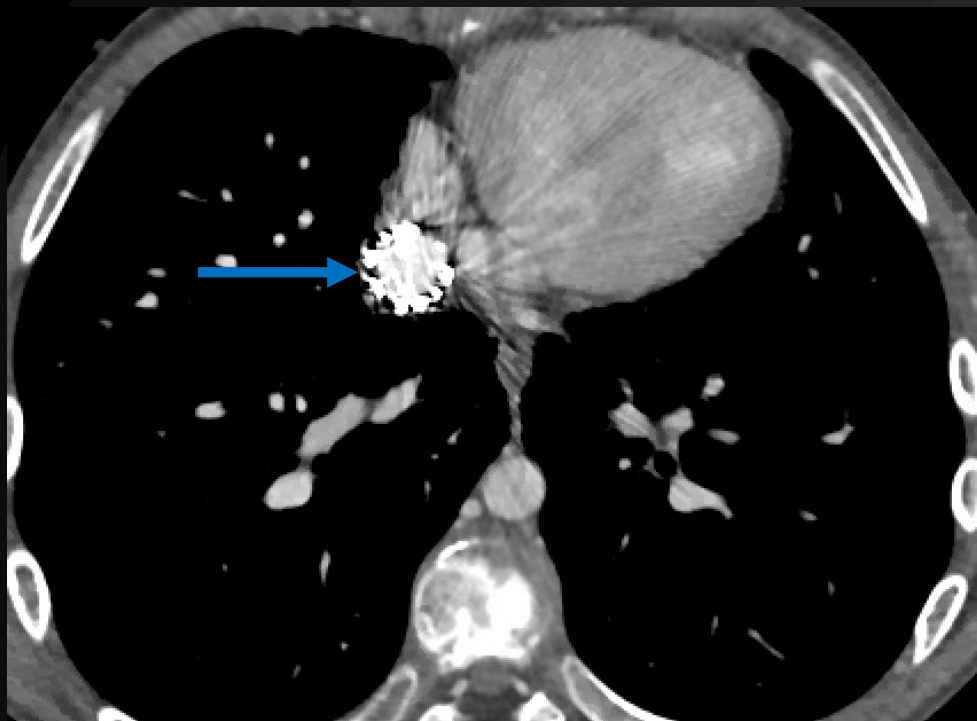
Montages chirurgicaux



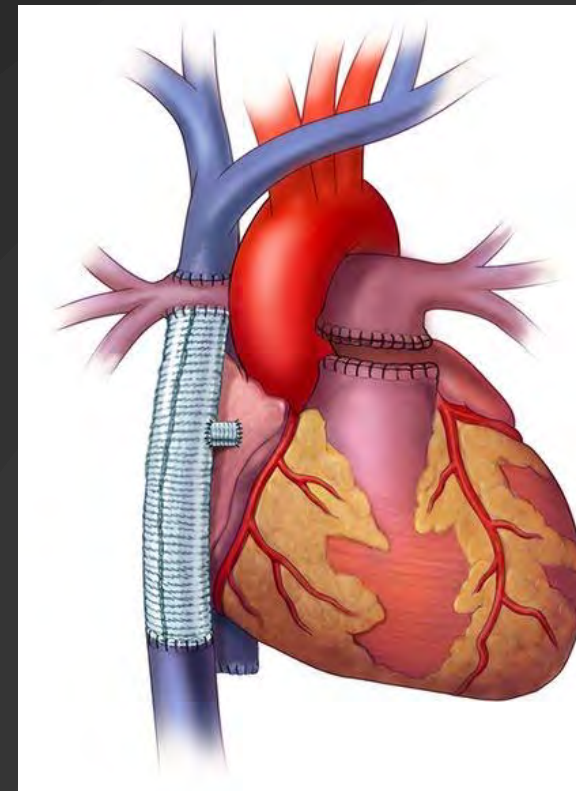
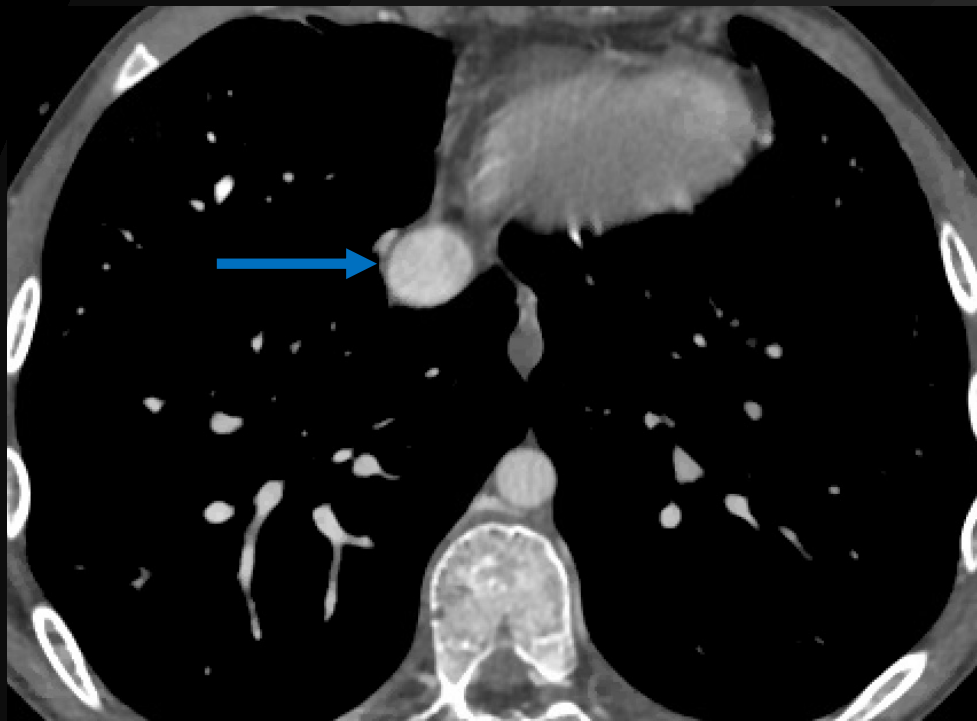
Montages chirurgicaux



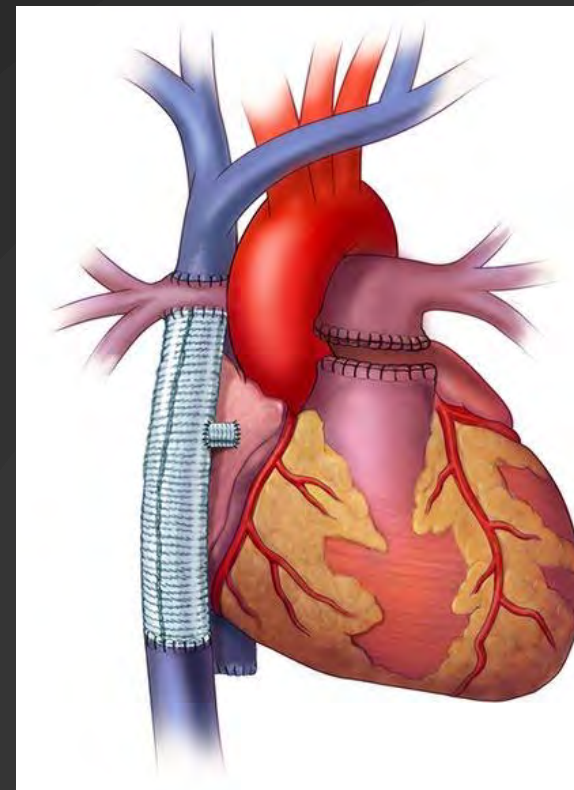
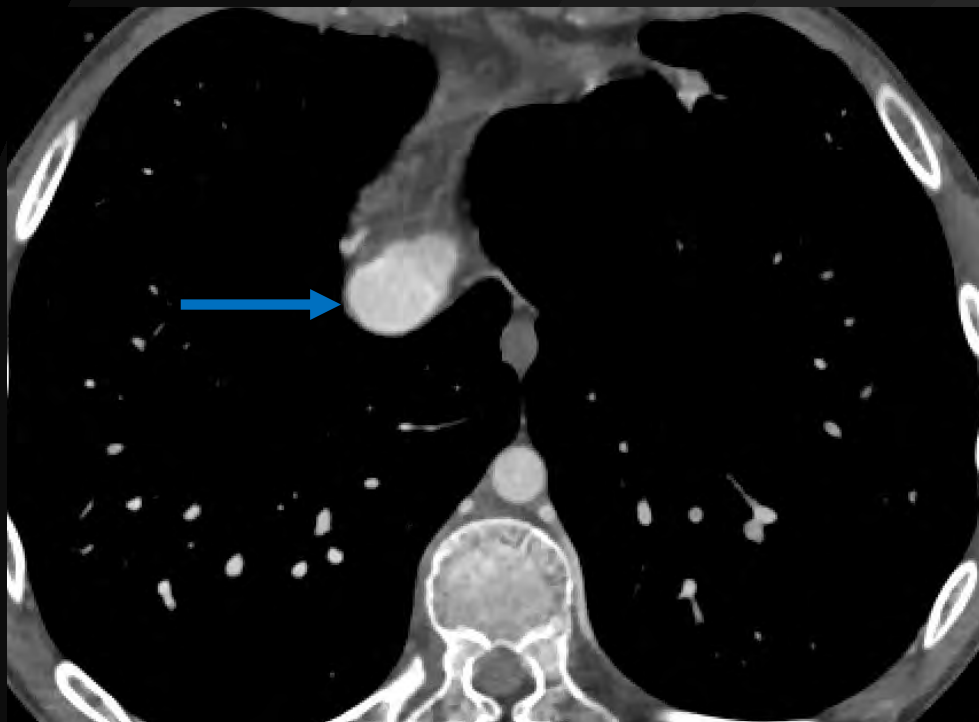Montages chirurgicaux



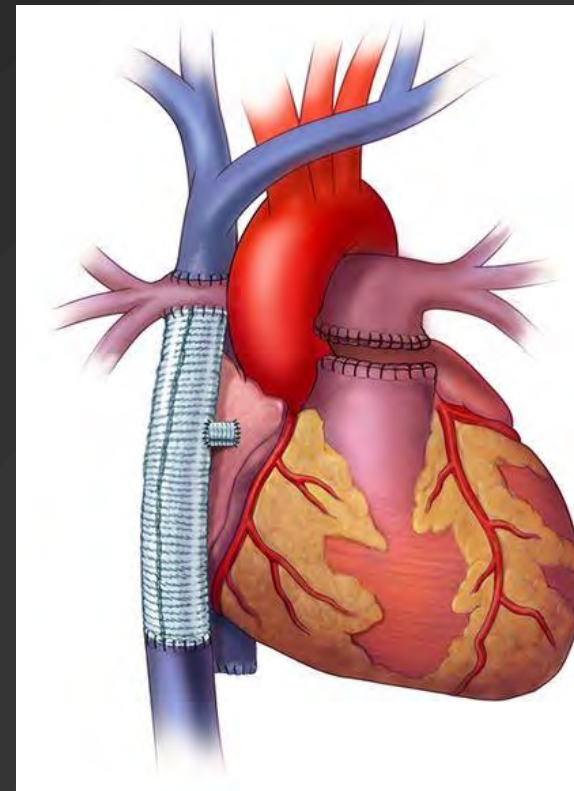
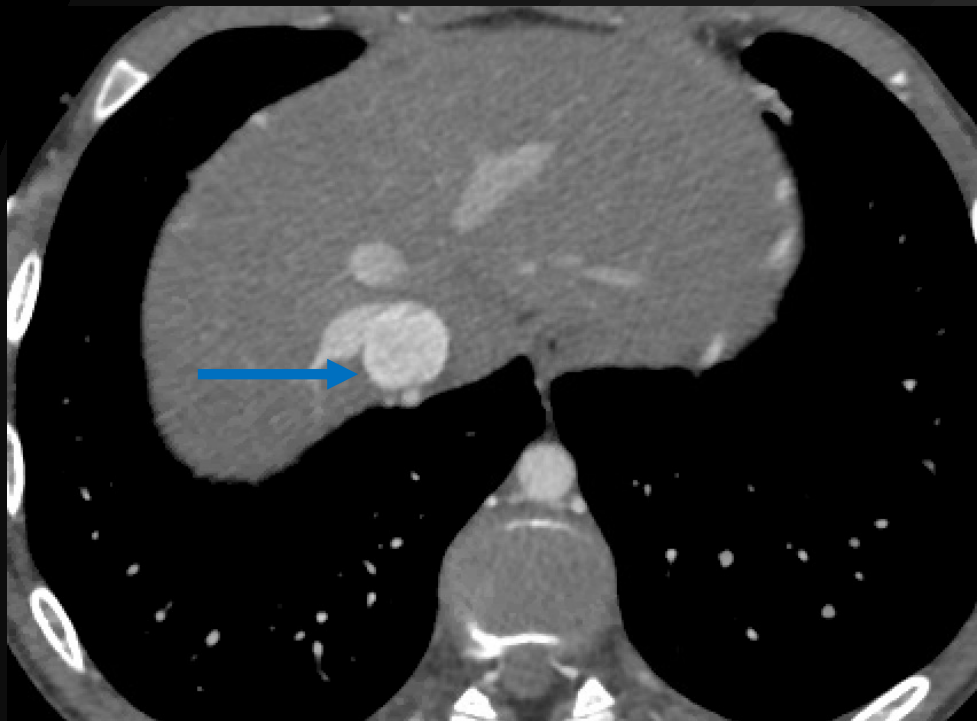Montages chirurgicaux



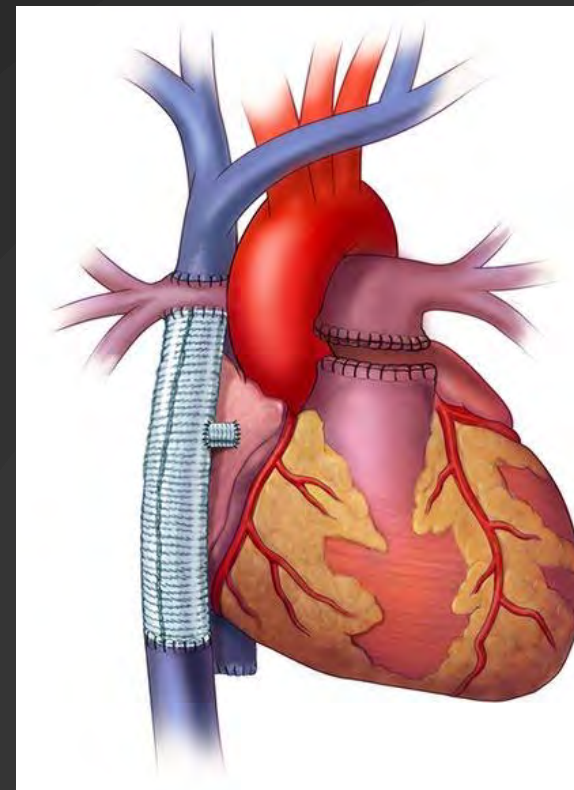
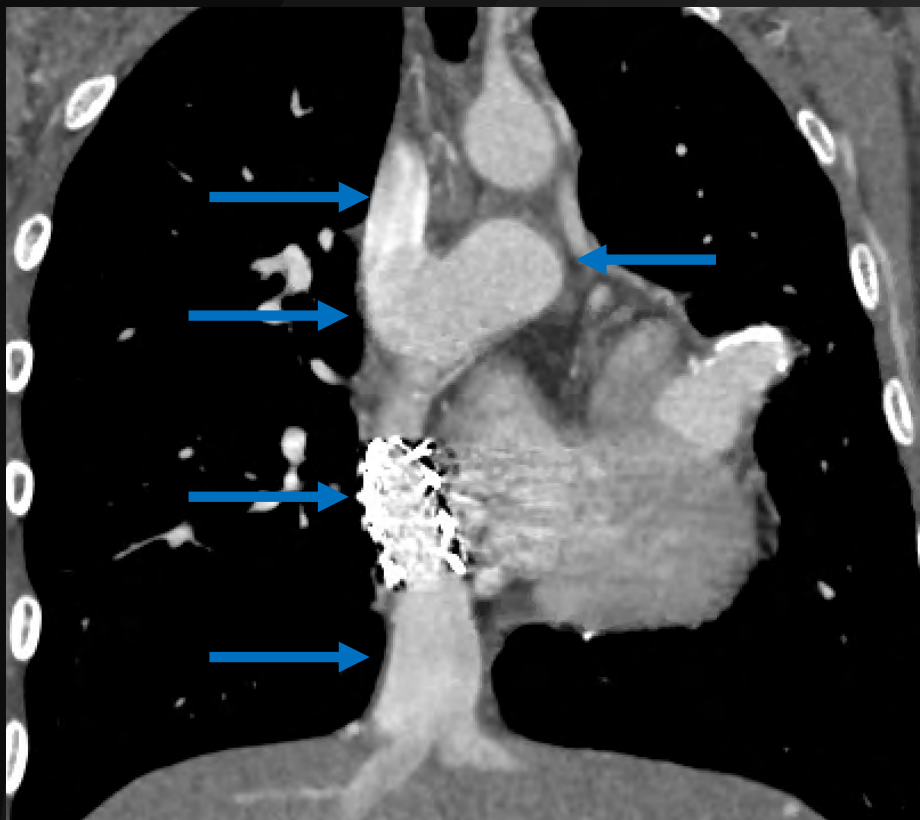
Montages chirurgicaux



Montages chirurgicaux



Montages chirurgicaux



Conclusion



Conclusion

- Scanner cardiaque, angioscanner, coroscanner
 - Accessible (en théorie...)
 - Performant pour l'analyse morphologique
 - Pré-requis:
 - Enfant calme (+/- sédaté)
 - Perfusion de bon calibre
 - Apnée si possible
 - Temps d'analyse
 - Collaboration radiologue / pédiatre-cardiologue