CHIRURGIE CARDIAQUE CONGENITALE

DU de cardiologie pédiatrique
Vendredi 20 Janvier 2023
Dr Margaux Pontailler

Sommaire

- Généralités
- Techniques chirurgicales
- Spécificités des GUCH
- Assistance circulatoire
- Transplantation



Background 1
Why early primary repair? 3
Surgical technique 13
Biomaterials for congenital cardiac surgery 28
Anesthesia for congenital heart surgery *James A. DiNardo* 45
Pediatric cardiac intensive care *Peter C. Laussen* 65

Cardiopulmonary bypass 113
The bypass circuit: hardware options *Robert Howe, Robert Fullerton and Gregory Mehr* 118
Prime constituents and hemodilution 136
Carbon dioxide, pH and oxygen management 151
Hypothermia, reduced flow and circulatory arrest 161
Myocardial protection 175

Specific congenital cardiac anomalies 186
Patent ductus arteriosus, aortopulmonary window, sinus of Valsalva fistula, aortoventricular tunnel 187
Coarctation of the aorta 207
Atrial septal defect 225
Ventricular septal defect 242
Transposition of the great arteries 258
Tetralogy of Fallot with pulmonary stenosis 279
Valve surgery 301
Left ventricular outflow tract obstruction: aortic valve stenosis, subaortic stenosis, supravalvular aortic stenosis 320
Hypoplastic left heart syndrome 341
Single ventricle 367
Complete atrioventricular canal 386
Anomalies of the pulmonary veins 402
Double outlet right ventricle 419
Truncus arteriosus 429
Tetralogy of Fallot with pulmonary atresia 440
Pulmonary atresia with intact ventricular septum 457
Interrupted aortic arch 470
Congenitally corrected transposition of the great arteries 483
Vascular rings, slings, and tracheal anomalies 497
Anomalies of the coronary arteries 510

GENERALITES

Voies d'abord

- Deux grandes voies
  - Sternotomie médiane
  - Thoracotomie (droite ou gauche)
- Avantages / inconvénients
  - Types de cardiopathie / chirurgie
  - Exposition
  - Douleur
  - Esthétique

Installation

- Installation décubitus dorsal, billot sous les épaules
- Intubation oro ou naso trachéale
- Scope, saturomètre
- 1 à 2 VVP
- KTA
- KTC
- Sonde urinaire
- Sonde thermique
- Plaque de BE
- Plaques de défibrillateur externe si redux

Tout cela sur 0.2 m² de surface corporelle
=
Protection points d'appui

Sternotomie

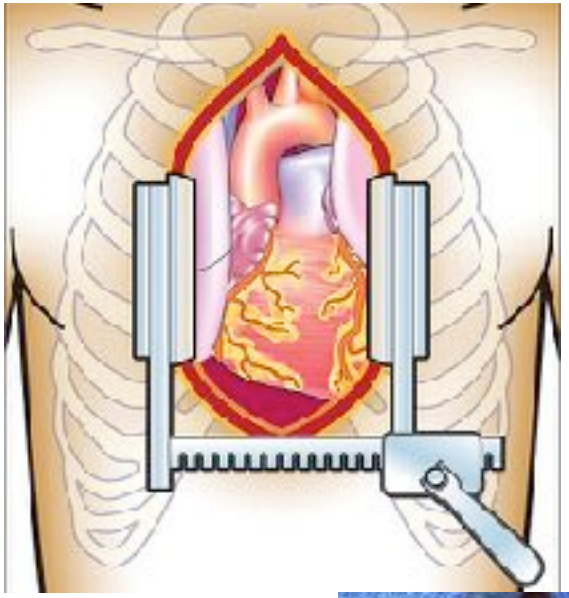

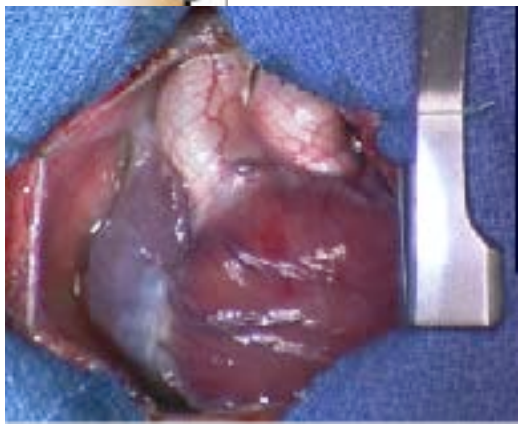

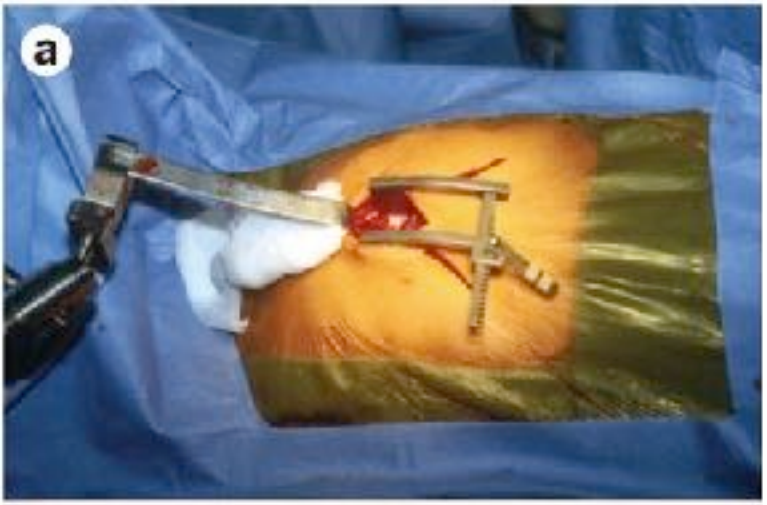
a

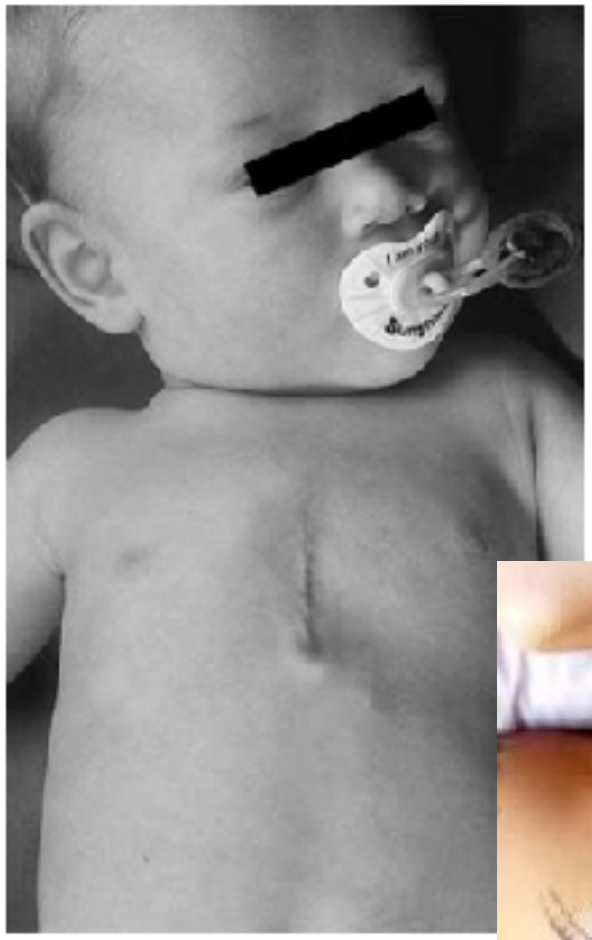

c

Thoracotomie

- Techniquage idem
- Installation en décubitus latéral D/G
- Main sur la tête
- Jambes en PLS
- Billot sous les côtes
- Protection points d’appui +++

Thoracotomie

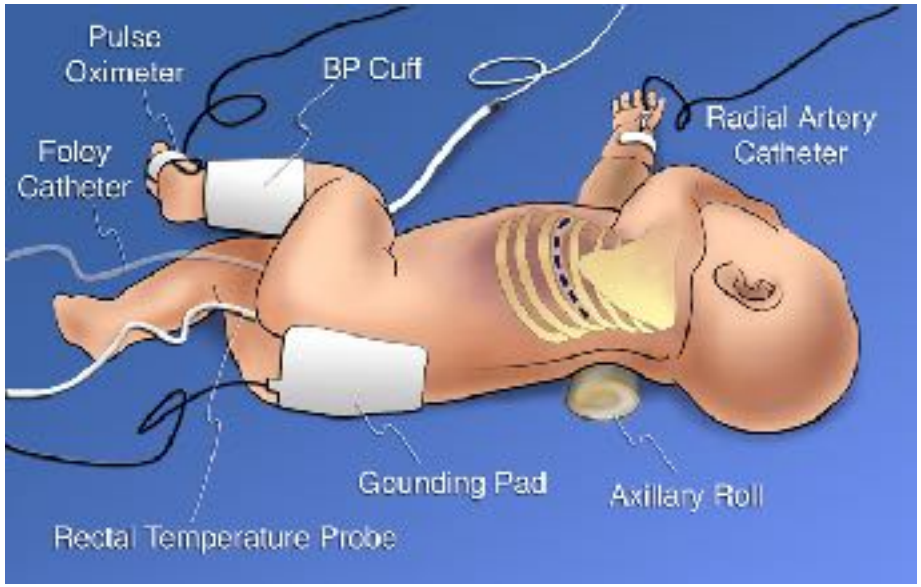

Chirurgie mini invasive

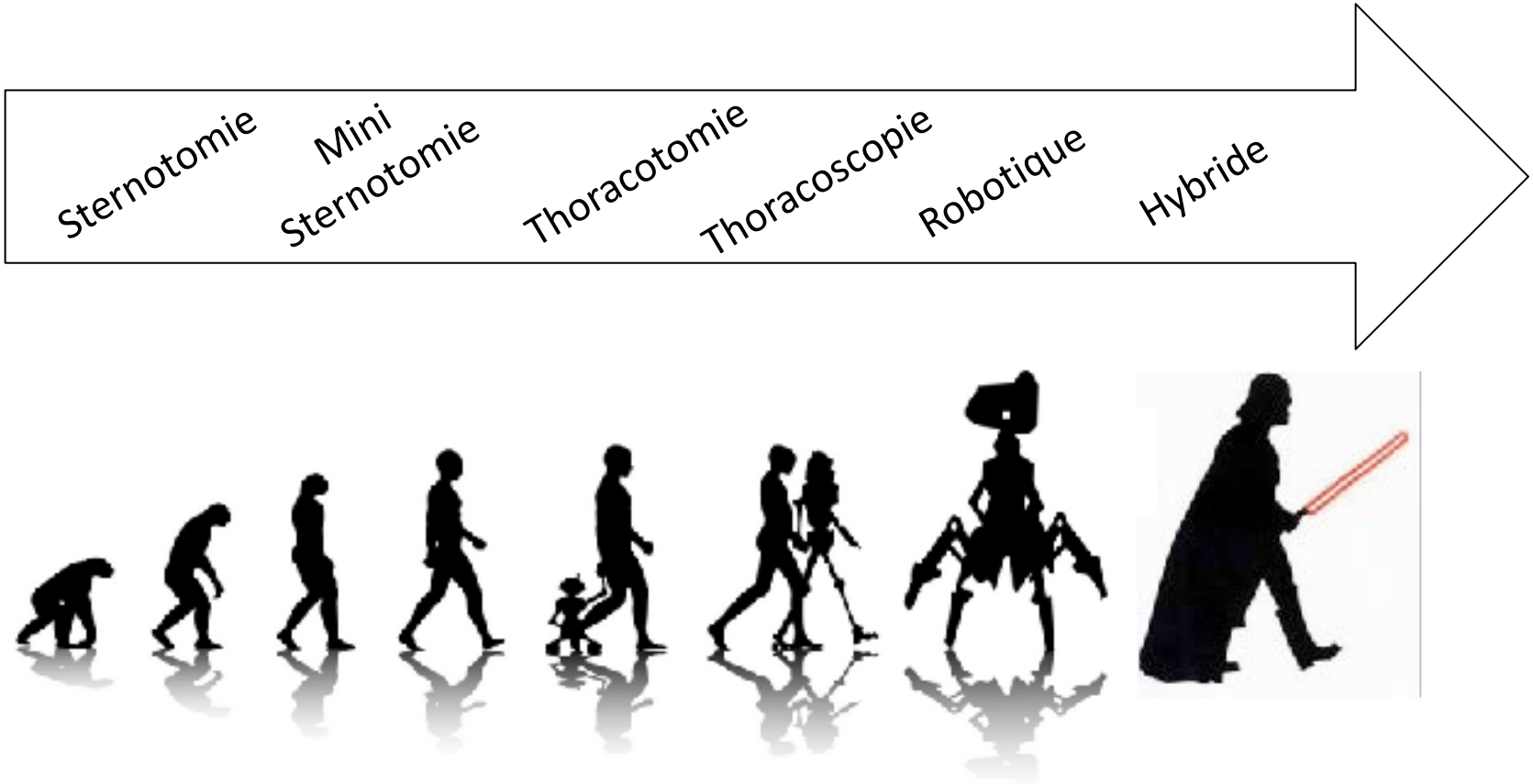

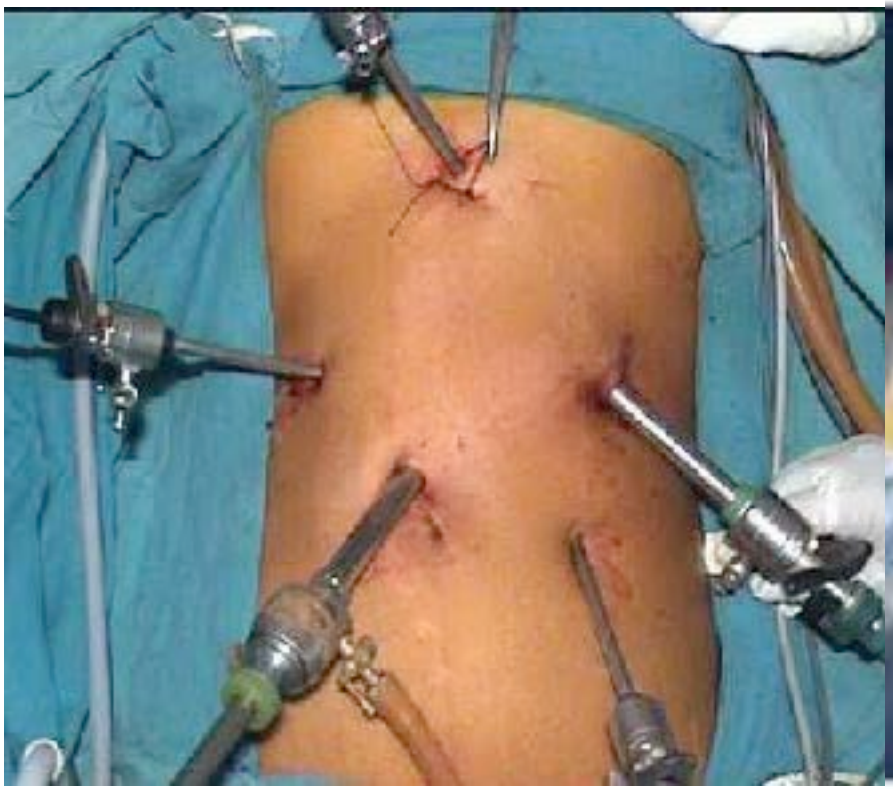

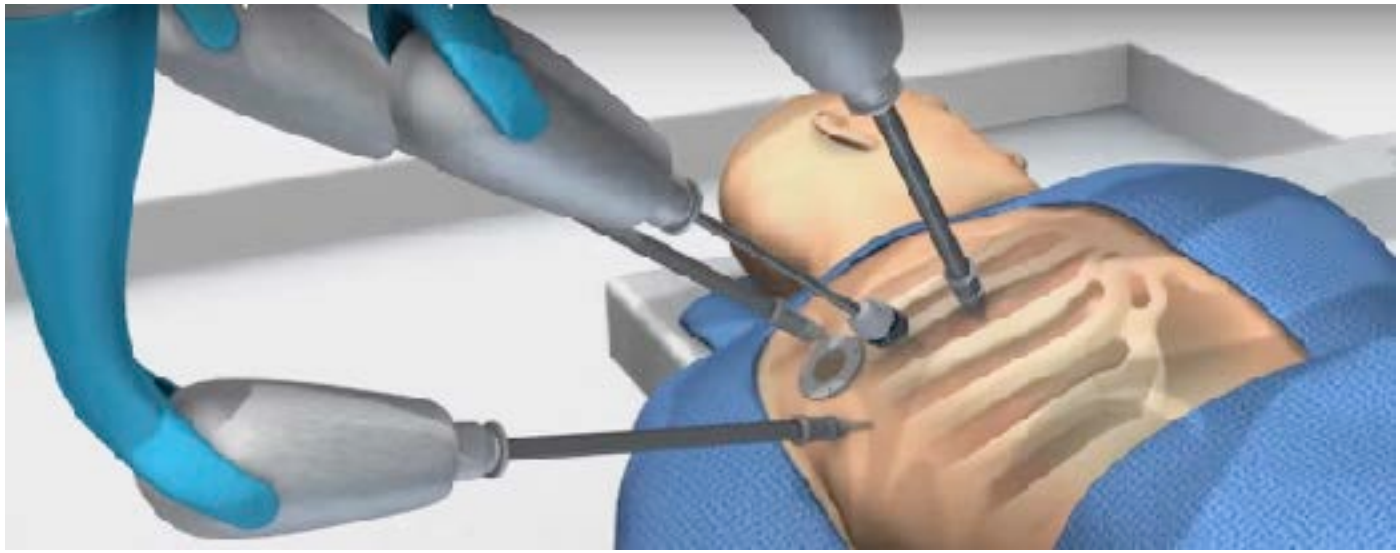

Principes de la chirurgie

Cœur fermé

versus

Cœur ouvert

Cure complète

Versus

Chirurgie palliative

Chirurgie palliative

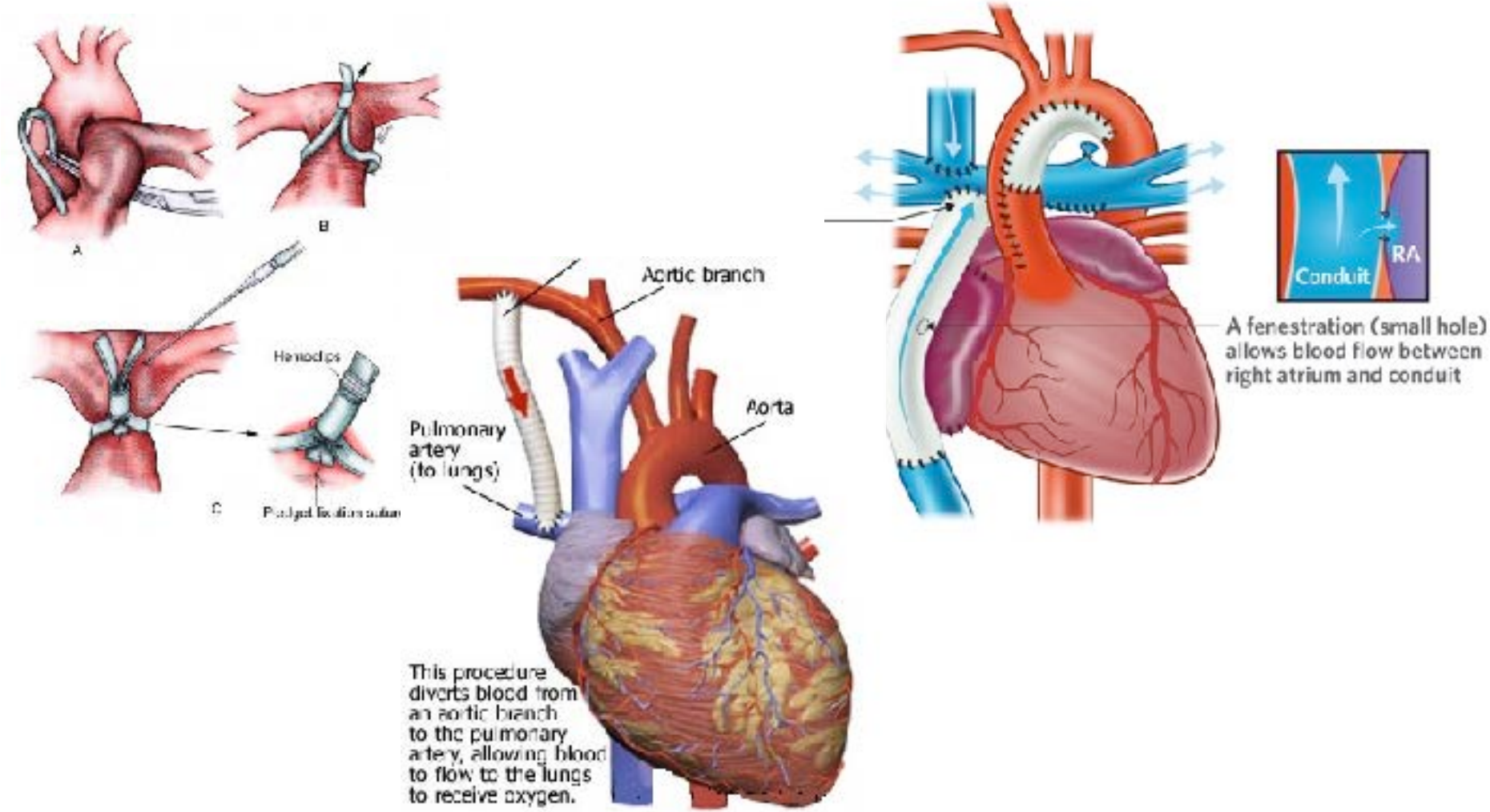

Cœur fermé : Pas de CEC

- Canal artériel
- Coarctation
- Pacemaker, défibrillateur
- Anastomose systémico-pulmonaire (Blalock)
- Anomalies arcs aortiques

Cœur ouvert = CEC

- Principes de la CEC
  - Assurer rôle du cœur
  - Assurer rôle du poumon
  - Visibilité des lésions
- Canules
  - Drainage
  - Réinjection
- Circuit
  - Réservoir
  - Filtre
  - Pompe
  - Oxygénateur
  - Echangeur thermique

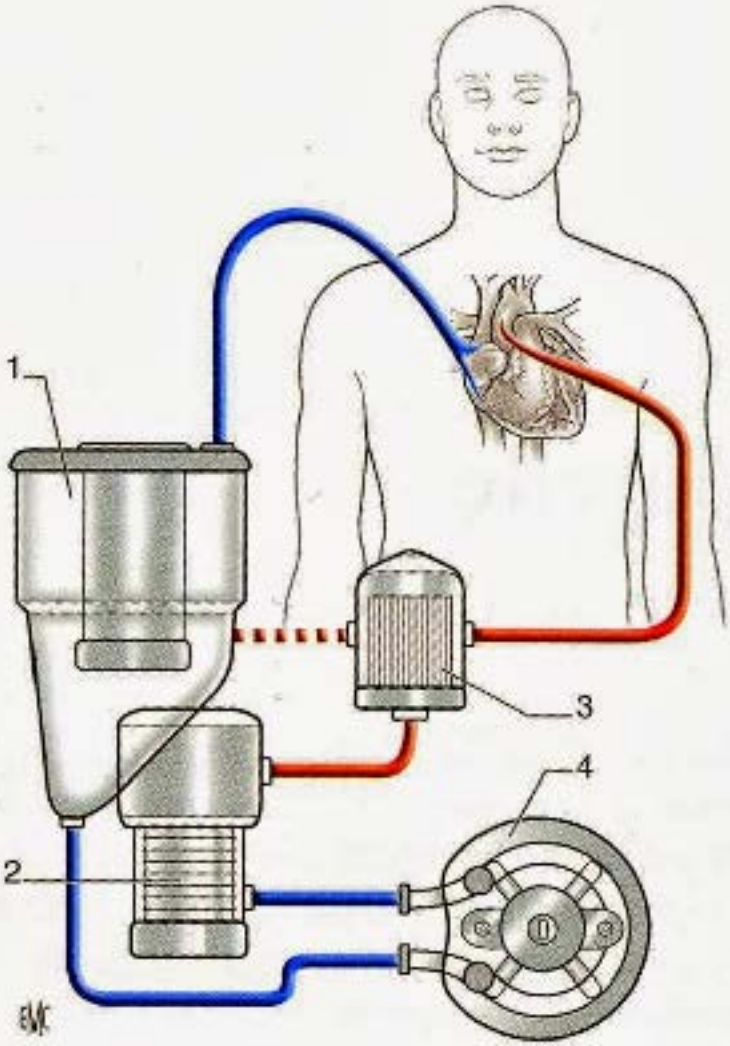

Figure 1. Circuit classique de circulation extracorporelle. 1. Réservoir de cardiotomie ; 2. oxygénateur ; 3. filtre artériel ; 4. pompe à galets.

Pompiste = contrôleur aérien

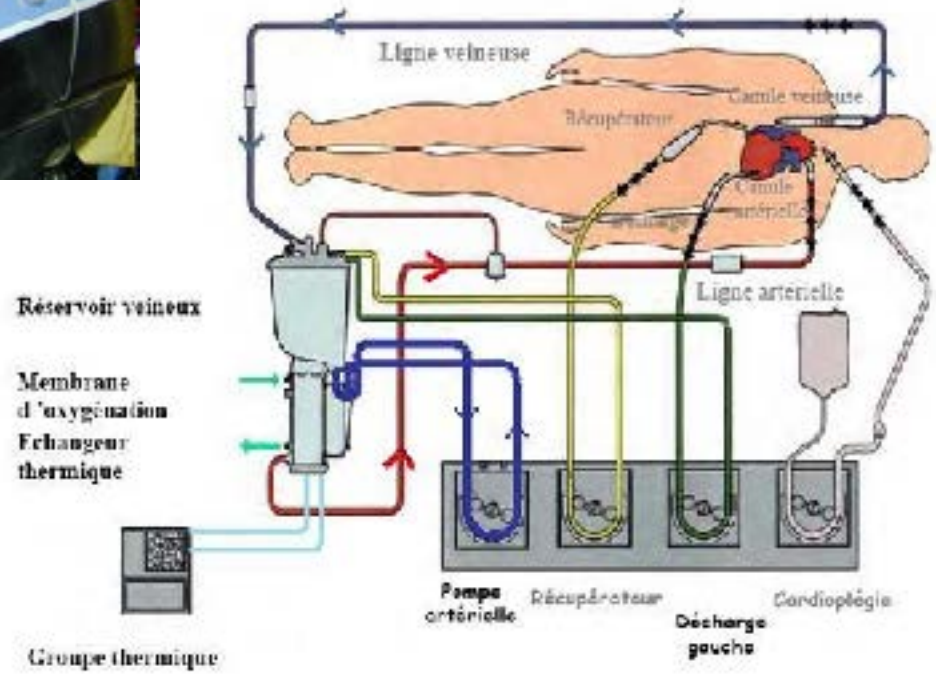

Canulation

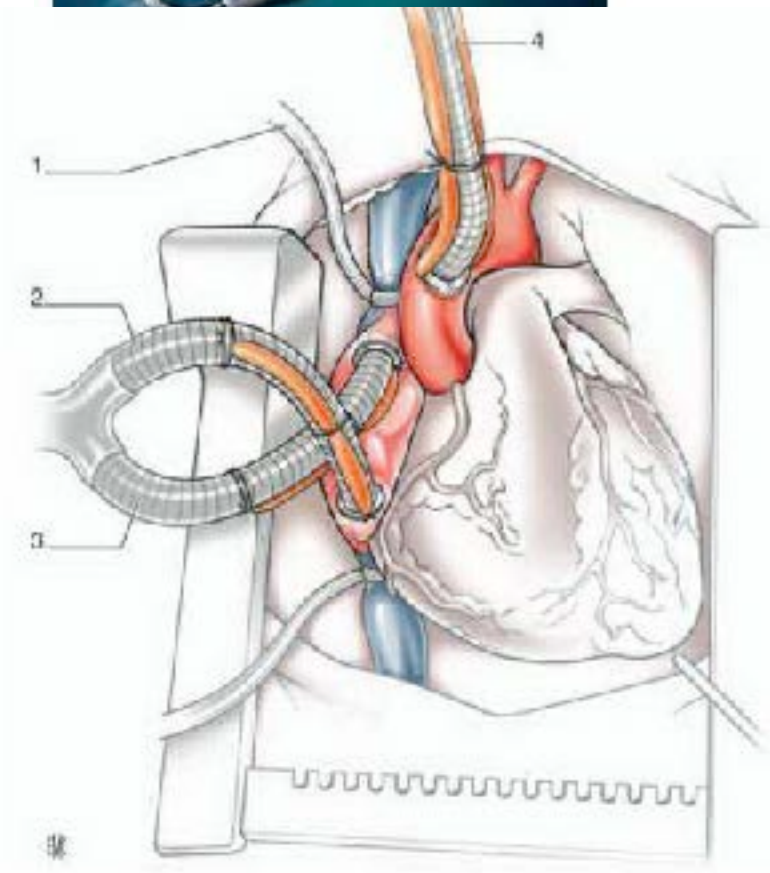

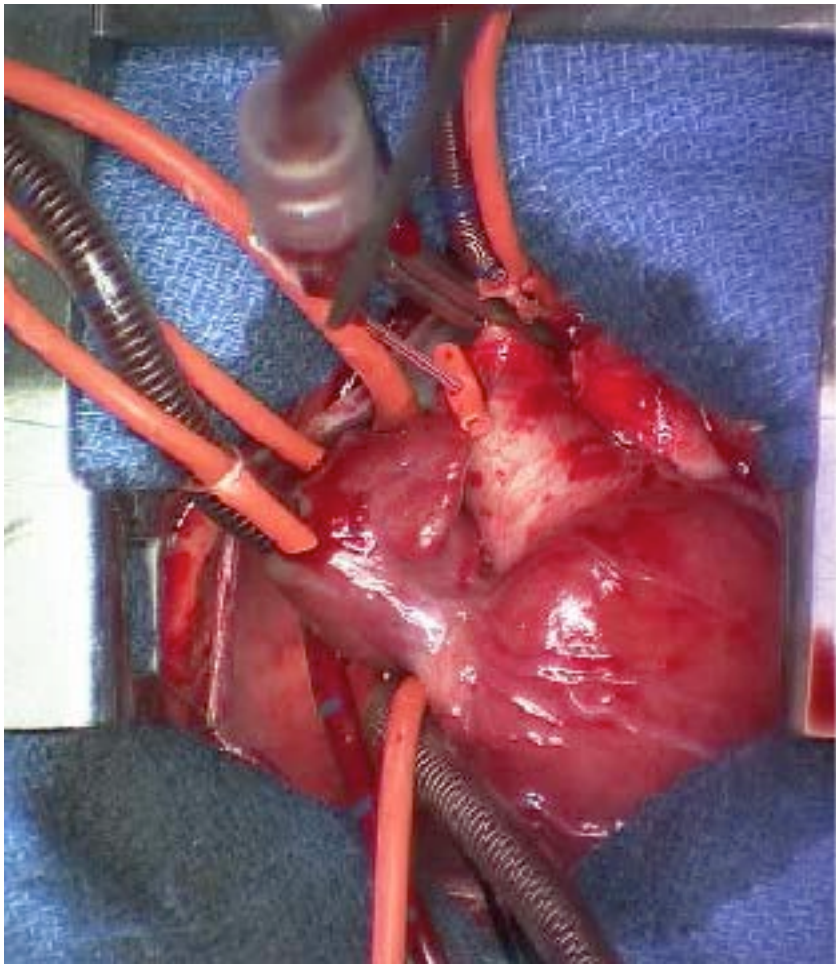

Canulation

- Canule artérielle
  - Distalité Ao ascendante : réinjection
- Canule(s) veineuse(s)
  - OD ou 2 veines caves : drainage
- +/- Canule de décharge gauche
  - OG : drainage
- +/- Canule de cardioplégie

Cardioplégie

- Arrêter le cœur
- Perfuser le coeur

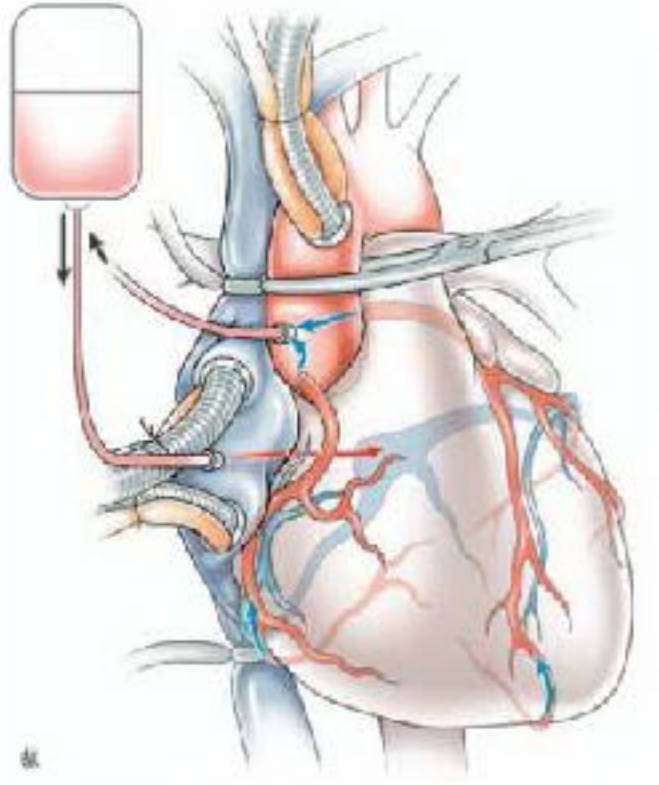

Cristalloïde / Sanguine
Chaude / Froide
Unique / Répétée / Continue
Antérograde / Rétrograde / Combinée

Normo ou hypothermie

- Normothermie
- Hypothermie modérée
- Hypothermie profonde
- Arrêt circulatoire
- Perfusion cérébrale sélective

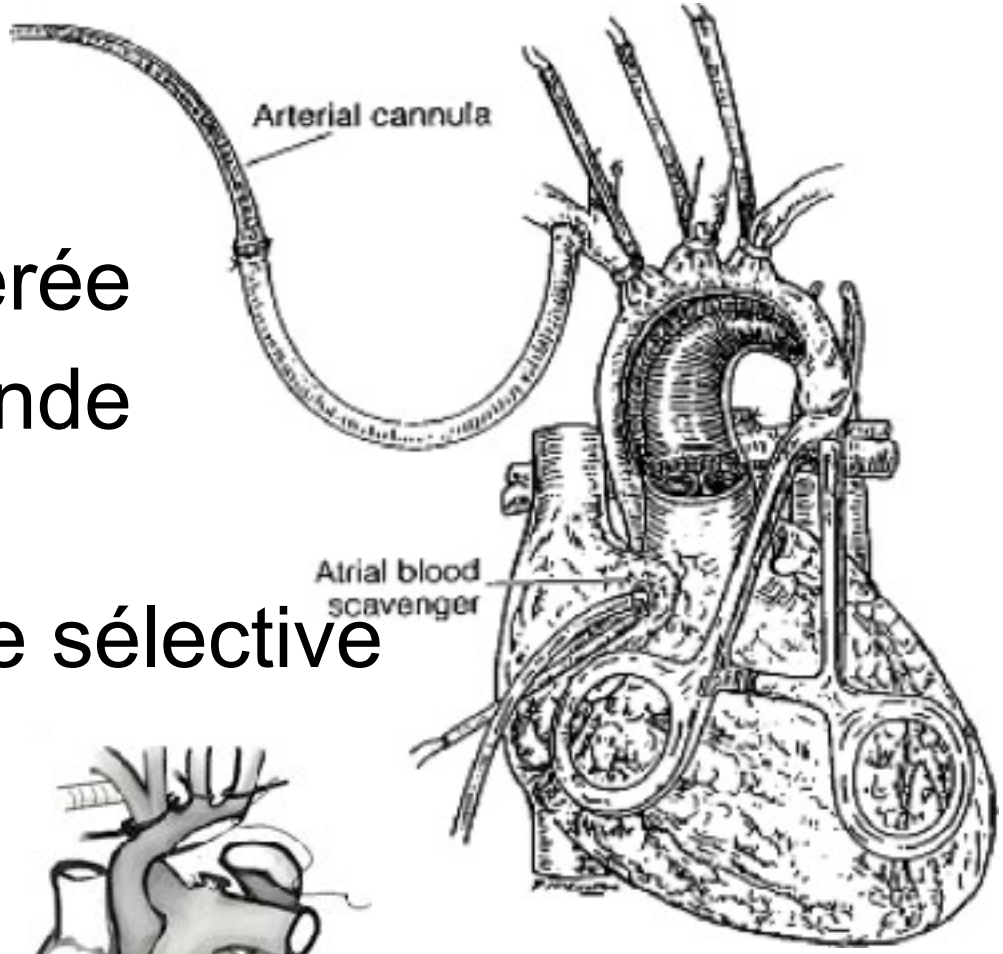

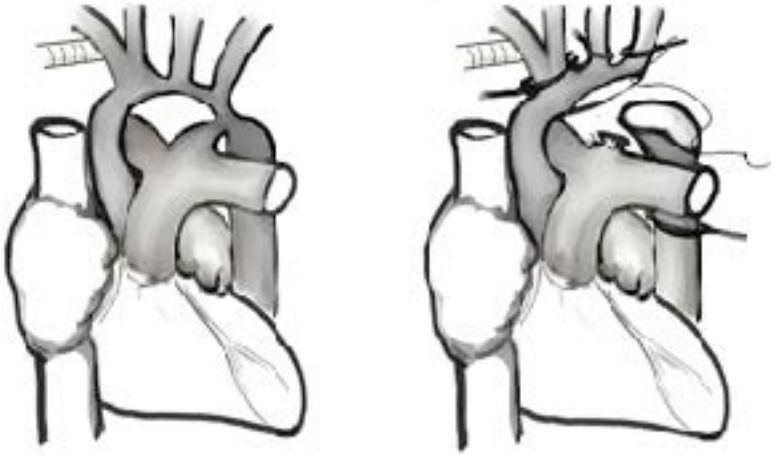

Risques de la CEC

- Hémodilution
  - Priming
  - Transfusion
- Inflammation
  - Durée de CEC
  - Matériel
- Ischémie myocardique
  - Cardioplégie
  - Temps de clampage
- Problème technique
  - Décanulation
  - Bullage



Déroulement de l'intervention

Sternotomie

Thymectomie

Canulation CEC

Clampage

Chirurgie

Déclampage

Sevrage CEC

Hémostase

Fermeture

Canulation en chirurgie cardiaque

Patchs

Bovine or Porcine
Pericardium
Easy to suture
Improved handling and suturability
compared to synthetic patches
Thinner patch available
for pediatric surgery
Flexible and
durable

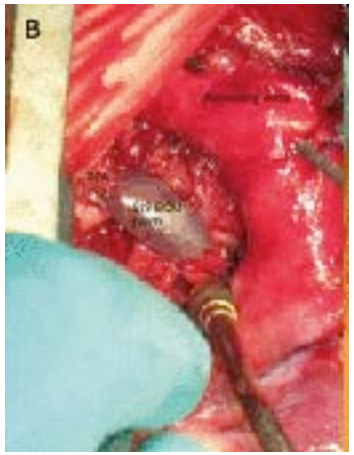
B

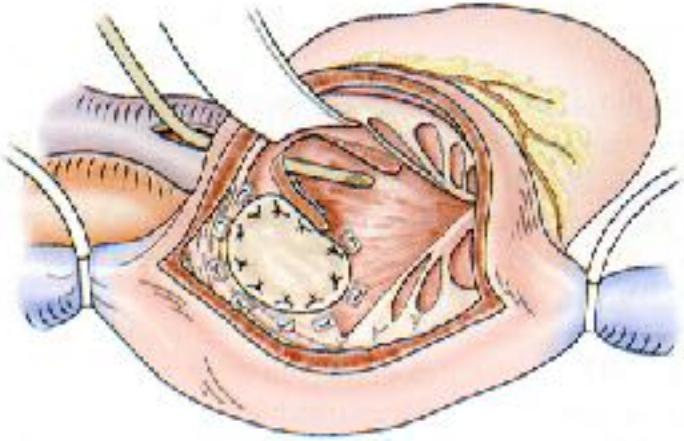

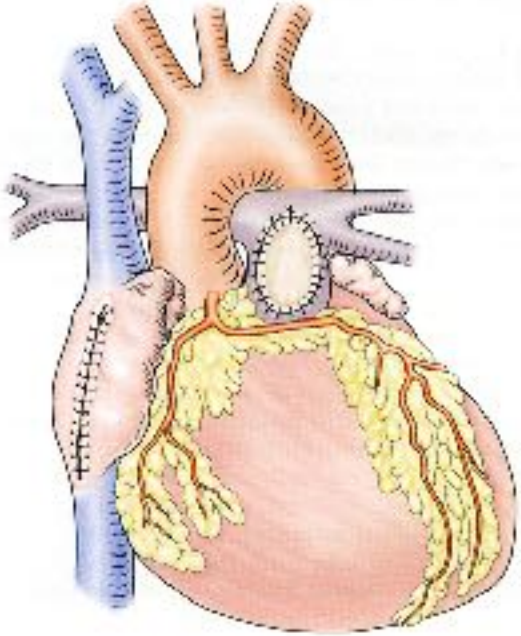

Valves

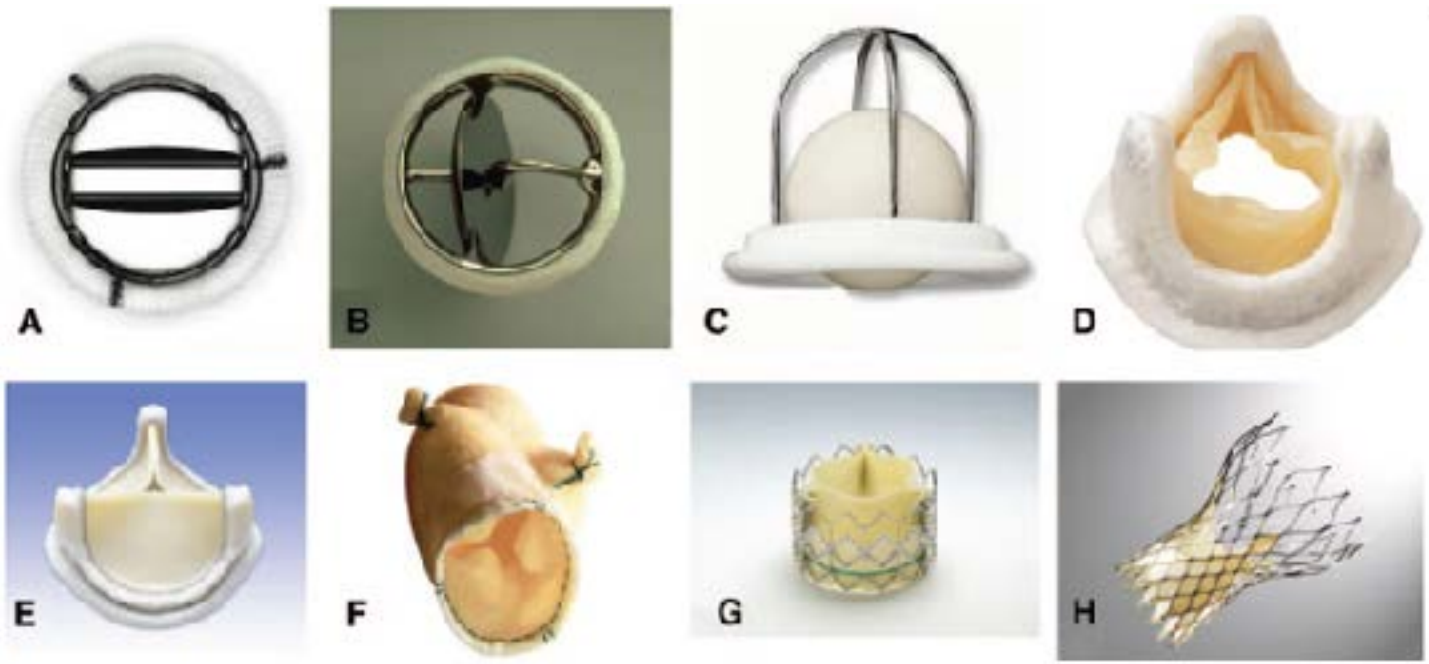

Figure 1. Different types of prosthetic valves. A, Bileaflet mechanical valve (St Jude); B, monoleaflet mechanical valve (Medtronic Hall); C, caged ball valve (Starr-Edwards); D, stented porcine bioprosthesis (Medtronic Mosaic); E, stented pericardial bioprosthesis (Carpentier-Edwards Magna); F, stentless porcine bioprosthesis (Medtronic Freestyle); G, percutaneous bioprosthesis expanded over a balloon (Edwards Sapien); H, self-expandable percutaneous bioprosthesis (CoreValve).

- Réparer +++
- Sinon remplacer

Valves

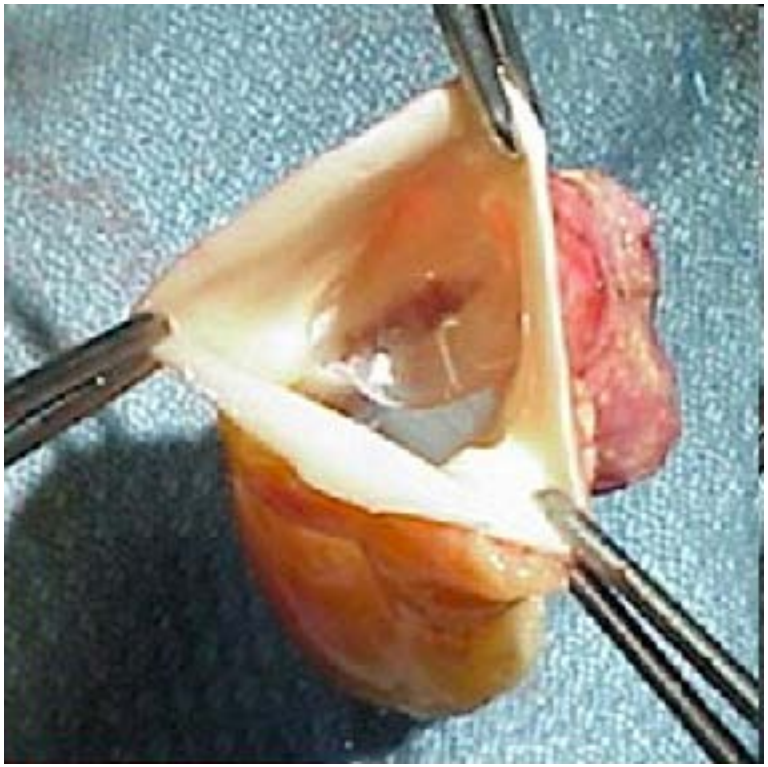

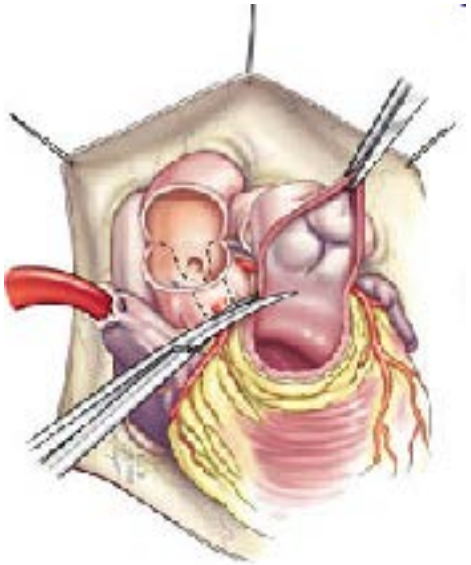

Matériel intra-thoracique

- Electrodes de stimulation
  - Auriculaires, ventriculaires
- Drainage
  - Redon ou drain pleural, médiastinal
- KT transthoracique
  - KT OG, KT AP

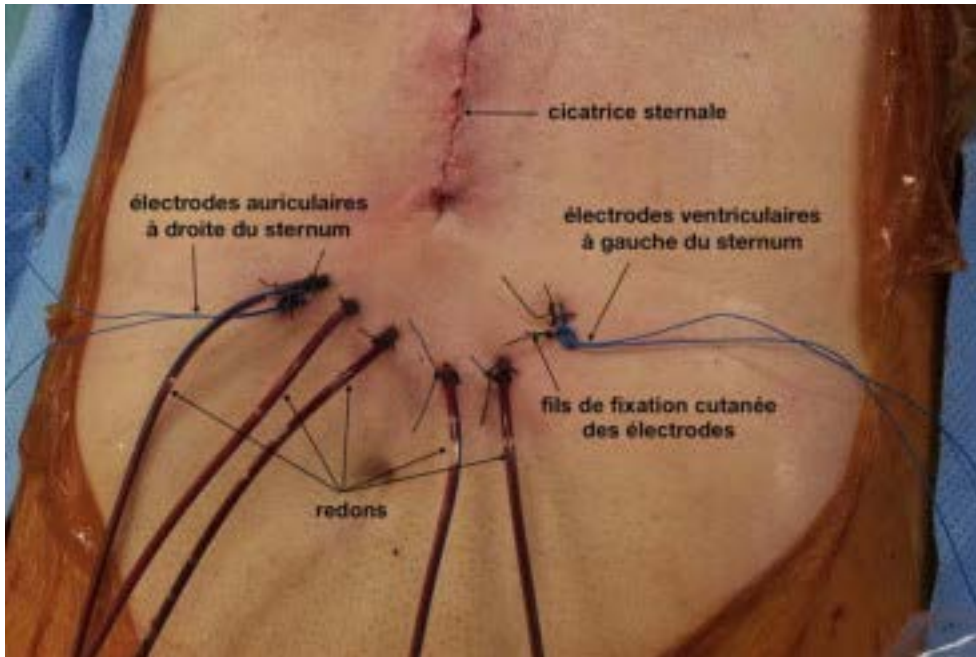

TECHNIQUES CHIRURGICALES

Canal artériel

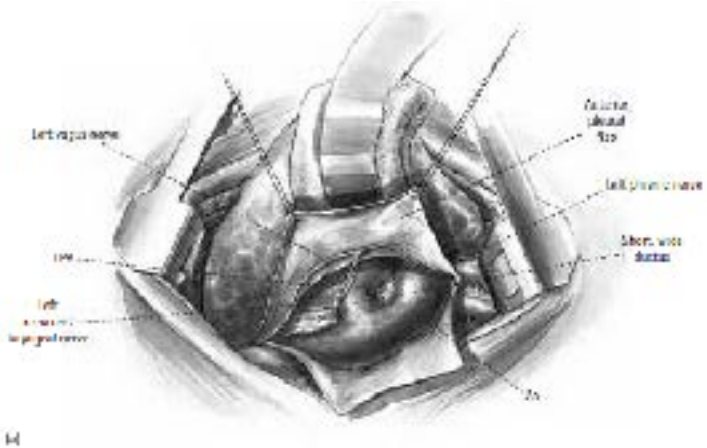

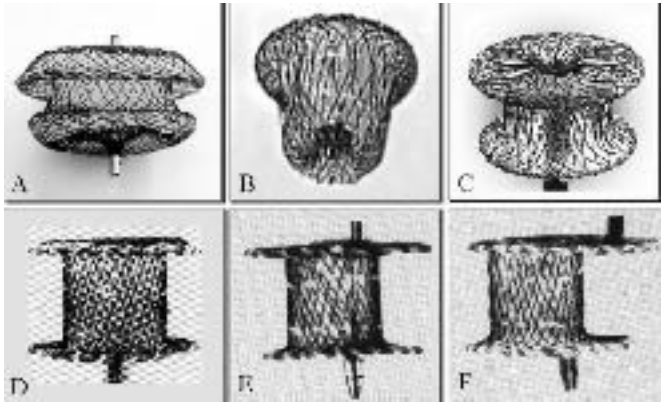

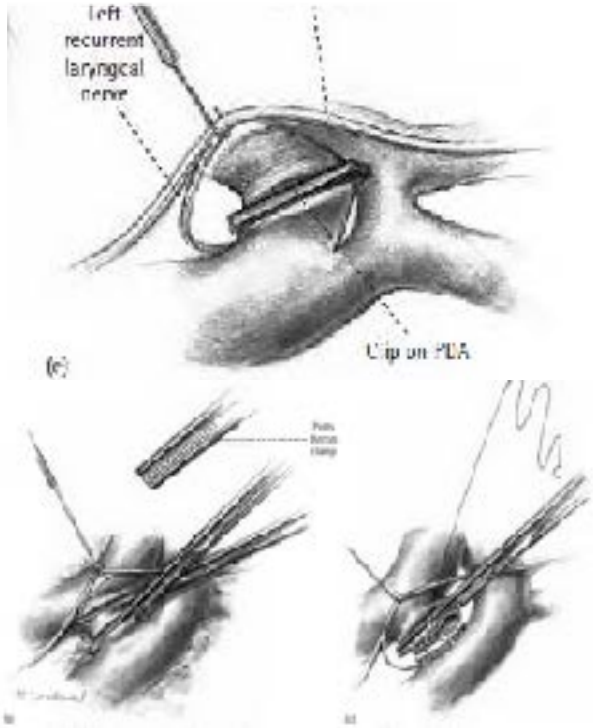

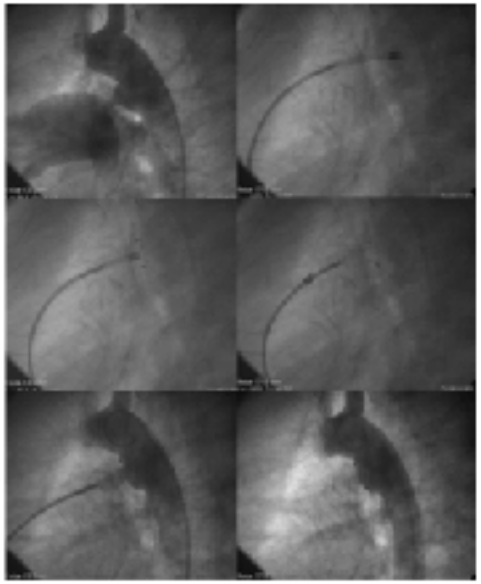

Coarctation

- Palpation des pouls fémoraux chez tous les nouveaux-nés avant sortie de la maternité

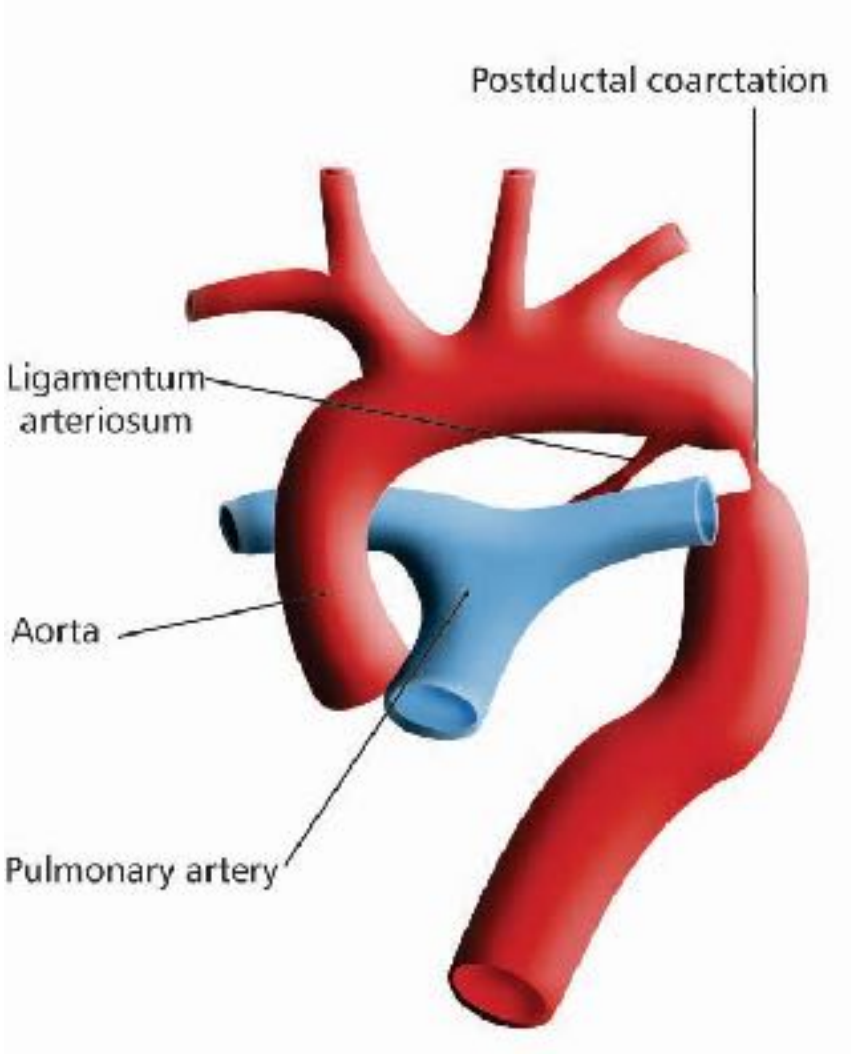

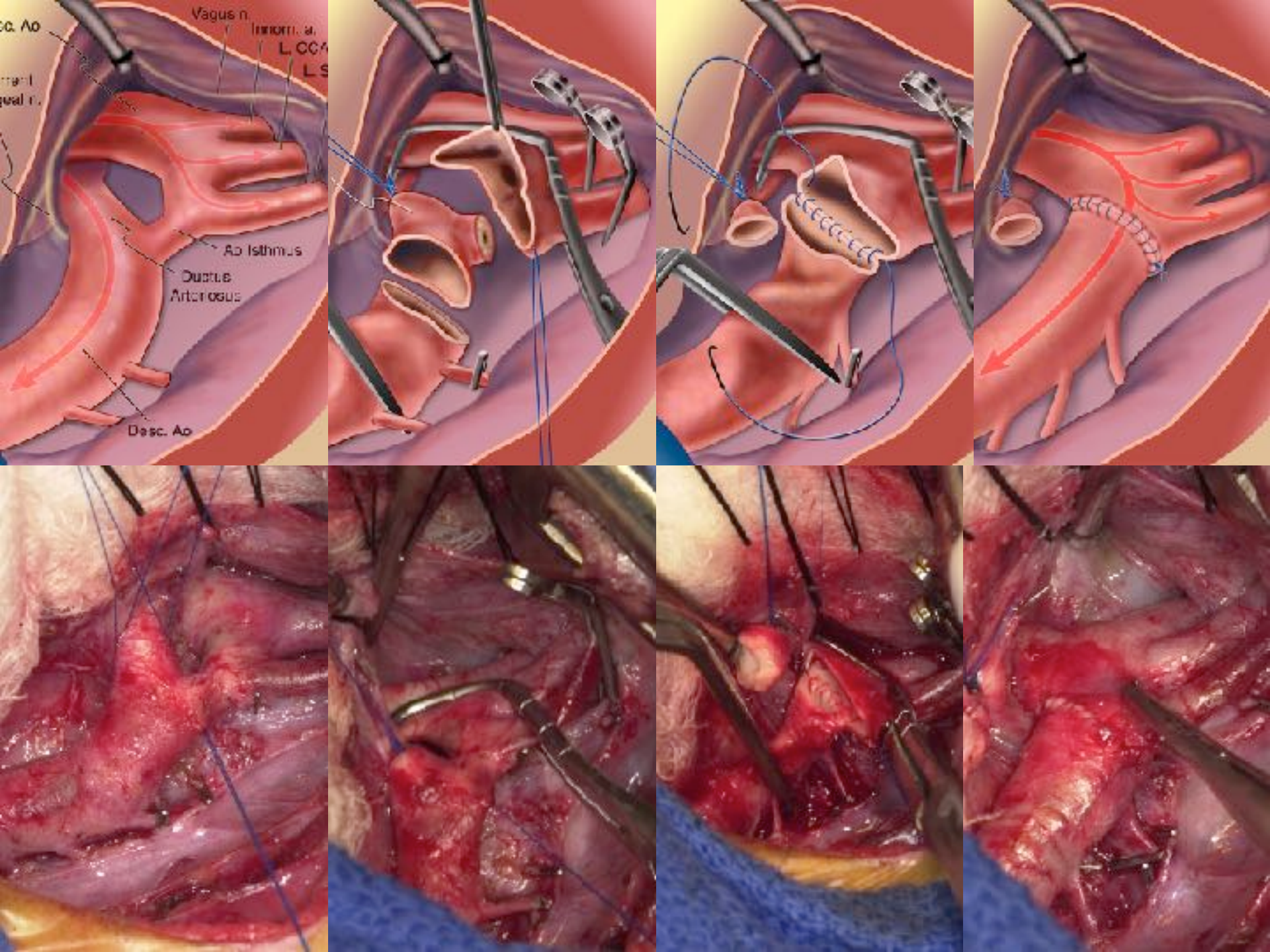
Vagus n.
Innom. a.
Ao Isthmus
Ductus
Arteriosus
Desc. Ao

Anomalies des arcs aortiques

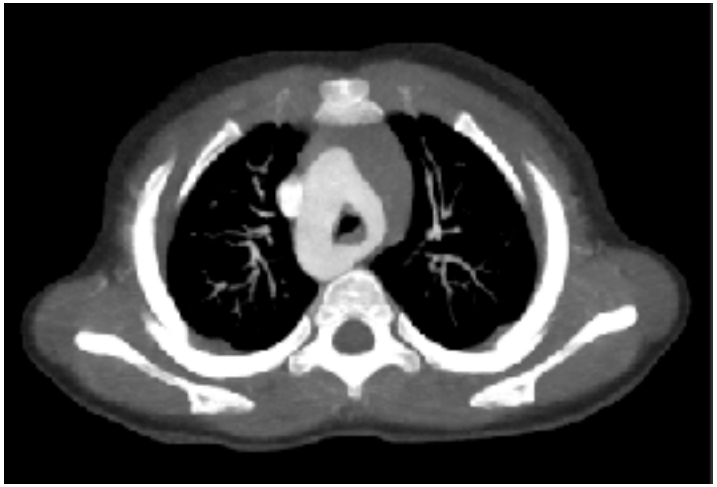

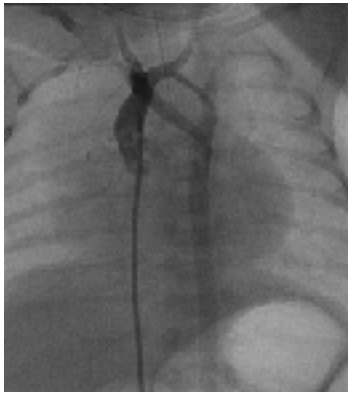

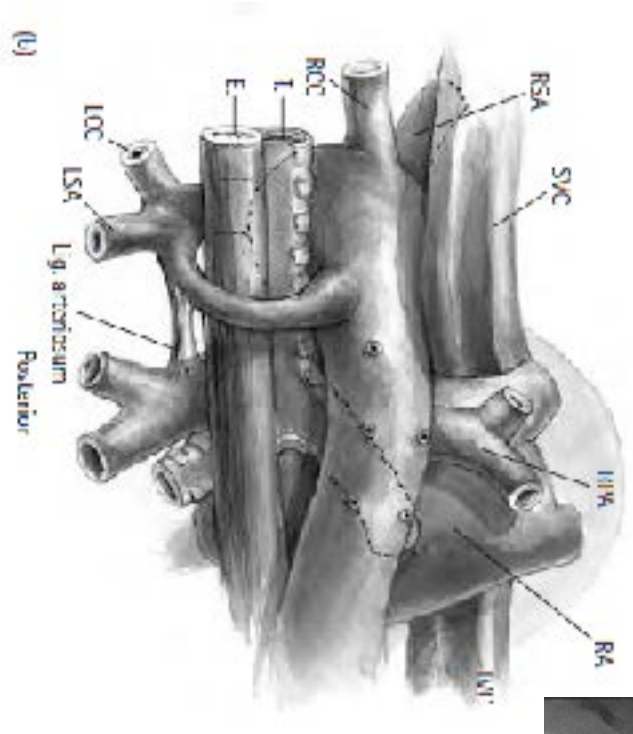

Rythmologie pédiatrique

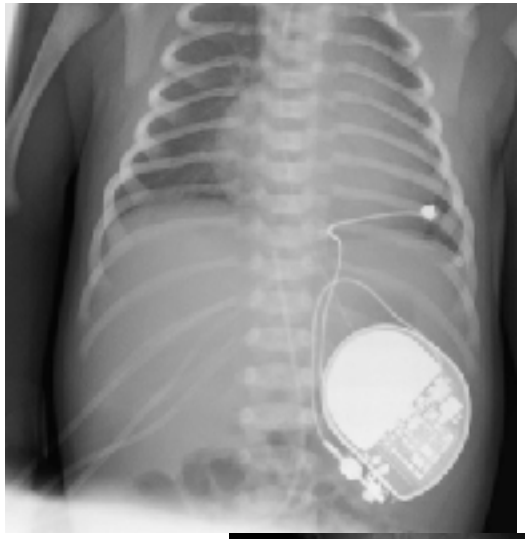

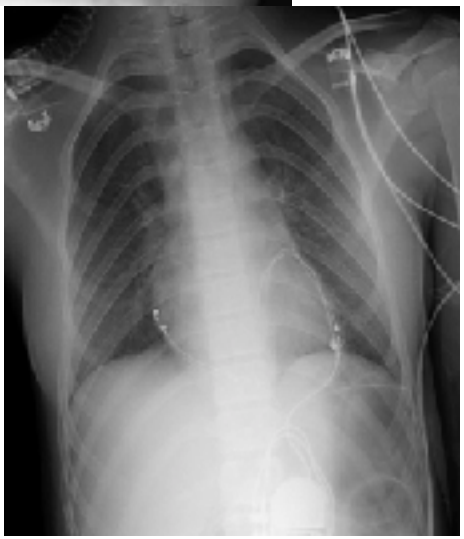

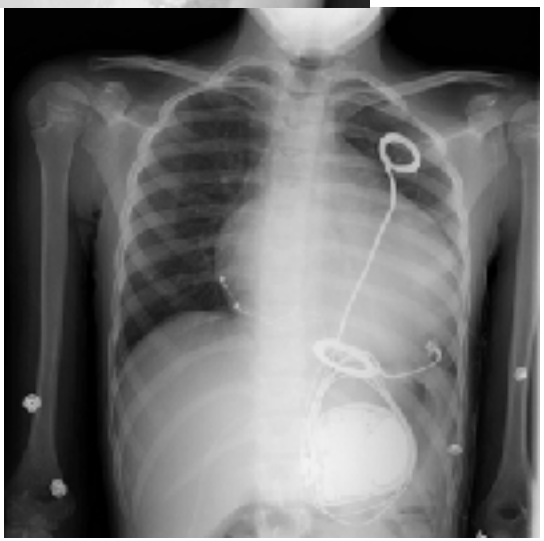

CIA

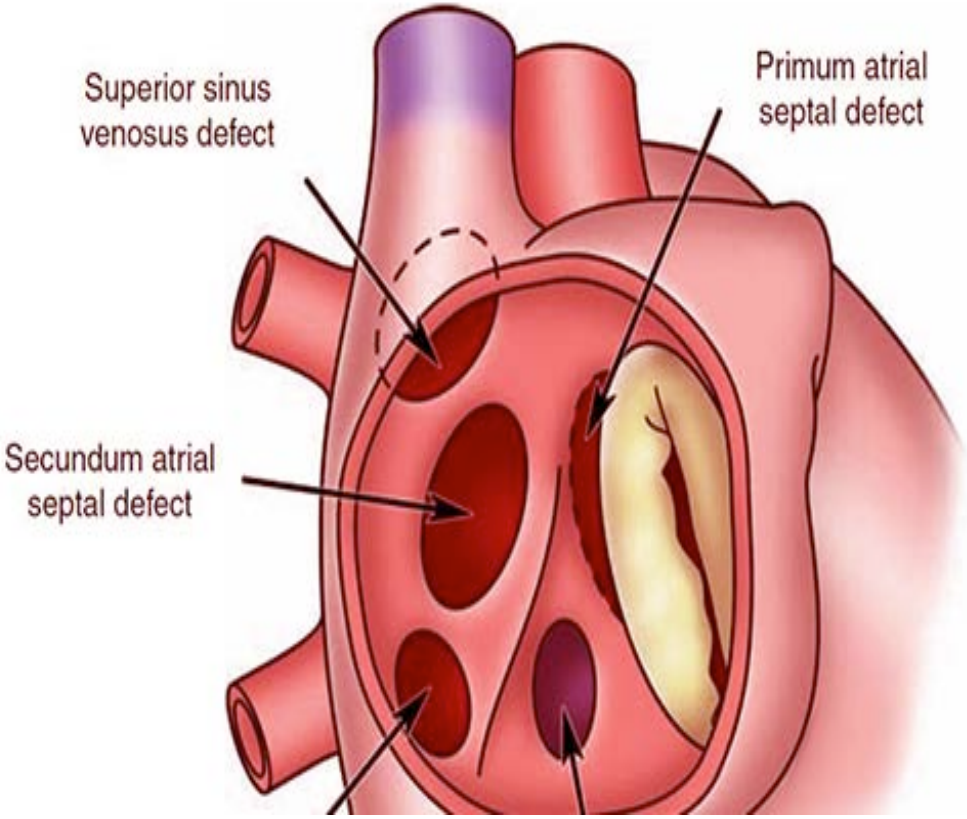
Superior sinus
venosus defect
Primum atrial
septal defect
Secundum atrial
septal defect

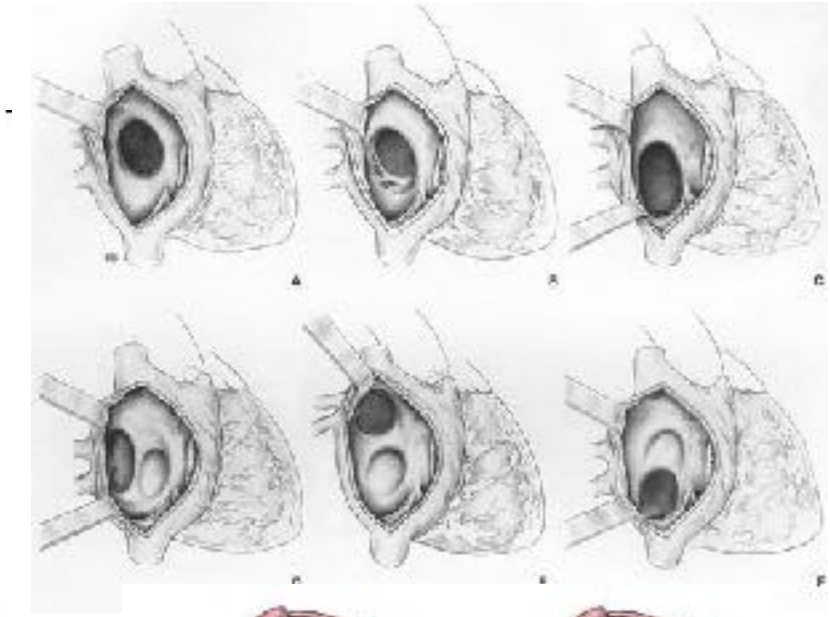

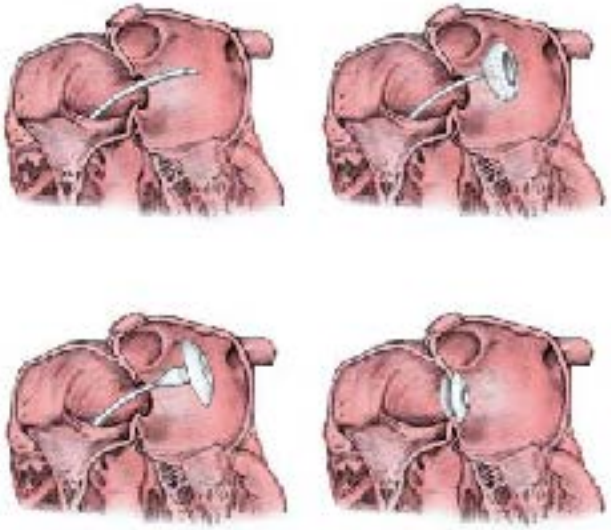

CIA RVPAP

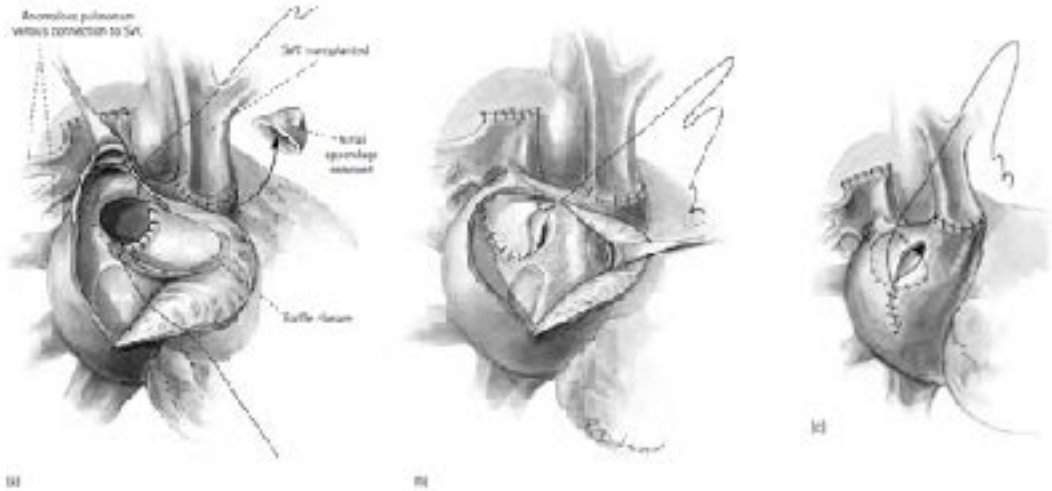

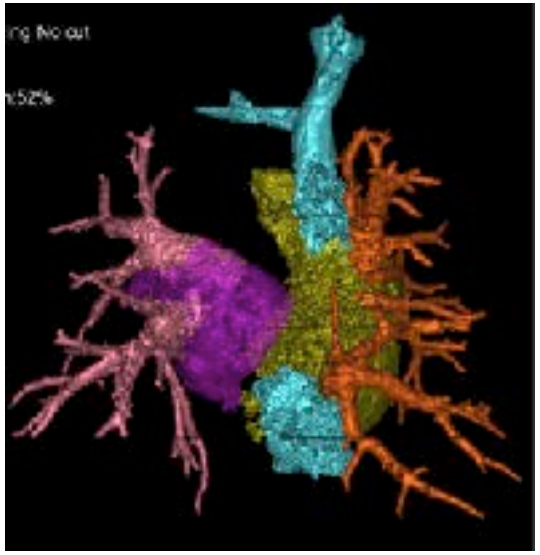

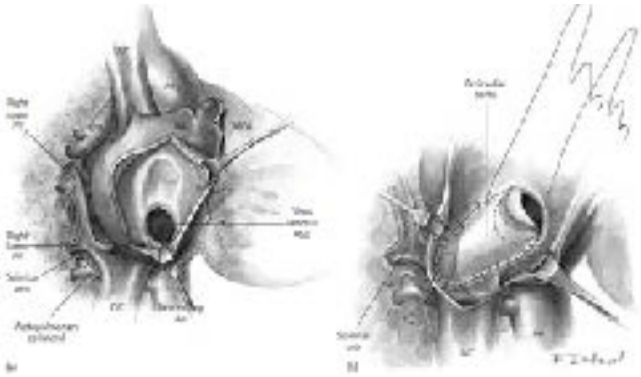

CIV

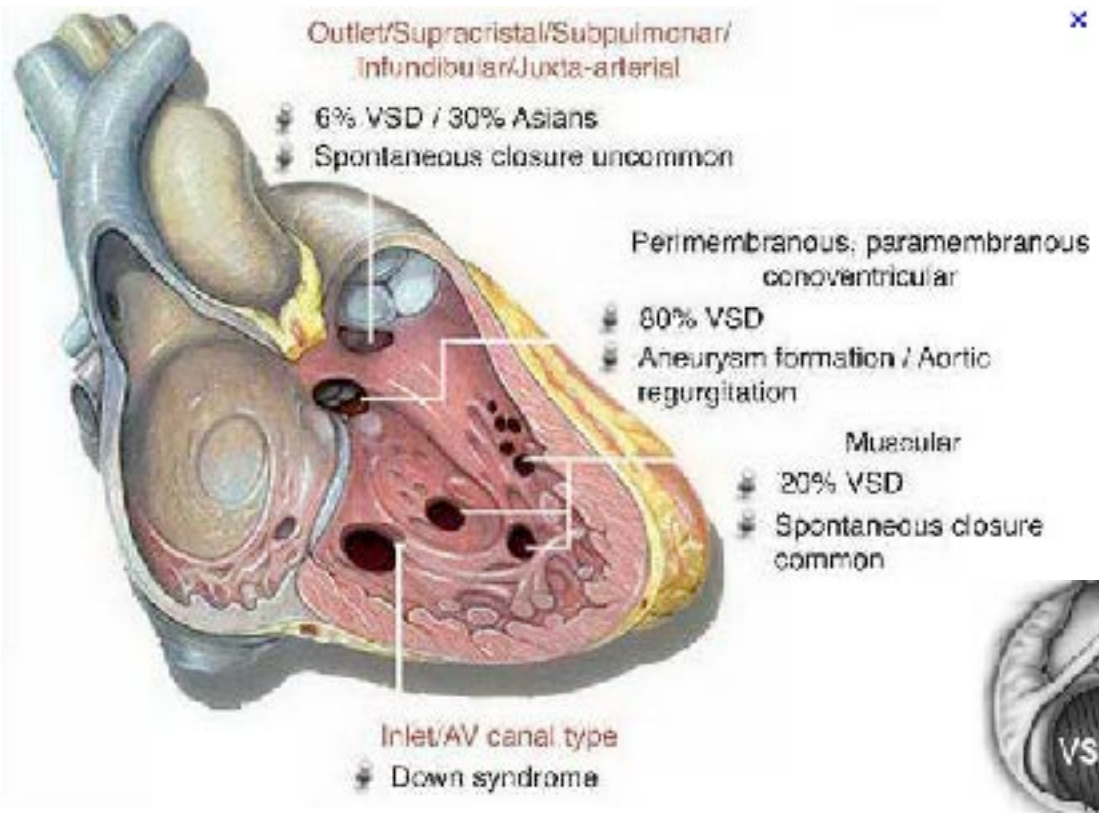
Outlet/Supracristal/Subpulmonar/
Infundibular/Juxta-arterial
6% VSD / 30% Asians
Spontaneous closure uncommon
Perimembranous, paramembranous
conoventricular
80% VSD
Aneurysm formation / Aortic
regurgitation
Muscular
20% VSD
Spontaneous closure
common
Inlet/AV canal type
Down syndrome

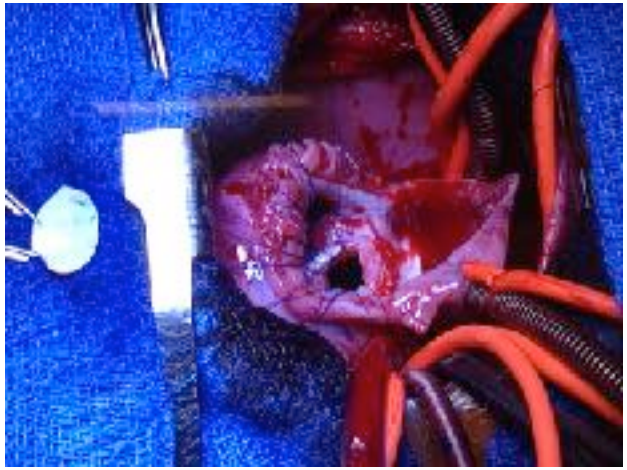

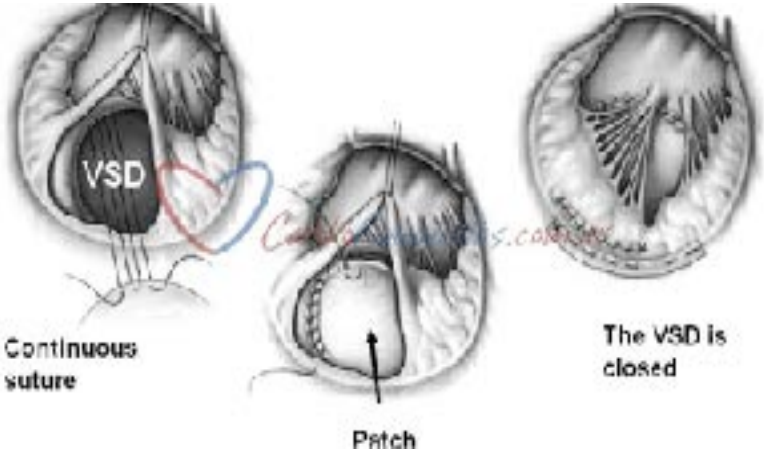
VSD
Continuous
suture
Patch
The VSD is
closed

Tétralogie de Fallot

Tétralogie = 4 éléments ?

1. CIV
2. Sténose pulmonaire
3. Dextroposition Ao
4. Hypertrophie Infundibulaire

→ Bascule antérieure du septum conal

Tétralogie de Fallot

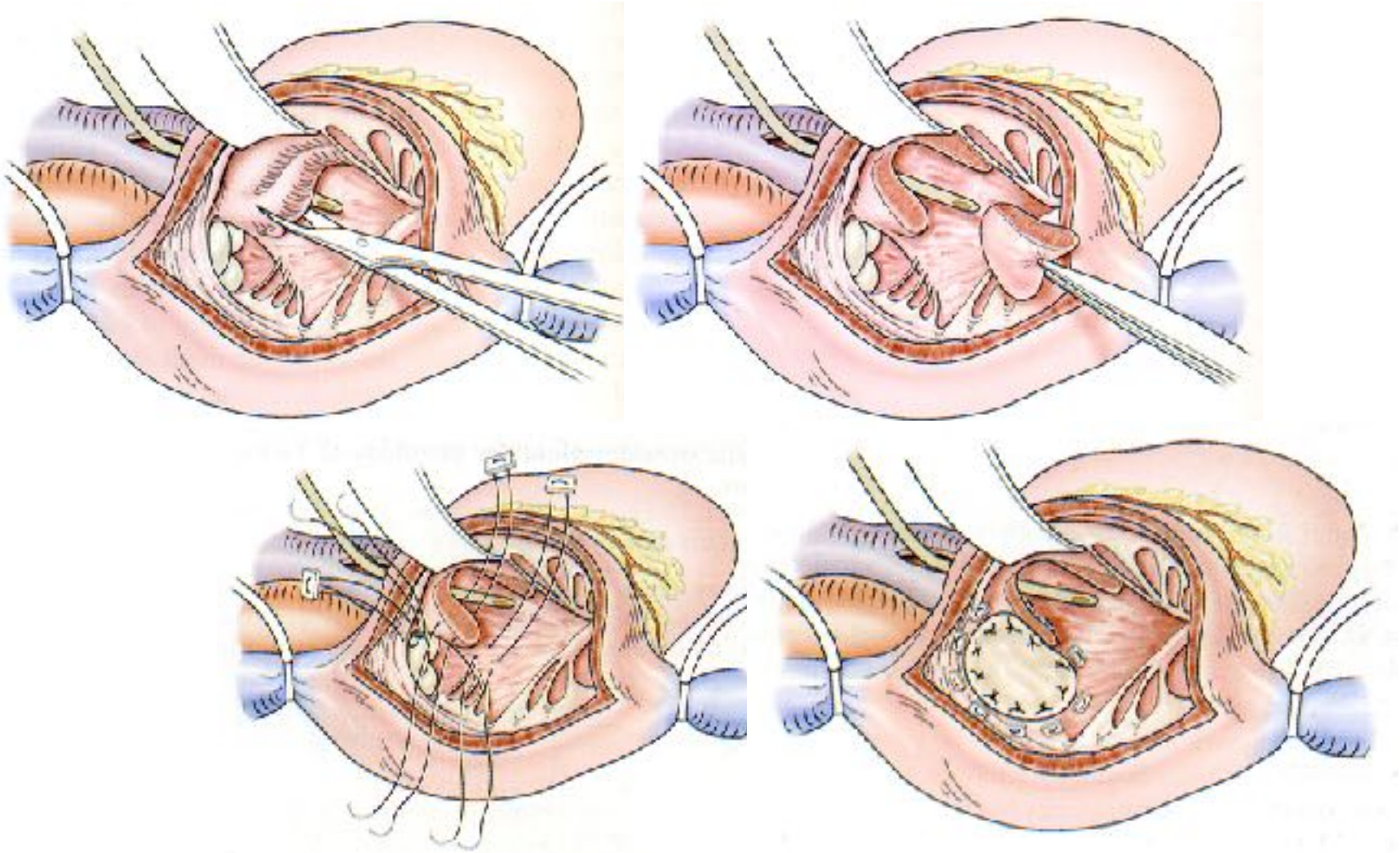

Tétralogie de Fallot

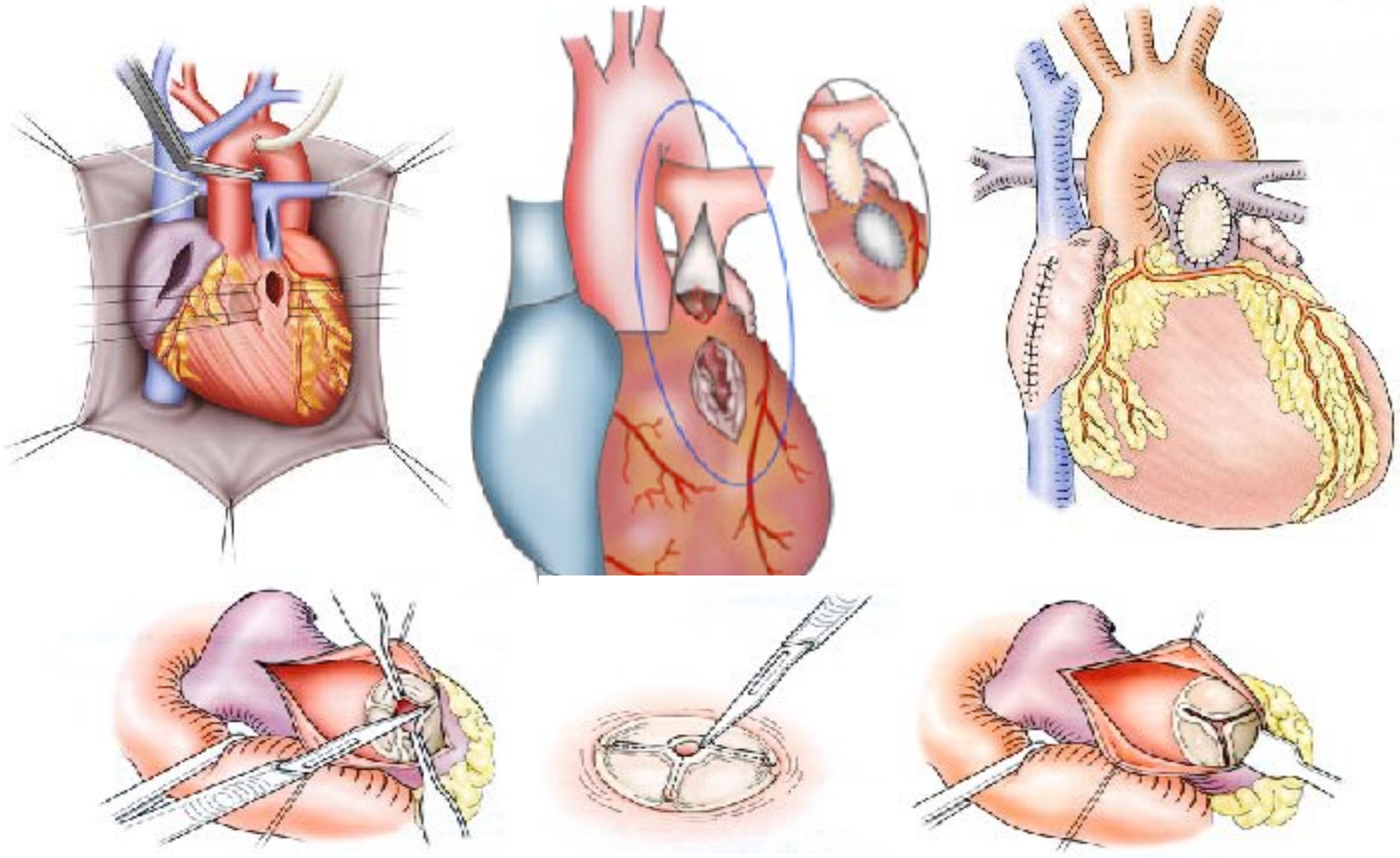

Canal Atrio-Ventriculaire

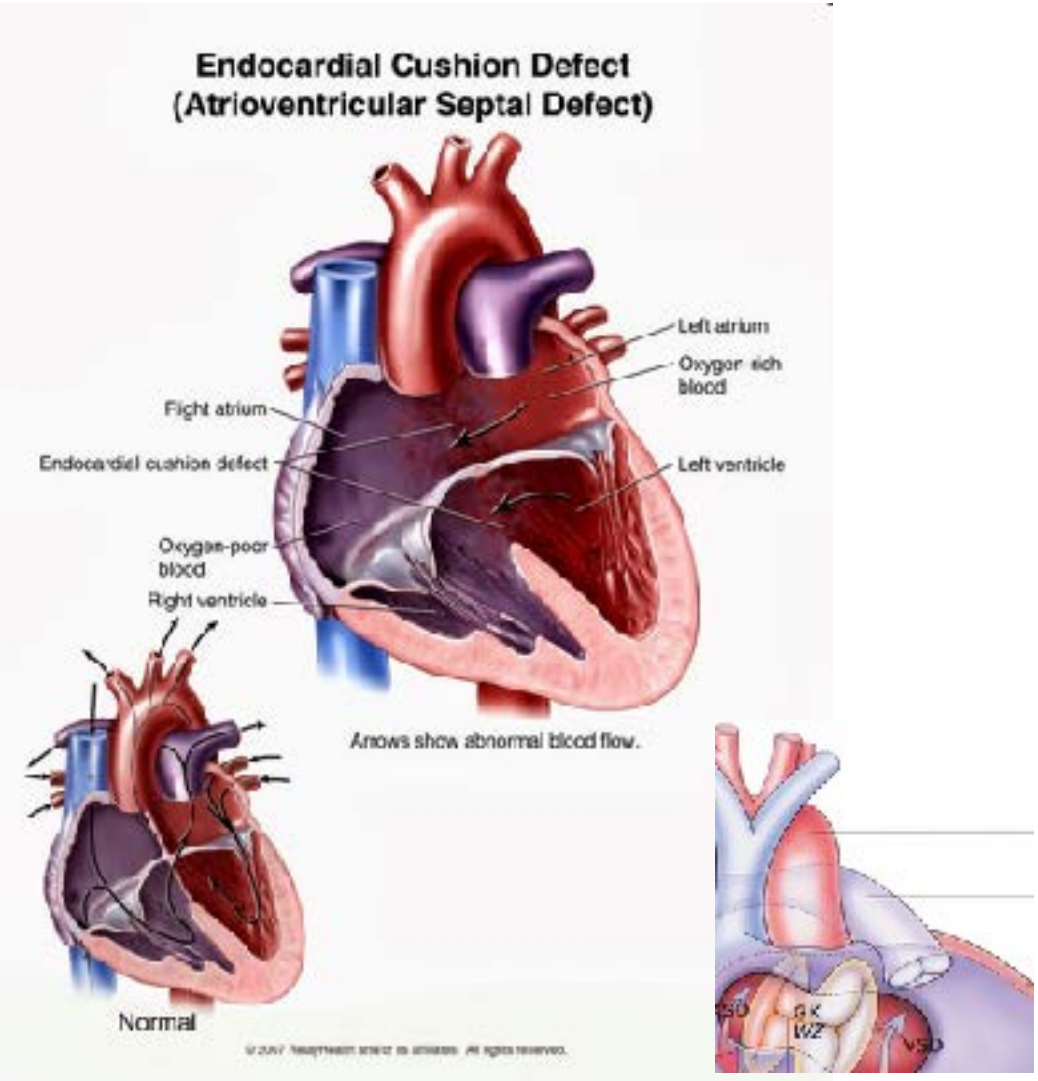

Valves et voies d’éjection

- Aortique
  - Sténose sous valvulaire, valvulaire, sus valvulaire
  - Insuffisance
- Pulmonaire
  - Sténose sous valvulaire, valvulaire, sus valvulaire
- Mitrale
  - IM, RM
- Tricuspide
  - IT, Ebstein

Sténoses Supra-Valvulaires Aortiques

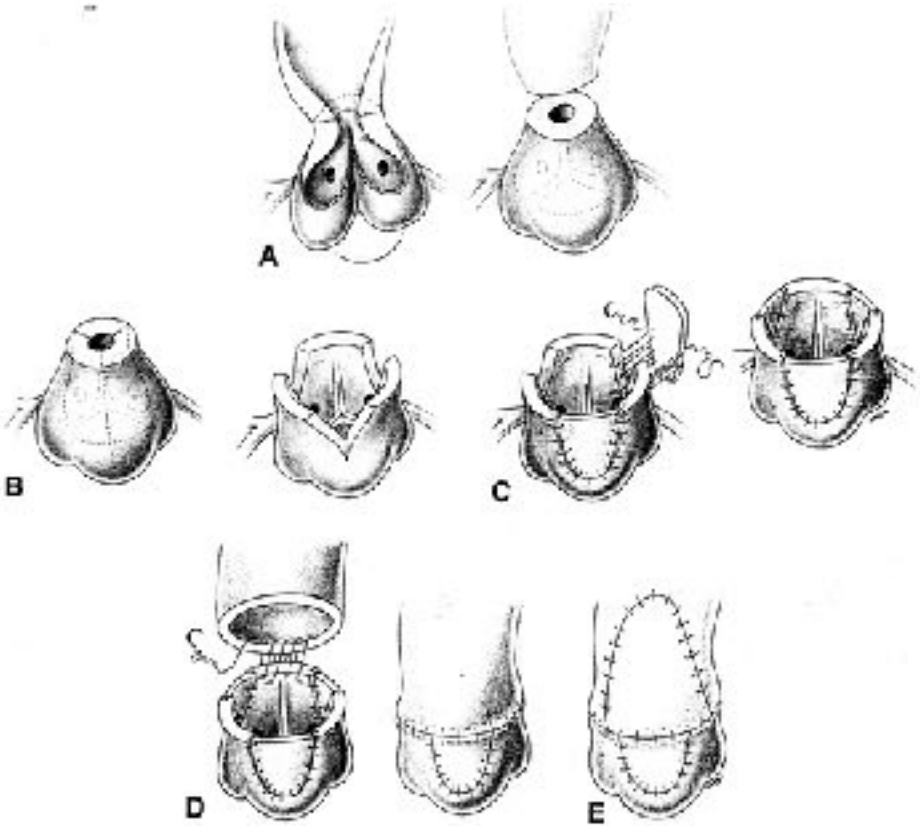

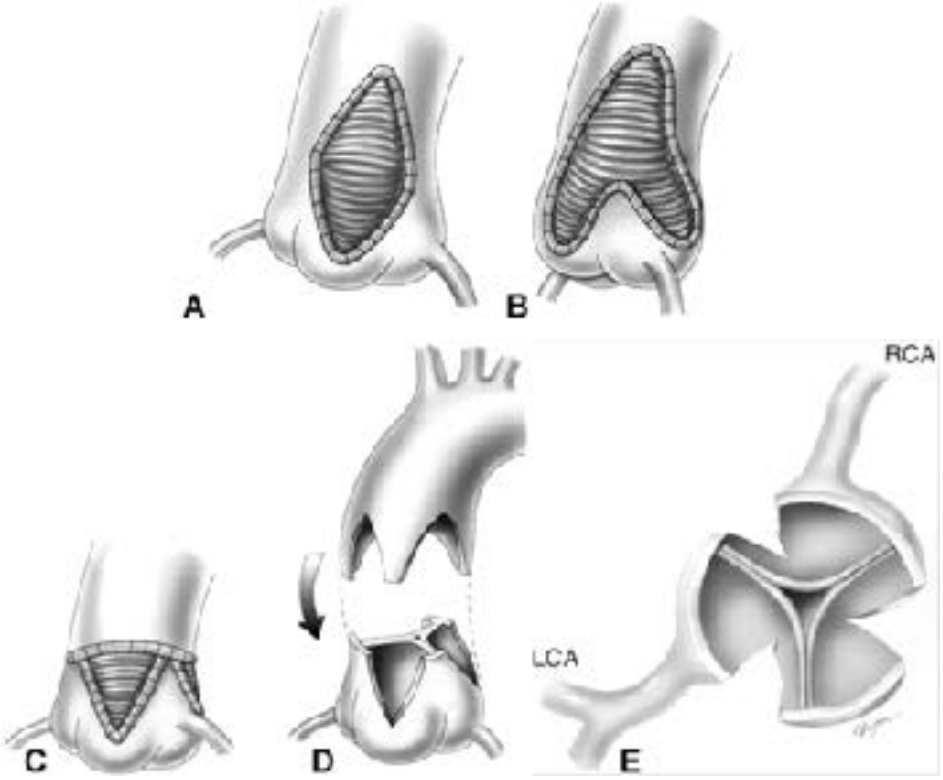

Sténoses Valvulaires Aortiques

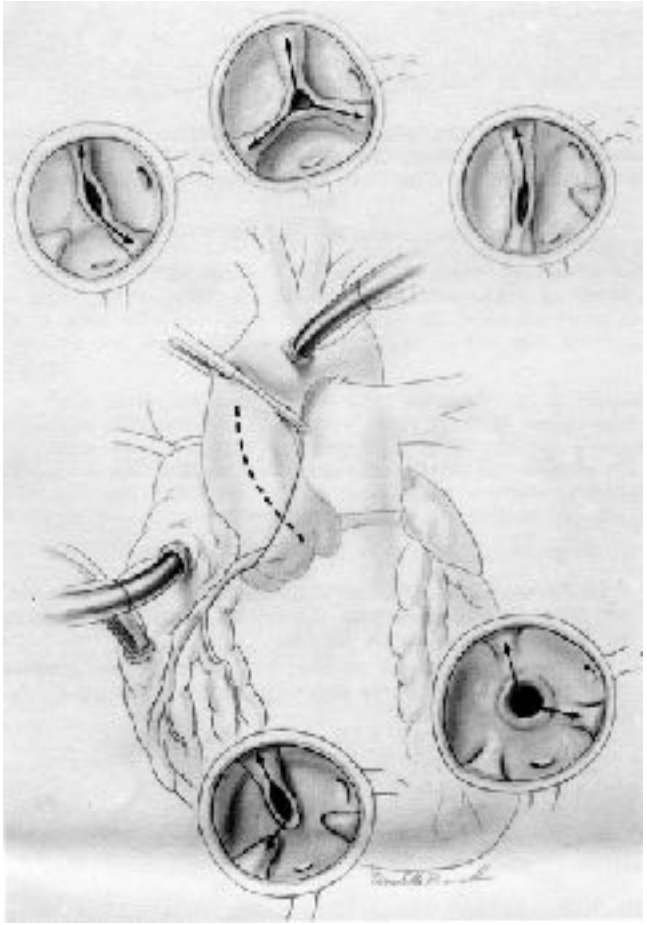

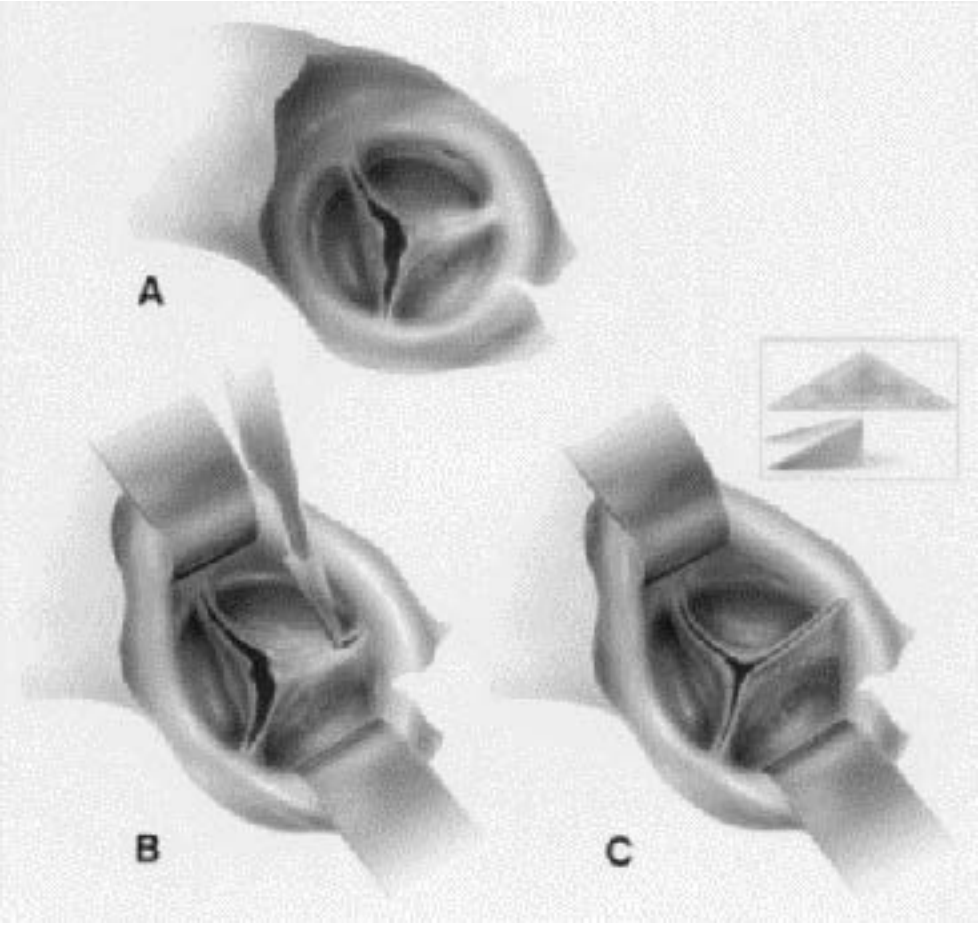

Sténoses Valvulaires Aortiques

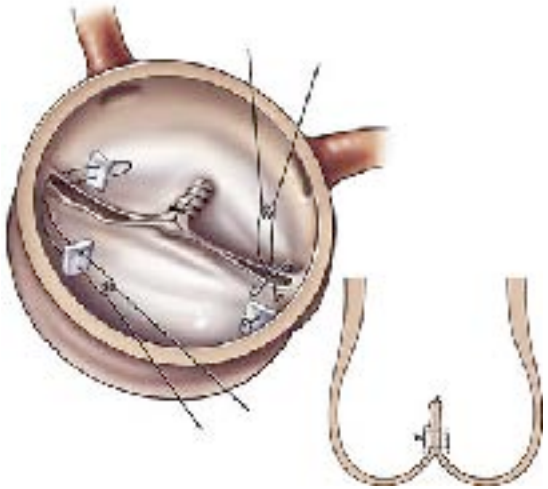

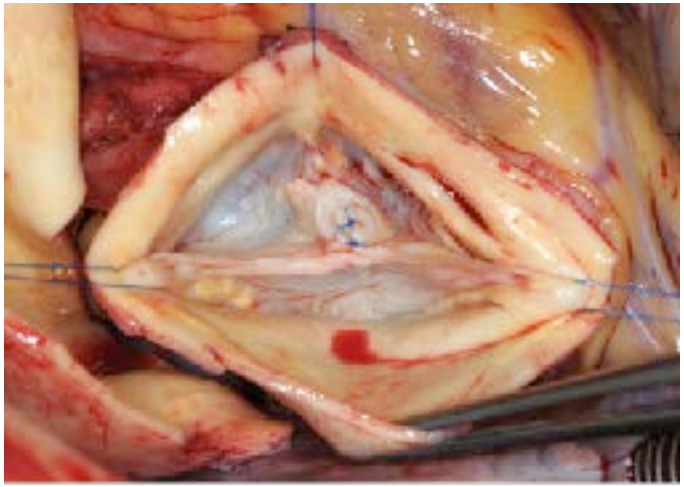

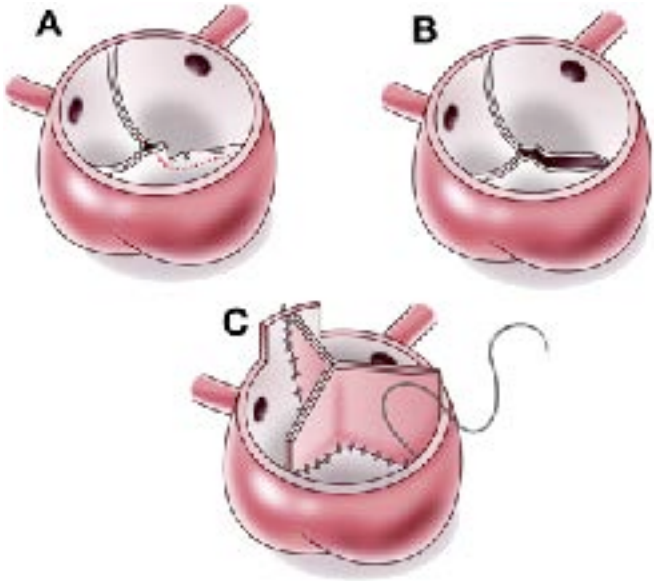

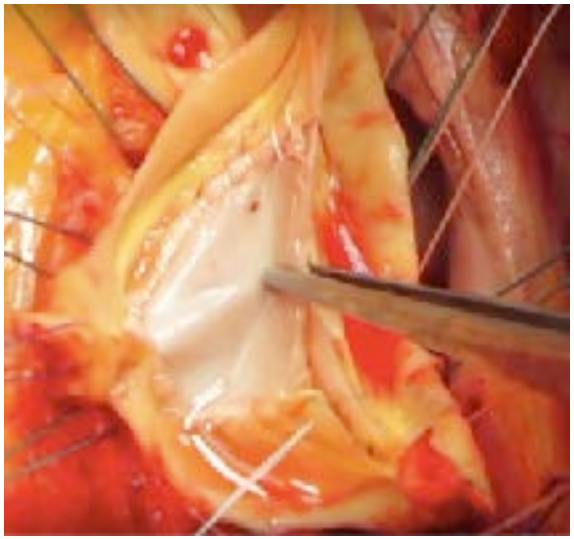

Sténoses Valvulaires Aortiques

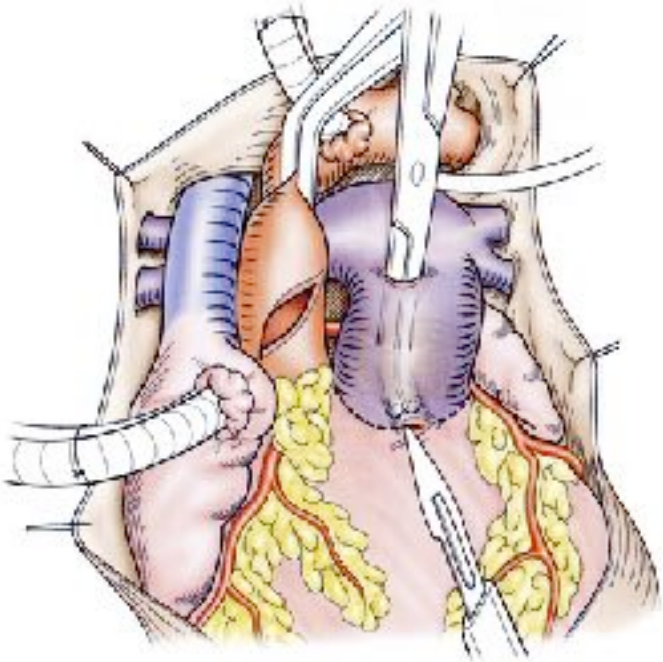

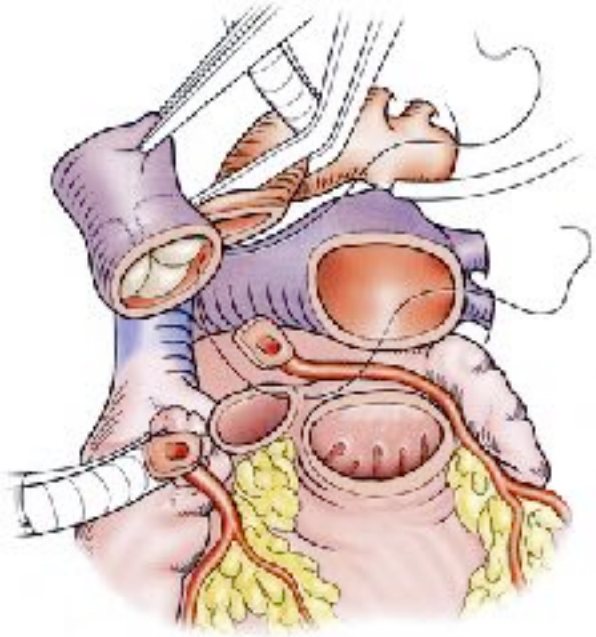

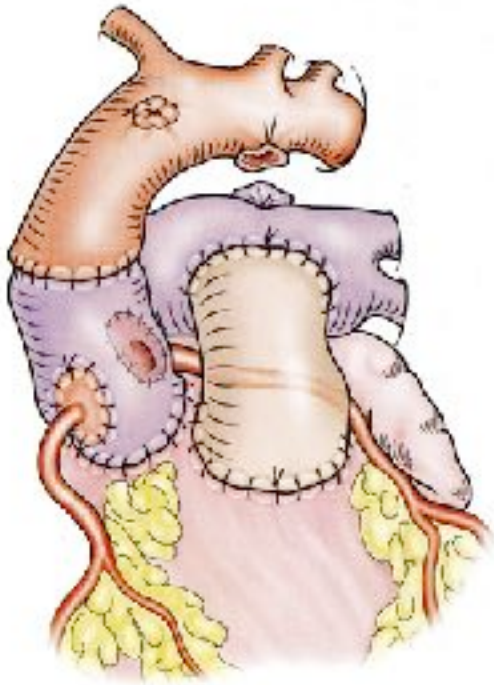

Sténoses Valvulaires Aortiques

Sténoses Valvulaires Aortiques

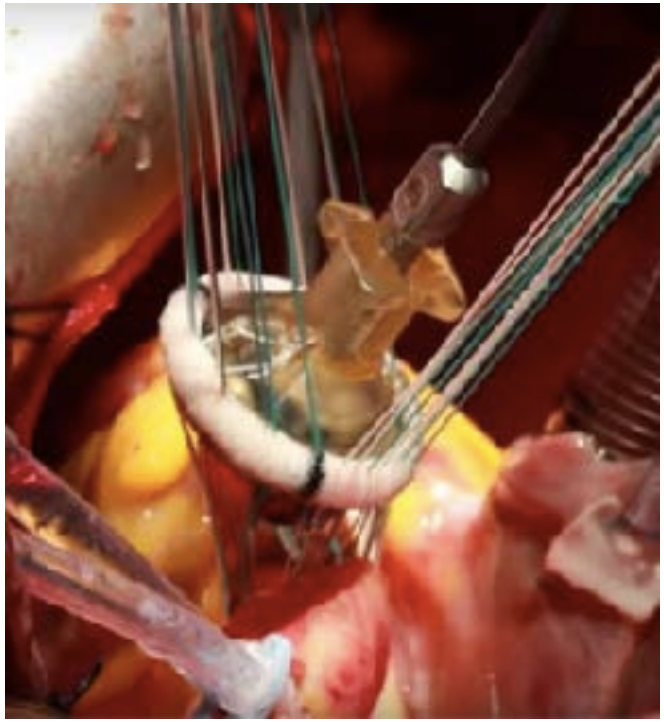

The Journal of Thoracic and Cardiovascular Surgery
Volume 148, Issue 4, October 2014, Pages 1341-1346e1

Acquired cardiovascular disease

Long-term outcomes after elective isolated mechanical aortic valve replacement in young adults

Ismail Boulbat MSc[a,b], Louis Mathieu Stevens MD, PhD[b], Jemine Mazine MSc[a], Nancy Poirier MD[a], Raymond Cartier MD[a], Philippe Demers MD[a], Ismail El-Hamamsy MD, PhD[a,b]

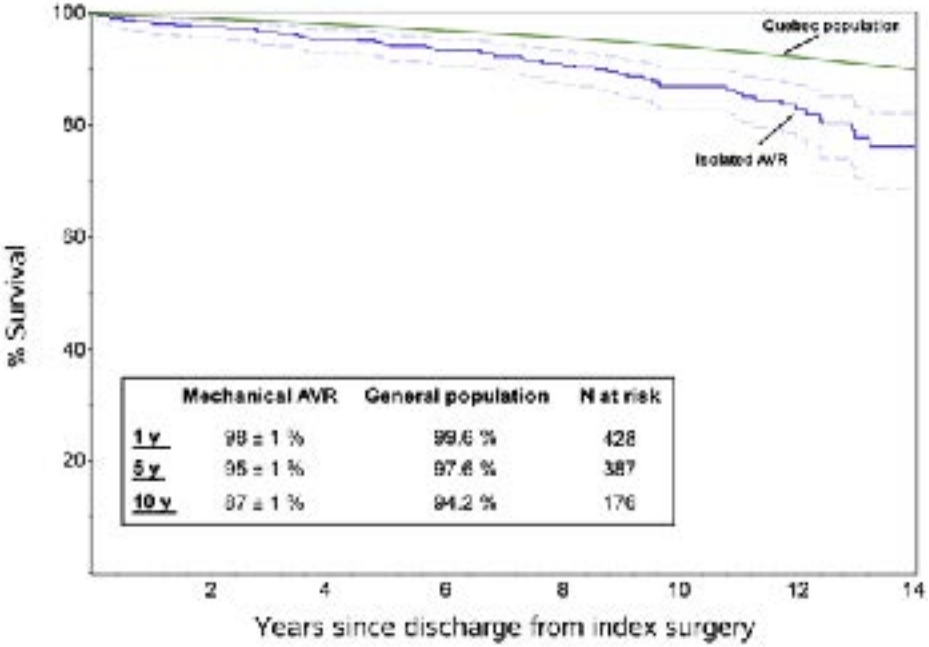

	Mechanical AVR	General population	N at risk
1 y	99 ± 1 %	99.6 %	428
5 y	95 ± 1 %	97.6 %	387
10 y	87 ± 1 %	94.2 %	176

Insuffisances Valvulaires Aortiques

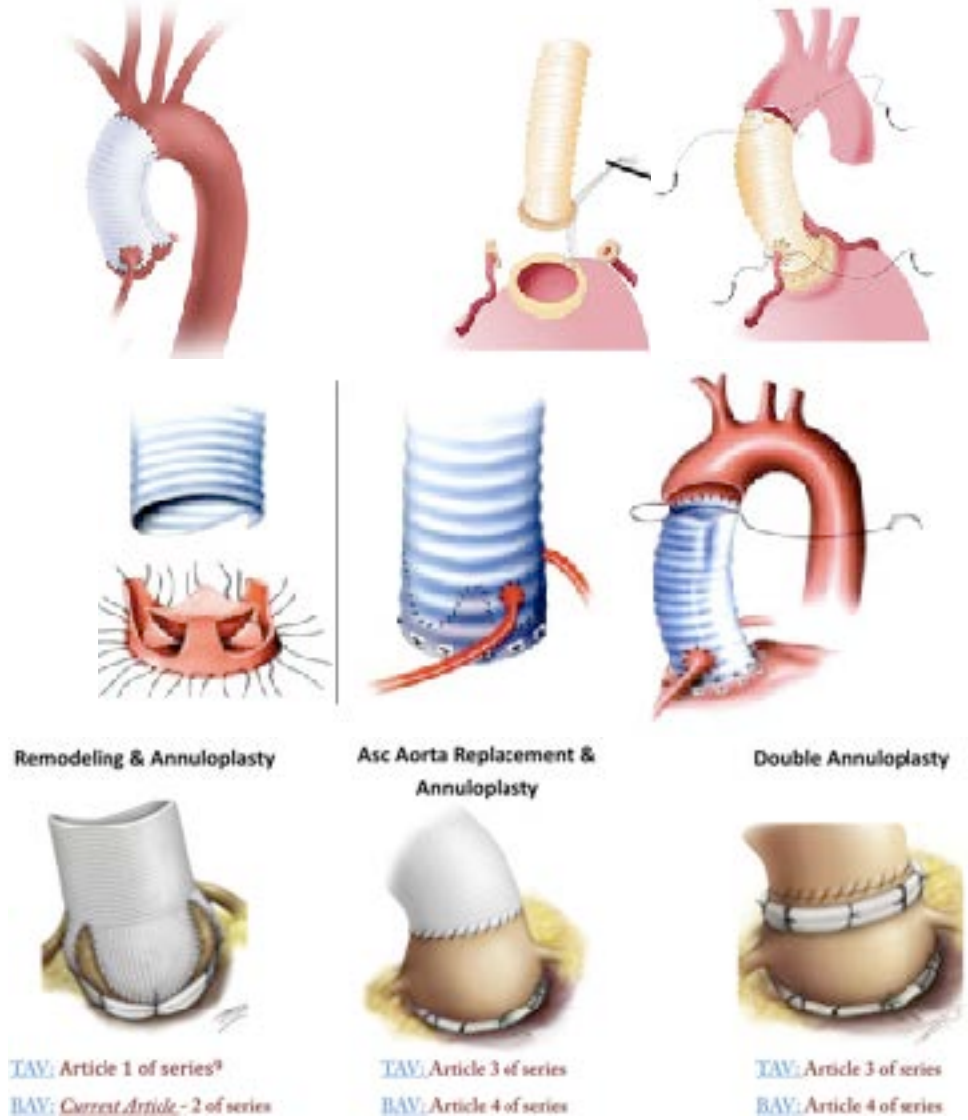

Pathologie mitrale

- Sténose mitrale
  - Rhumatismale
- Insuffisance mitrale
  - Fente mitrale
  - CAV
  - Dilatation / Secondaire

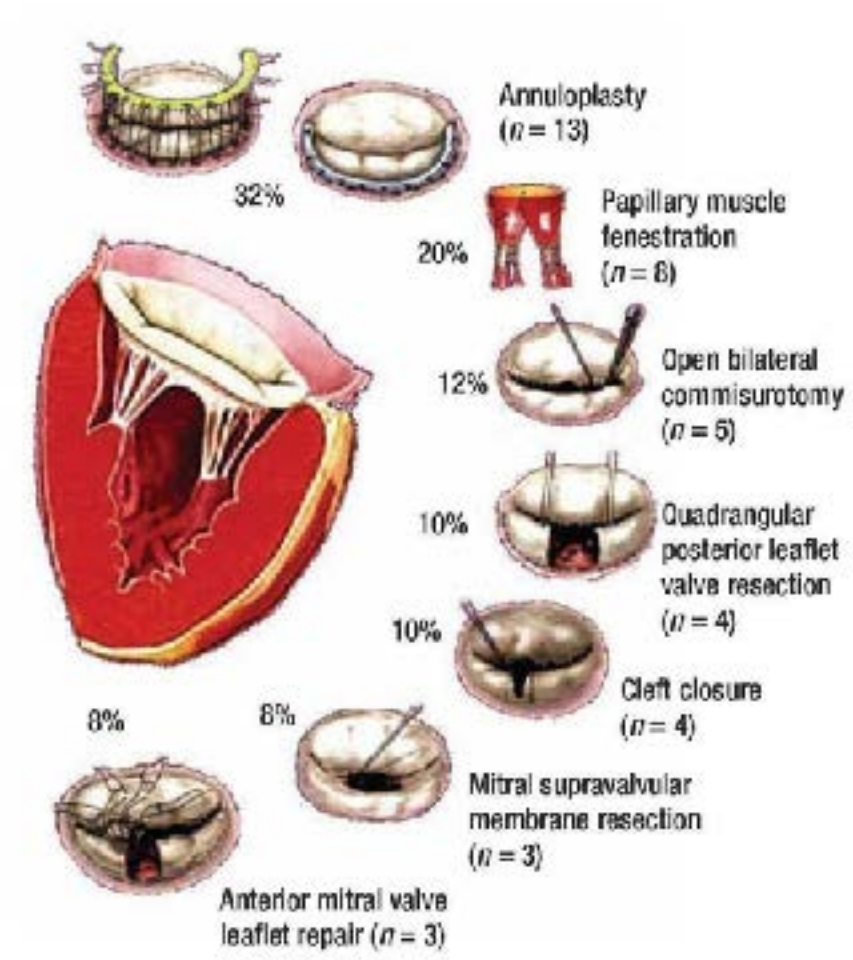

Remplacement valvulaire mécanique

- RVA mécaniques
  - Mortalité précoce 5%
  - Survie moyenne 93% à 5 ans et 10 ans
  - Survie sans réintervention 87% à 10 ans
- RVM mécaniques
  - Mortalité précoce 9%
  - Survie moyenne 82% à 5 ans, 79% à 10 ans
  - Survie sans réintervention 68% à 10 ans
- PM 11%, 3,5% endocardite, 2% thrombose de valve, 7% saignement grave, 6% embolie

Pathologie tricuspide

- Insuffisance tricuspide congénitale / Ebstein

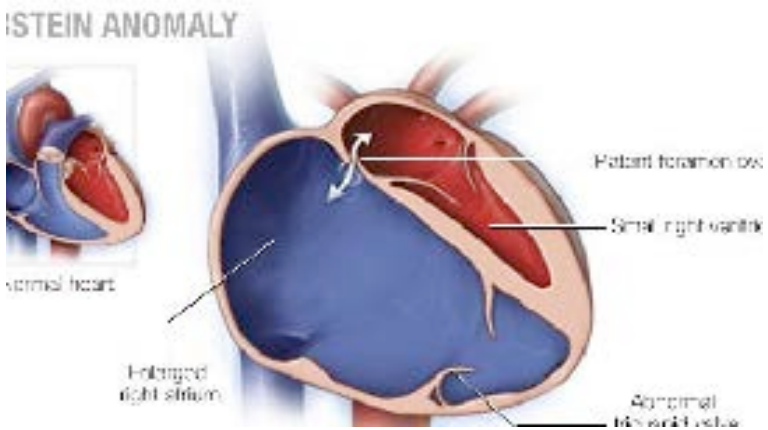

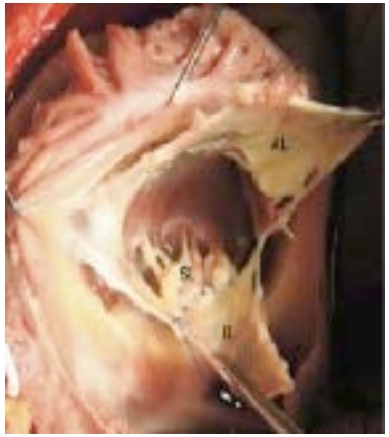

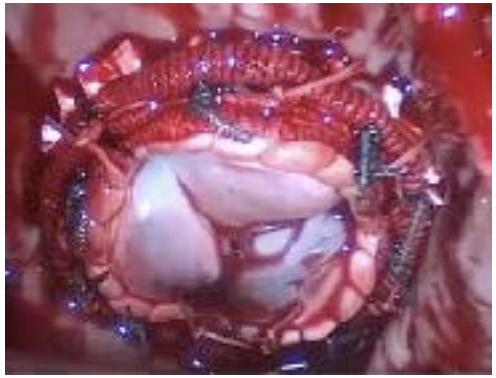

Transposition des Gros Vaisseaux

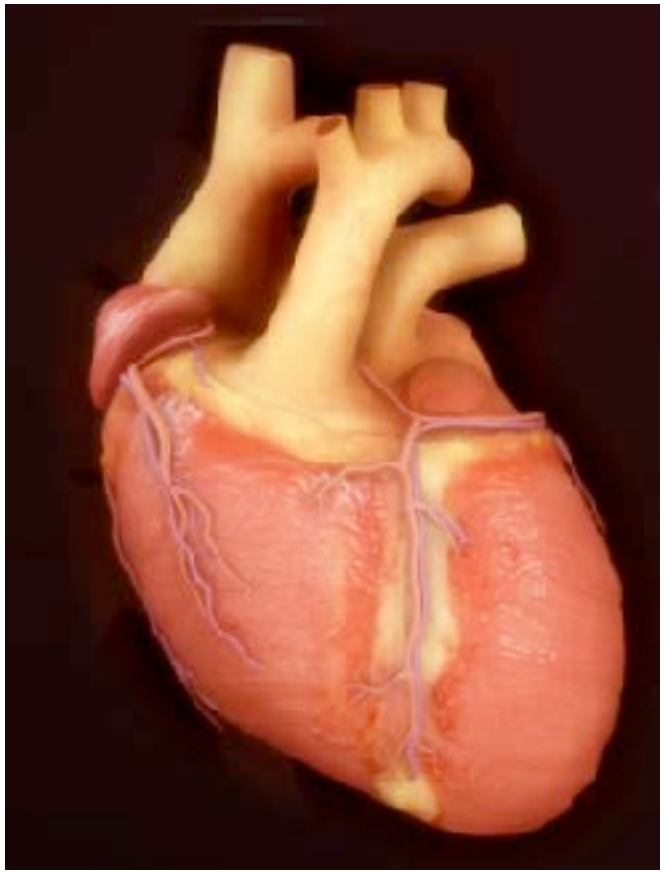

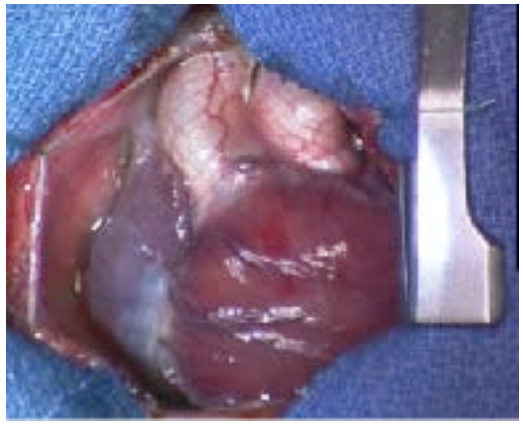

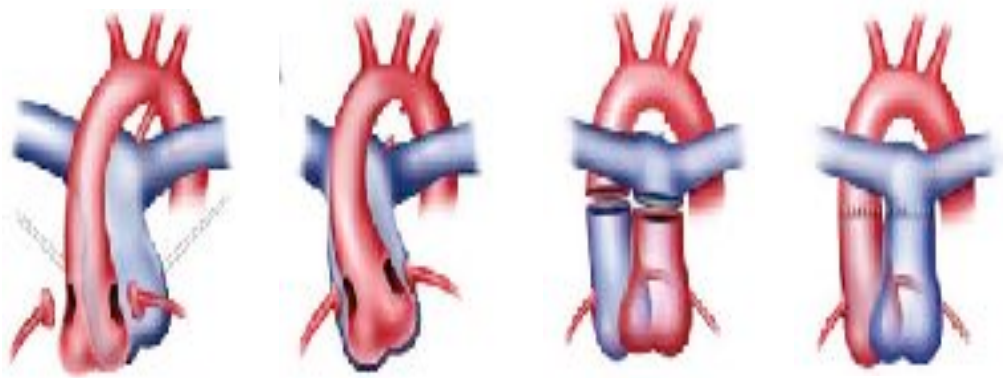

Sections Aortique et Pulmonaire

- Aortique:
  - à distance de la néo-valve pulmonaire
- Pulmonaire:
  - au dessus des commissures
  - exploration des néo-cusp aortique
  - recherche d'un malignement commissural

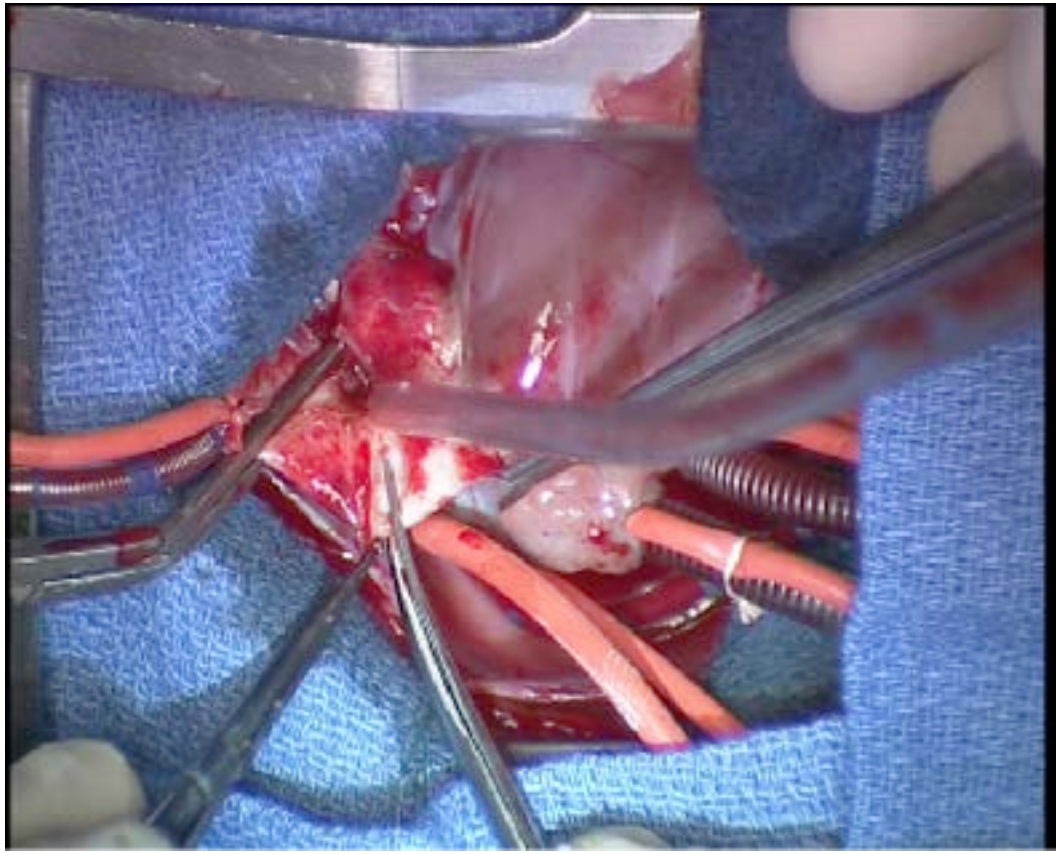

Manœuvre de Lecompte

- Mobilisation extensive des AP
- Section distale de l'aorte
- Néo-aorte courte

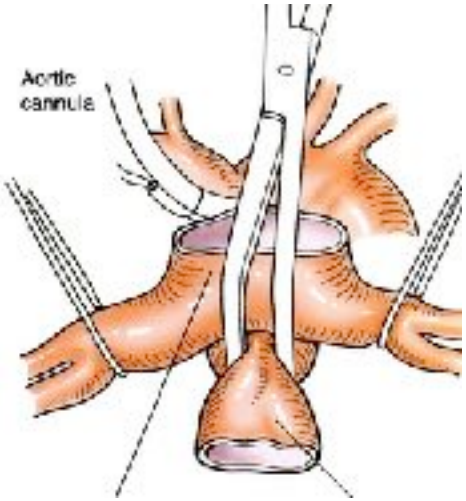

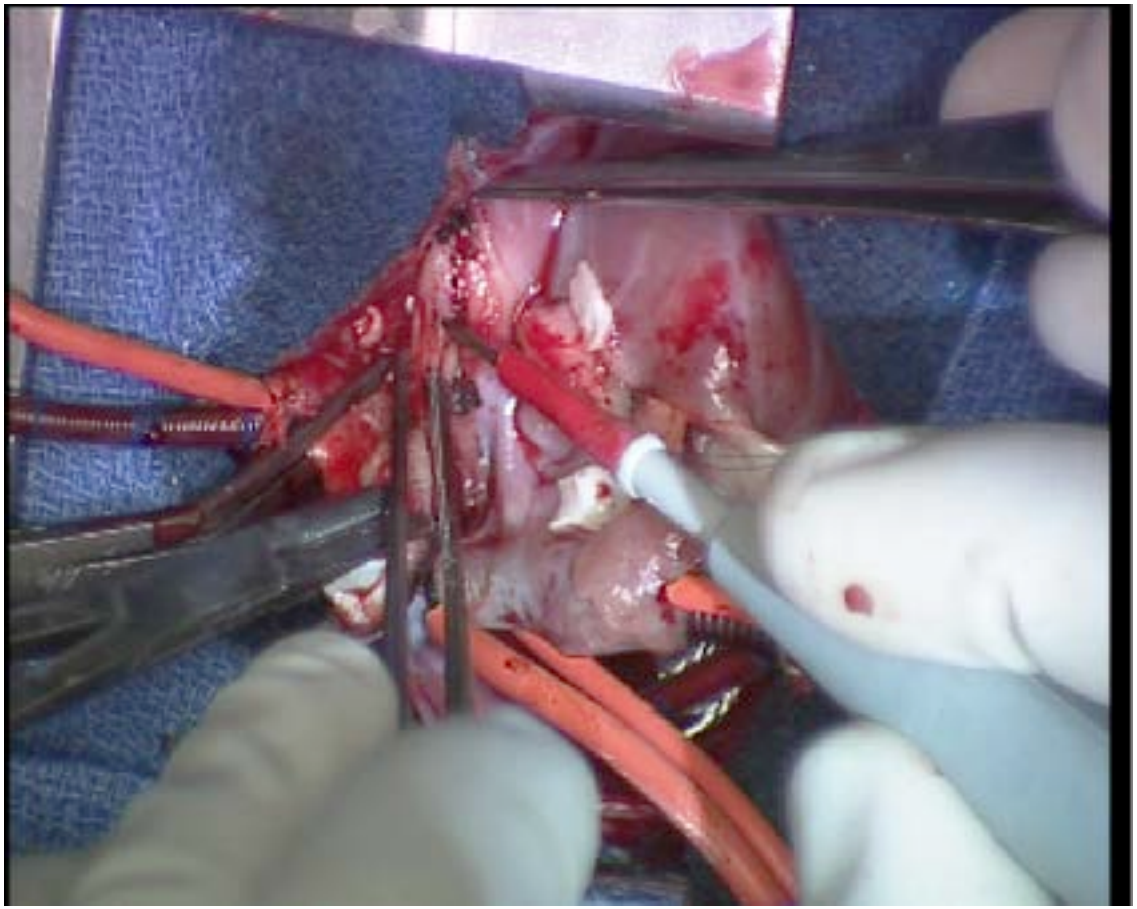

Prélèvement des coronaires

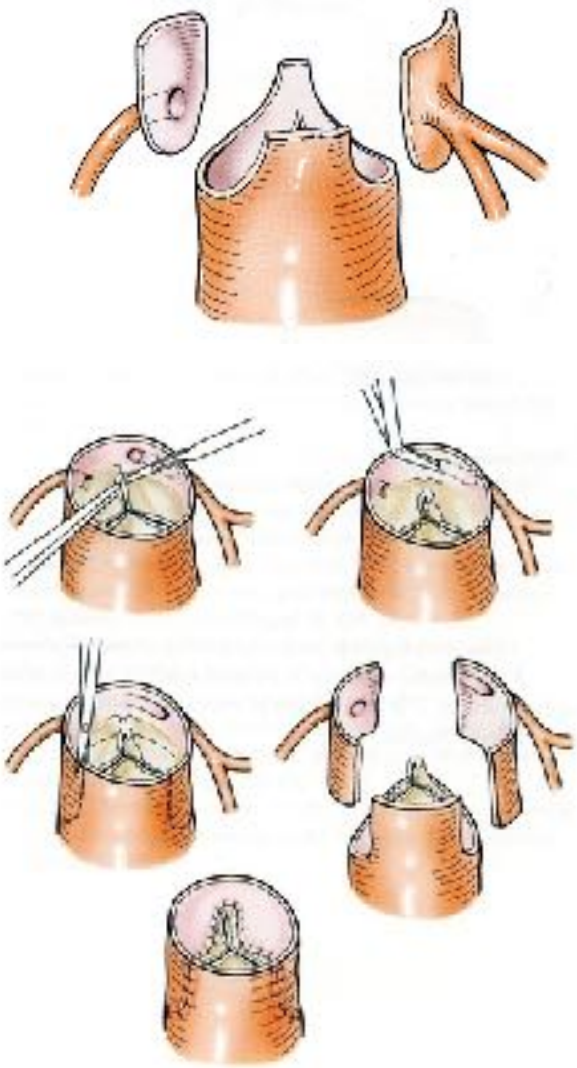

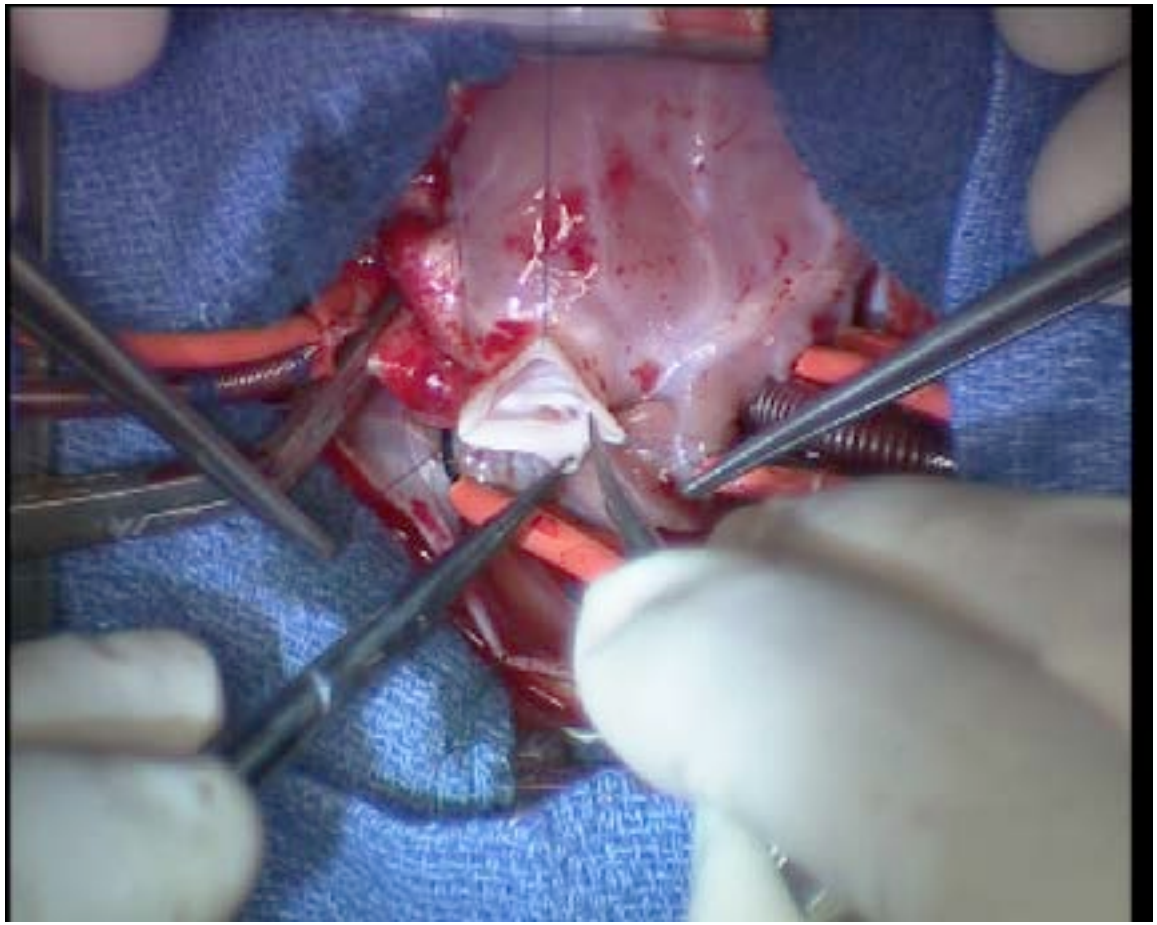

Réimplantation coronaire

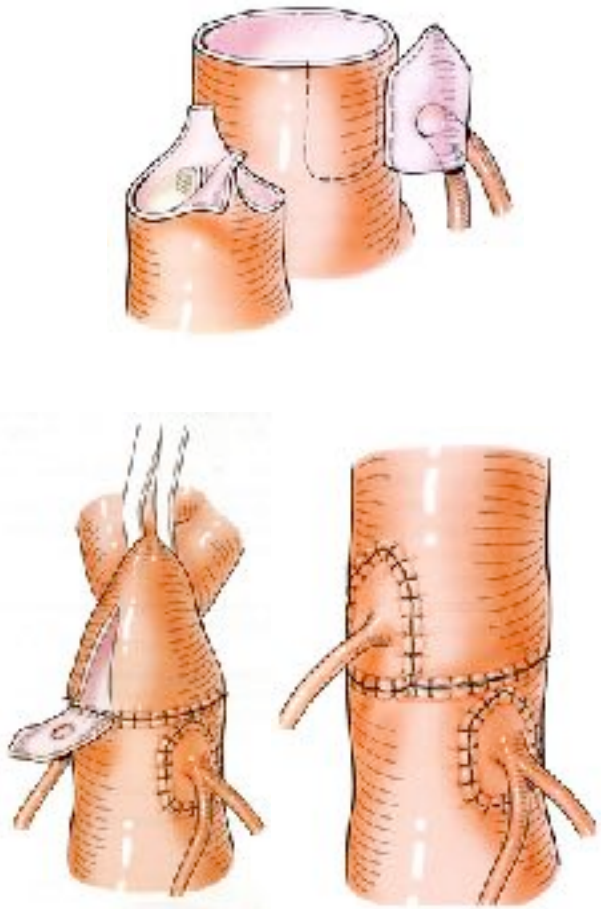

Reconstruction pulmonaire

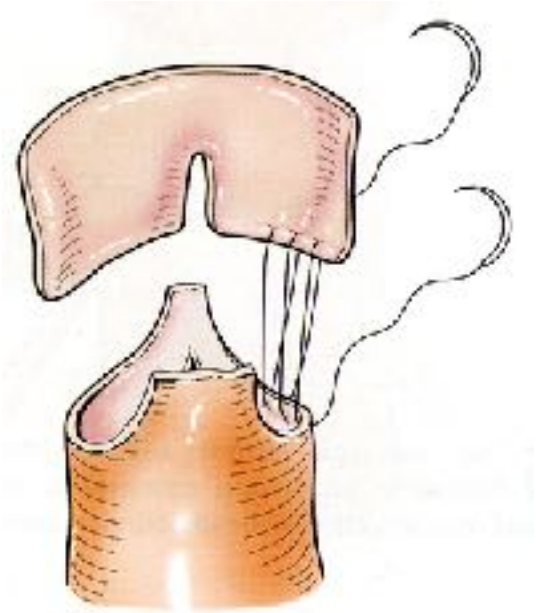

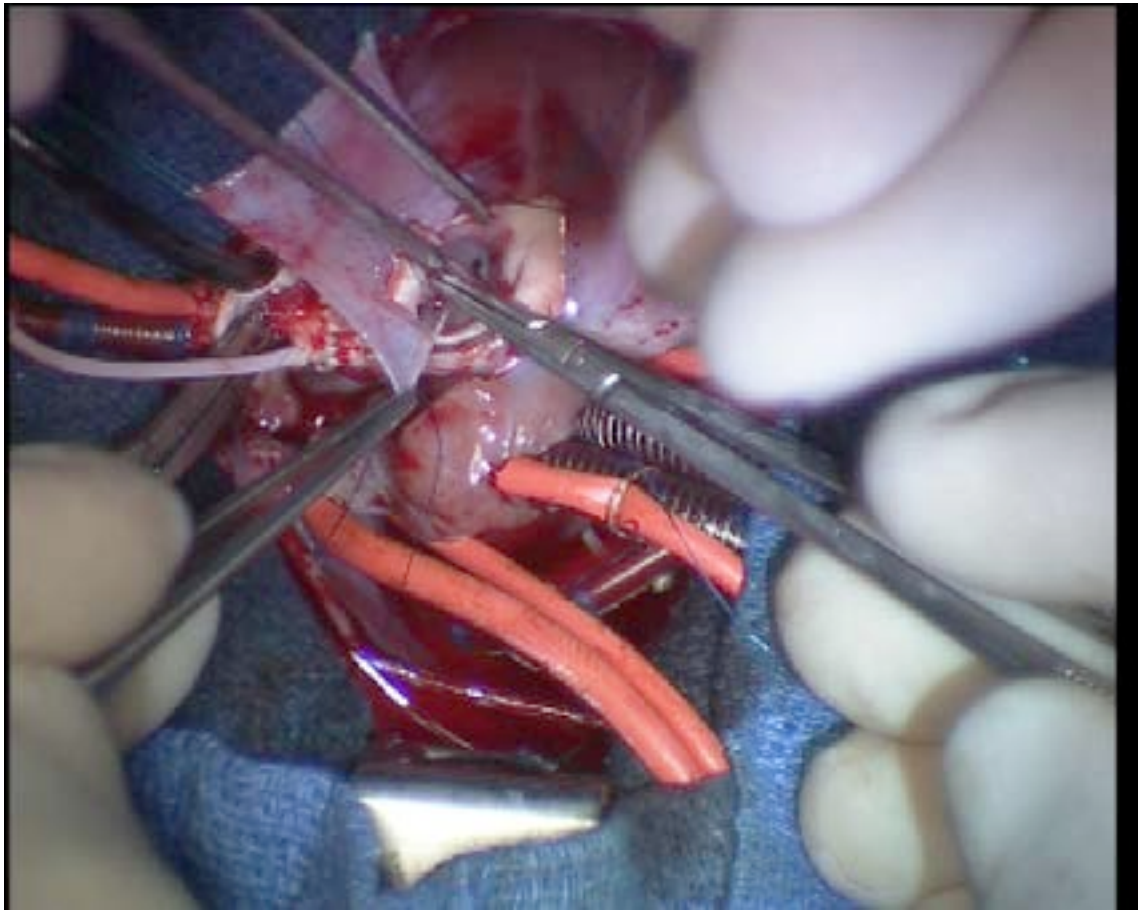

SPECIFICITES DES GUCH

Chirurgie des cardiopathies congénitales chez l'adulte

- GUCH : Grown up Congenital Heart Disease
  -> ACHD : Adult Congenital Heart Disease
- Cardiopathie vieillie découverte tardivement
- Redux, tridux, quadridux… multiopéré

Due to medical, surgical, and technological evolutions, >90% of individuals with CHD who are born, now survive into adulthood

2020. ESC Guidelines. European Heart Journal

Chirurgie des cardiopathies congénitales chez l'adulte

ESC
European Society of Cardiology
European Heart Journal (2021) 42, 563–645
doi:10.1093/eurheartj/ehaa554

ESC GUIDELINES

2020 ESC Guidelines for the management of adult congenital heart disease

The Task Force for the management of adult congenital heart disease of the European Society of Cardiology (ESC)

Endorsed by: Association for European Paediatric and Congenital Cardiology (AEPC), International Society for Adult Congenital Heart Disease (ISACHD)

Chirurgie des cardiopathies congénitales chez l'adulte

- Principalement chirurgie de la voie droite
  - Fallot, APSO
- Evaluation imagerie ++
  - Proximité des structures cardiaques avec sternum : TDM !
  - Accès vasculaire : Echo doppler !
  - Shunt persistant ?

Chirurgie des cardiopathies congénitales chez l'adulte

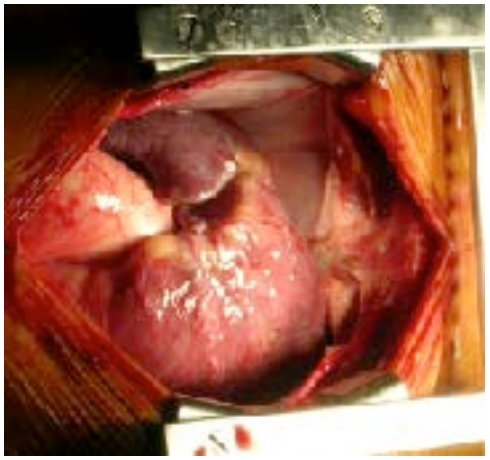

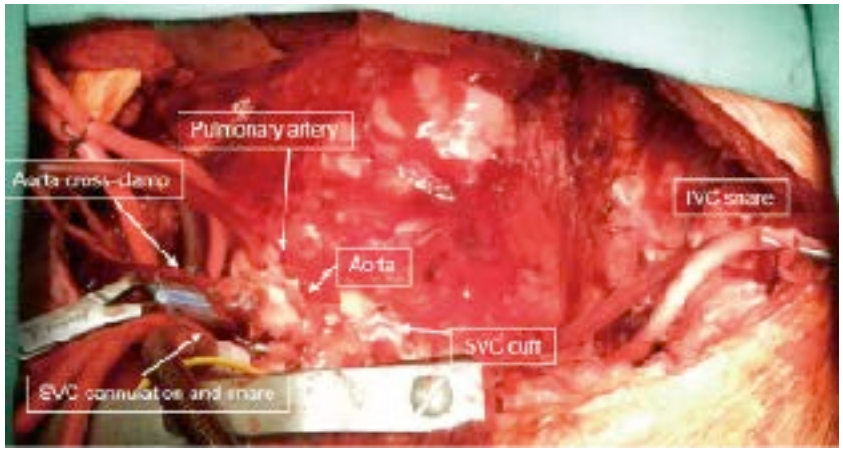

ASSISTANCE CIRCULATOIRE

Les Assistances Circulatoires

V-A ECMO support cardio-respiratoire

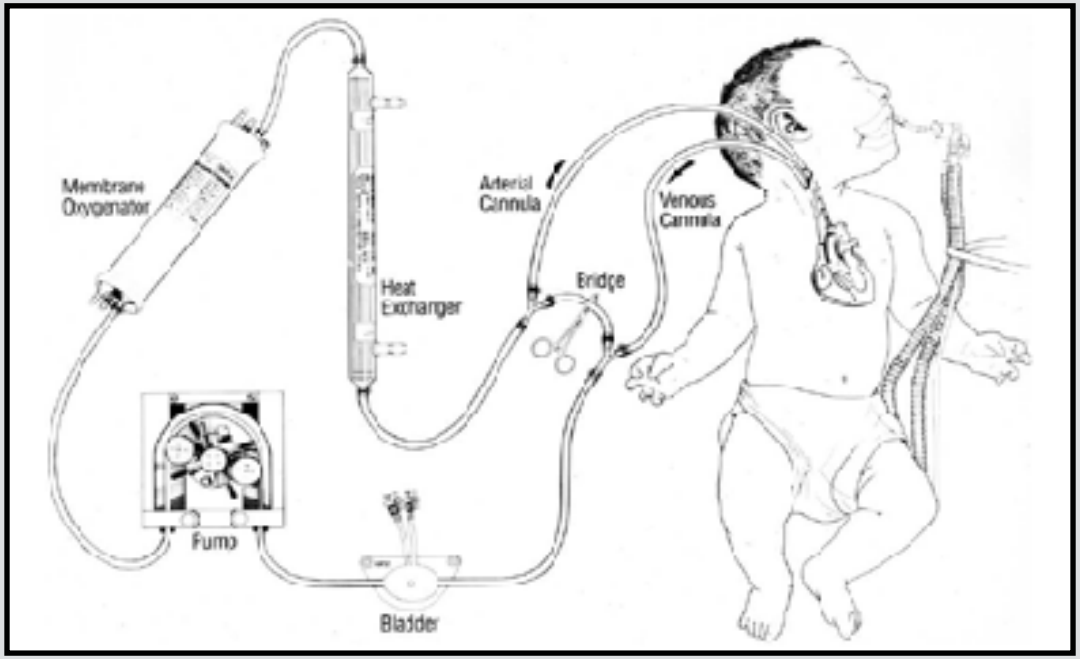

V-V ECMO support respiratoire

Les Assistances Circulatoires

- ECMO VV
  - Jugulaire unique
  - Jugulo-fémorale
- ECMO VA
  - Jugulo-carotidienne
  - Fémoro-fémorale
  - Centrale OD/Ao

Indications de l'ECMO

1) Défaillance post-cardiotomie
   - Dysfonction myocardiaque pré-opératoire (ALCAPA, hypoVG, TGV vieillie)
   - Dysfonction myocardiaque post-opératoire (clampage Ao prolongé, cardioprotection, dysfct VD, lésion résiduelle)
   - Post-transplantation
2) Défaillance circulatoire « médicale »
   - Myocardite, décompensation CMD
   - Intoxication médicamenteuse
   - Arythmies réfractaires
   - ACR
   - Hypoxémie et CHD

Contre-indications de l'ECMO

- Réanimation cardio-pulmonaire prolongée (+de 5 à 30 min dans les recommandations de l'ECLSO)
- Cardiopathie irréversible inopérable
- Atteinte neurologique sévère (acquise ou congénitale)
- Saignement actif important
- Terrain (sd polymalformatif, trisomie 18...)
- Nouveau né - de 2kg / - de 35 SA
- Canulation impossible sur un patient en arrêt

THE JOURNAL OF PEDIATRICS • www.jpeds.com

ORIGINAL ARTICLES

Should Extracorporeal Membrane Oxygenation Be Offered? An International Survey

Kevin W. Kuo, MD[1], Ryan P. Barbaro, MD[1], Samir K. Gadepalli, MD[2], Matthew M. Davis, MD[3], Robert H. Bartlett, MD[2], and Folafoluwa O. Odetola, MD[1]

Berlin Heart

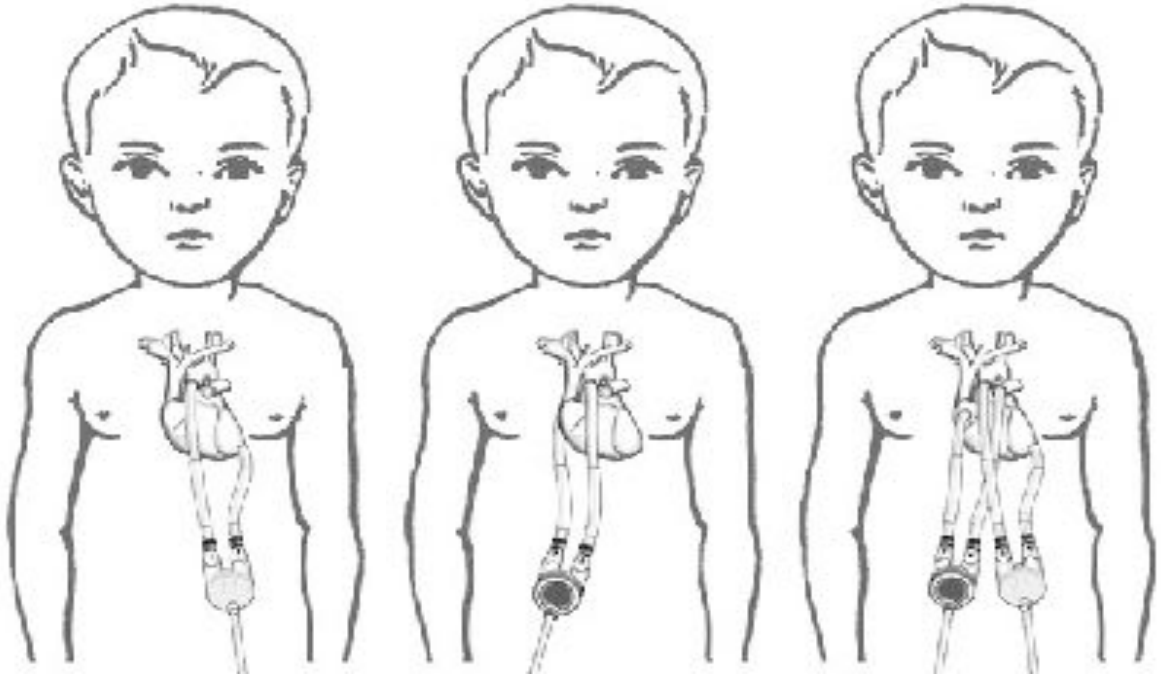

VAD
mono G
VG/Ao

VAD
mono D
OD/AP

biVAD

Berlin Heart

Ventricules de 10 à 80ml : patients de 3kg jusqu’aux adultes



Berlin Heart

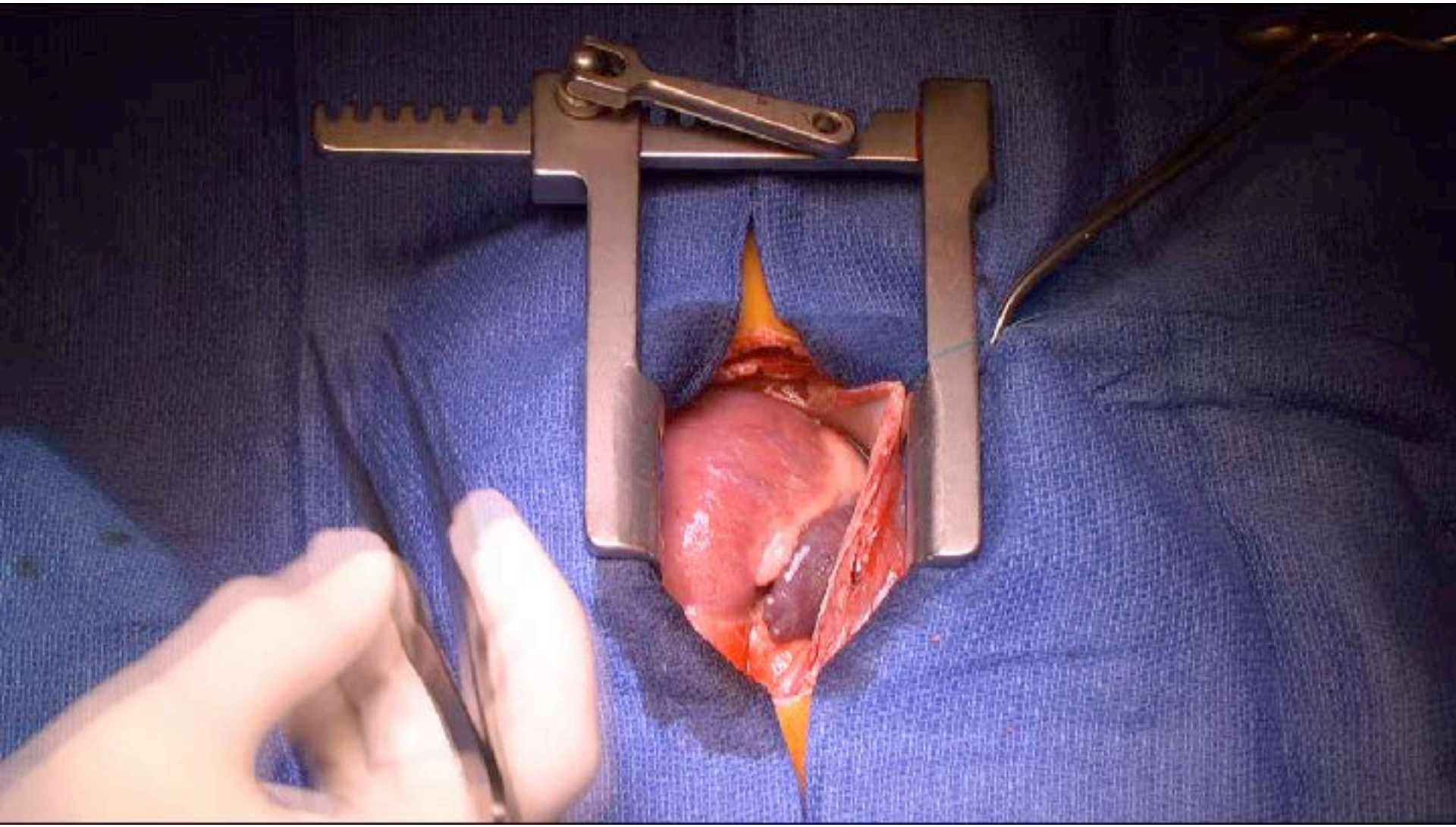

TRANSPLANTATION

Le donneur idéal

- Age < 40-50 ans
- Pas de tabac ou <10-20 PA
- Pas d'ATCD de néoplasie, traumatisme thoracique, chirurgie cardio-thoracique
- Distance (ischémie)

CŒUR

- Pas ou peu d'amines
- Pas ou peu de troponine
- ETT normale
- Coronaires saines

POUMONS

- P/F > 300
- Intubation < 24h
- Fibro normale
- Imagerie thoracique normale

Choix du greffon : selon le patient

- Groupe sanguin
- CMV et EBV
- Antigènes interdits

CŒUR

- Morphologie – Poids
- Indication - Poids

POUMONS

- Taille - CPT
- Indication – CPT

Taille (m)	T.C	T.C
1.10	1.5	1.5
1.12	1.7	1.5
1.14	1.7	1.7
1.16	1.8	1.7
1.18	1.8	1.8
1.20	2.0	1.8
1.22	2.1	2.0
1.24	2.2	2.1
1.26	2.3	2.2
1.28	2.4	2.3
1.30	2.5	2.4
1.32	2.6	2.5
1.34	2.7	2.6
1.36	2.8	2.7
1.38	2.9	2.8
1.40	3.1	2.9
1.42	3.2	3.0
1.44	3.3	3.1
1.46	3.4	3.3
1.48	3.5	3.4
1.50	3.7	3.5
1.52	3.8	3.6
1.54	4.0	3.7
1.56	4.1	3.9
1.58	4.2	4.0
1.60	4.4	4.1
1.62	4.5	4.3
1.64	4.7	4.5
1.66	4.8	4.5
1.68	5.0	4.3

Technique : PMO

- Préparation étage abdominal
- Préparation étage thoracique
- Canulations
- Clampage
- Décharges
- Explantation cardiaque
- Explantation pulmonaire
- Explantation hépatique
- Explantation rénale

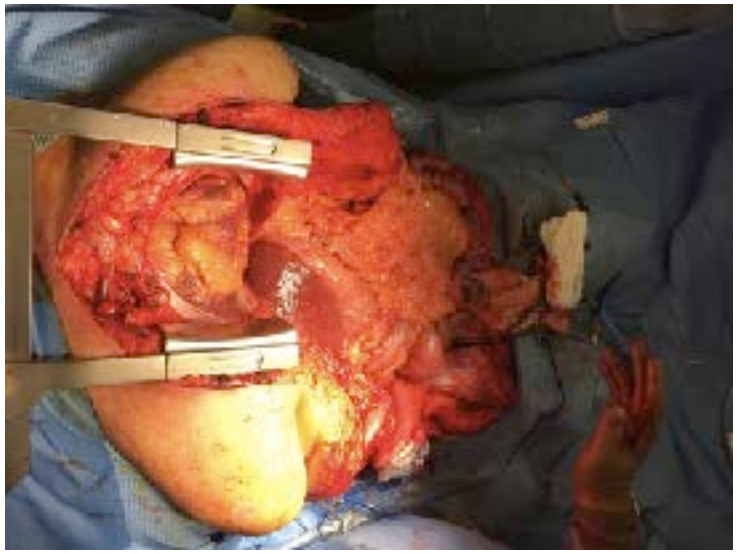

Technique : PMO coeur

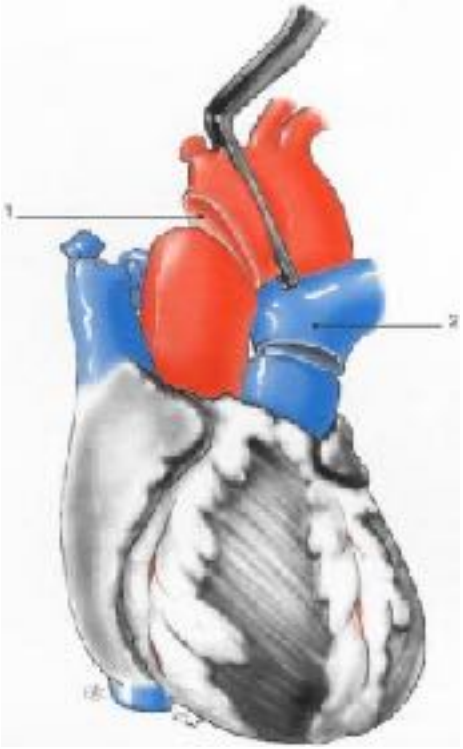

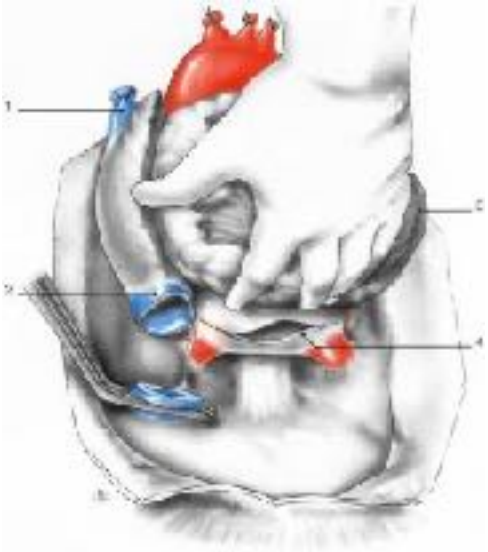

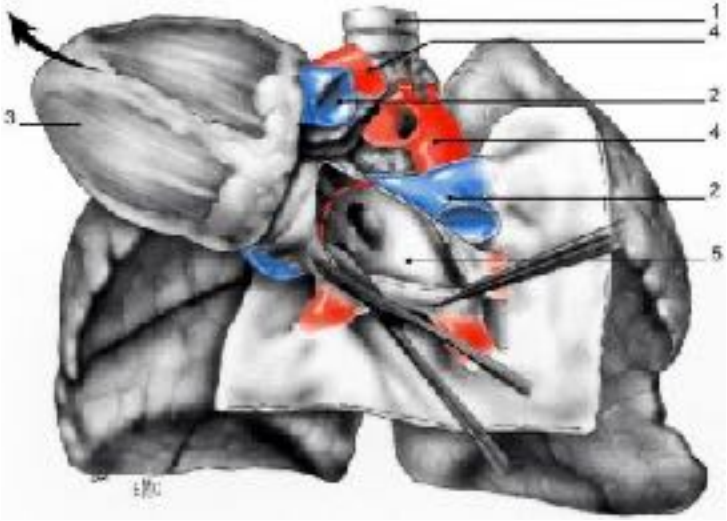

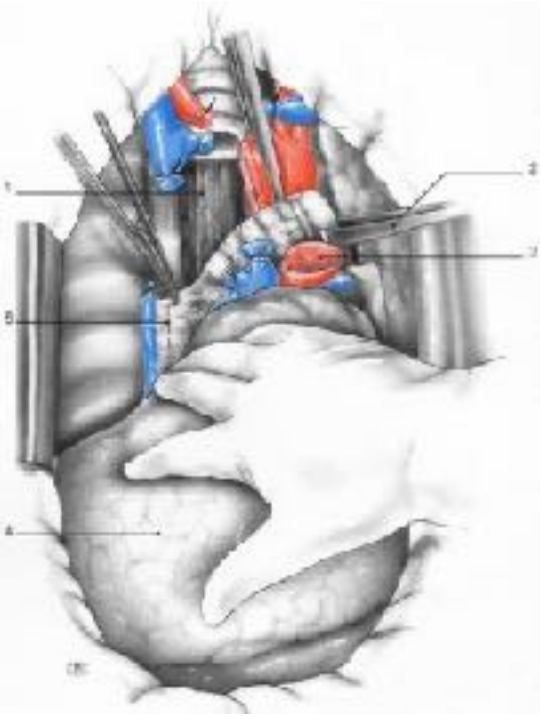

Tx cardiaque : explantation

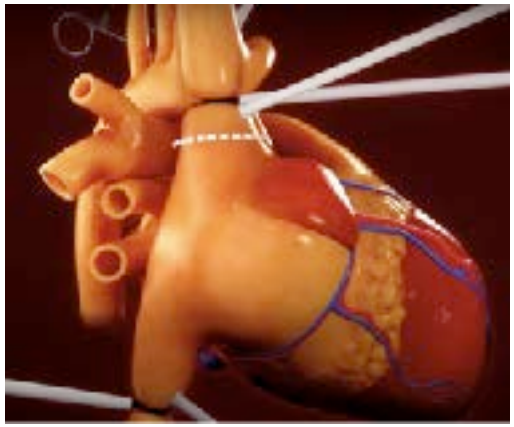

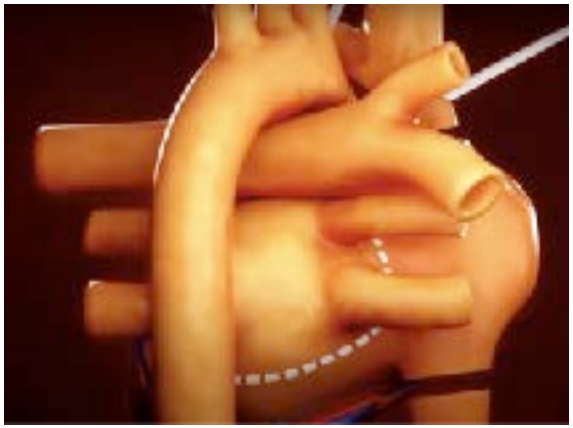

https://www.youtube.com/watch?v=VGZRMHA4ics

Tx cardiaque : implantation

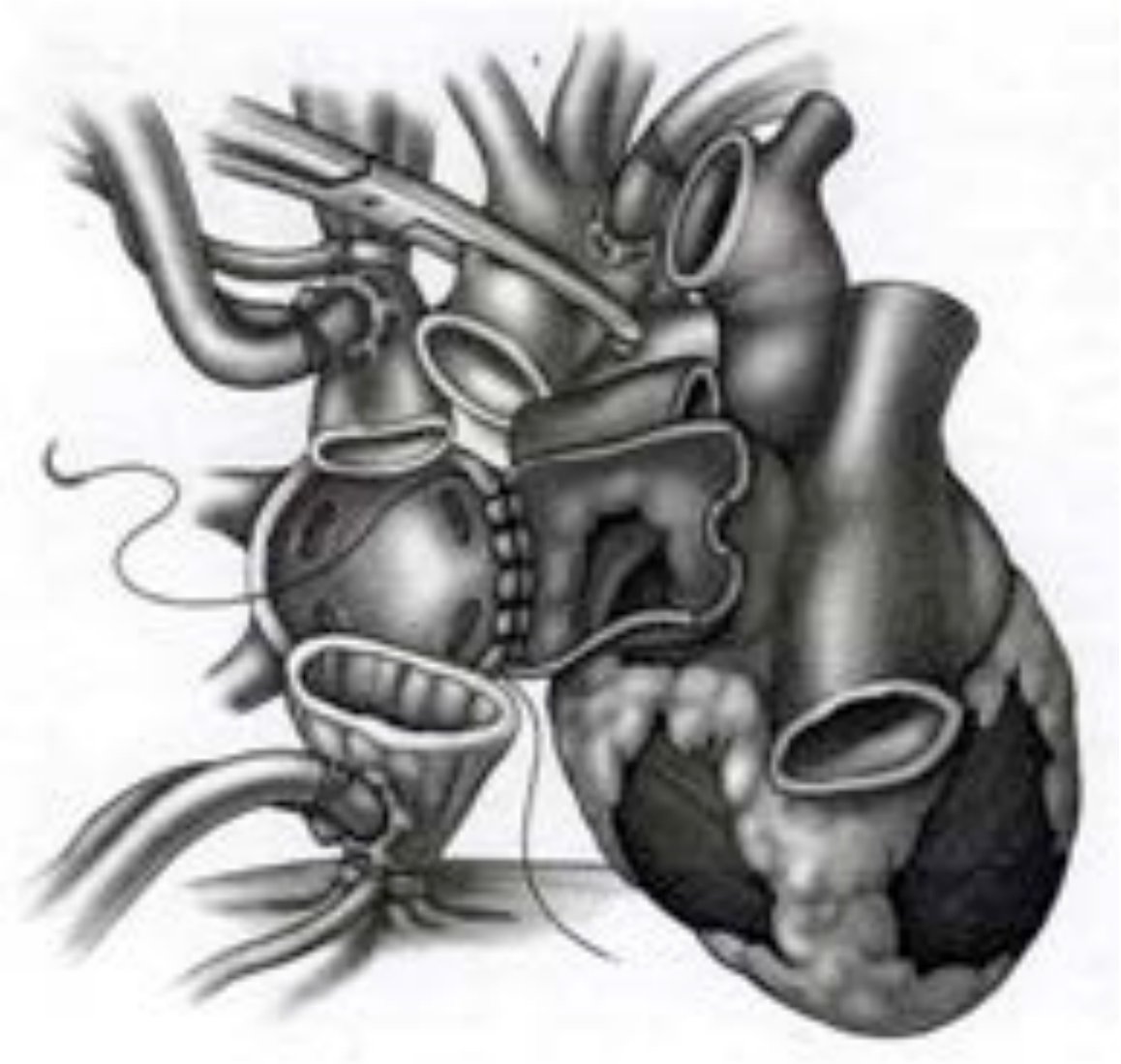

Tx cardiaque

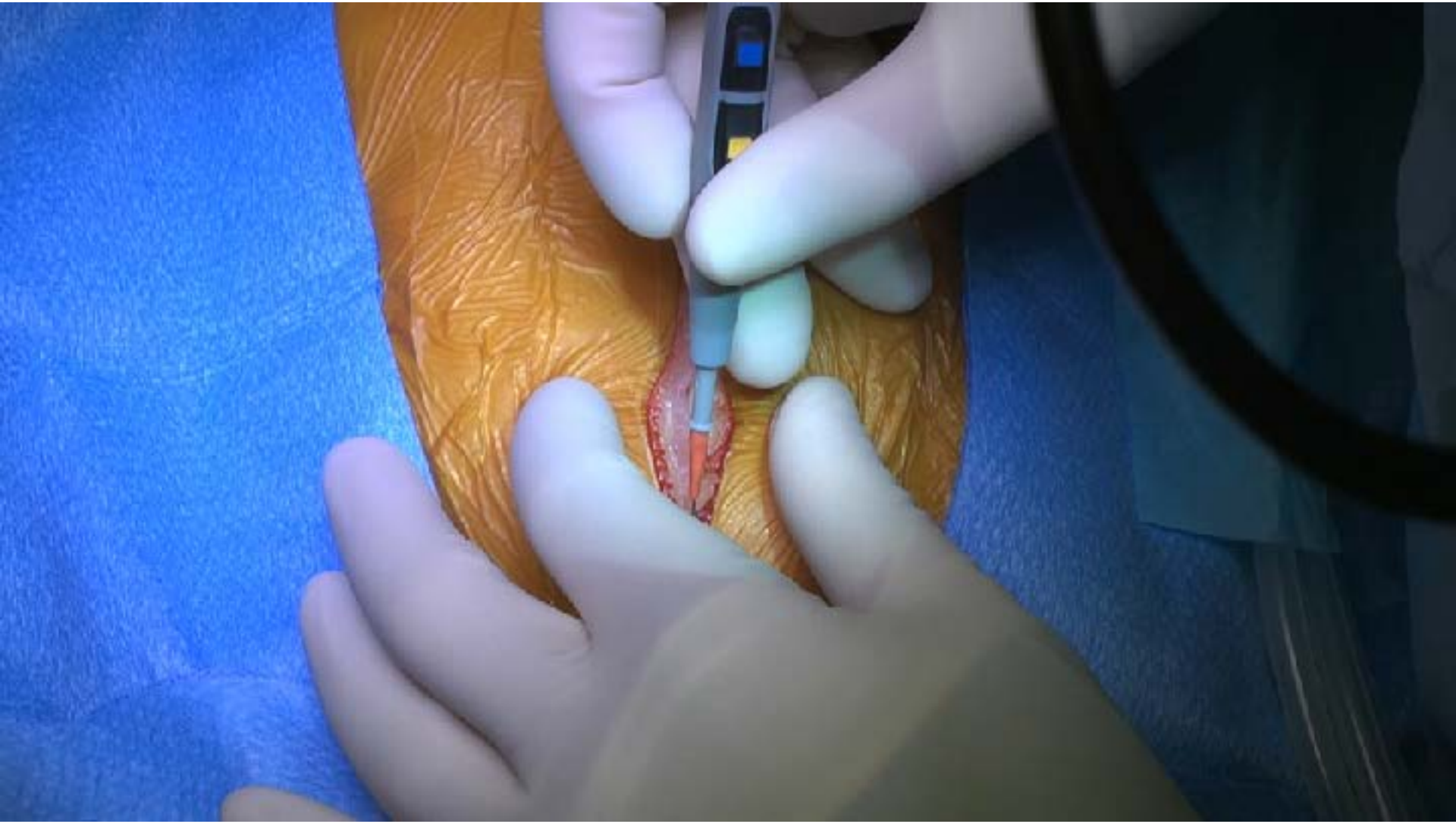

Tx cardiaque : survie

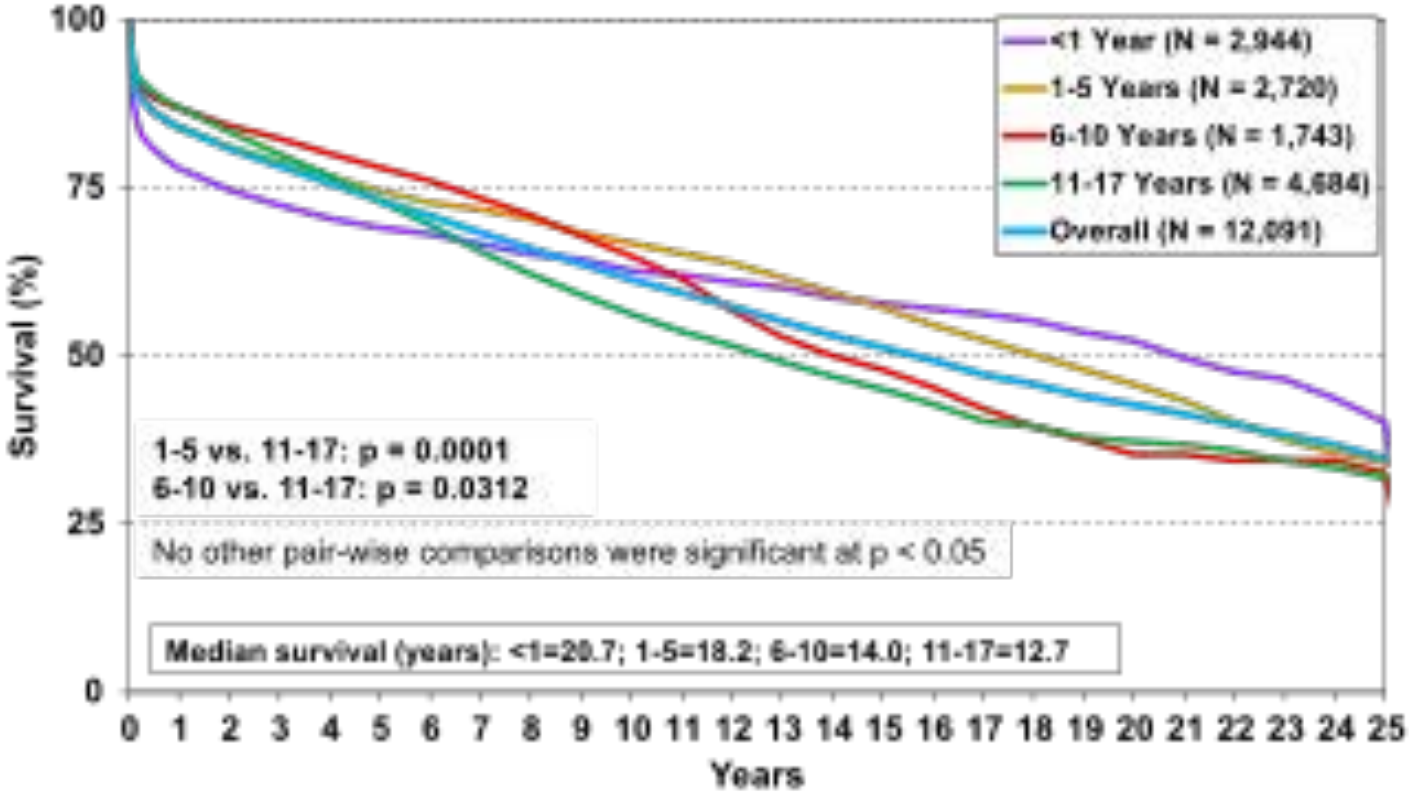

Médiane de survie de 15 ans

2016. Rossano. ISHLT

Merci de votre attention
margaux.pontailler@aphp.fr