



Coronary pathology in children

Damien Bonnet

Unité médico-chirurgicale de Cardiologie Congénitale et Pédiatrique
Hôpital Universitaire Necker Enfants malades – AHP, Université Paris Descartes, Sorbonne Paris Cité
IcarP Cardiology, Institut Hospitalo-Universitaire IMAGINE

Centre de Référence Maladies Rares
Malformations Cardiaques Congénitales Complexes-M3C

Centre de Référence Maladies Rares
Maladies Cardiaques Héritaires- CARDIOGEN



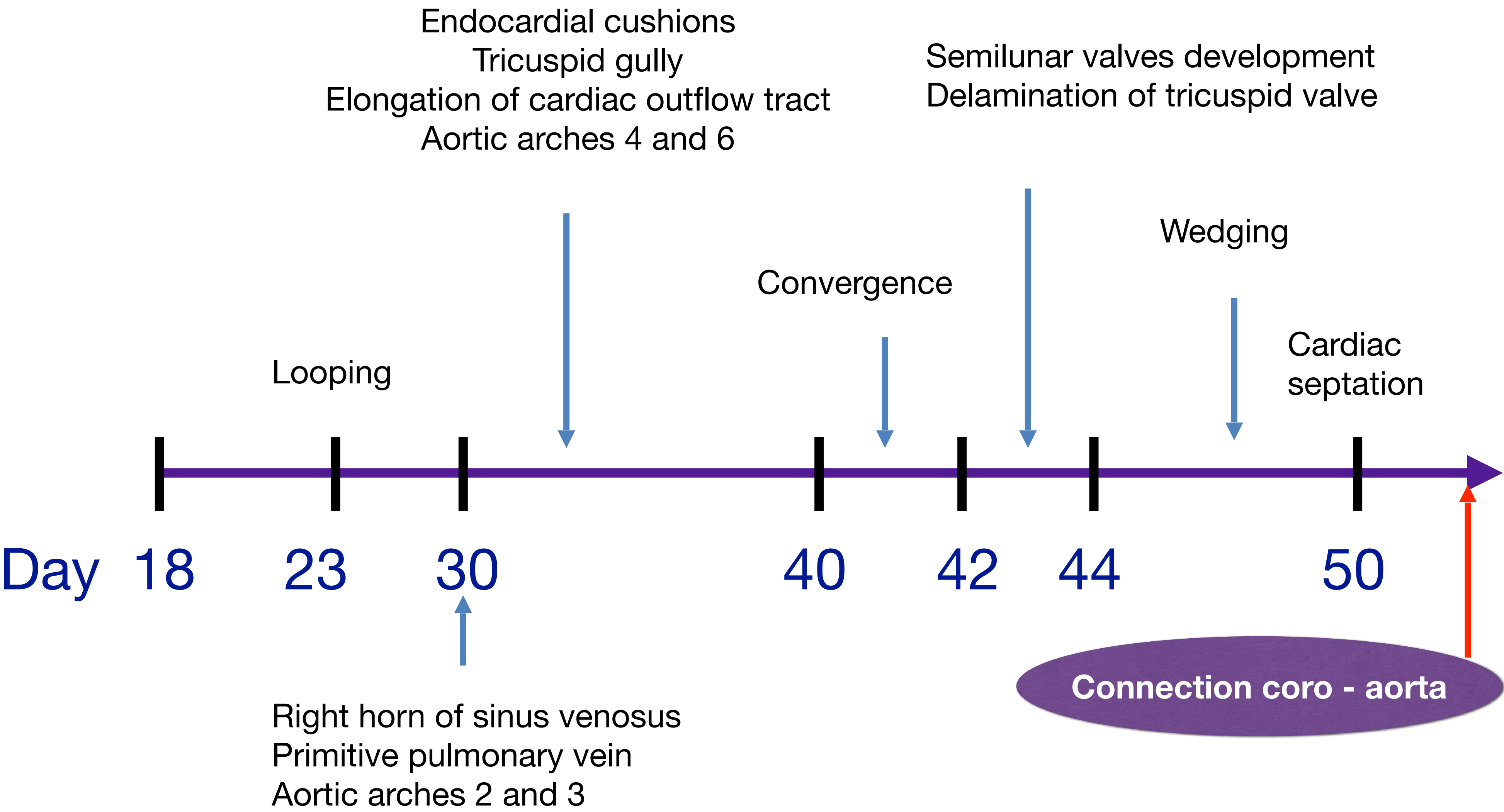
Coronary arteries in animals

« Not everyone has coronary vessels »

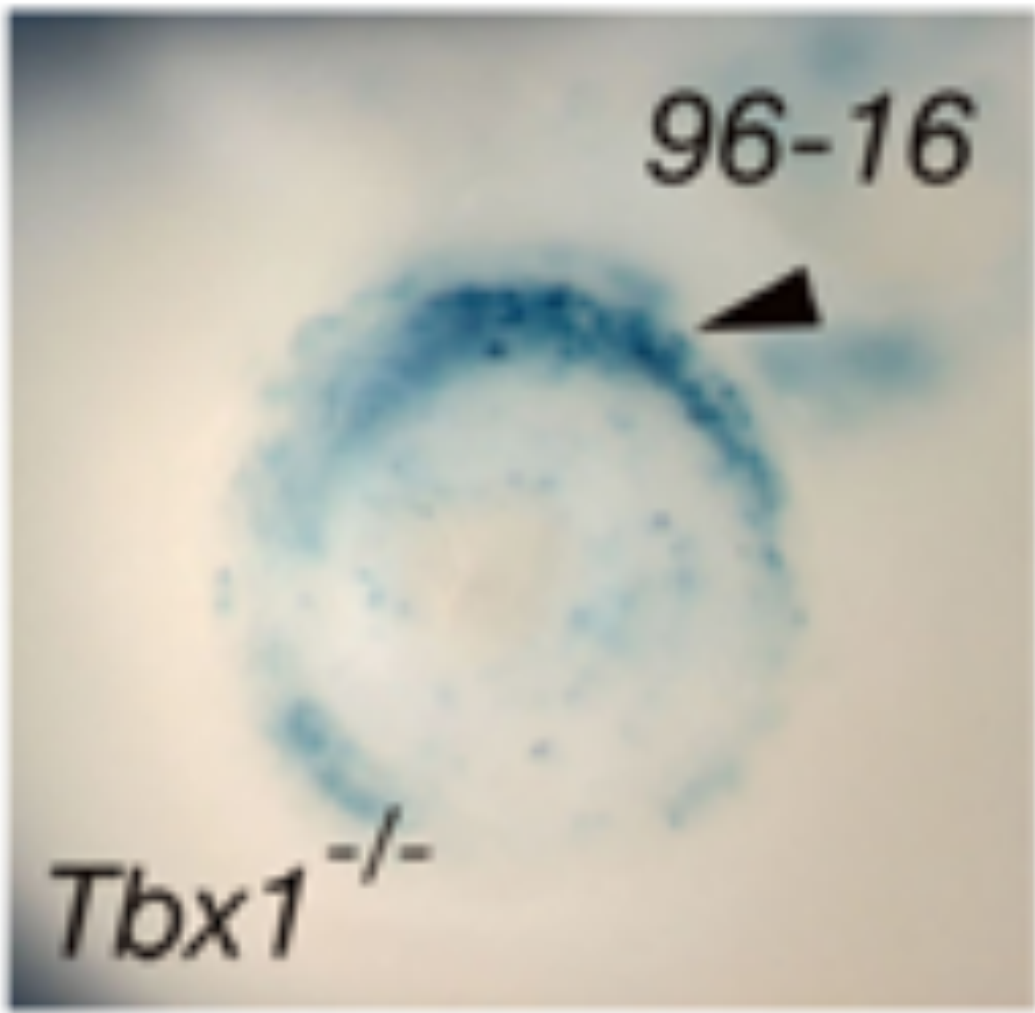
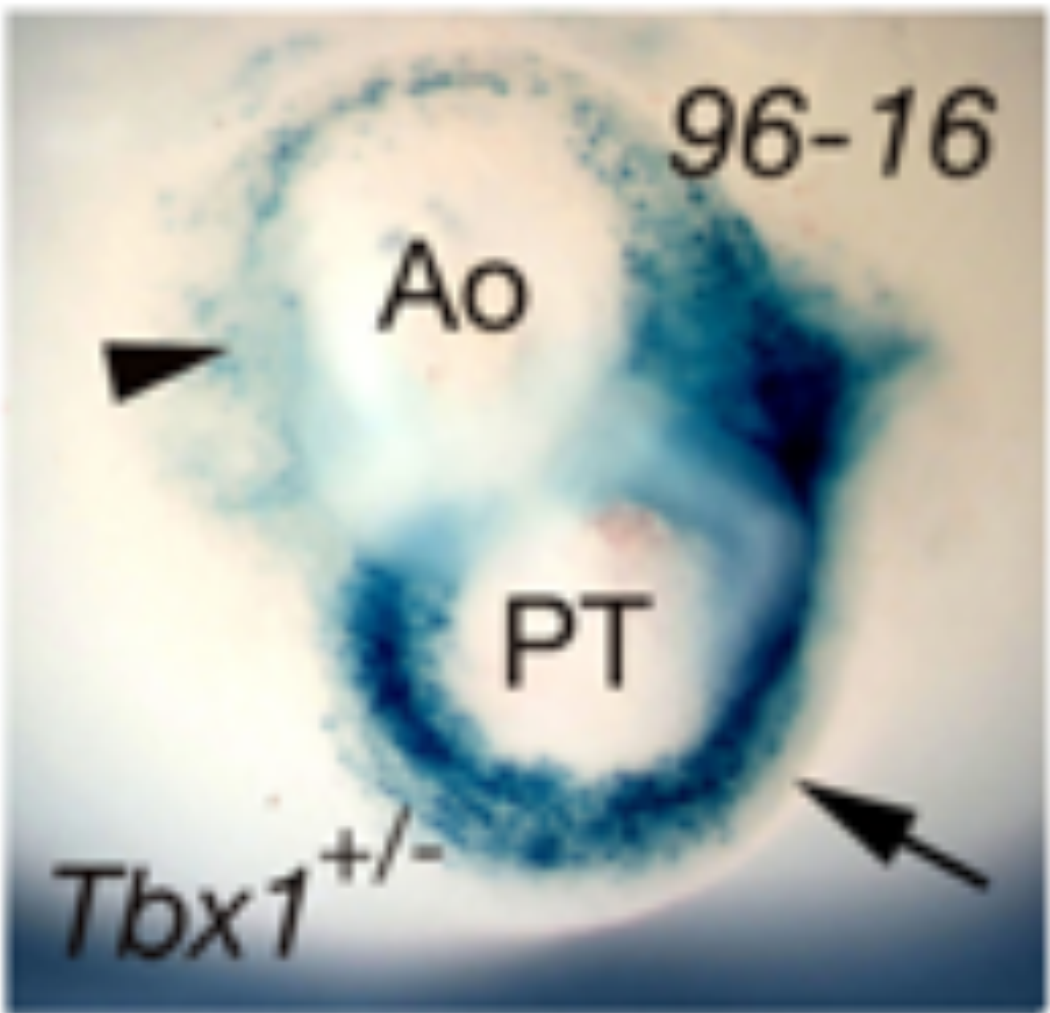
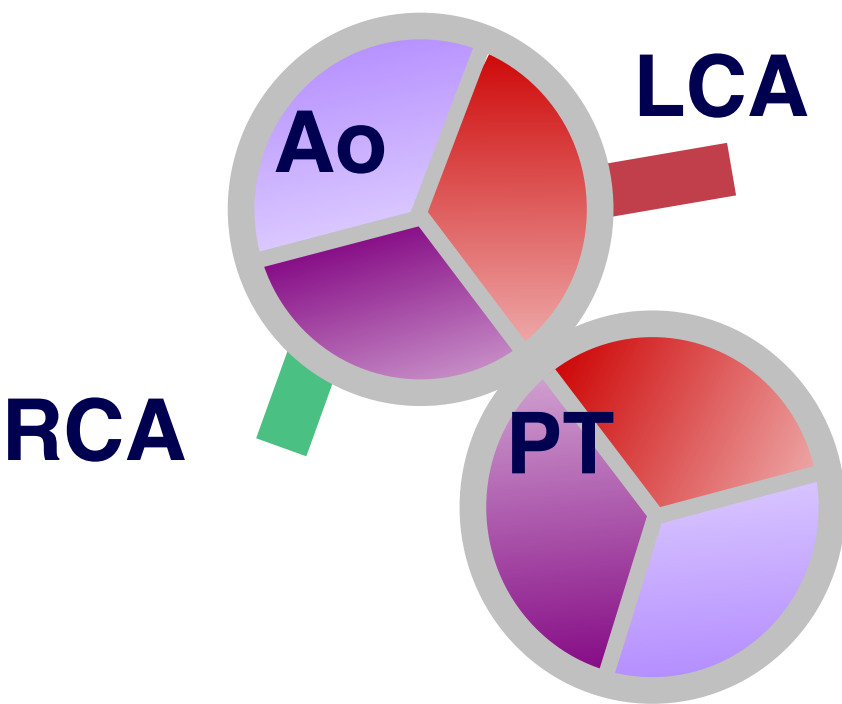
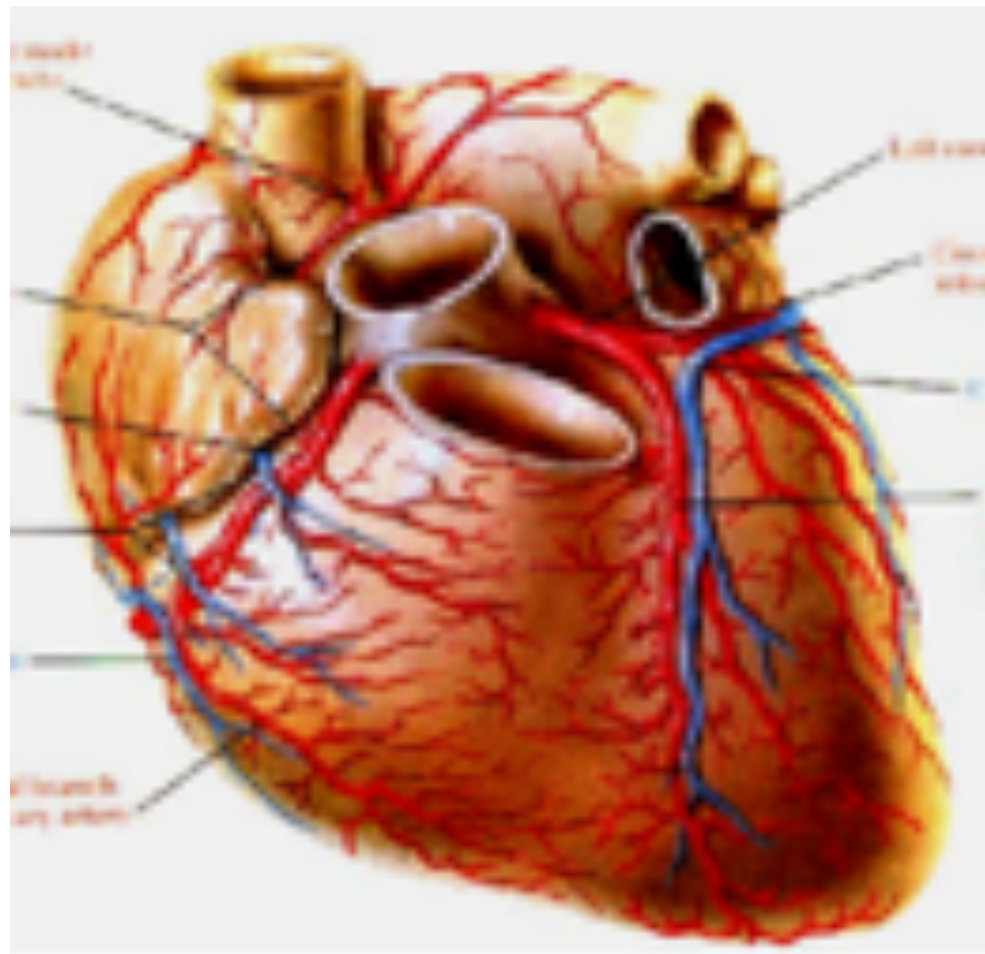
- Invertebrates : no
- Amphibians : no
- Vertebrates : mammals, reptiles, avians : yes
 - common characteristics : pulmonary respiration and no percutaneous respiration
- Fish : coronary arteries only in:
 - Larger, fast-swimming, predatory
 - Living in poorly oxygenated environment



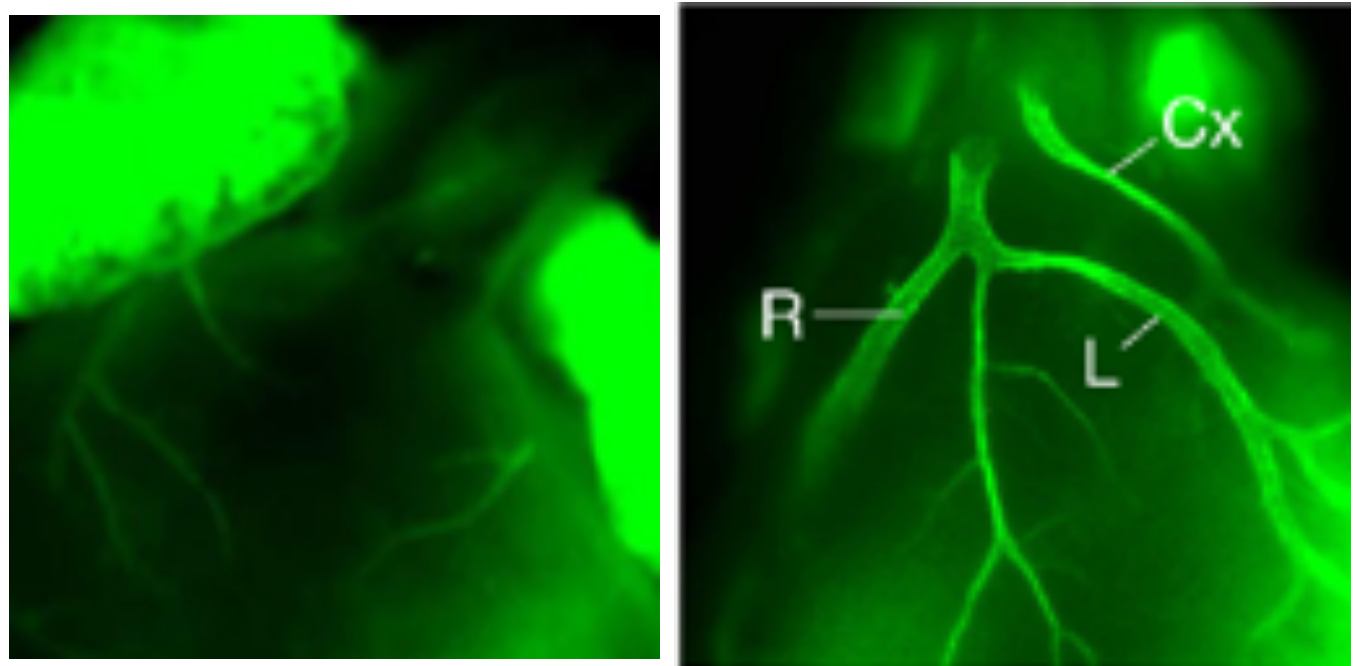
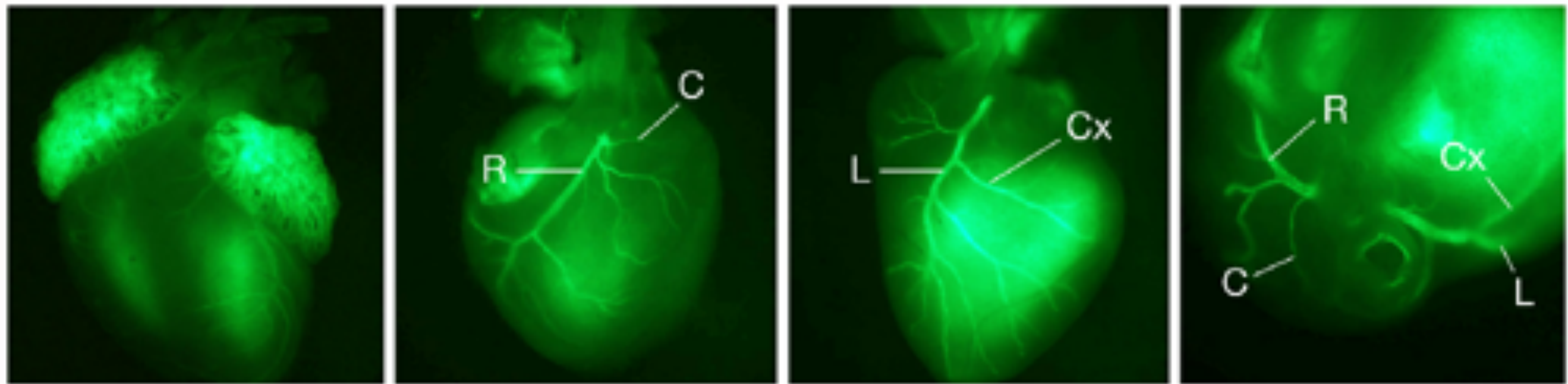
Development of coronary arteries : late event in cardiac morphogenesis



Coronary artery patterning in *Tbx1*^{-/-} hearts




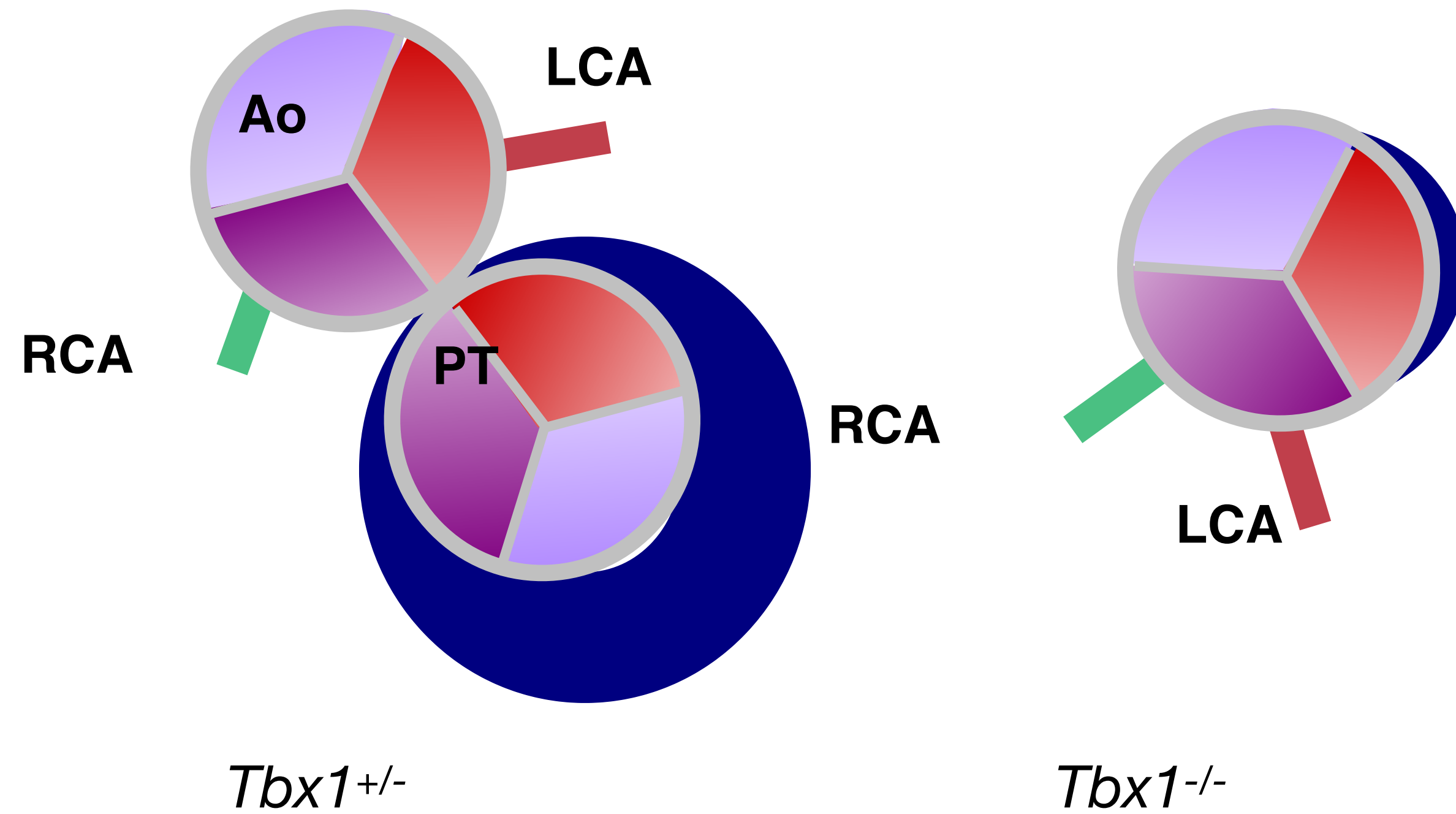
Tbx1^{+/-}
Connexin40
eGFP



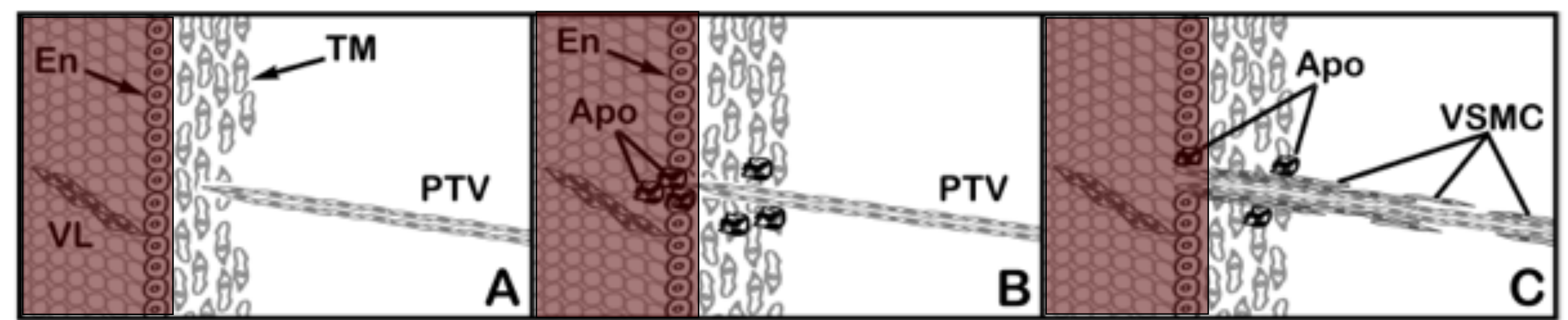
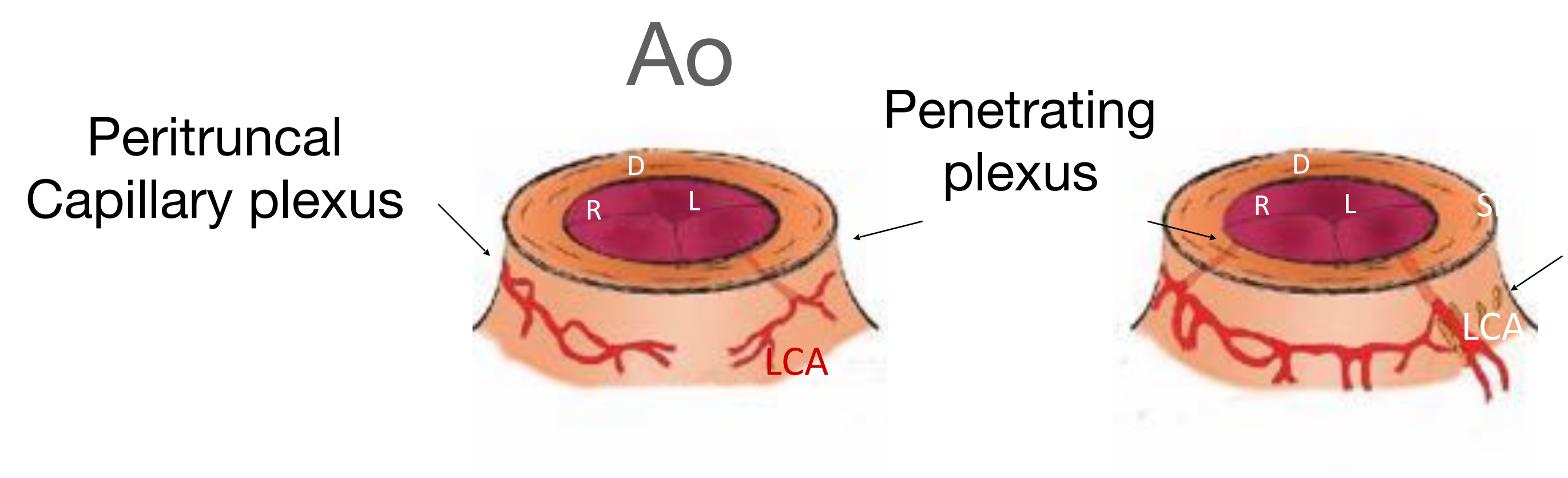
Tbx1^{+/+}

Tbx1^{-/-}

Coronary artery patterning in *Tbx1*^{-/-} hearts



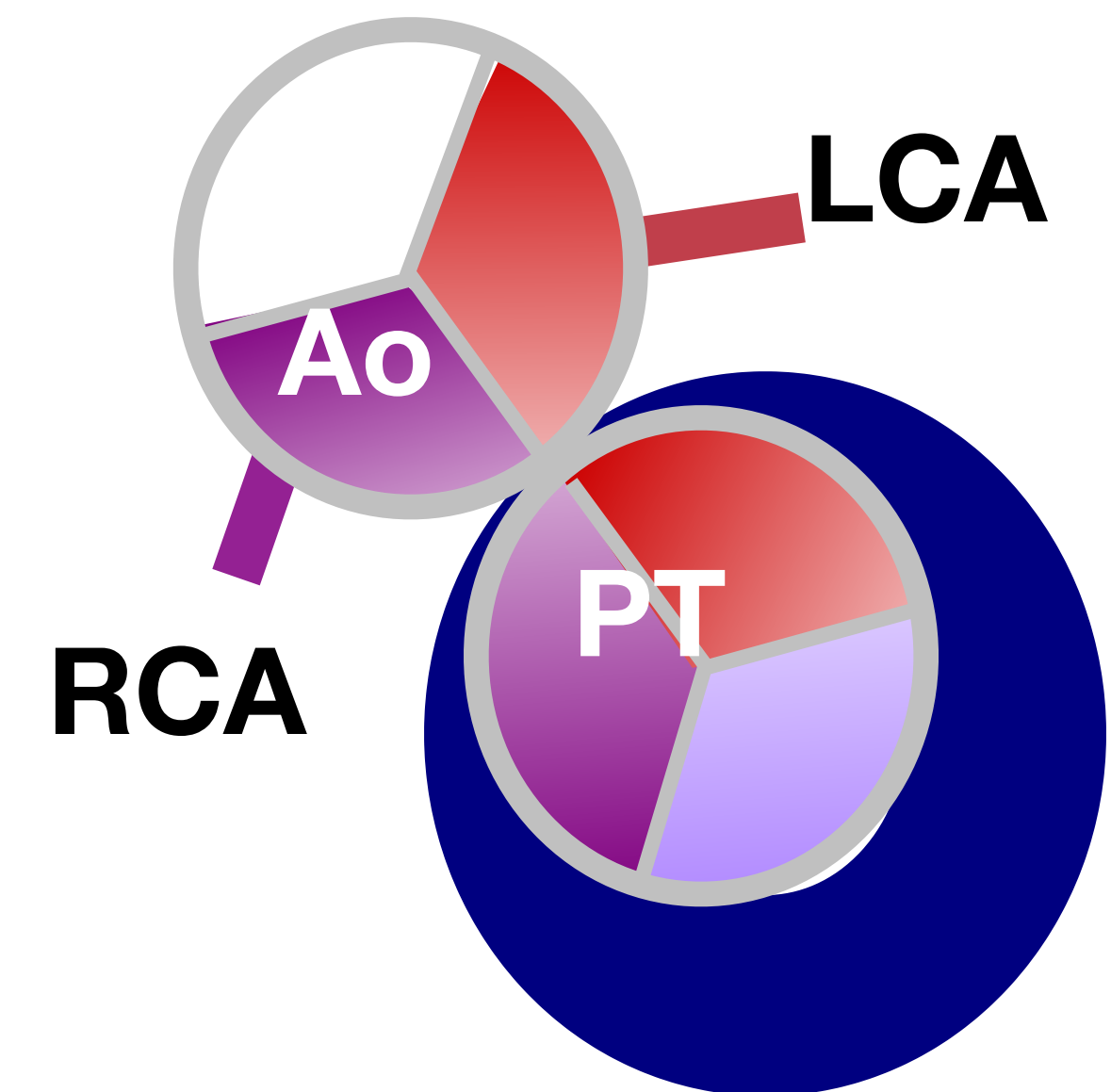
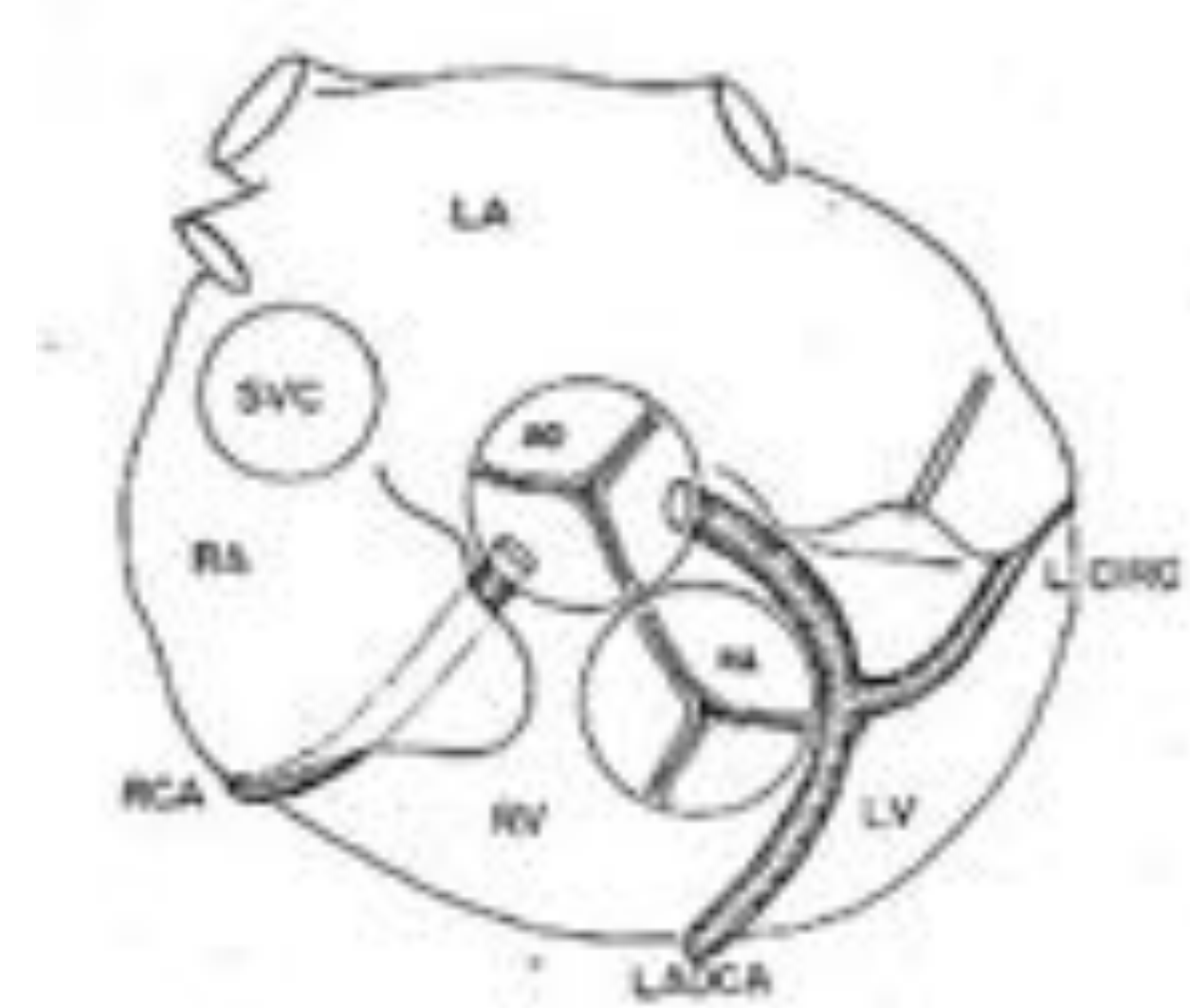
Coronary sinuses are formed via ingrowth of the peritruncal capillary plexus



Hypoxia and apoptosis are correlated with the invasion of the Aorta

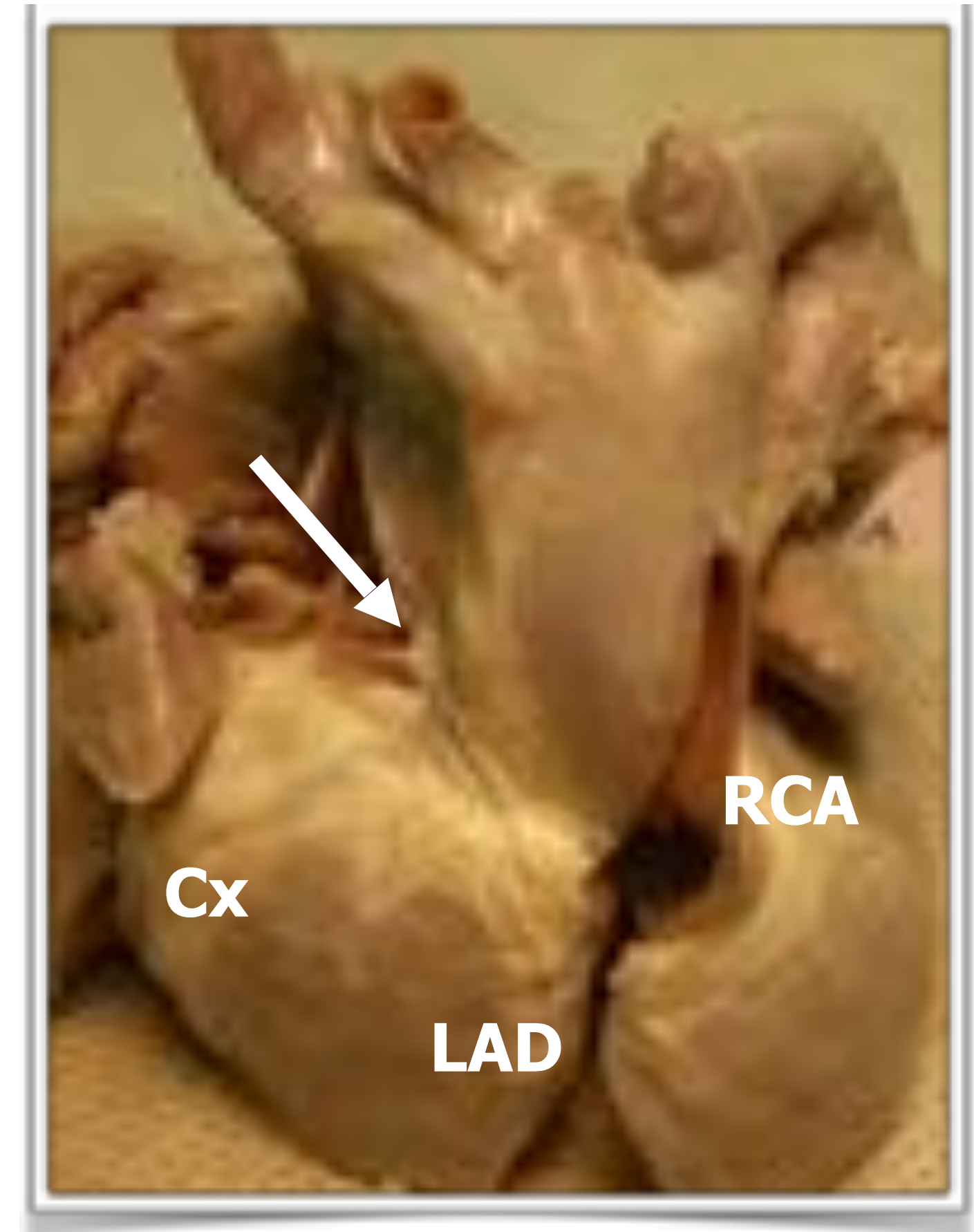
Embryology : the coronary arteries enter the aorta

- The coronary arteries are « attracted » by the aorta (subaortic domain)
- They enter the aorta to the nearest point of their epicardial course
- While avoiding the pulmonary artery (myocardial subpulmonary domain)



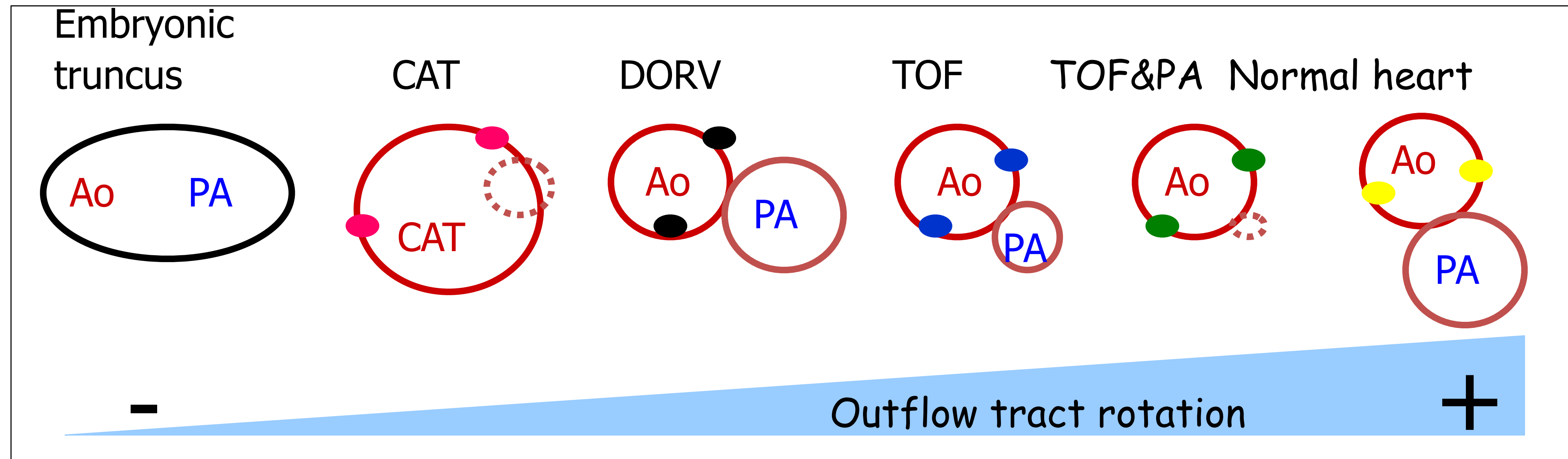
Embryology : coronary artery patterning

- Coronary artery patterning also depends on the underlying ventricle (double discordance)
- L-loop : mirror-imaged coronary arteries



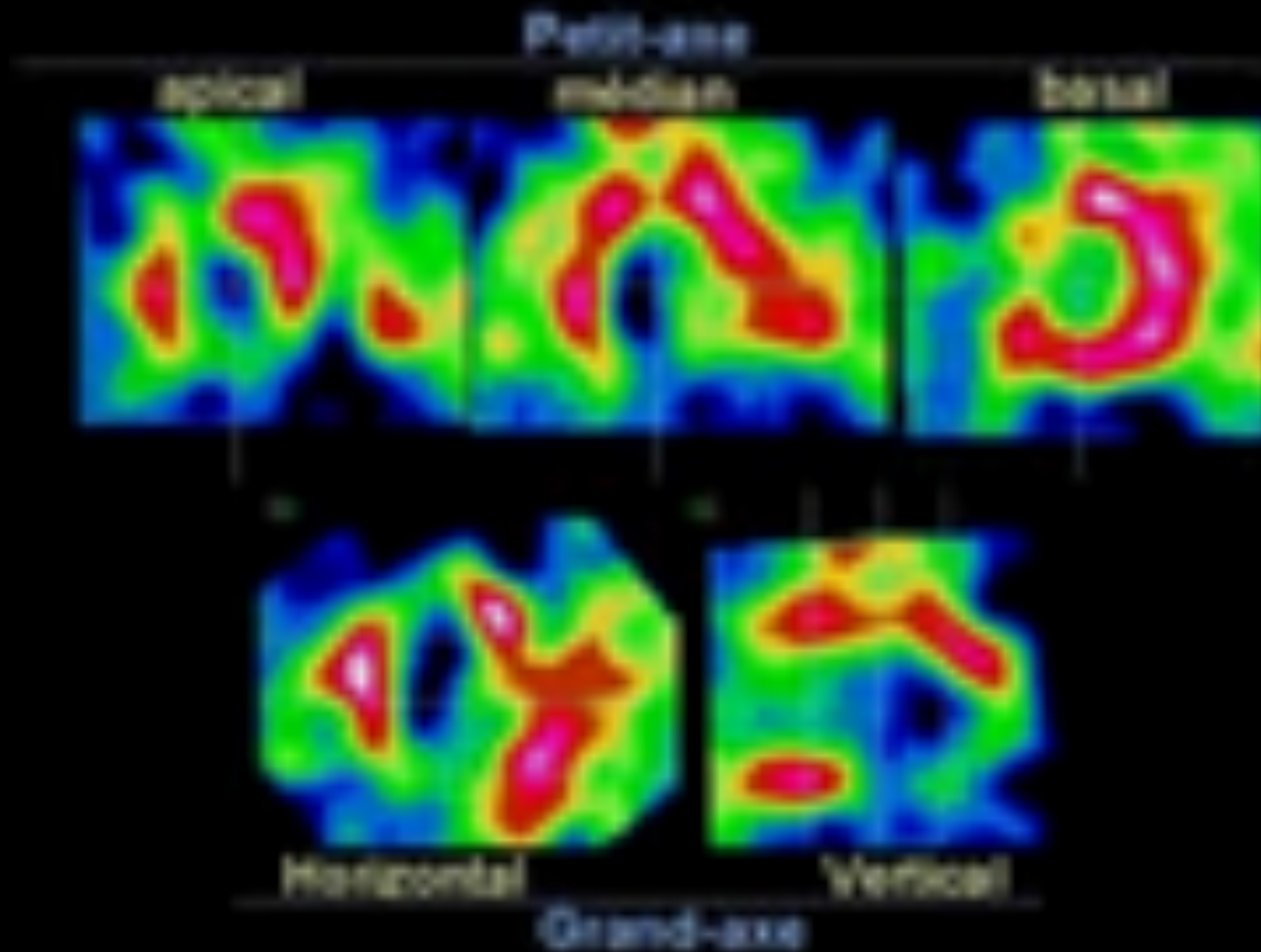
Conotruncal defects

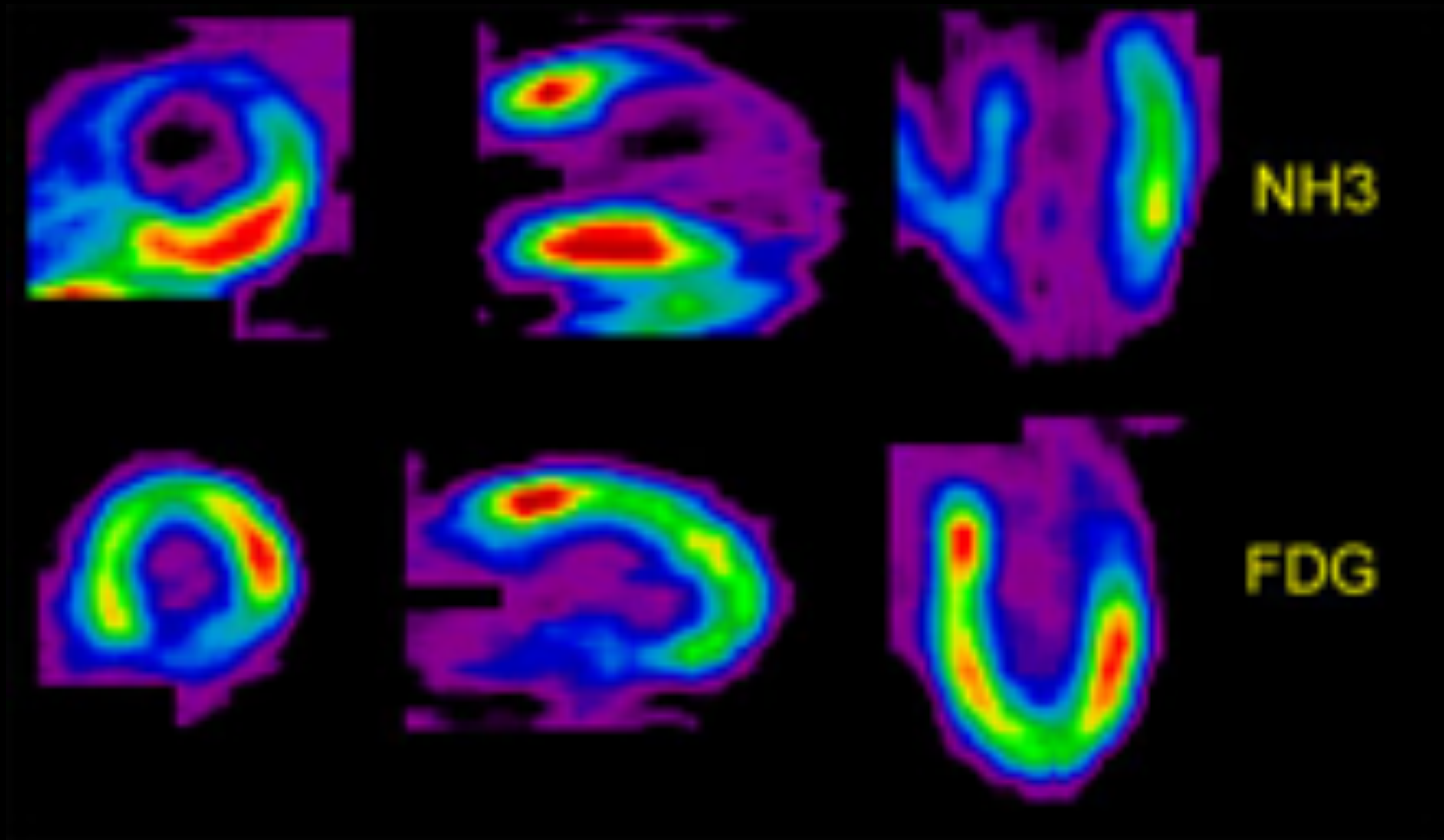
- The location of the coronary ostia depends on the degree of rotation of the outflow tract (which modifies the location of the subpulmonary domain)

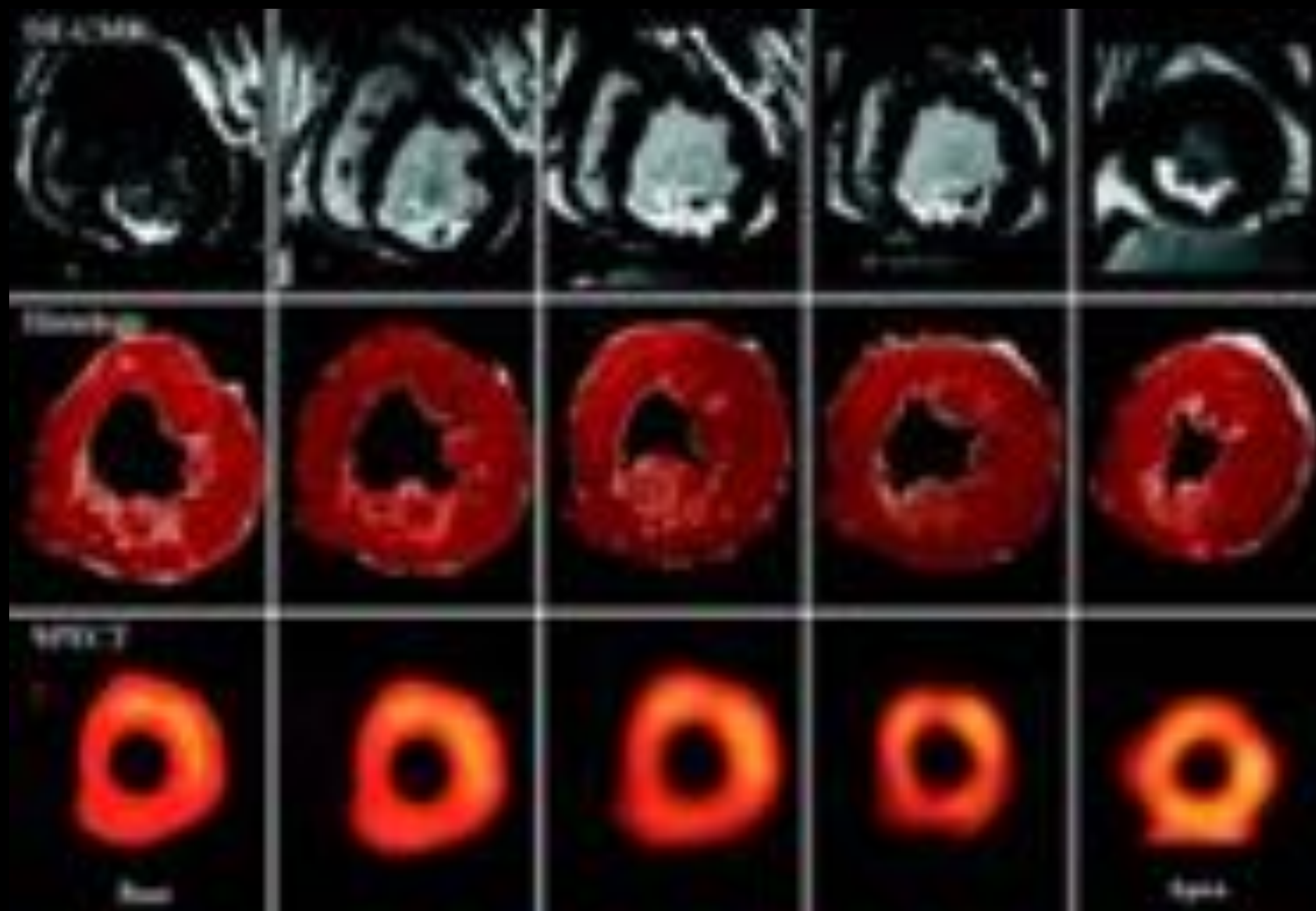


Detection of myocardial ischemia in children

SPECT : Tl-201 effort







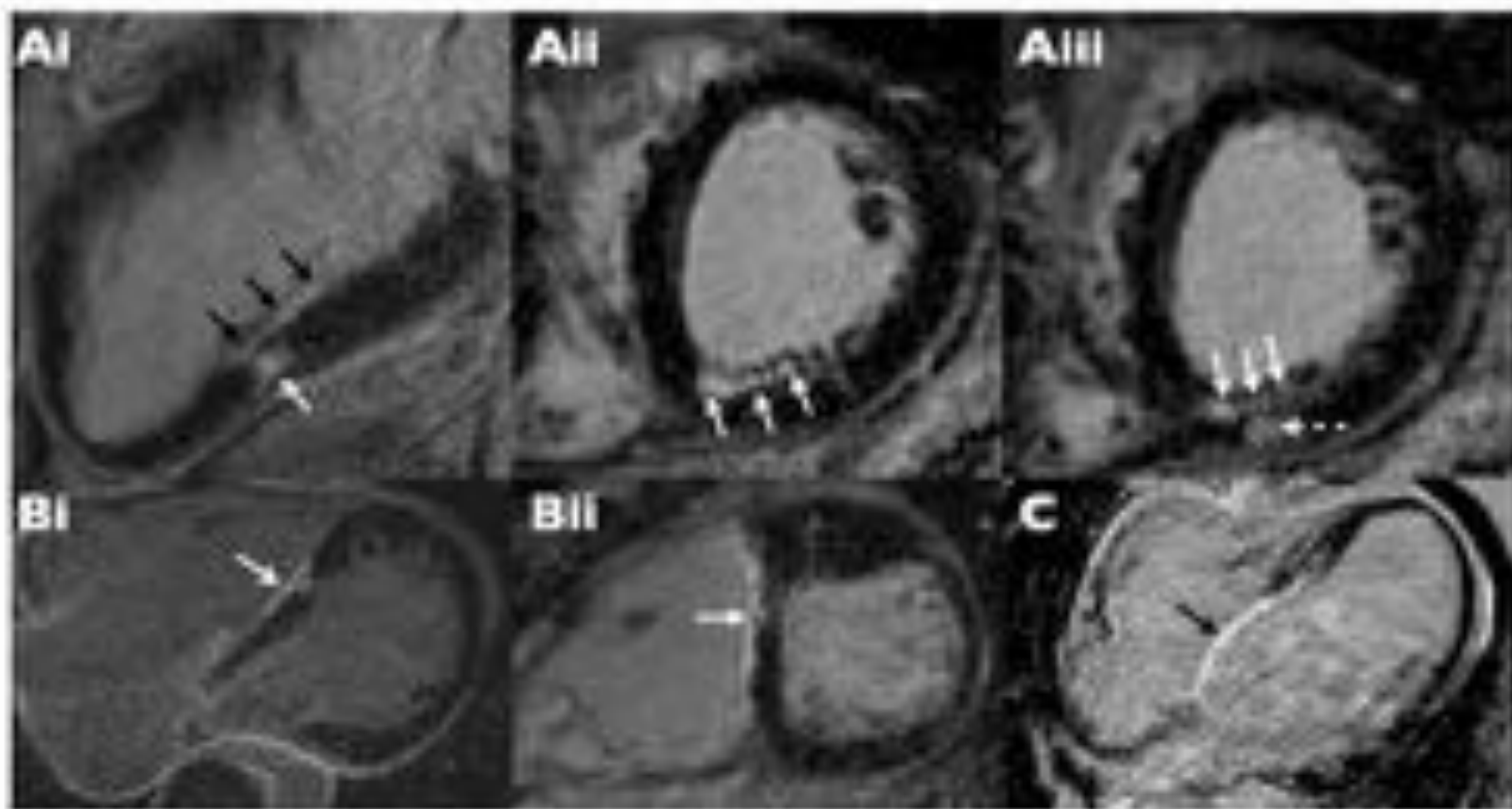
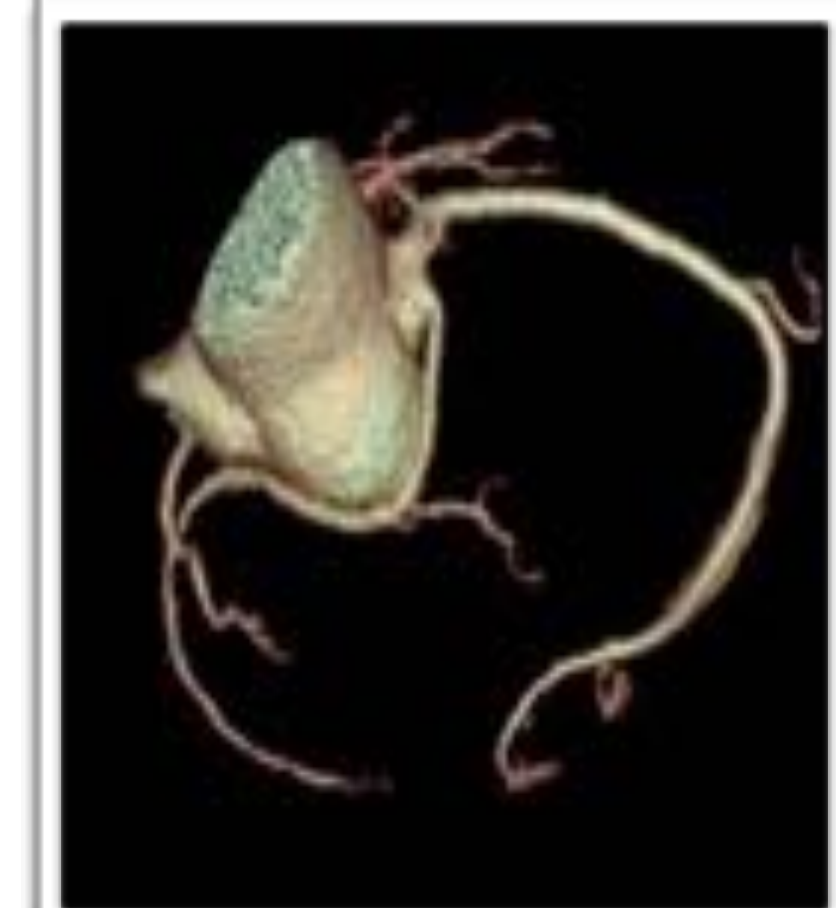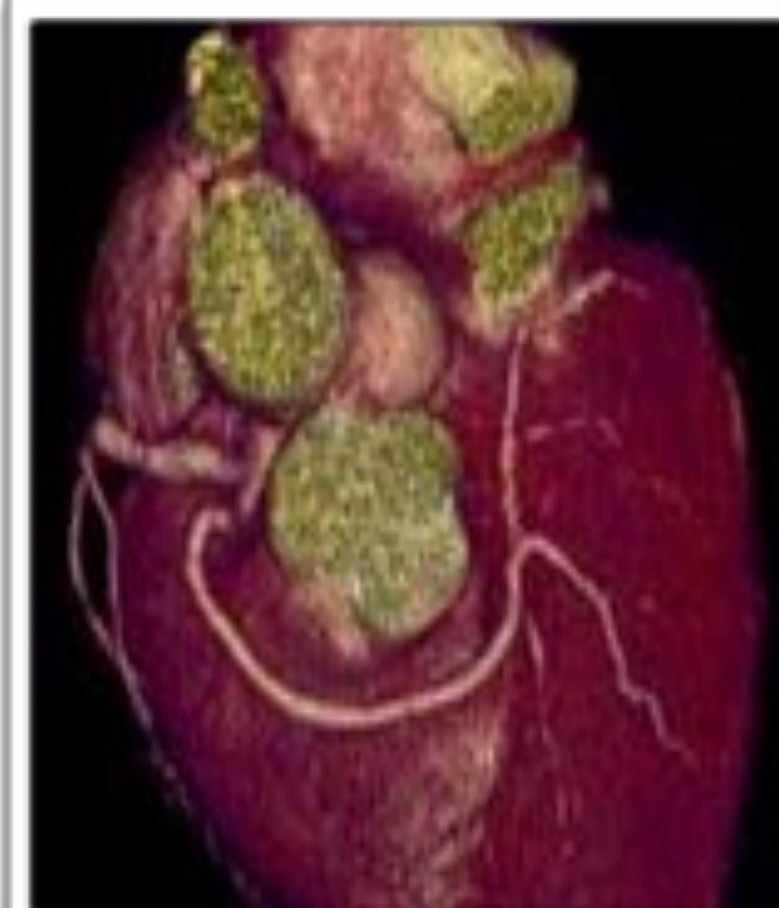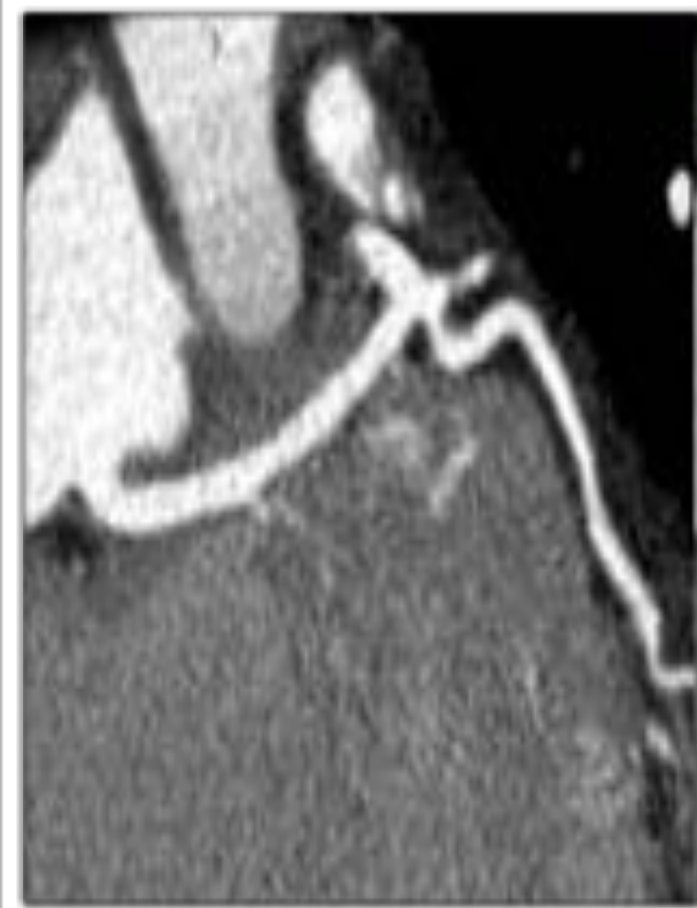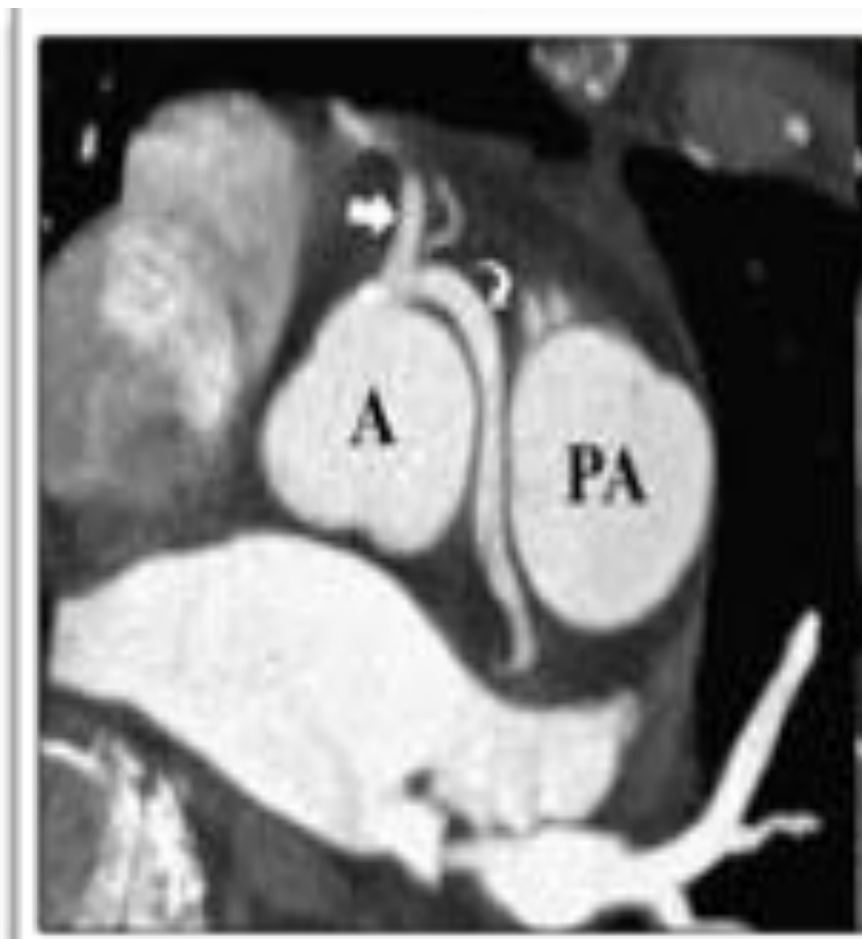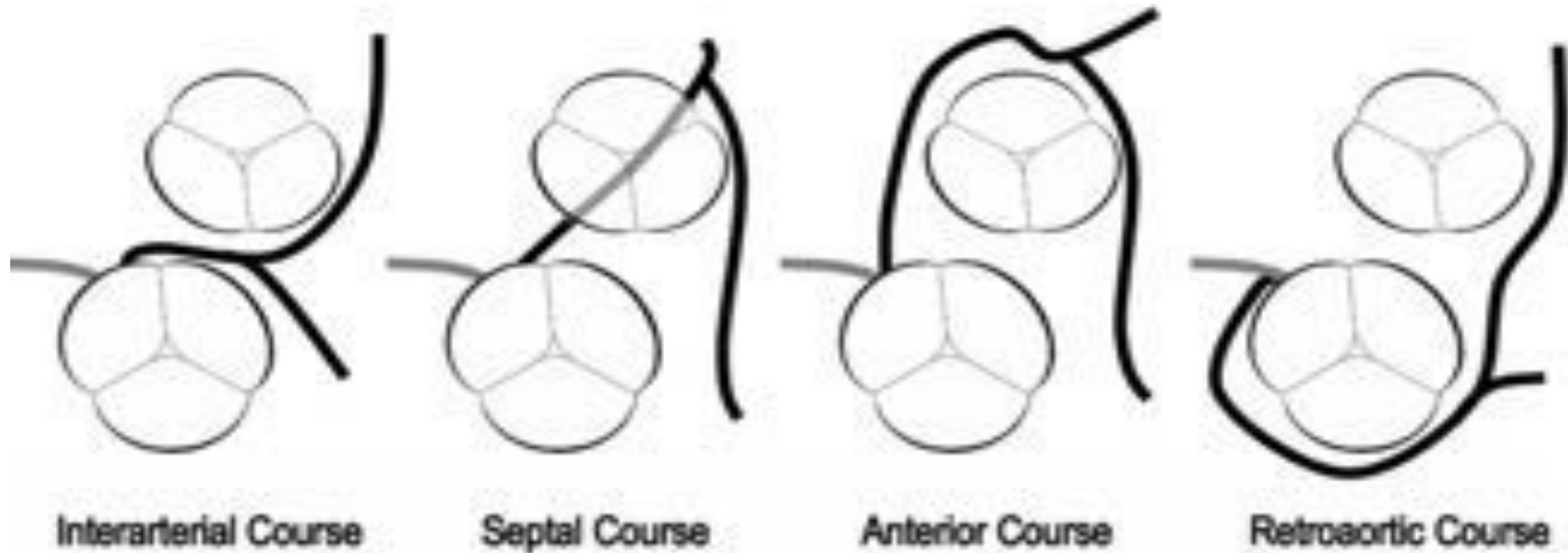


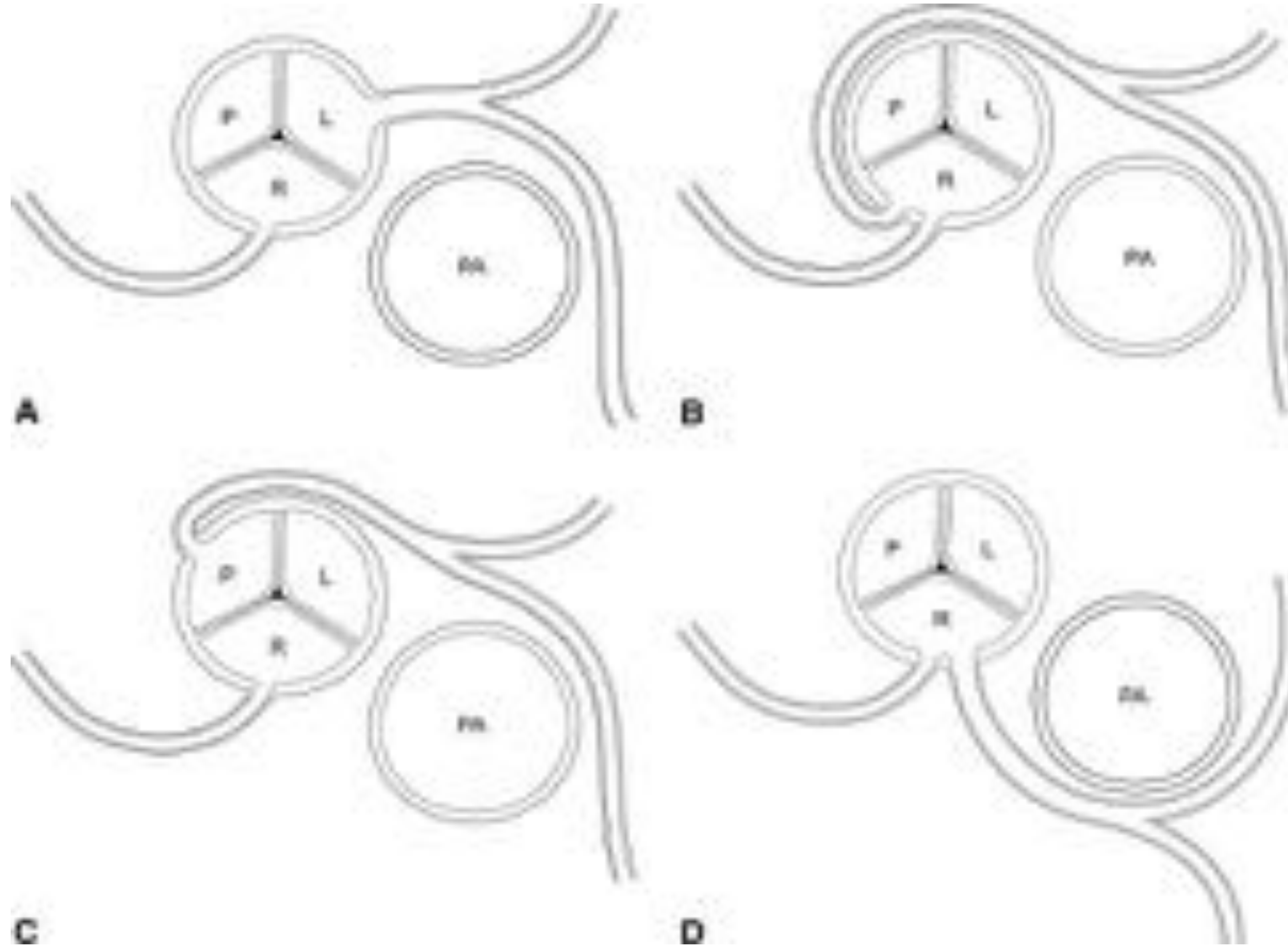
Figure 2 Real and "pseudo-real" late gadolinium enhancement (LGE) in 3 patients with positive LGE studies. (A-I) Converse LGE is evident in the mid-myocardial wall in the 2-chamber view (A I) with both short (black arrow) and long (gray) white arrow enhancement. Confirmation of these findings is provided by short and long axis through the septum, which also show subendocardial (white arrow) and midwall-myocardial (black arrow) myocardial layer. (B-I) The short LGE (white arrow) is present at the site of ventricular septal defect (VSD) region shown in 4-chamber (B) and short axis (B II) views. (C) The short LGE (black arrow) extends in a large septal perforator for VSD repair.

Abnormal epicardial course of coronary arteries

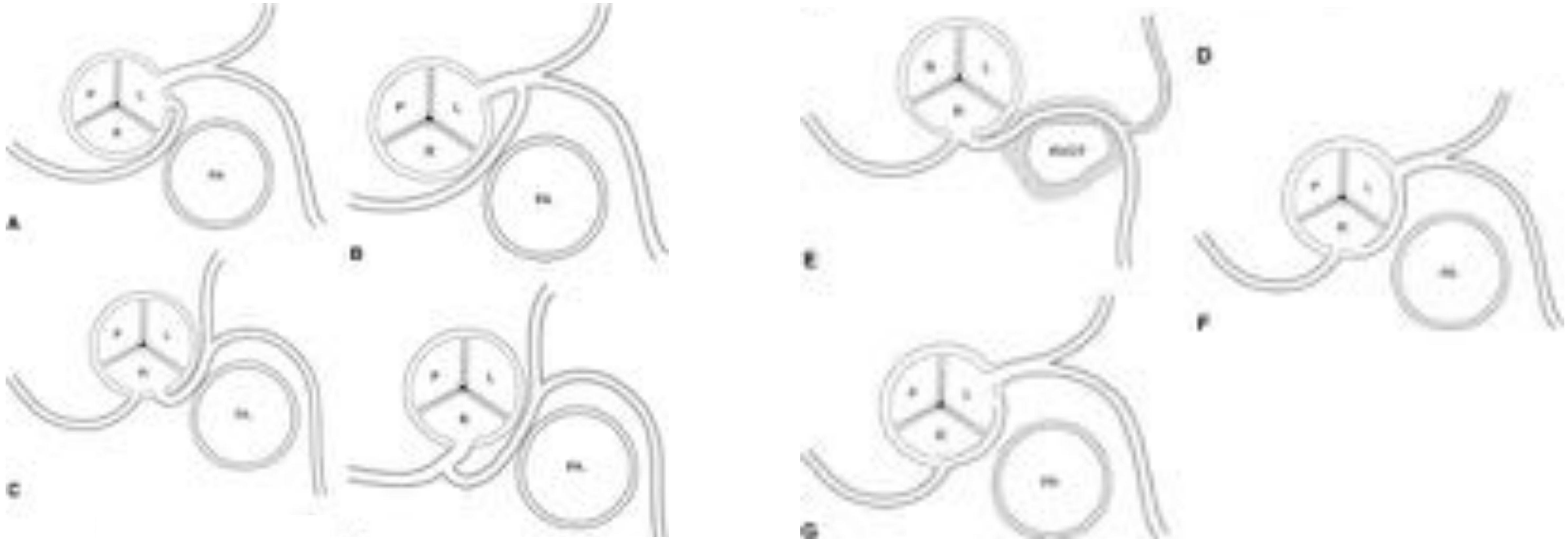
Main abnormal epicardial courses of coronary arteries



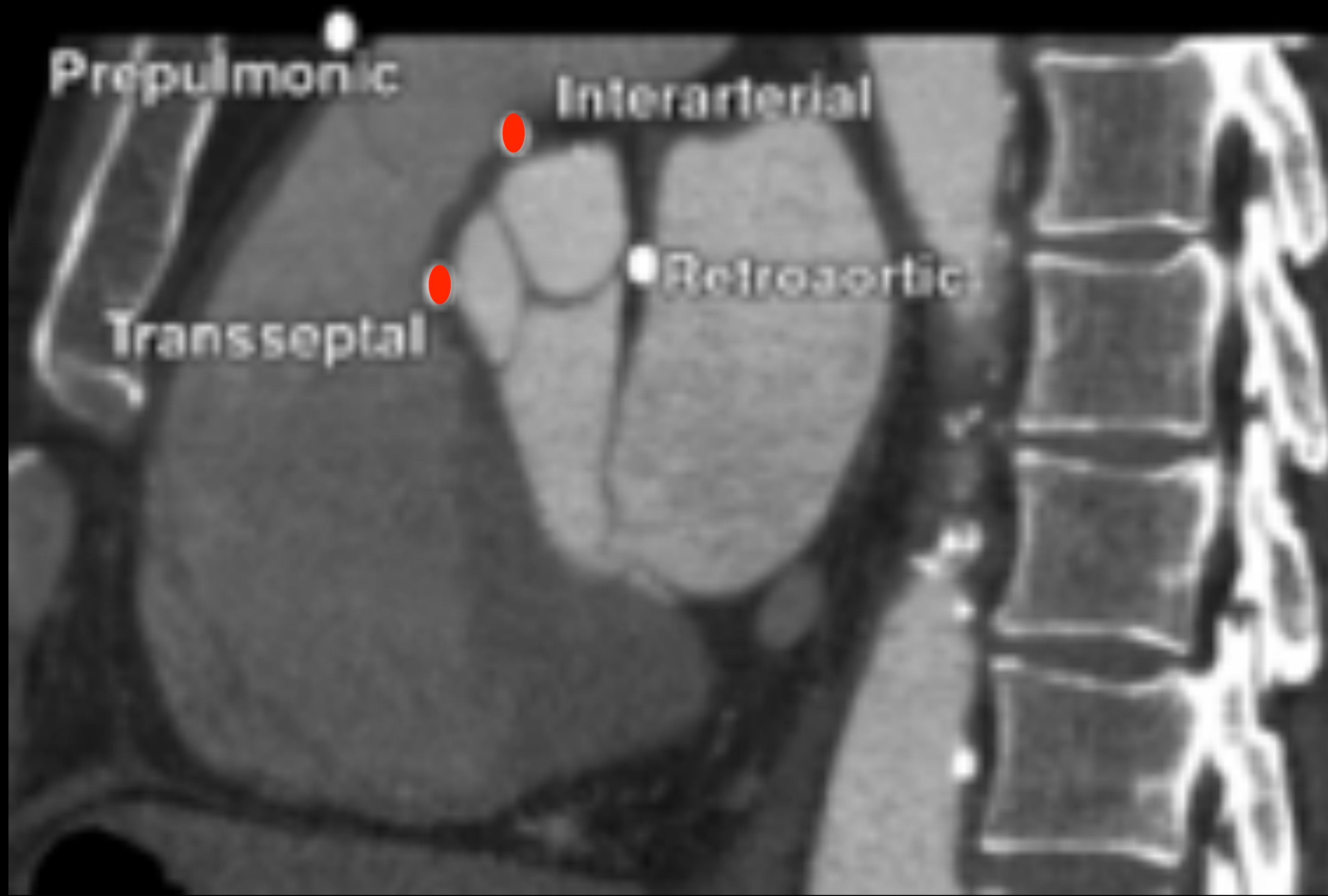
Abnormal courses considered at low risk of cardiac event



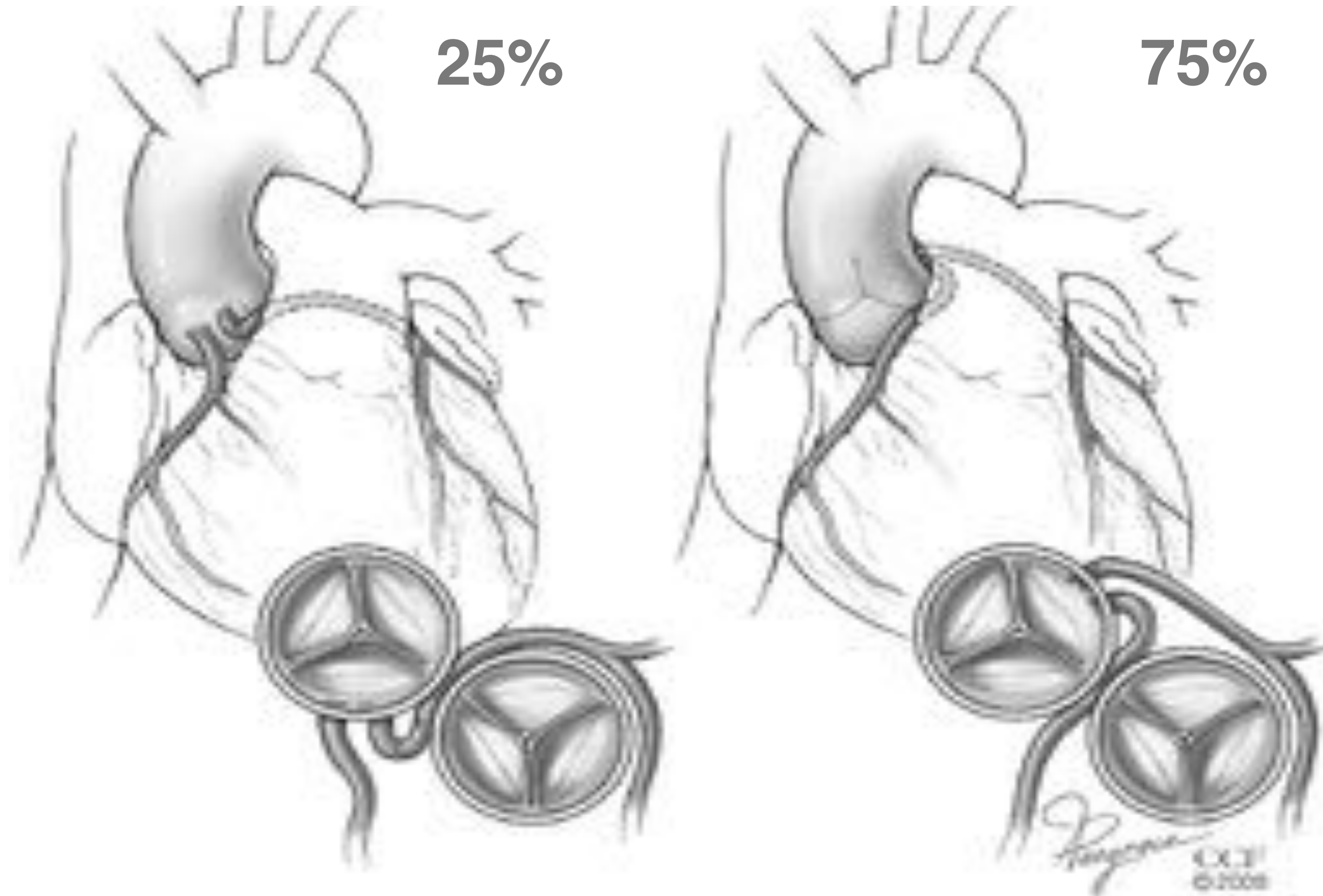
Abnormal courses considered **at high risk** of cardiac event



Main abnormal epicardial courses

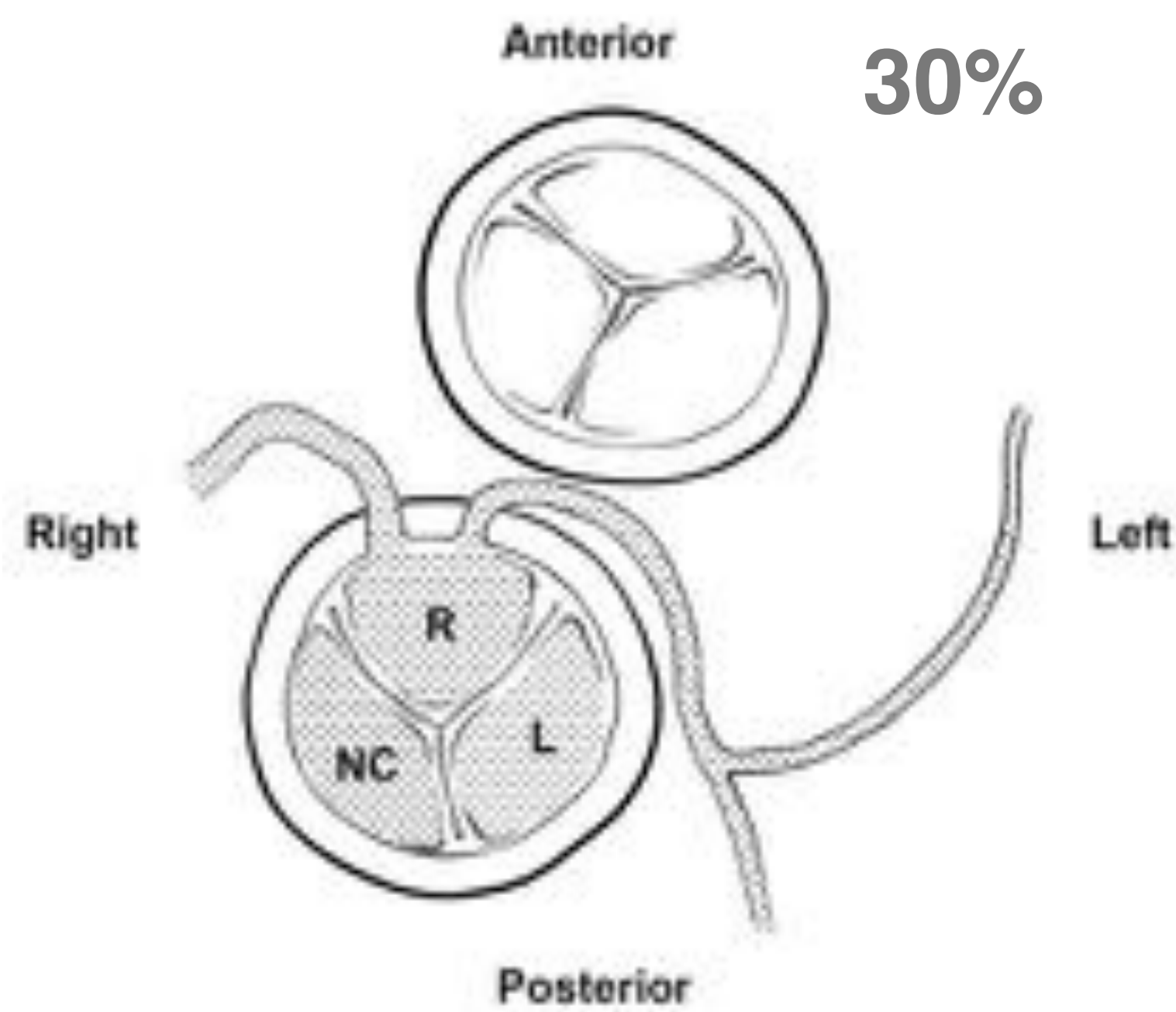


Interarterial course of coronary arteries

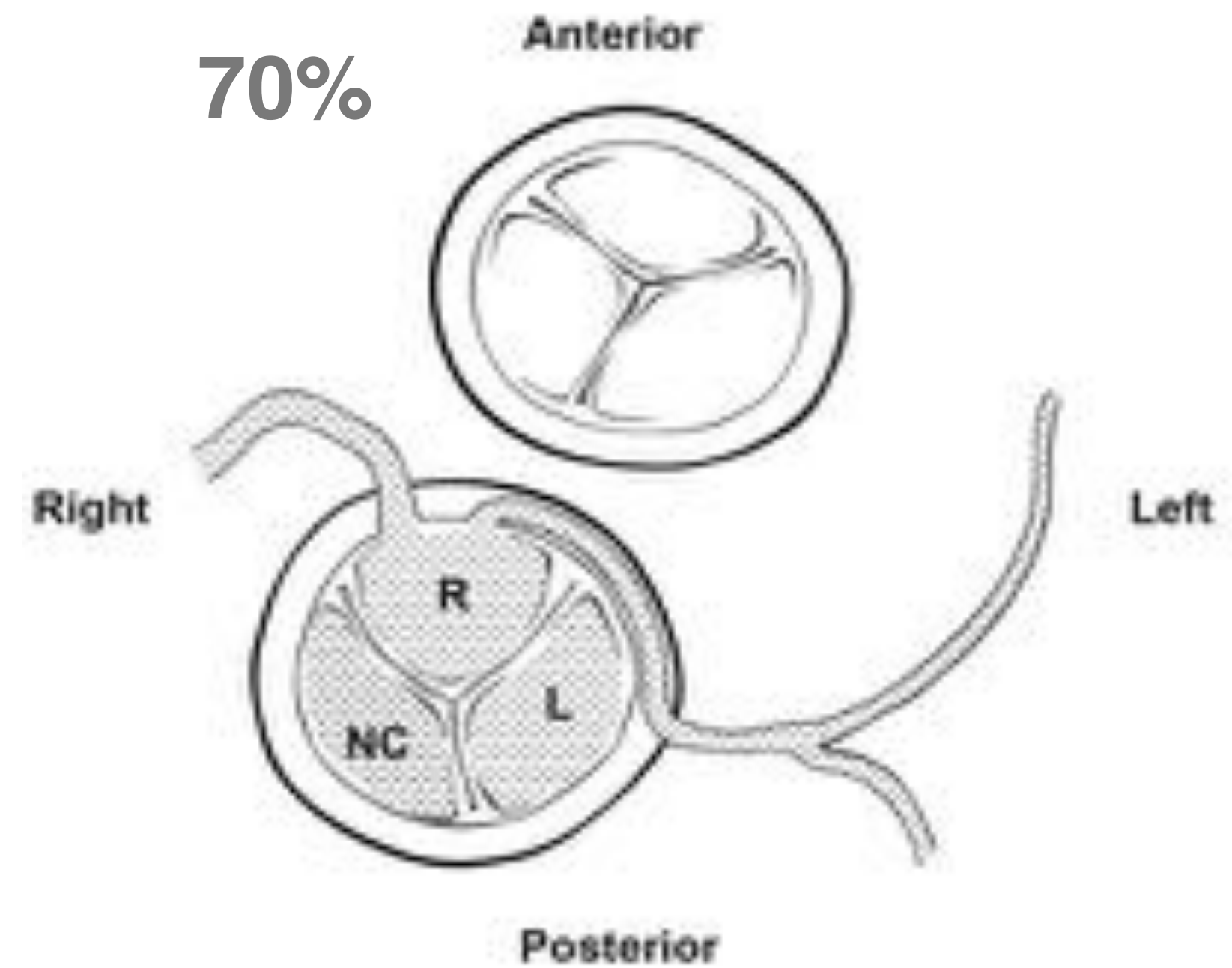


0,1% - 0,3% of the population (\approx 100 000 people in France)

Two anatomical variants

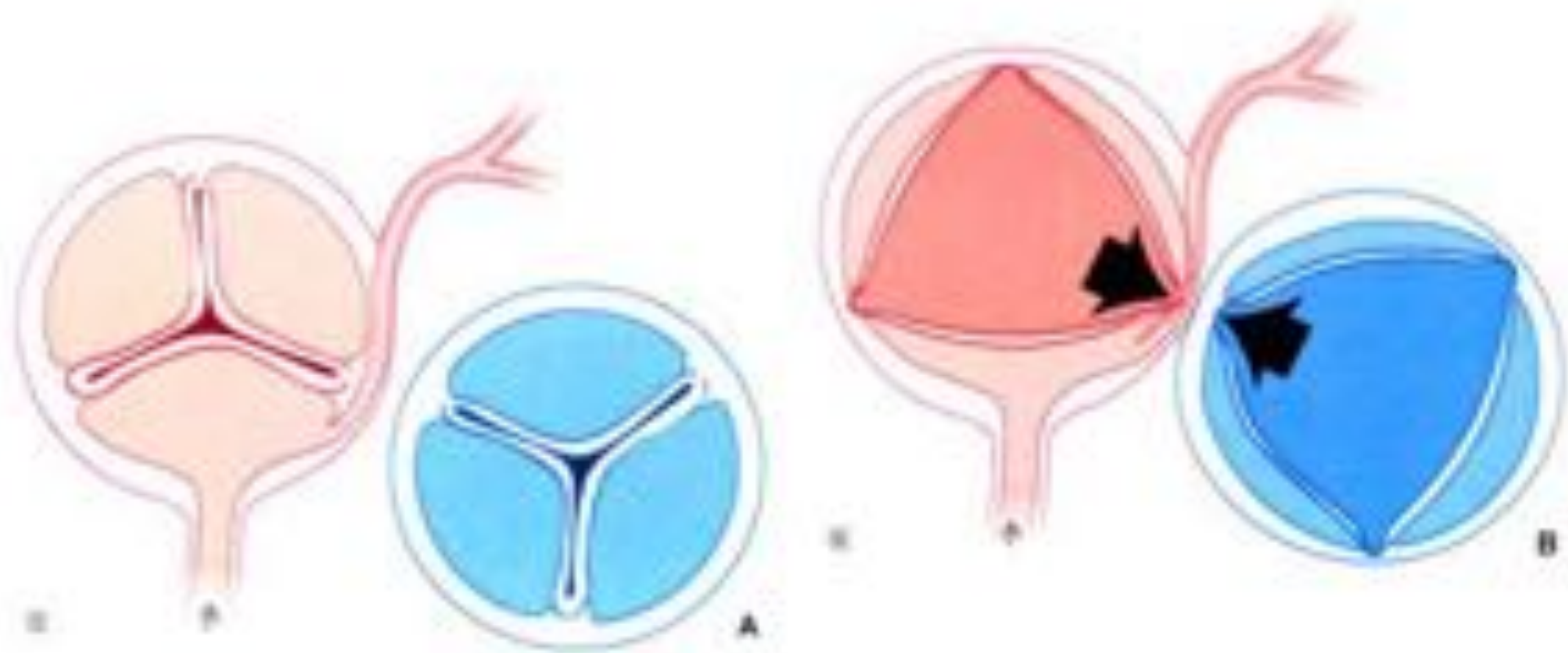


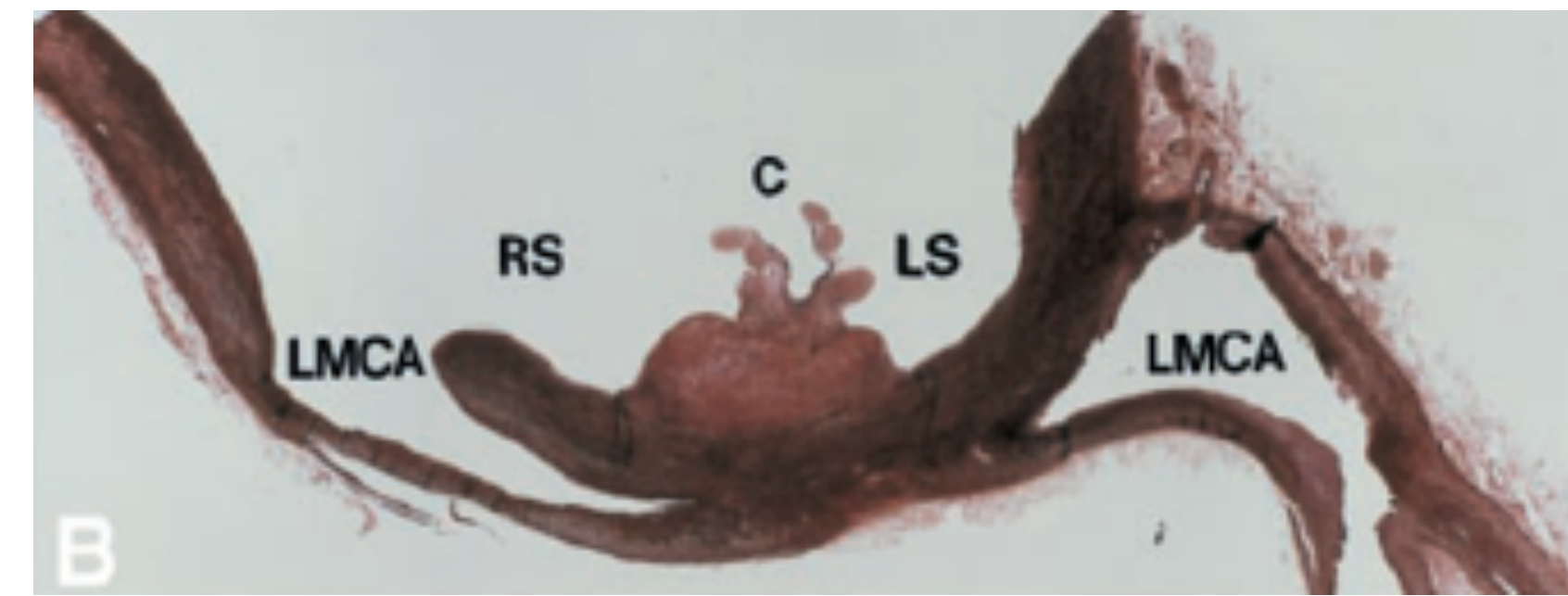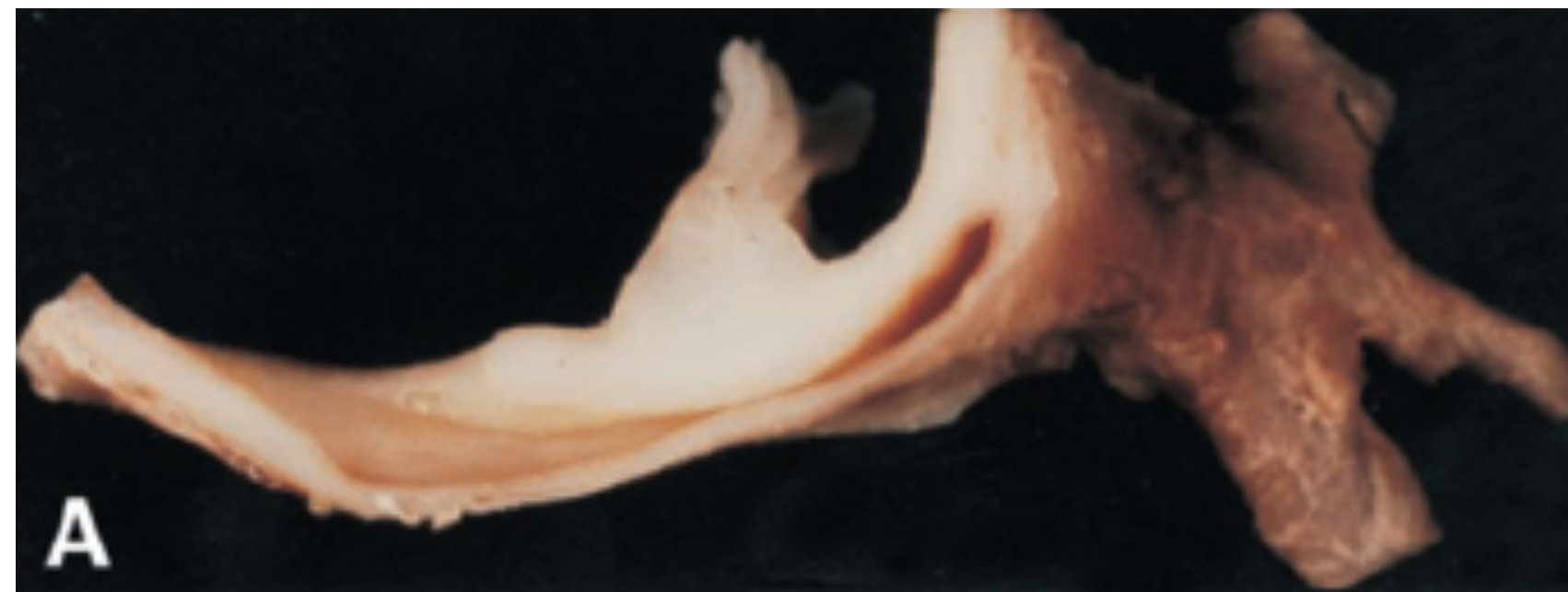
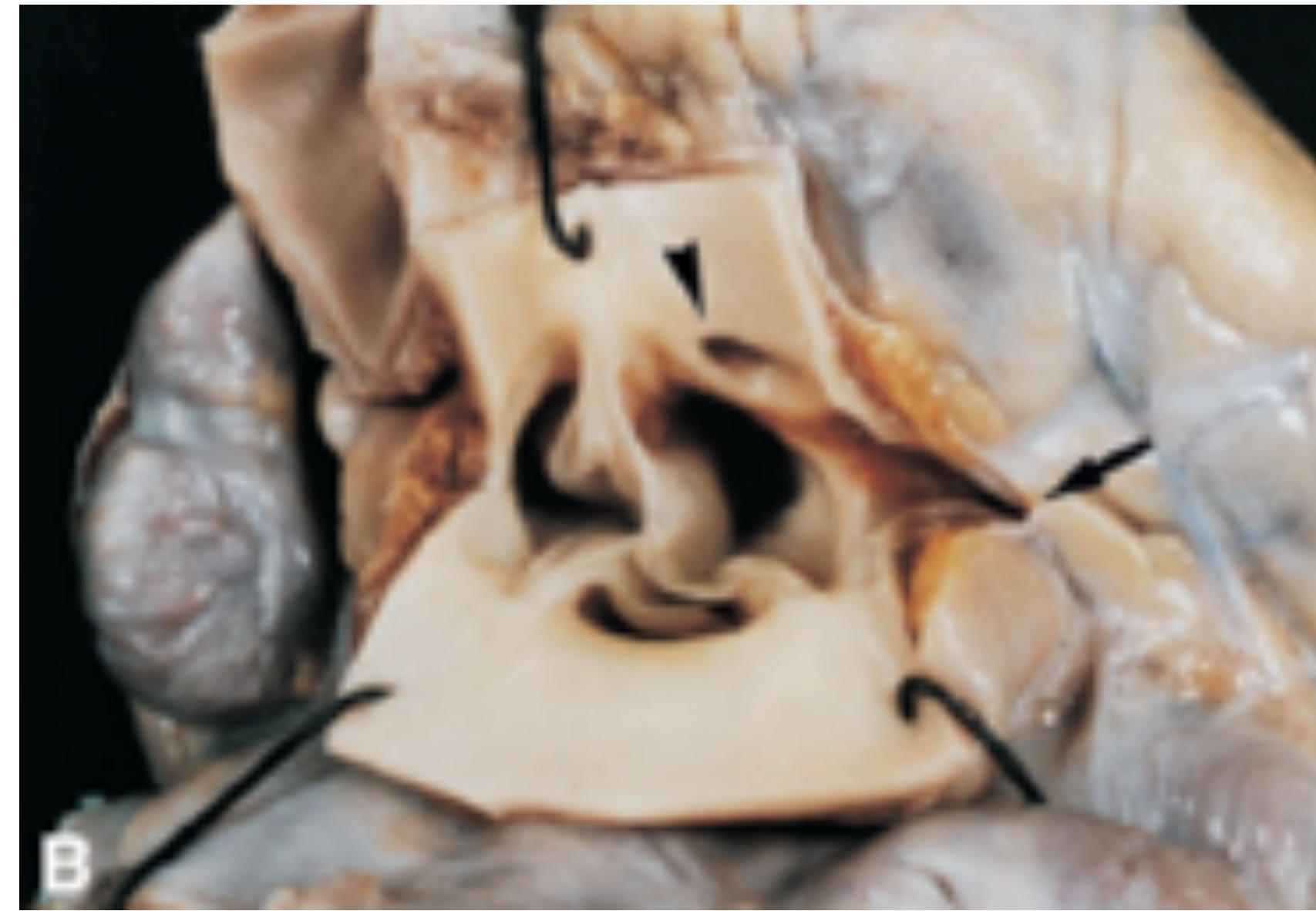
Interarterial course isolated



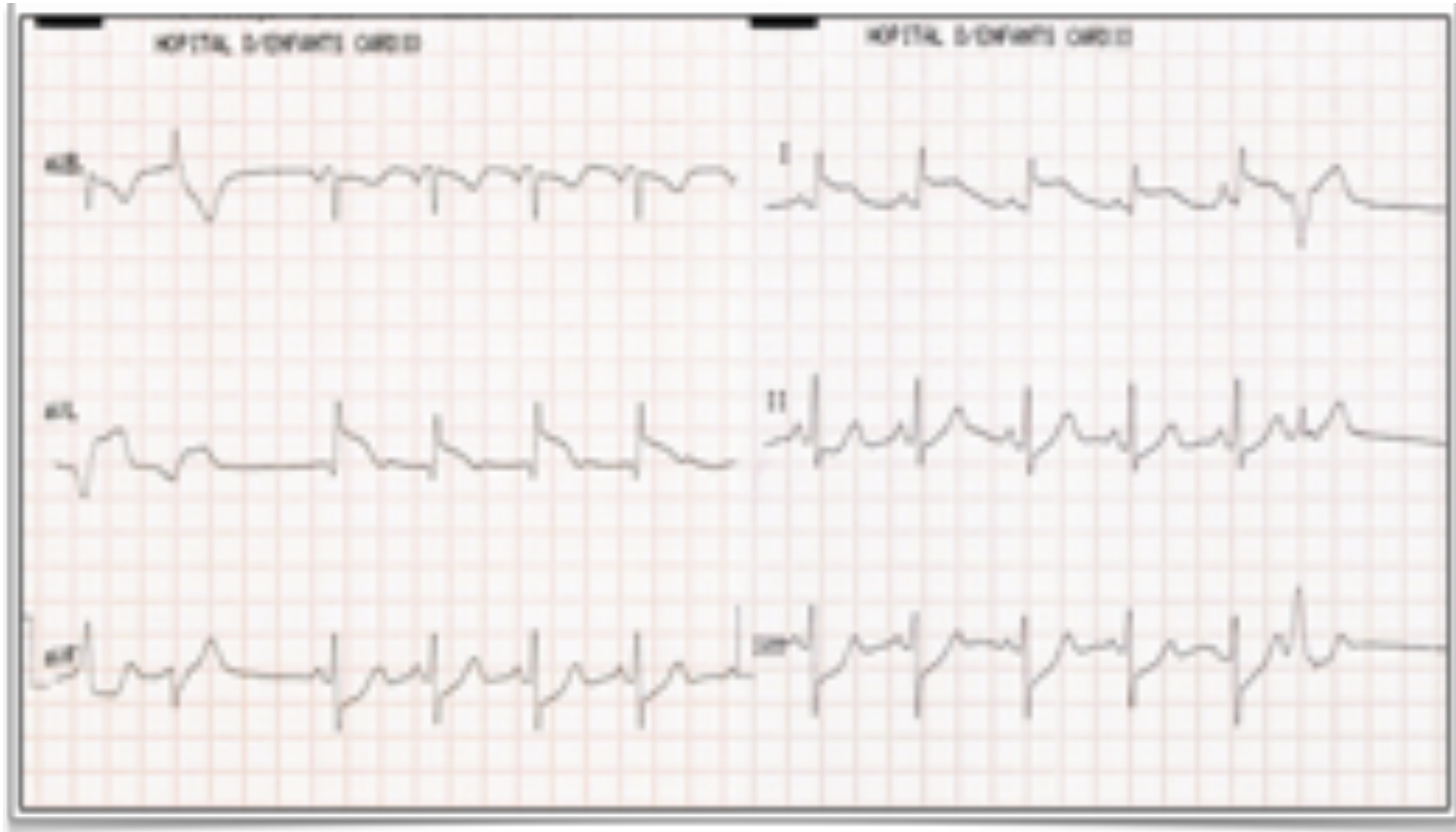
Interarterial course and intramural

Mechanism of myocardial ischemia





Serendipitously diagnosed or not

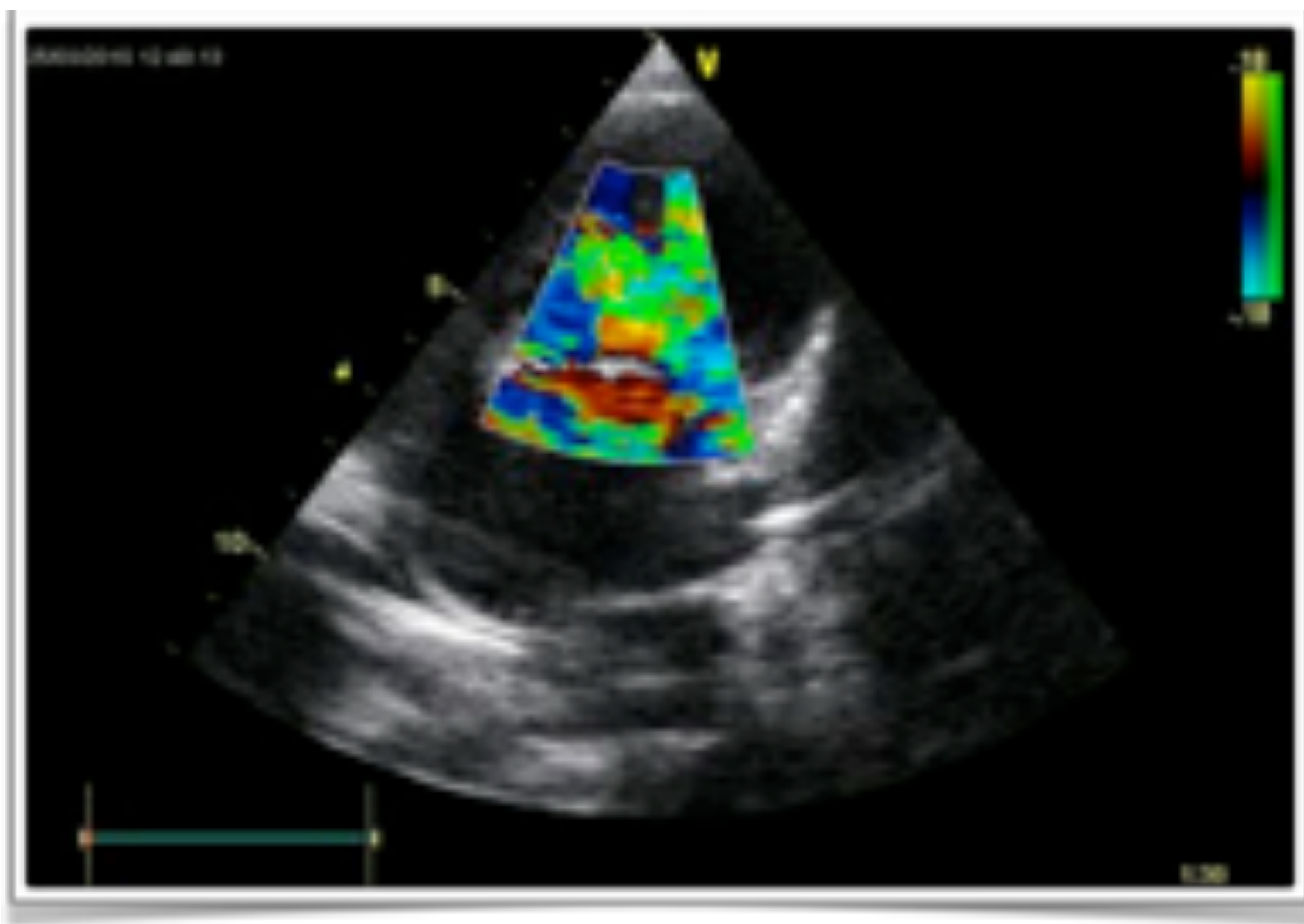


In Vivo Detection of Coronary Artery Anomalies in Asymptomatic Athletes by Echocardiographic Screening*

Frank Cecchin, MD, Andrew Della Porta, MD, Thomas K. Jones, MD, Julie A. Davis, MD, Laura Tait, MD, Alessandro Giordano, MD, and Andrew Portman, MD, FACC

(J Am Coll Cardiol 2001;37:1097-1099)

3/3150
0.09%



Journal of the American College of Cardiology
© 2001 by the American College of Cardiology
Published by Elsevier Science Inc.

Vol. 37, No. 2, 2001
ISSN 0735-1097/01/\$20.00
PII S0735-1097(00)01136-0

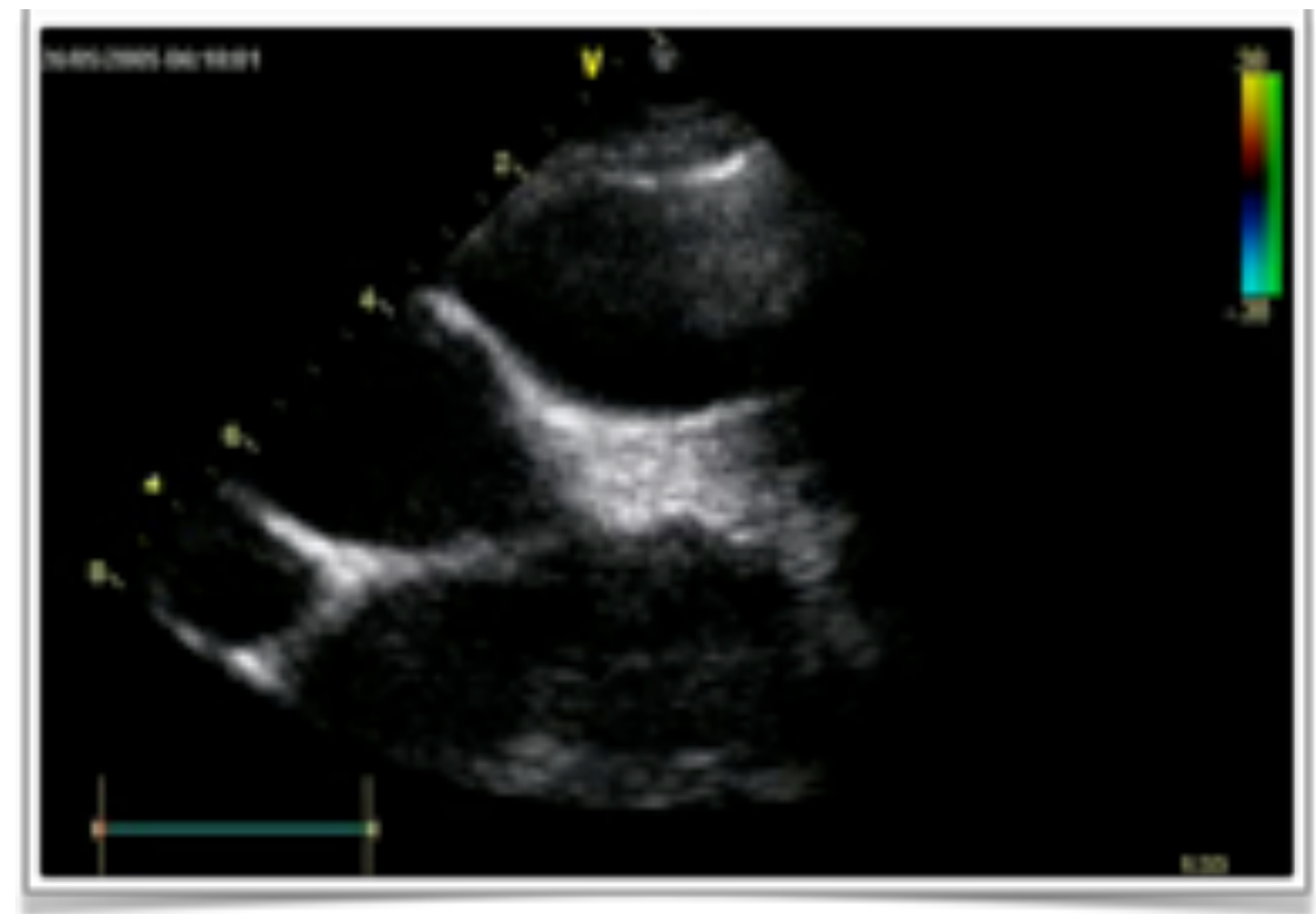
Pediatric Cardiology

Major Coronary Artery Anomalies in a Pediatric Population: Incidence and Clinical Importance

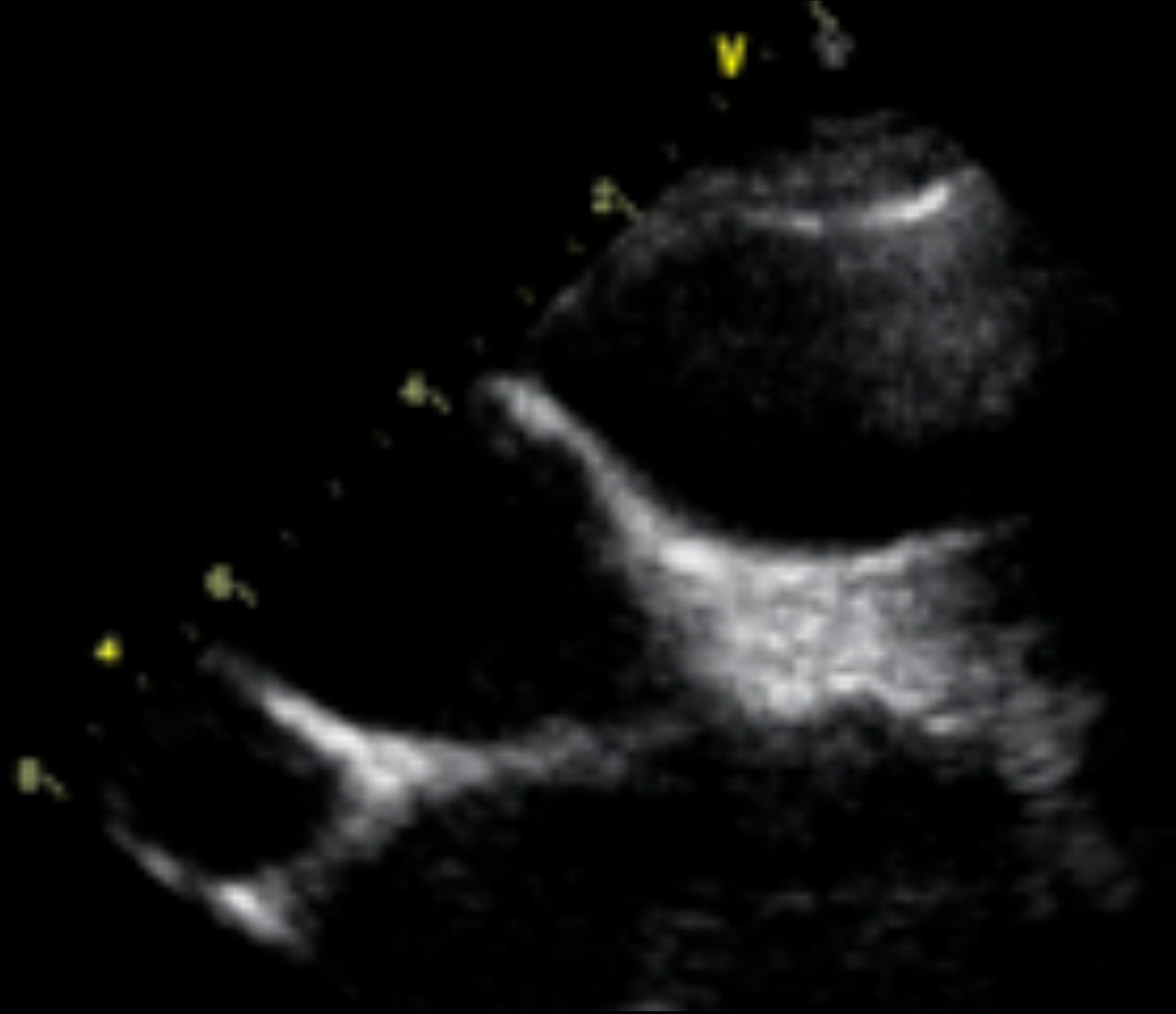Julie A. Davis, MD, Frank Cecchin, MD, FACC, Thomas K. Jones, MD, FACC, Michael A. Portman, MD, FACC

Seattle, Washington

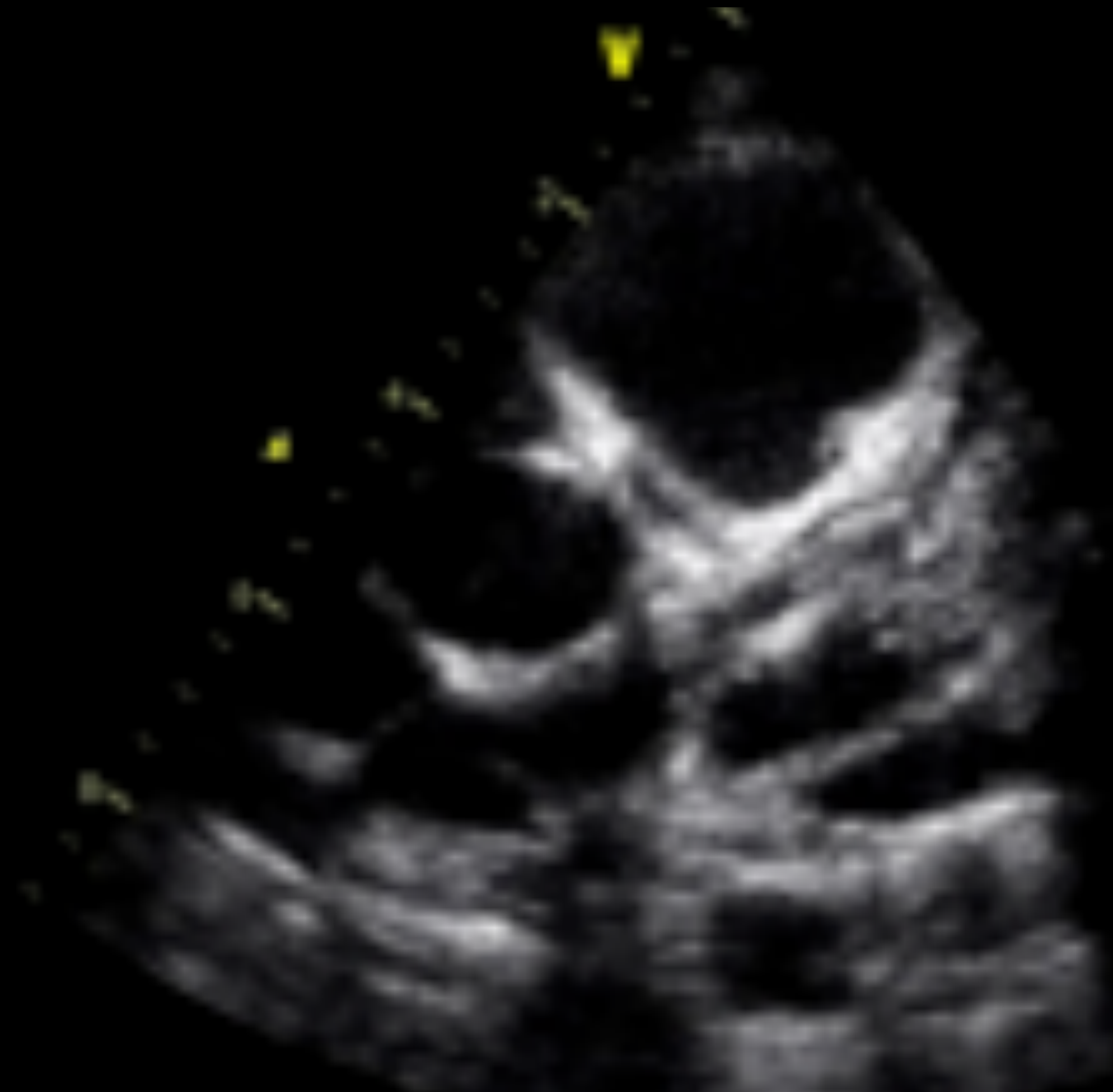4/2388
0.17%



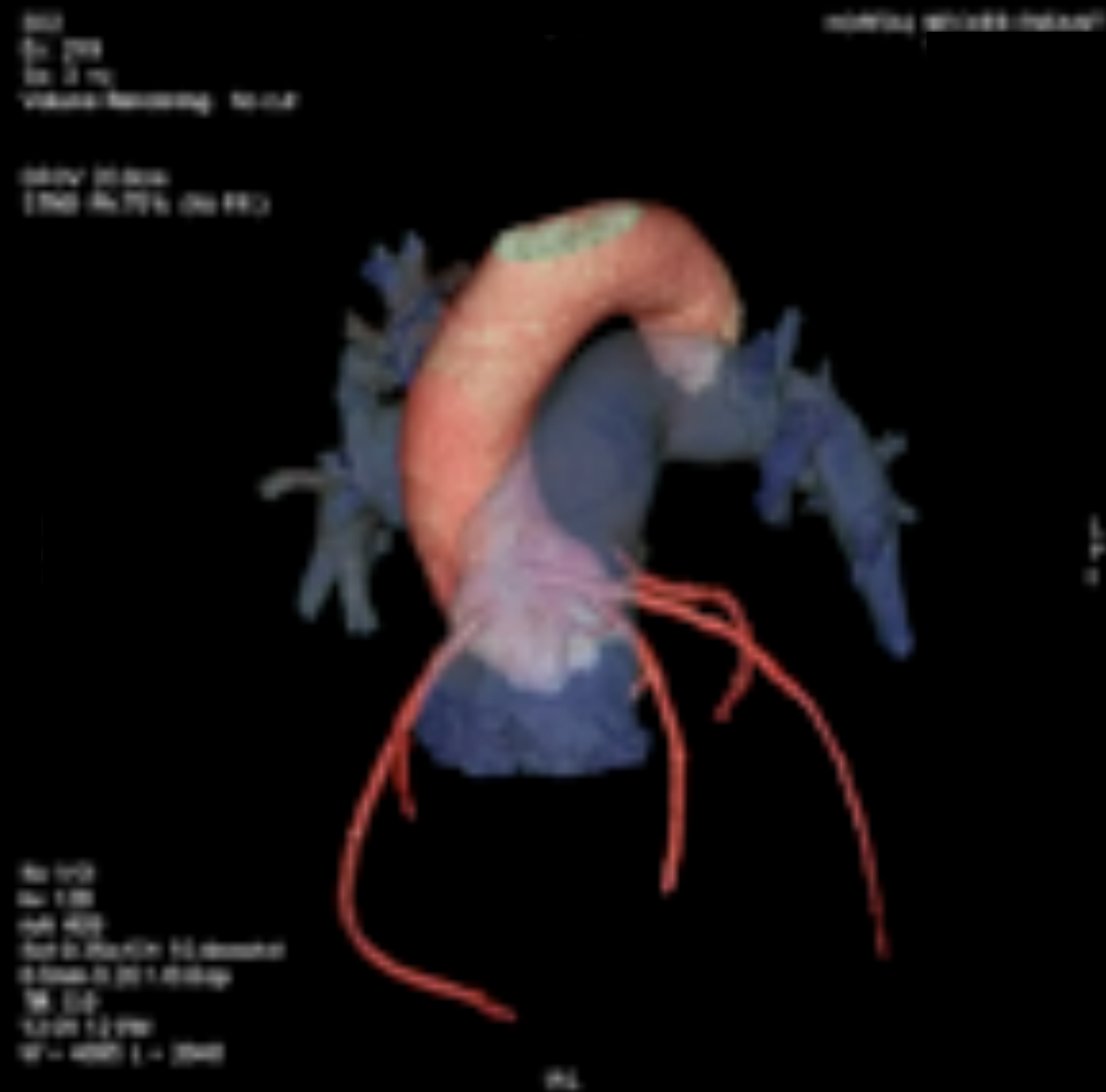
Left coronary artery from the right ostium with inter arterial course

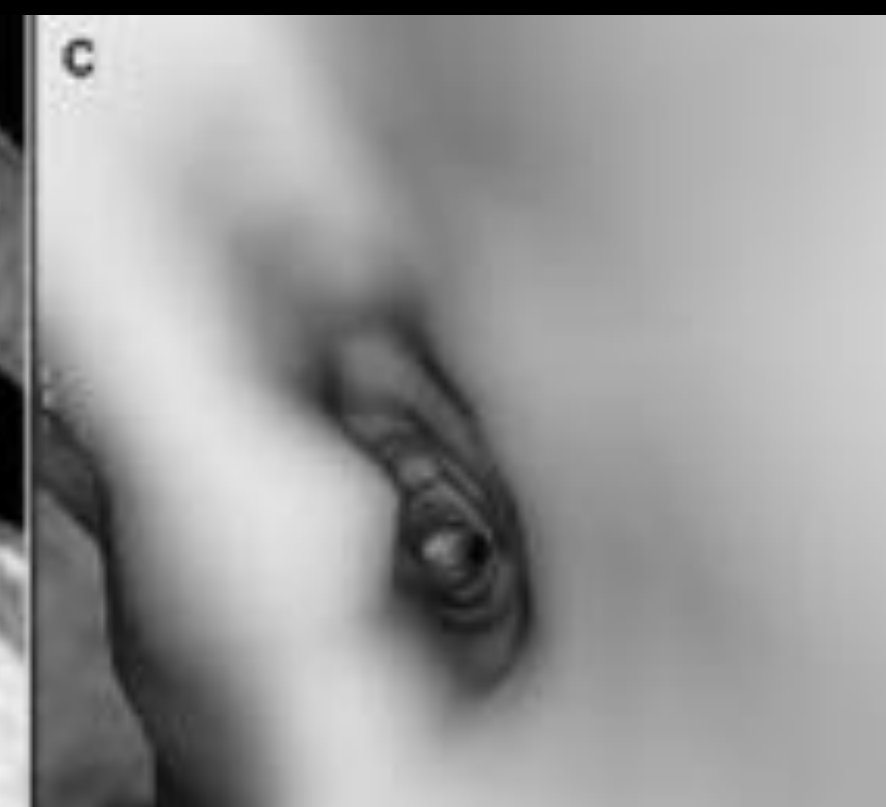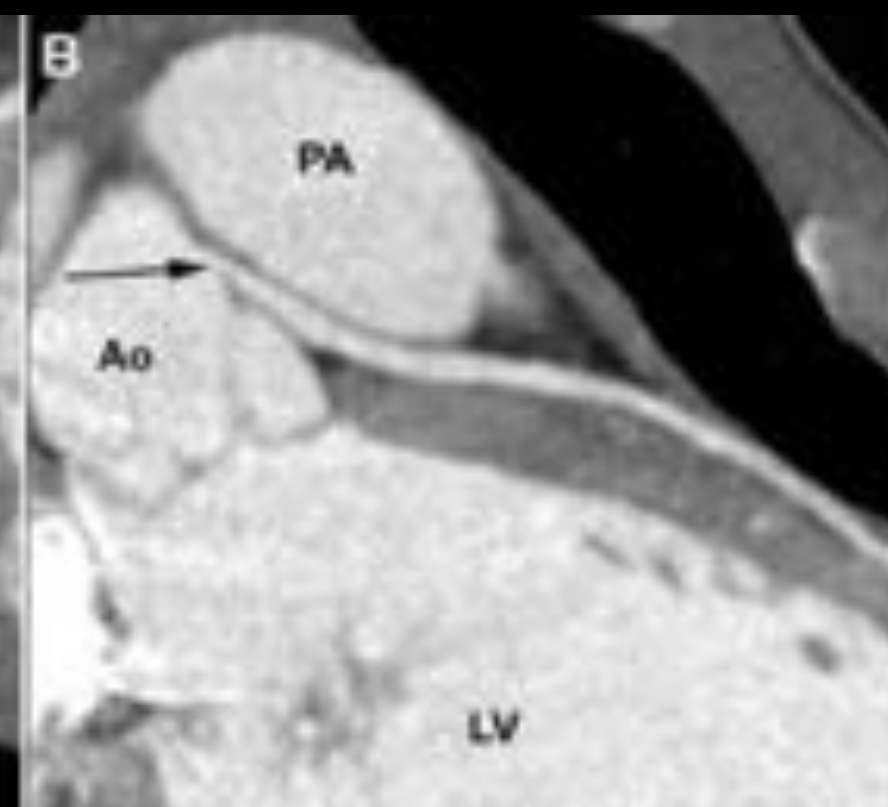
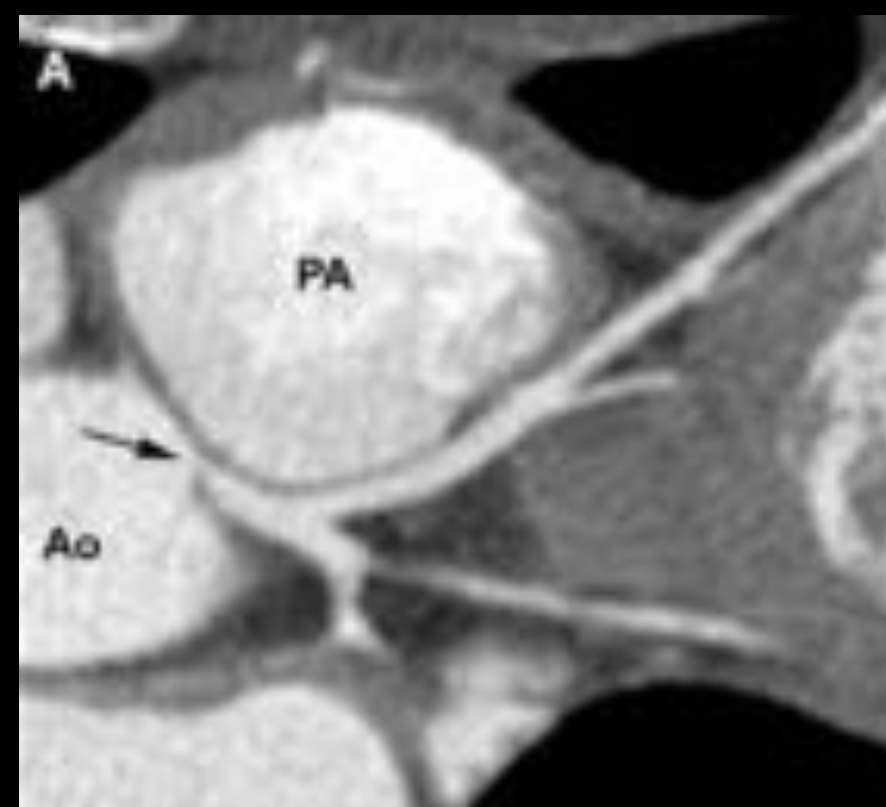
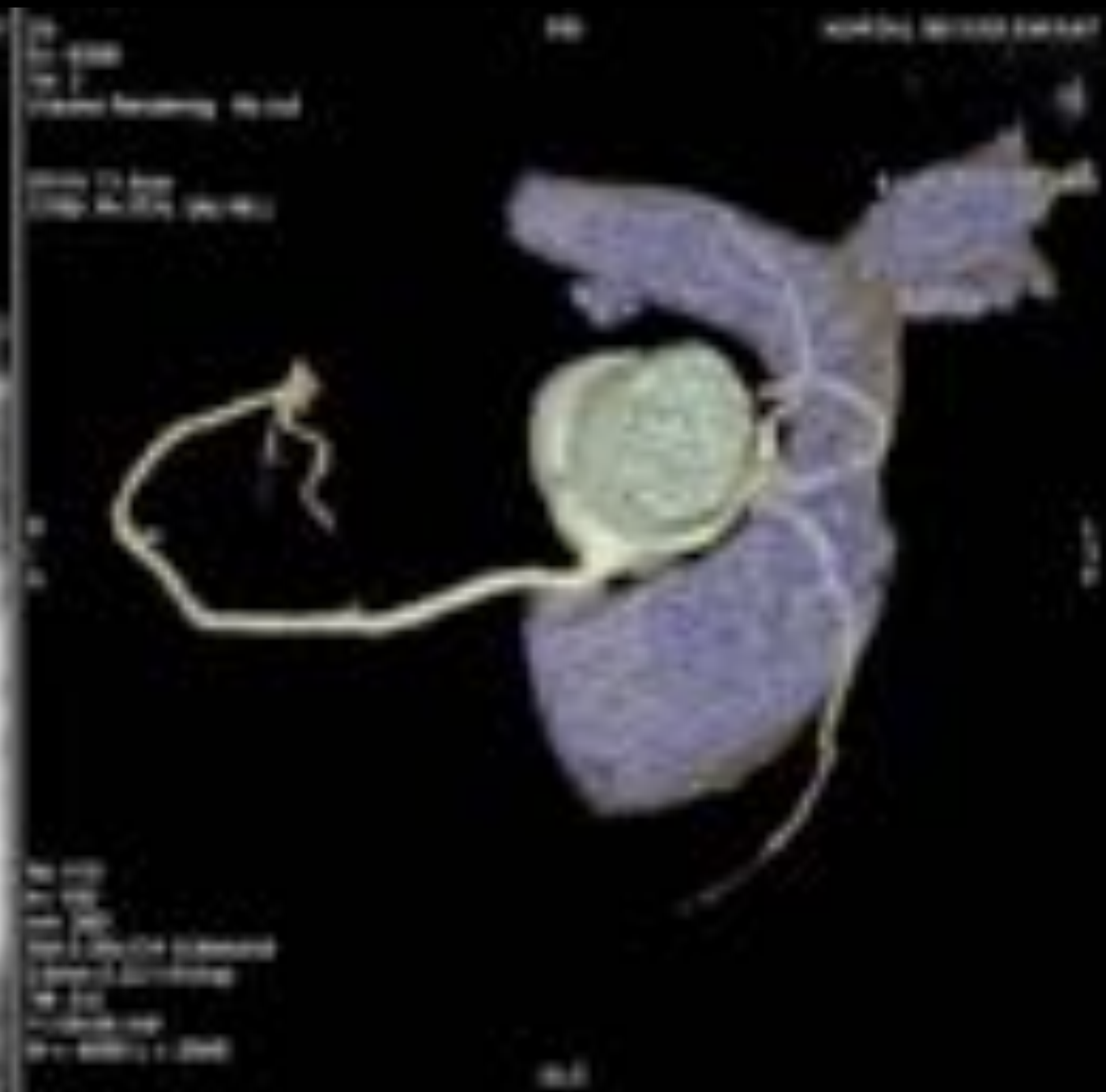

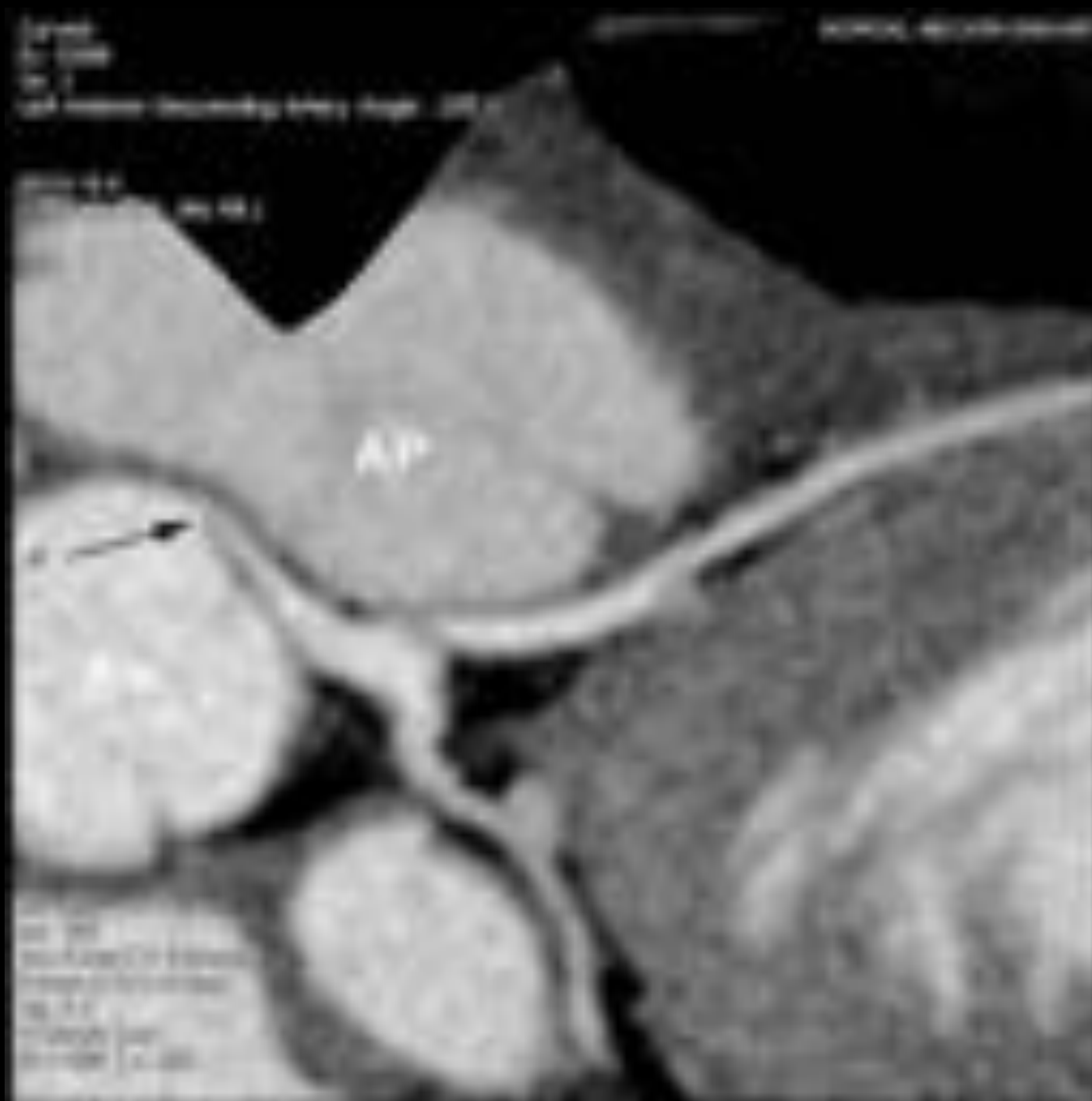
Left coronary artery from the right ostium with inter arterial course

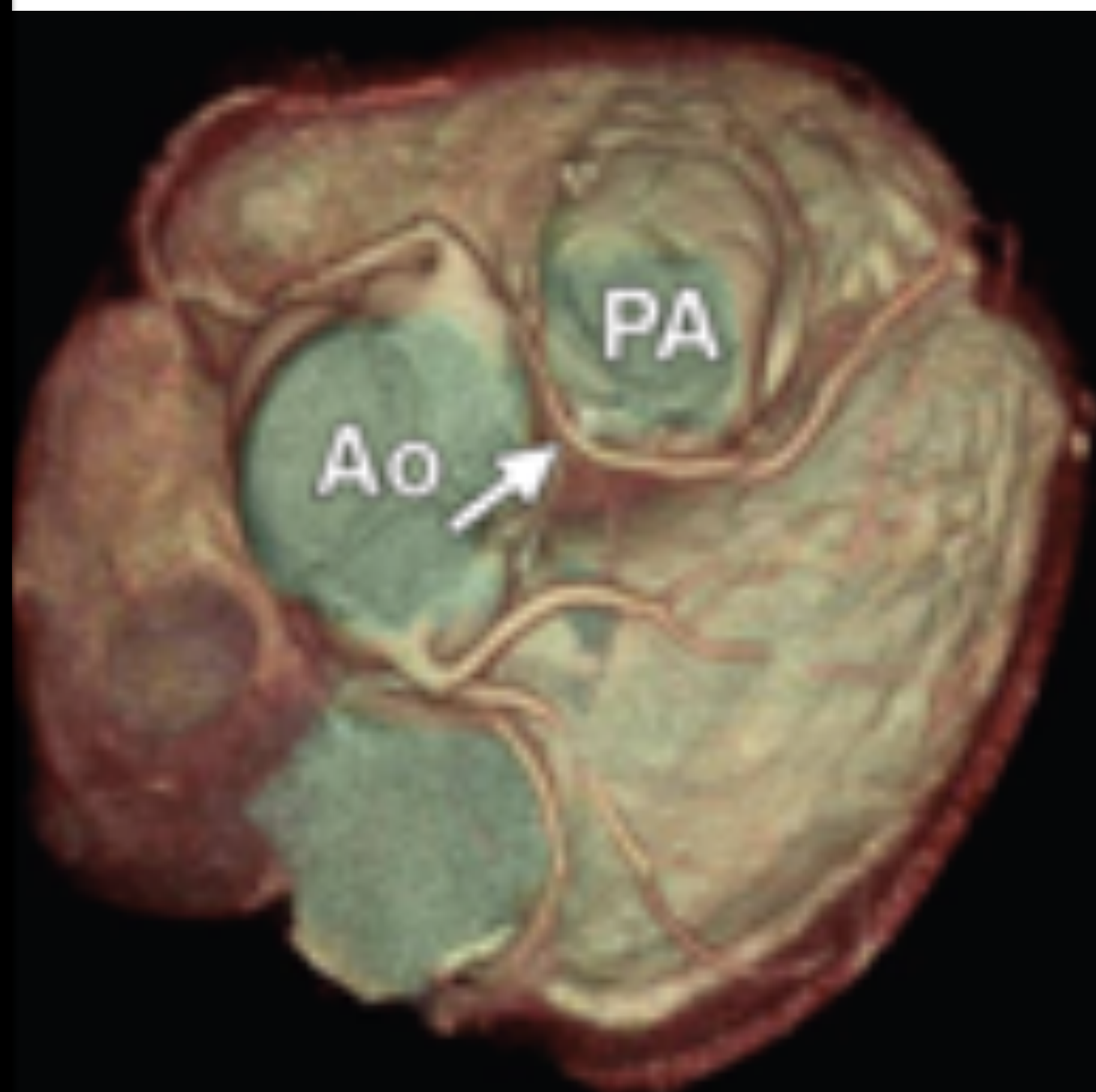
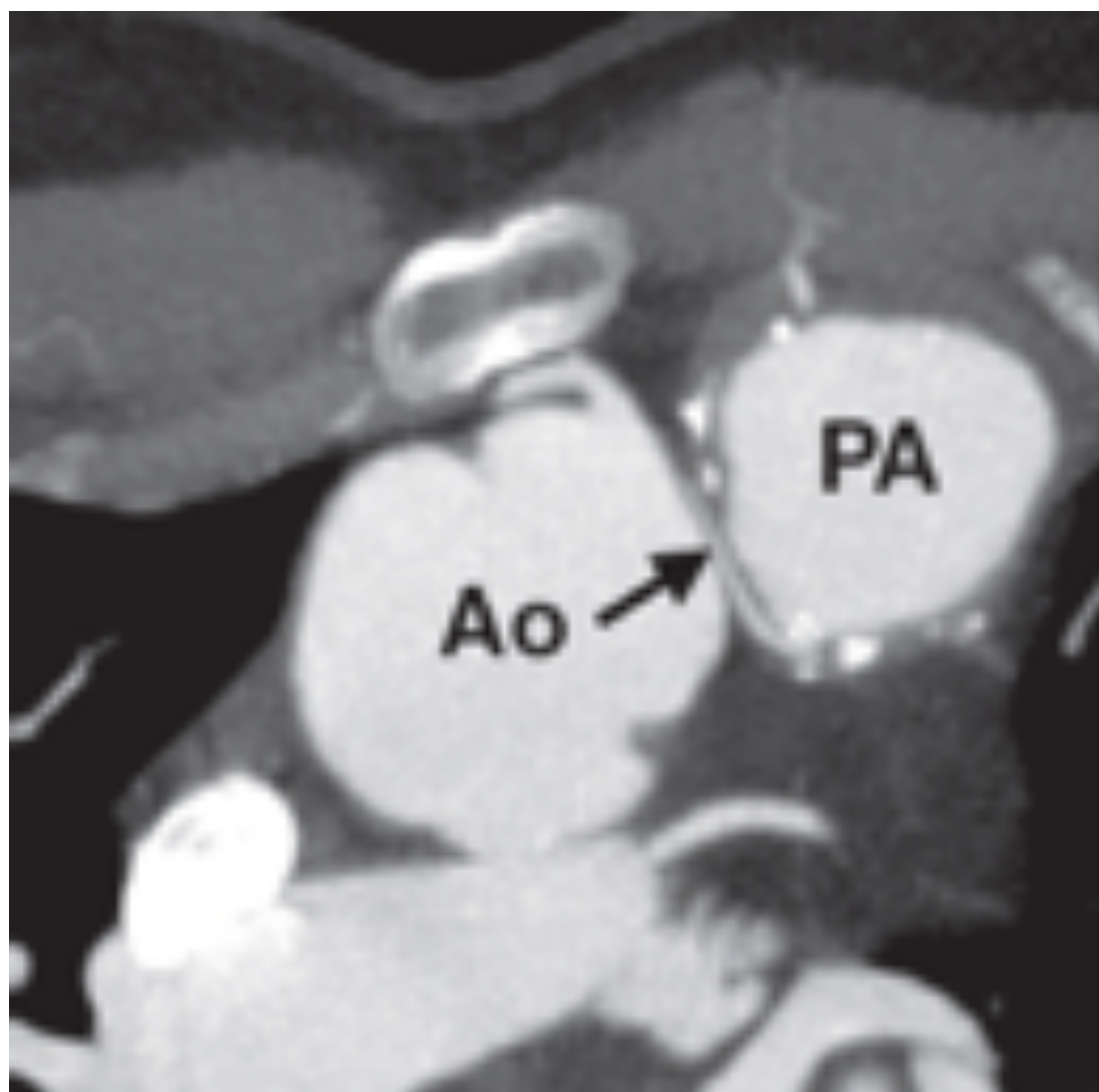


Left coronary artery from the right ostium with inter arterial course

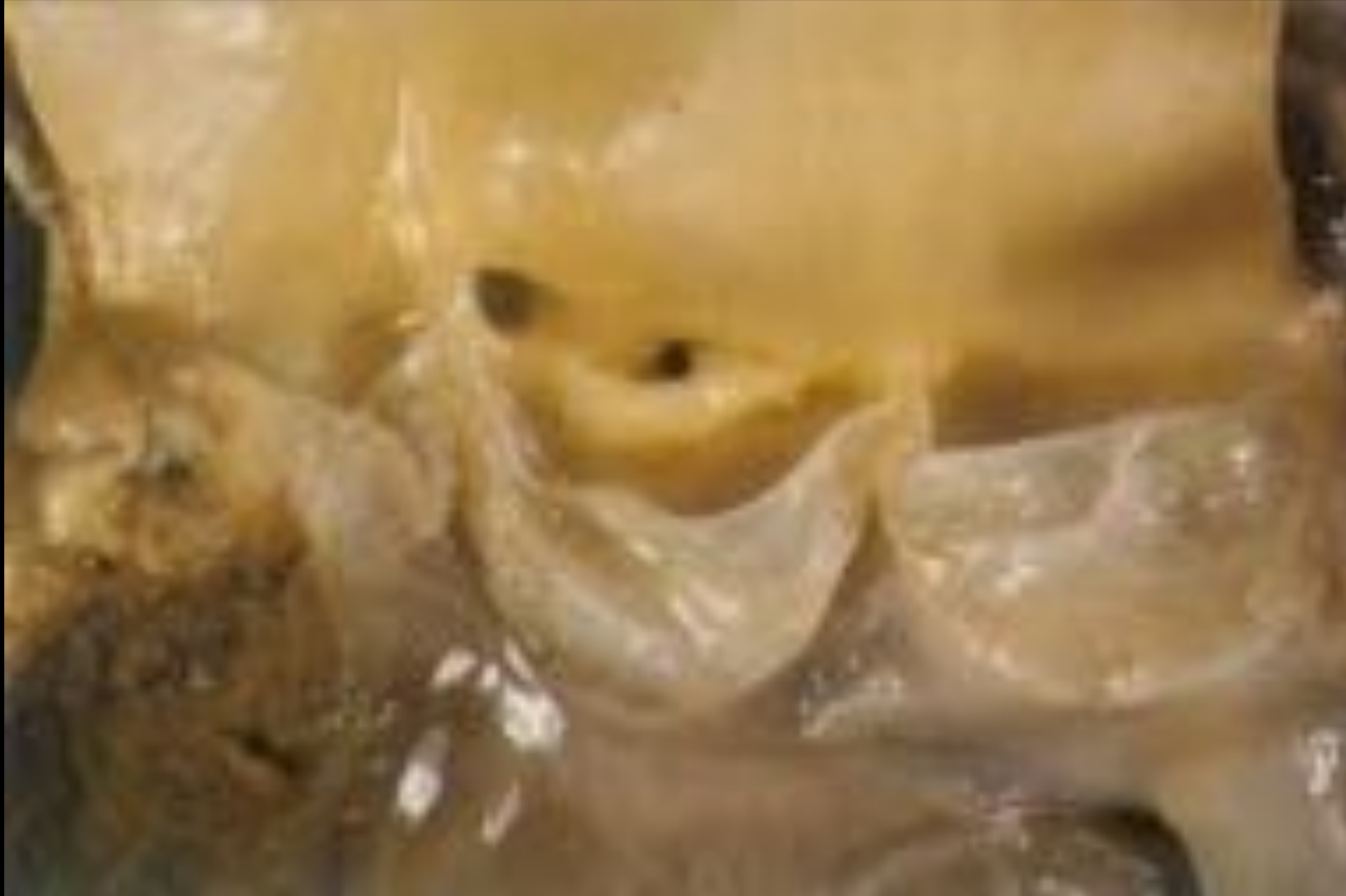



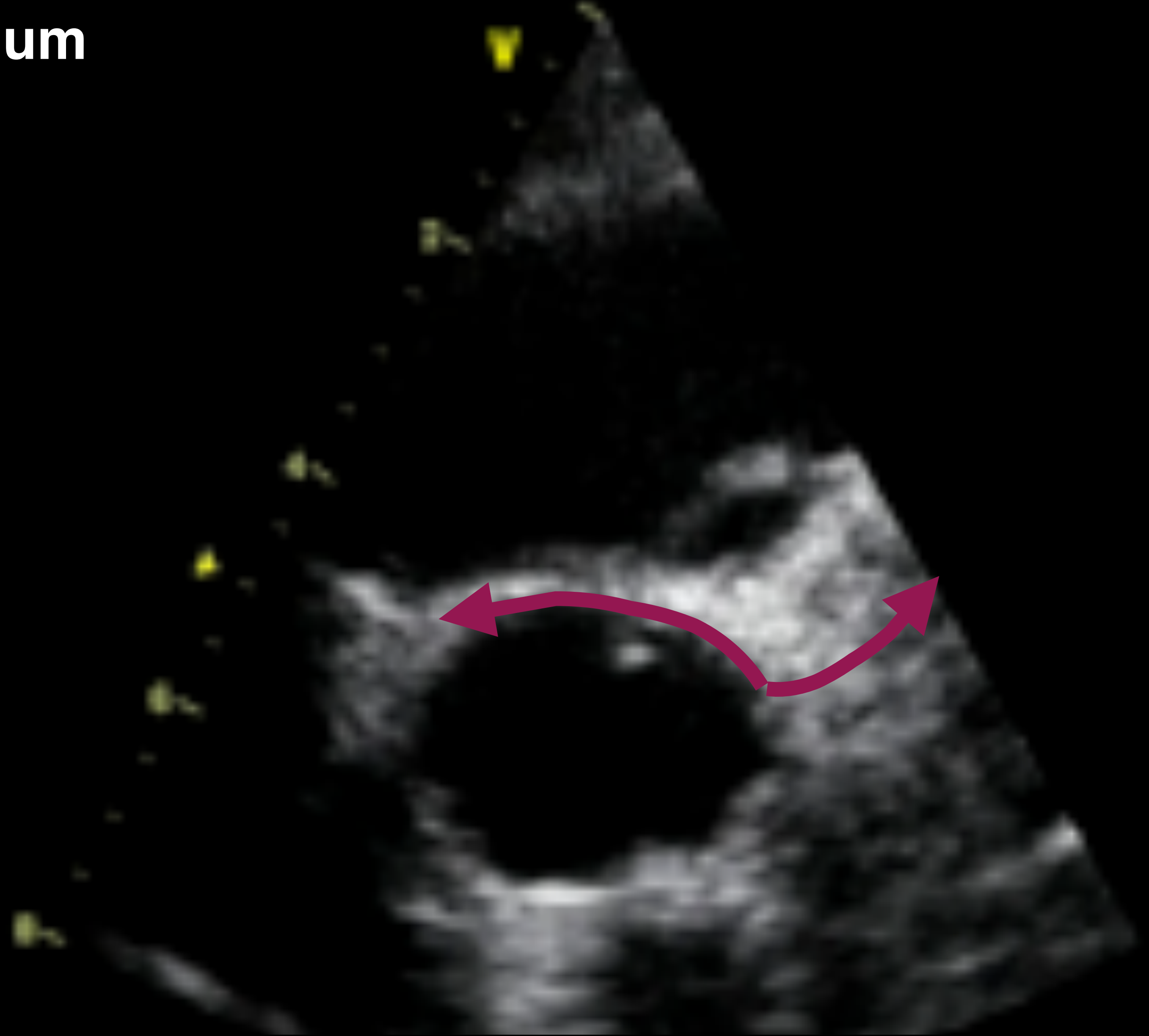
Left coronary artery from the right ostium with inter arterial course and intramural origin



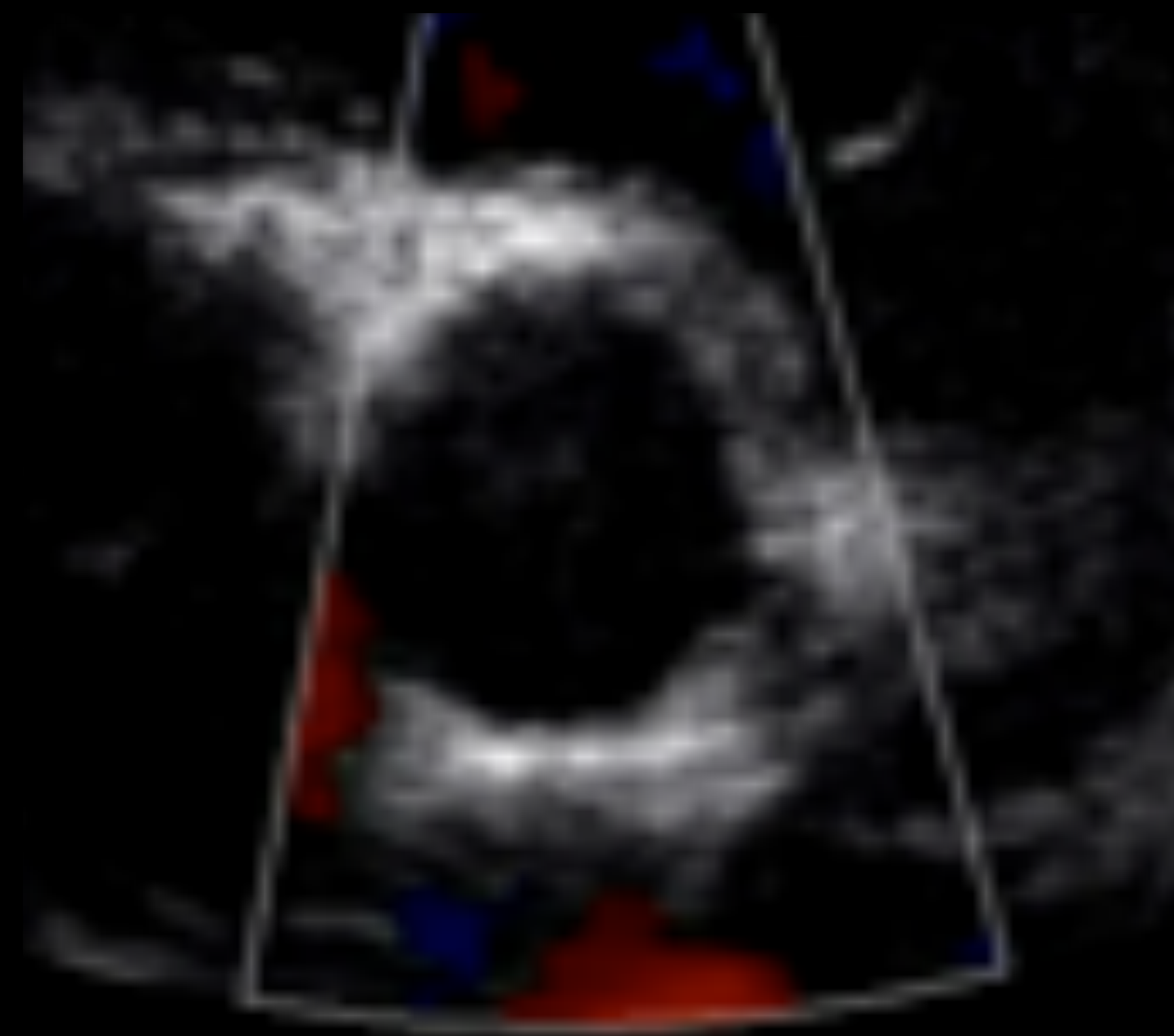
Left coronary artery from the right ostium with inter arterial course



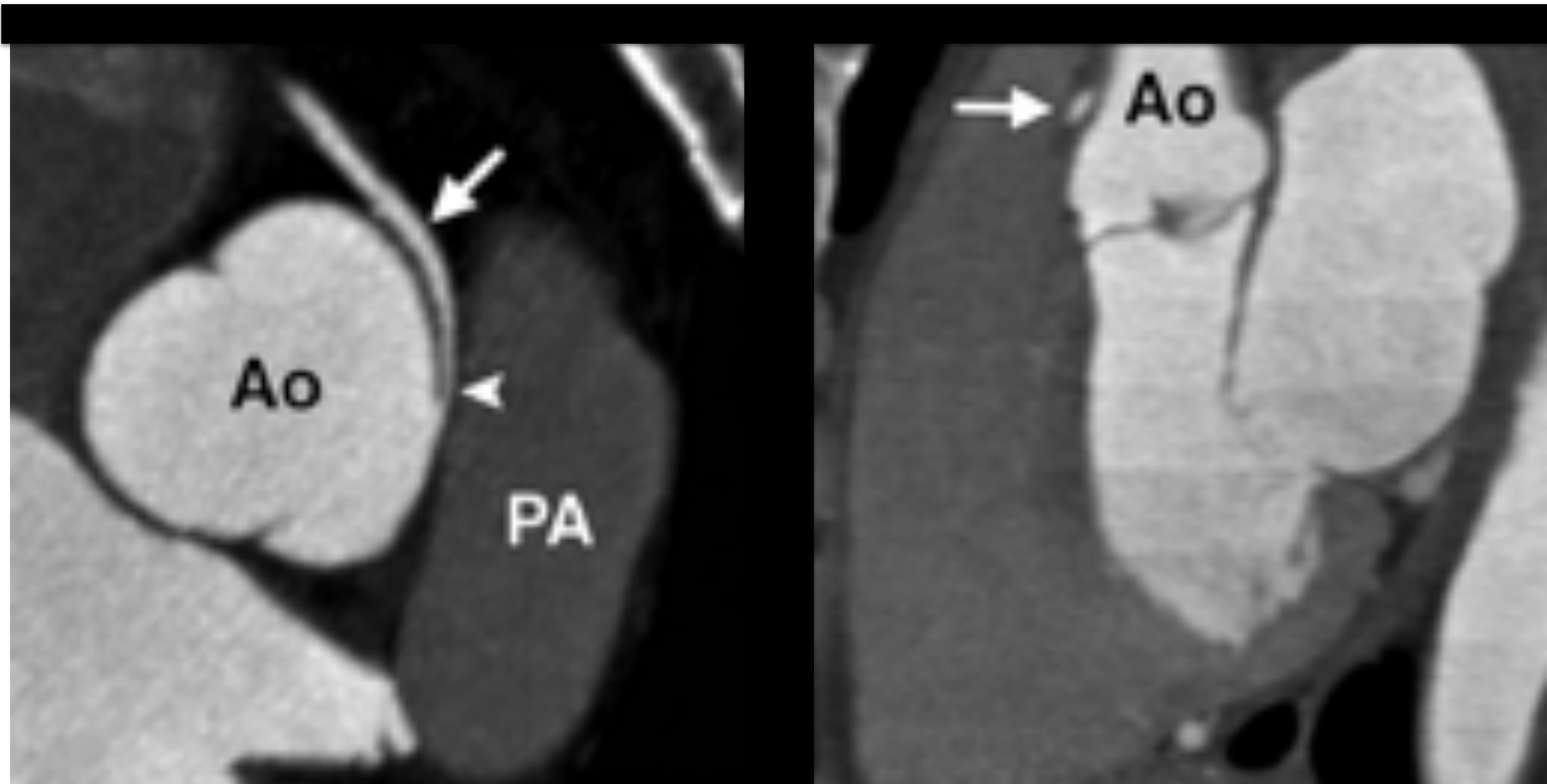
RCA from left ostium



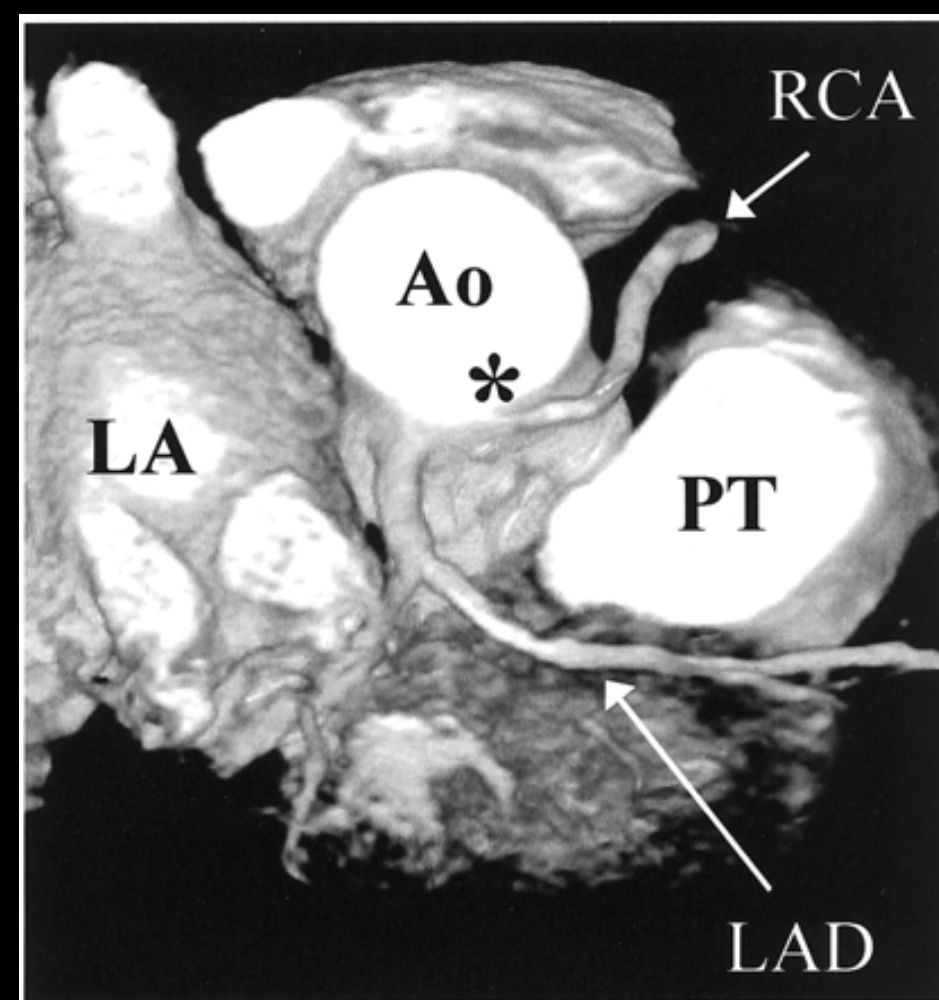
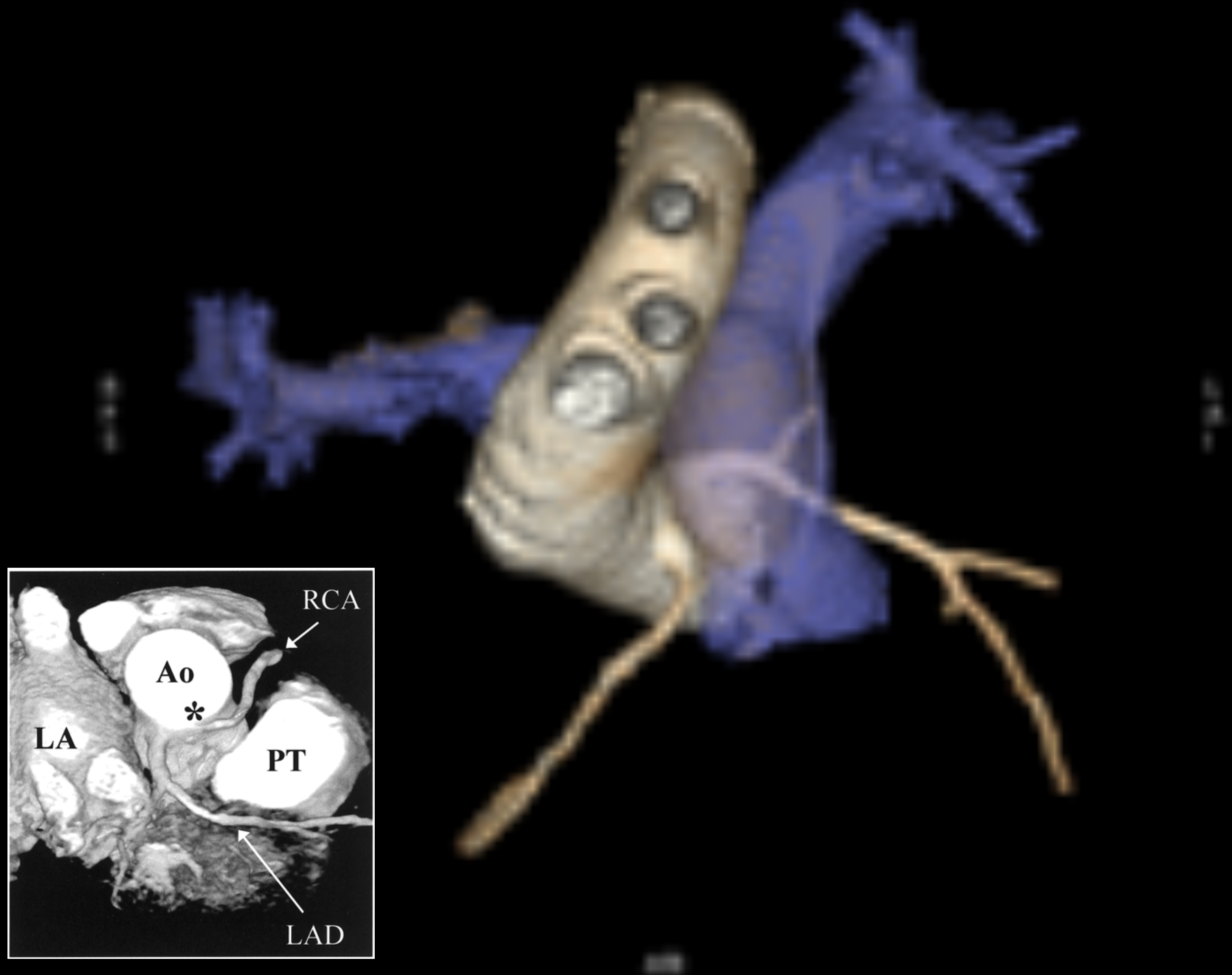
RCA from left ostium



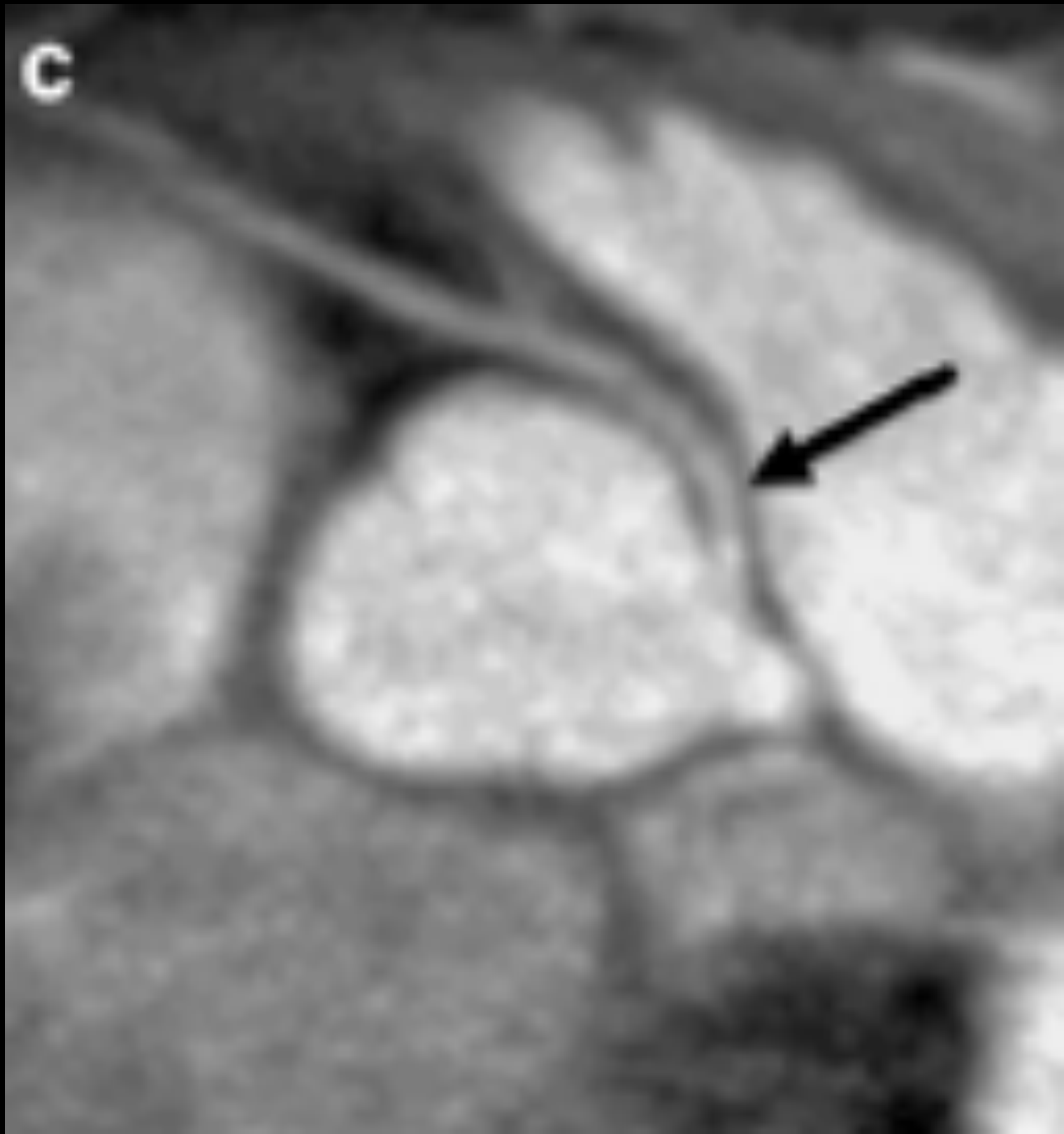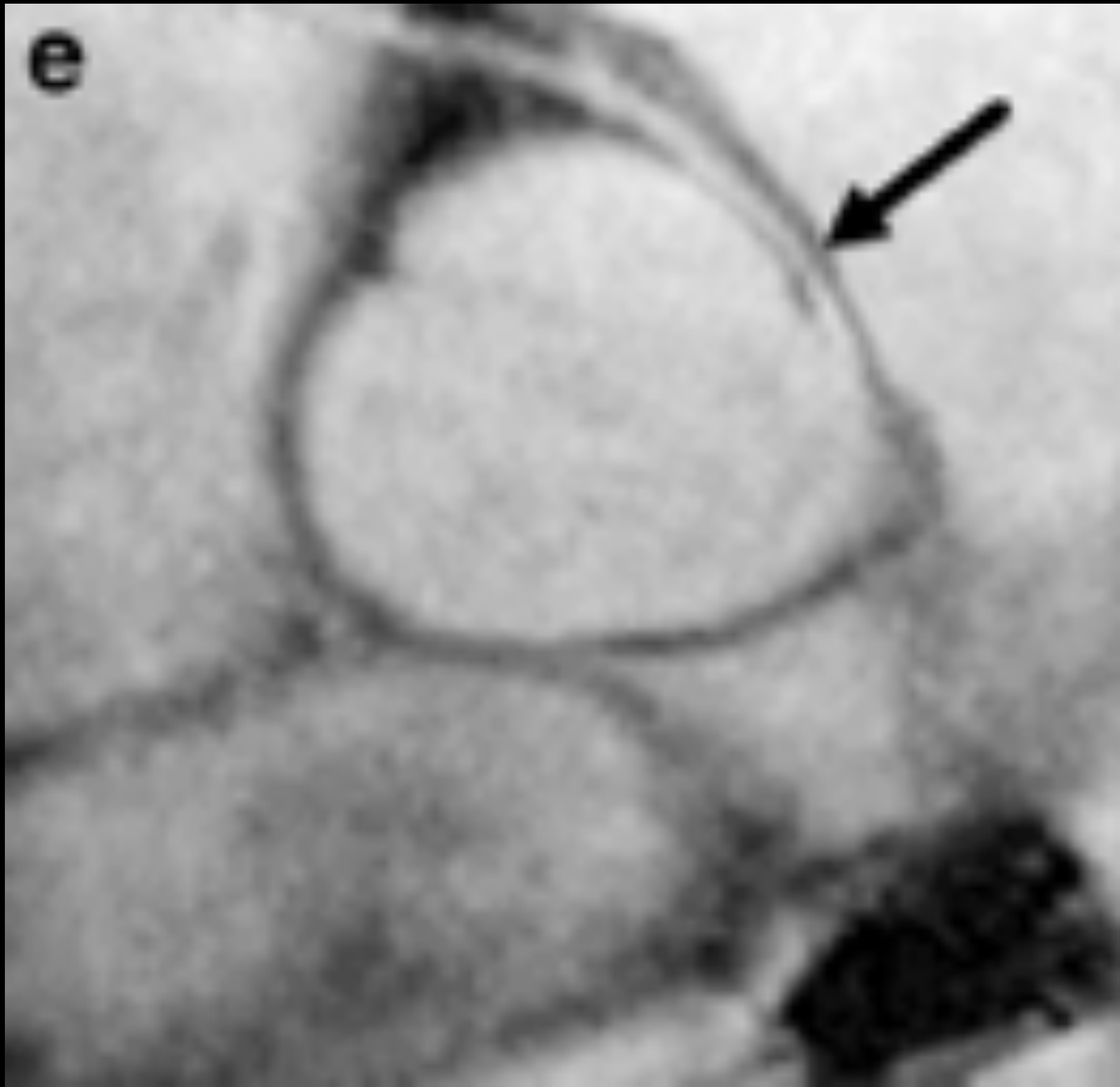
RCA from left ostium



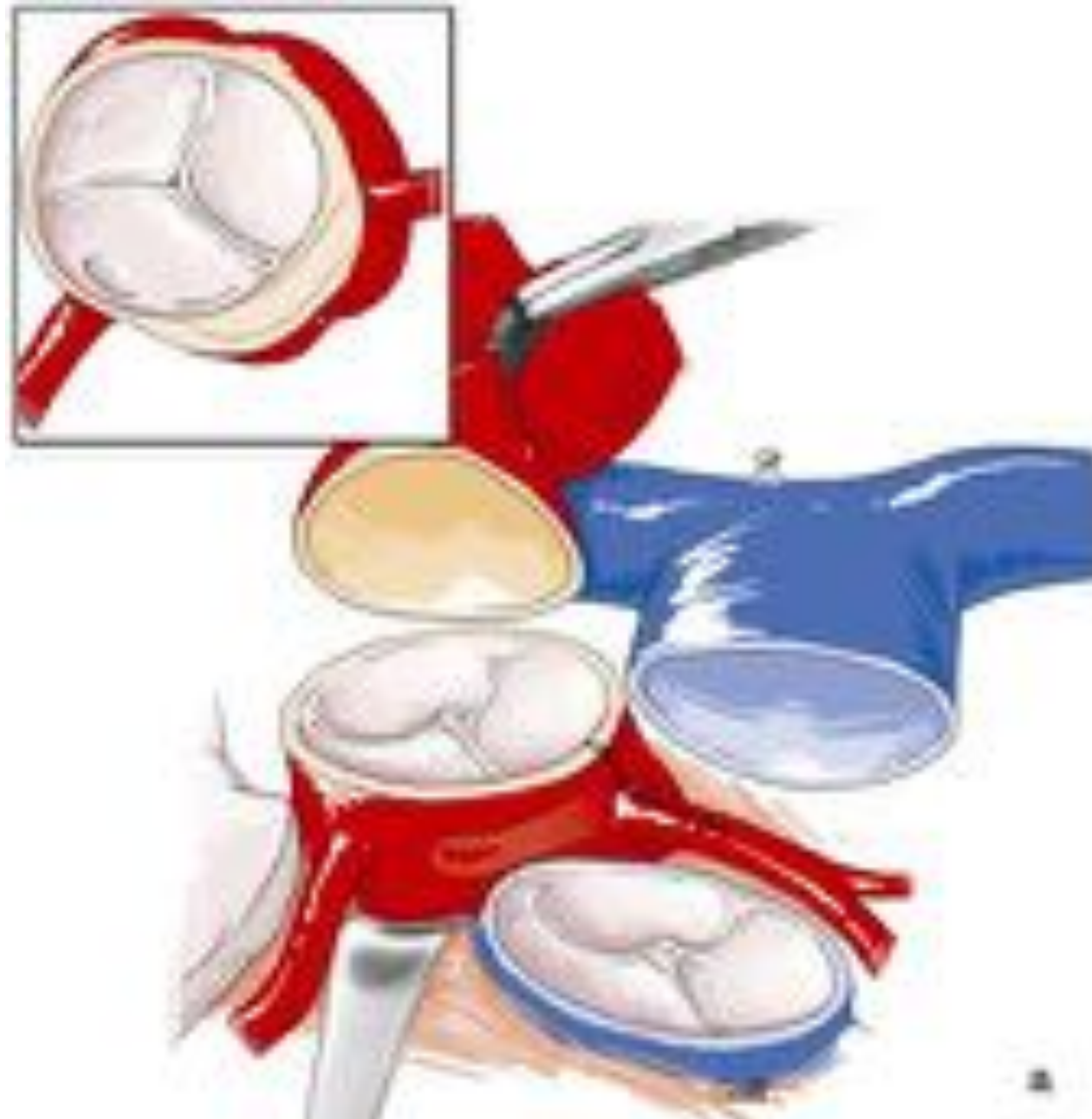
RCA from left ostium



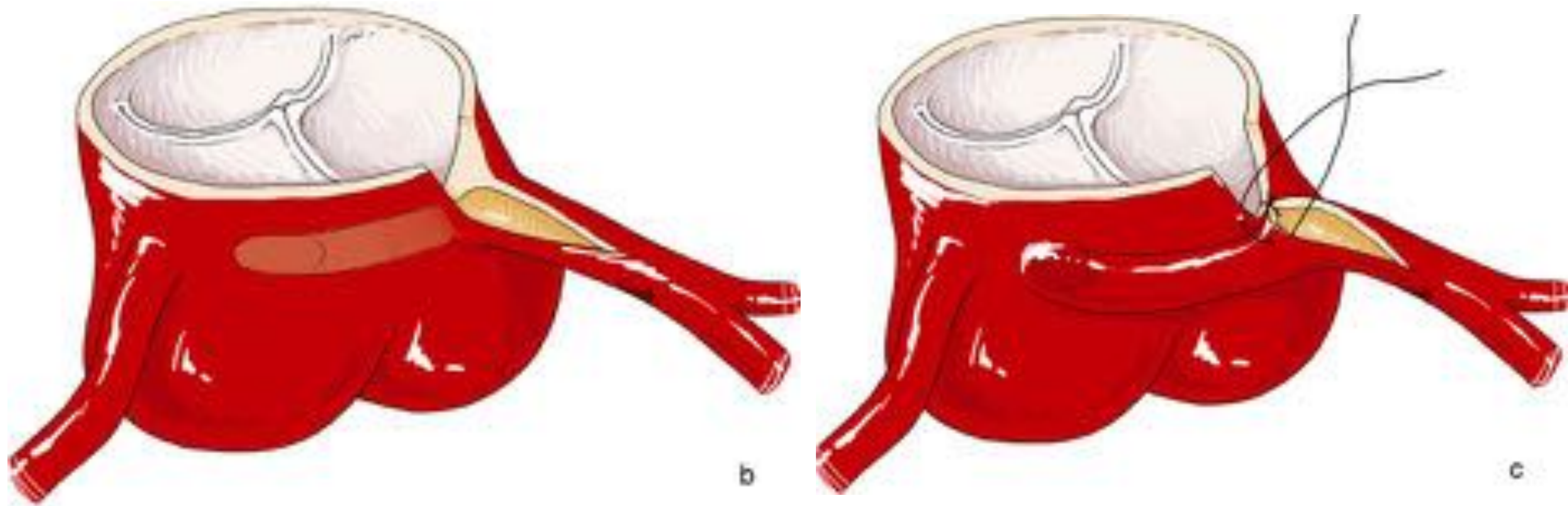
RCA from left ostium



Anatomical repair

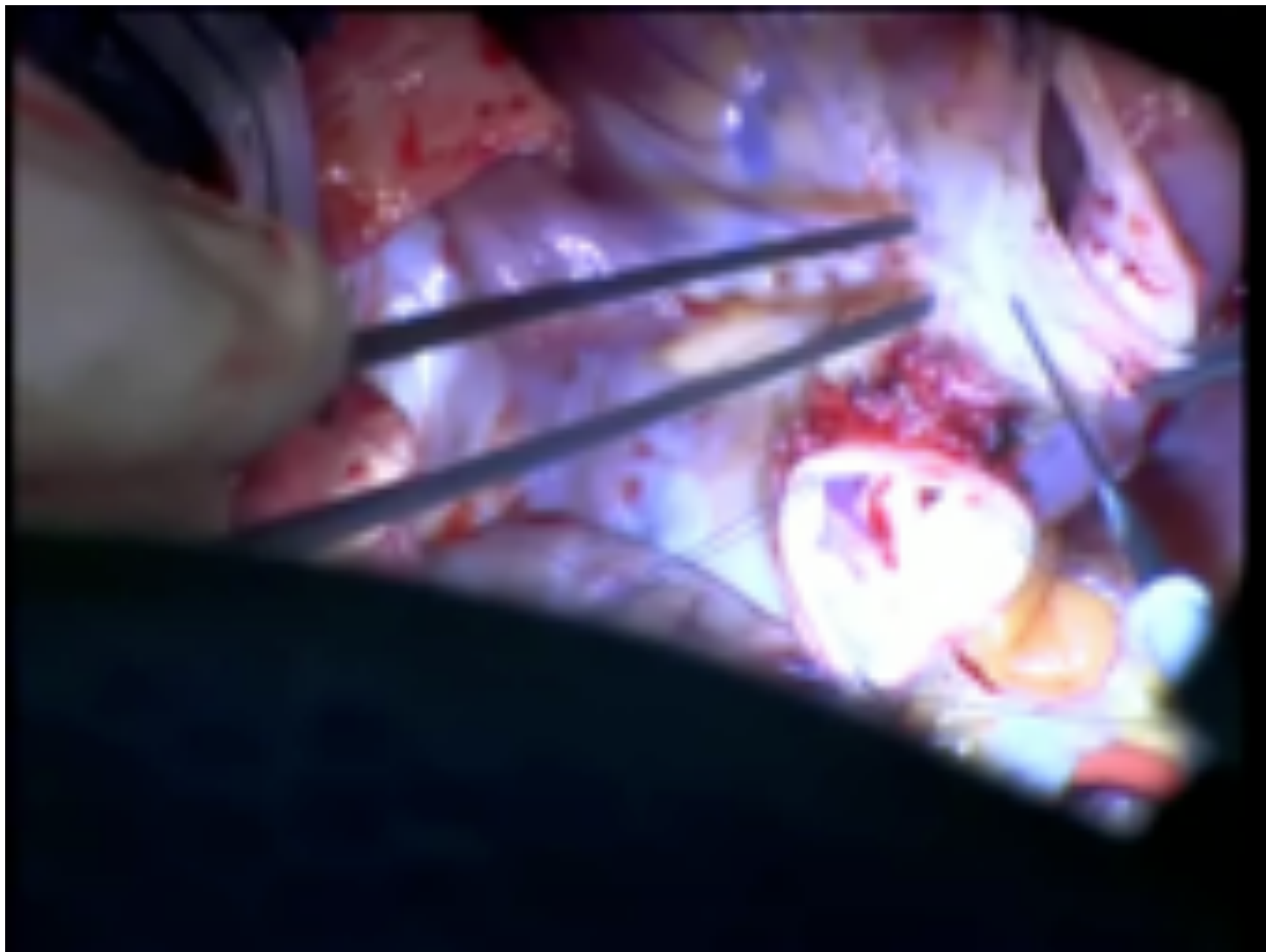


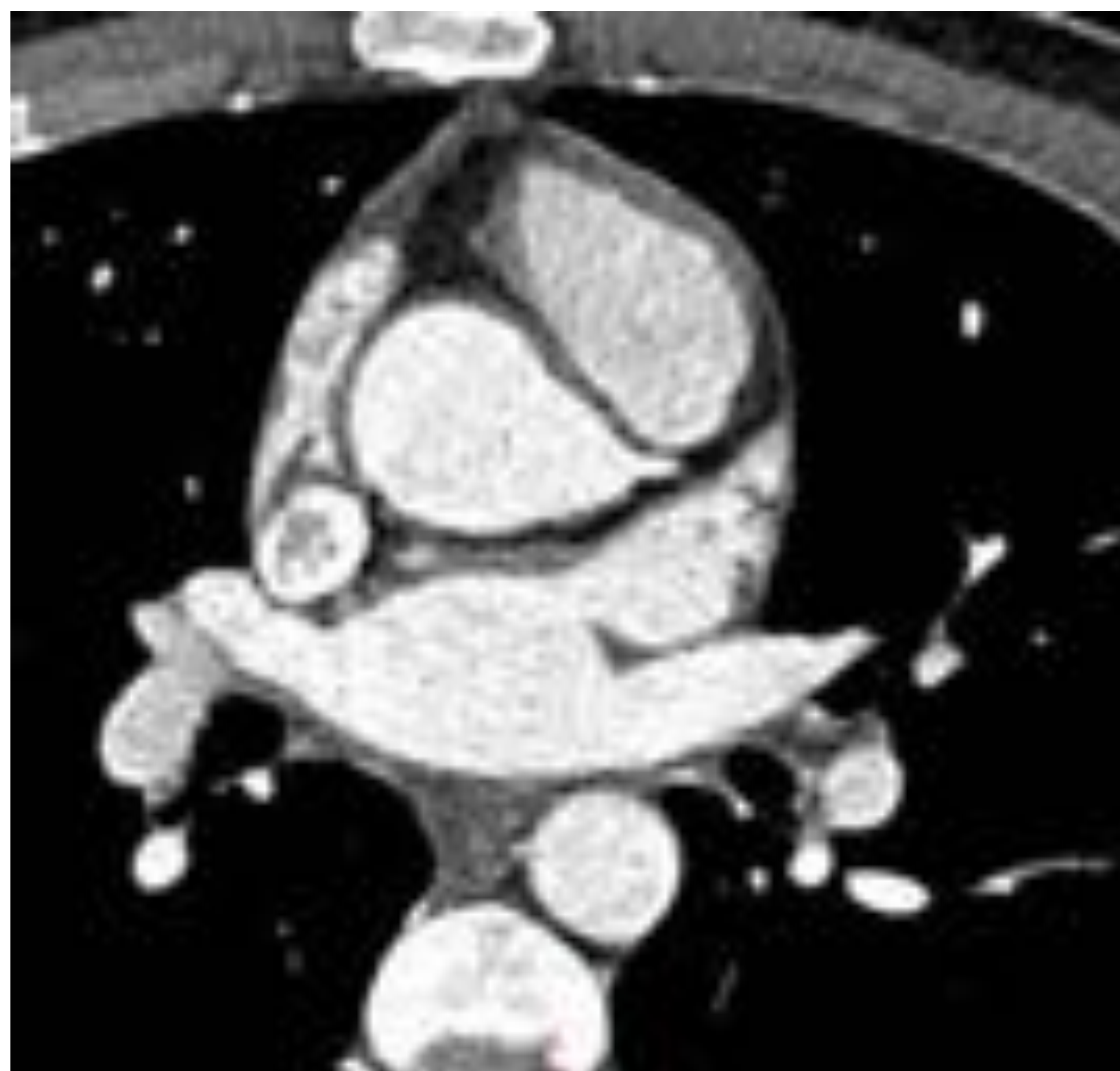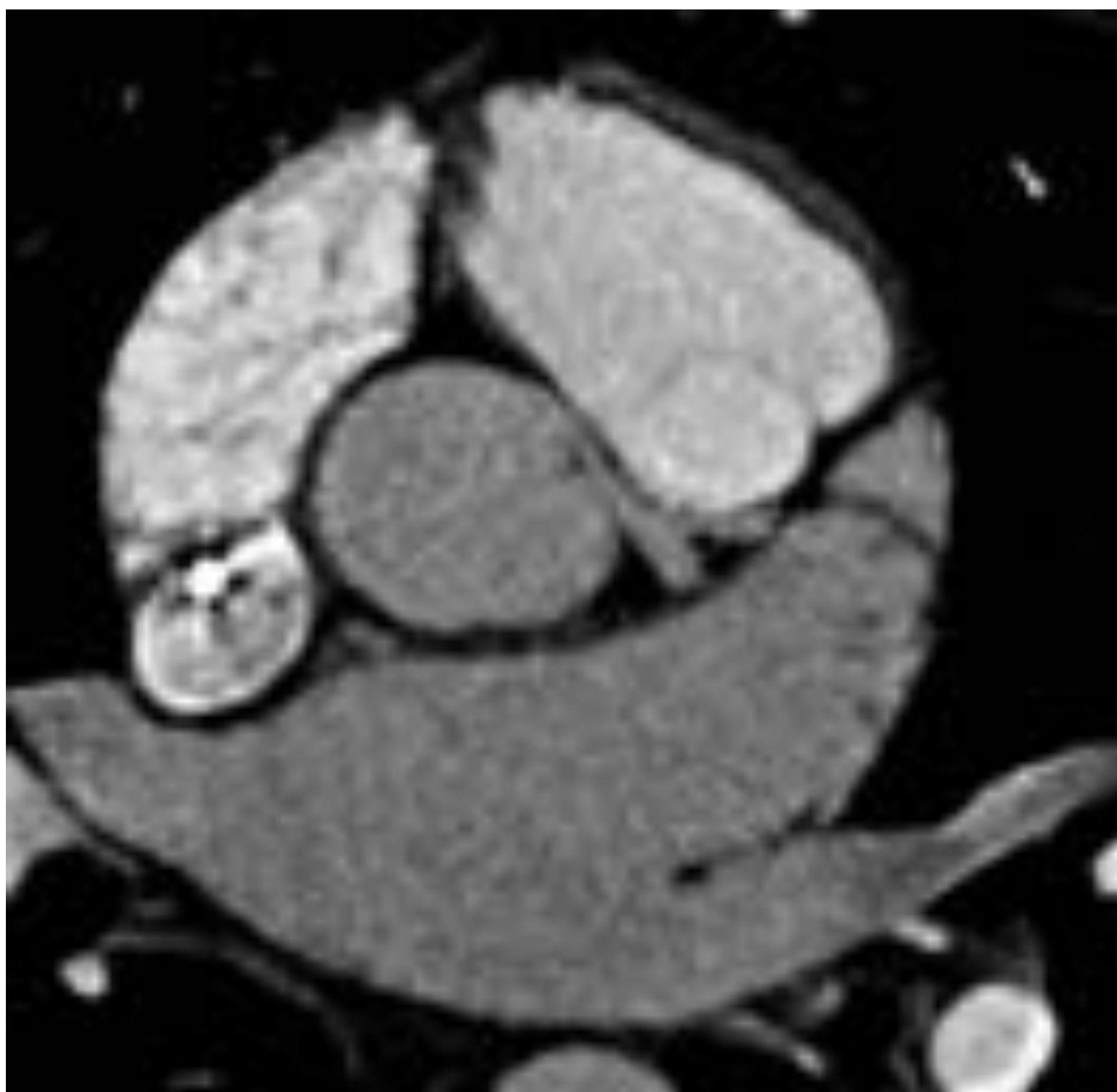
Anatomical repair



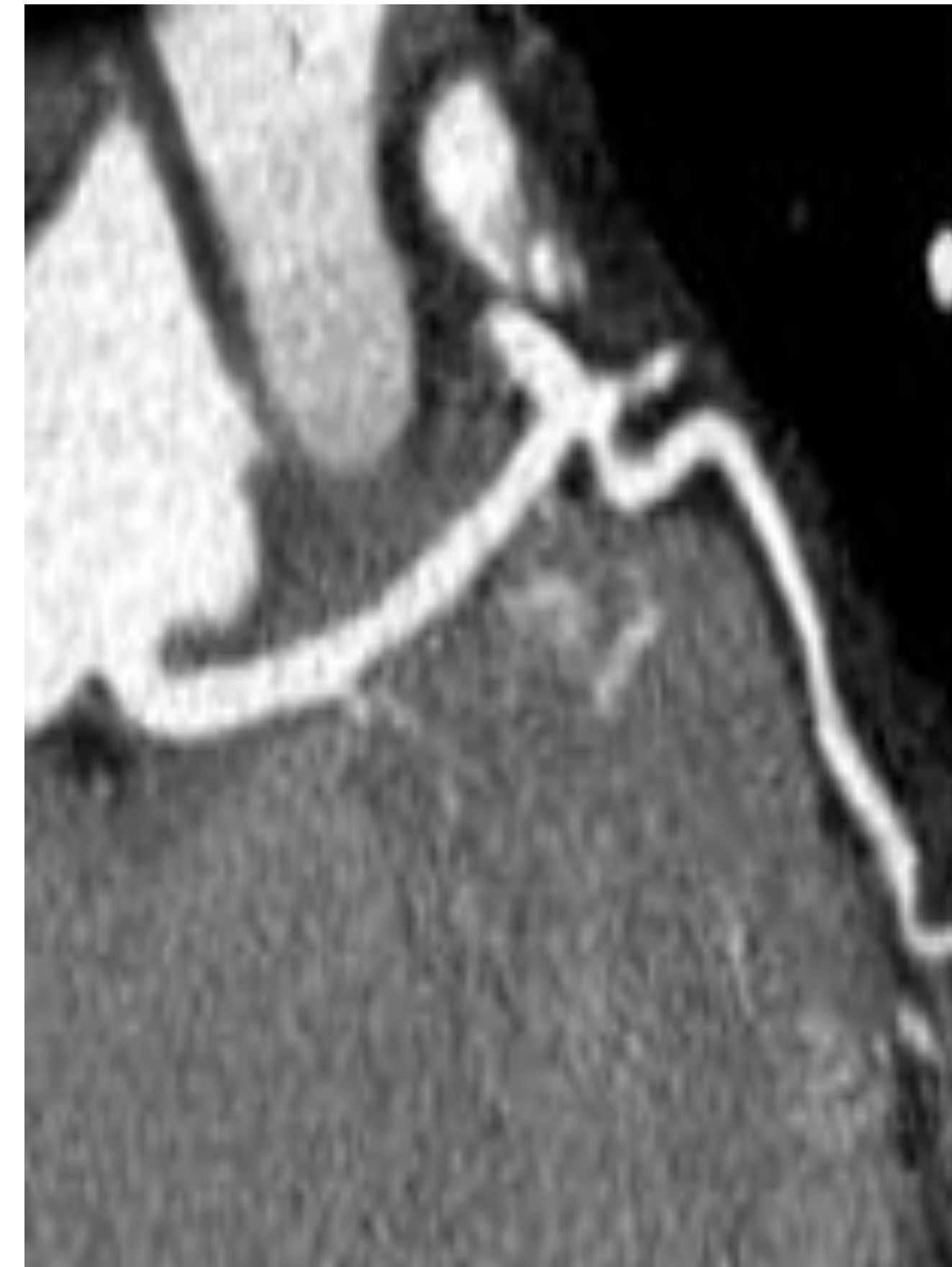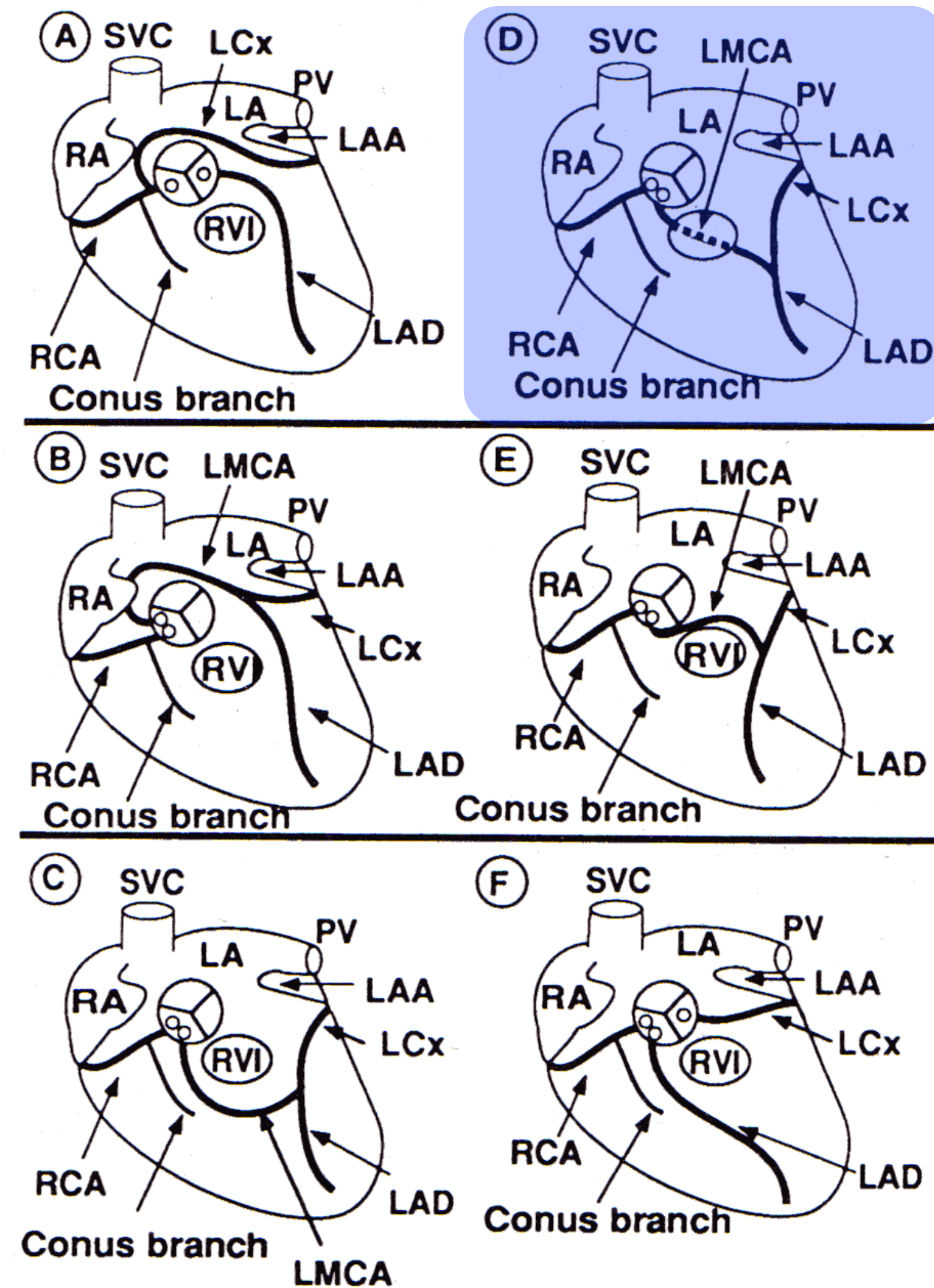
Anatomical repair



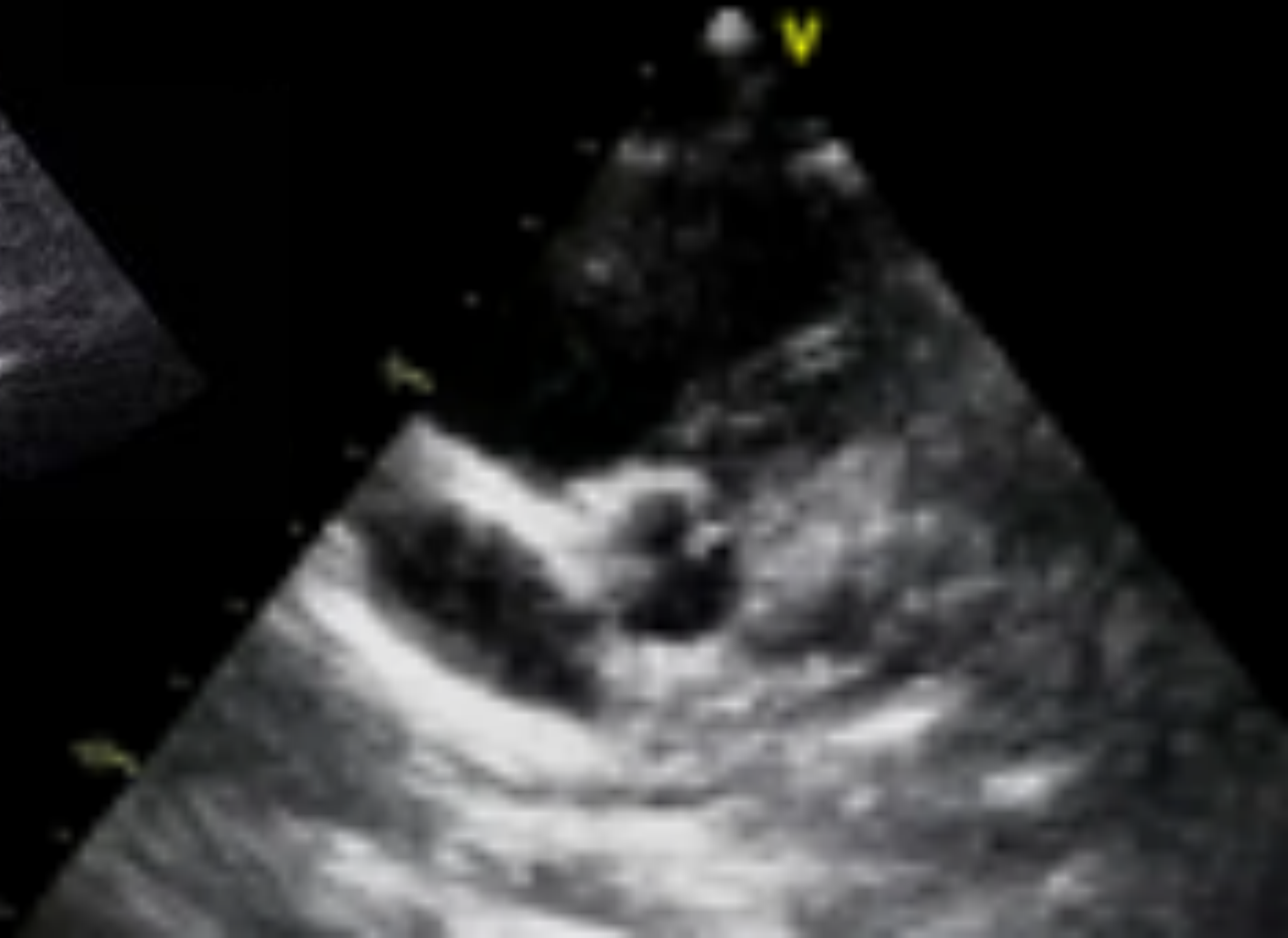
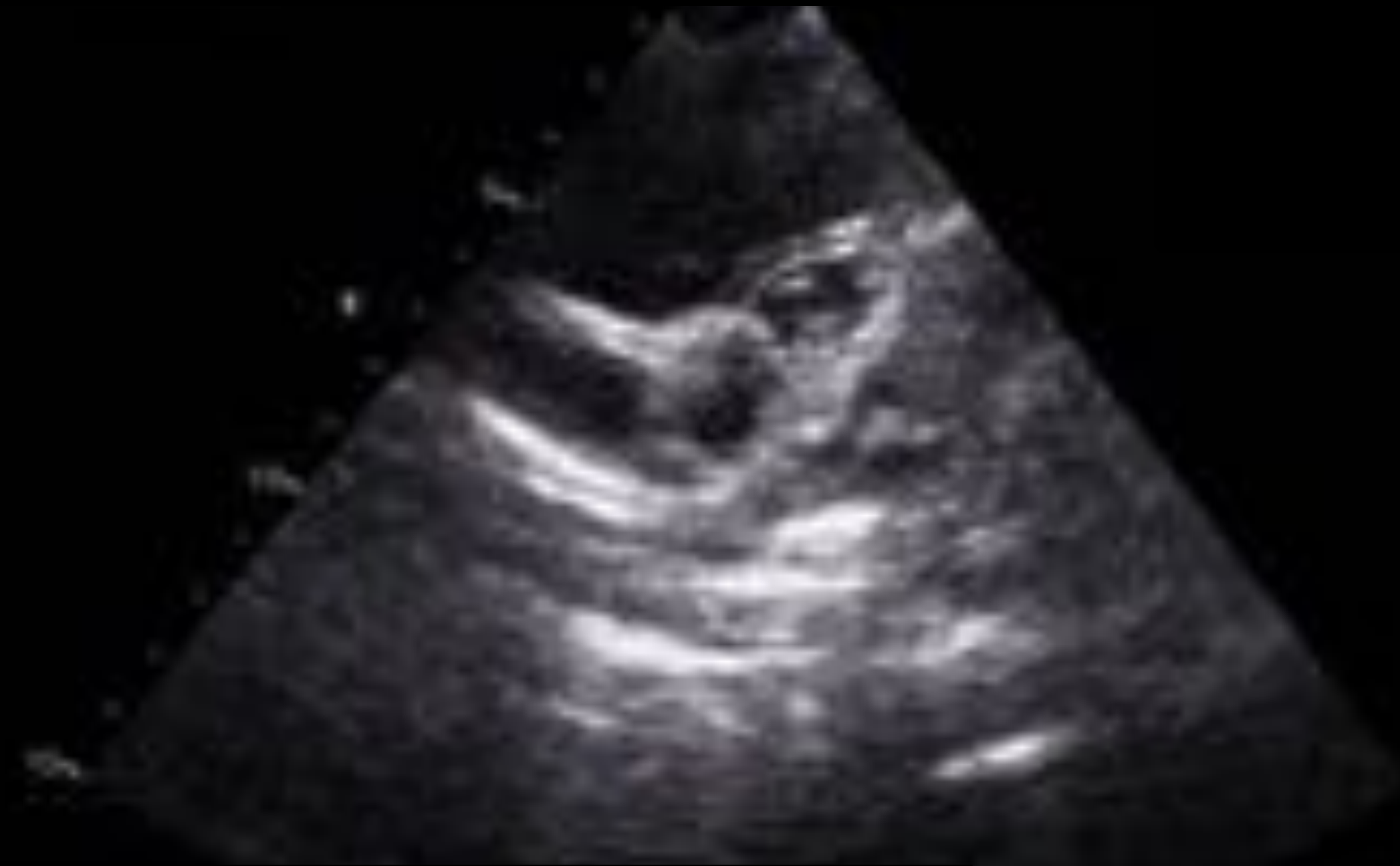


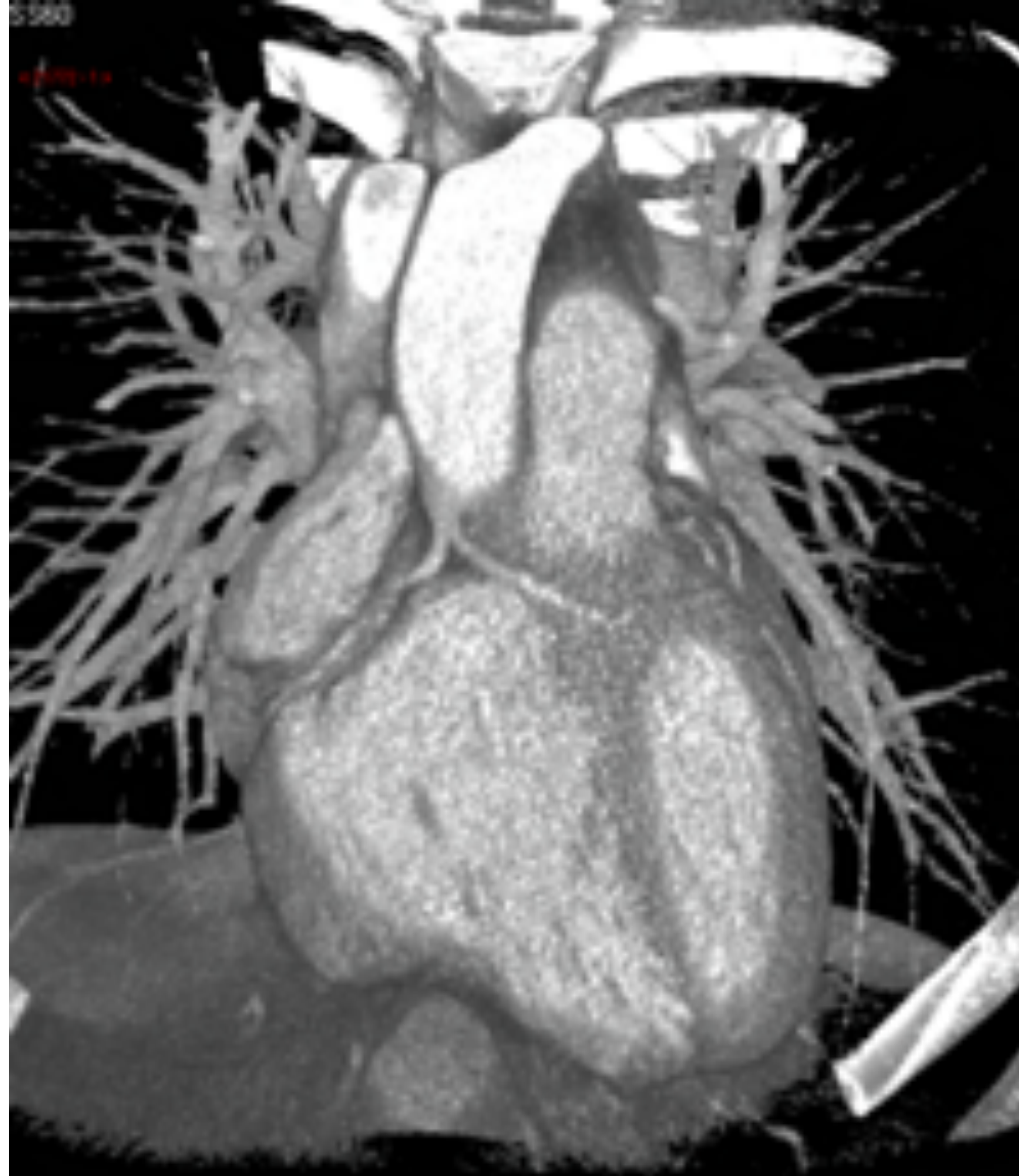Septal course of LAD in the conal septum

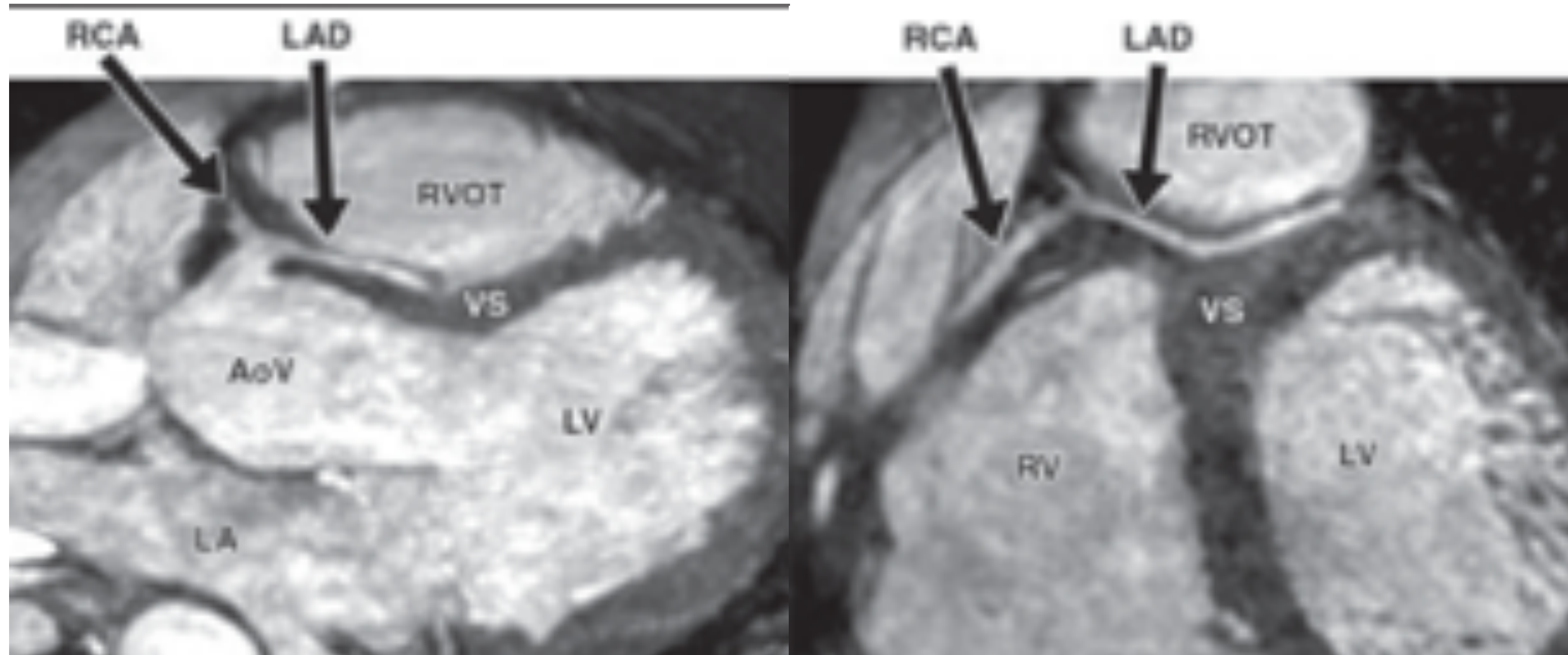


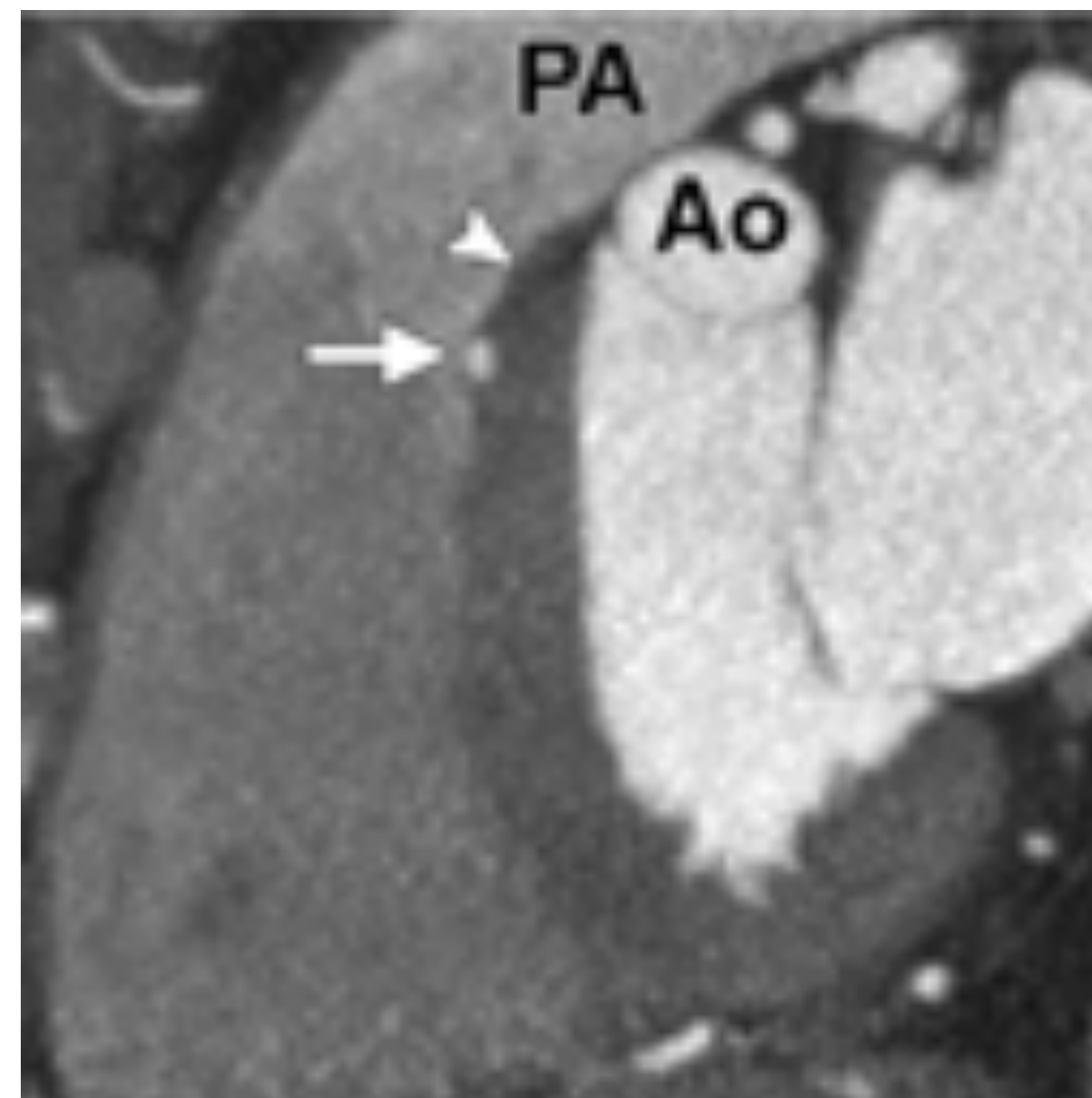
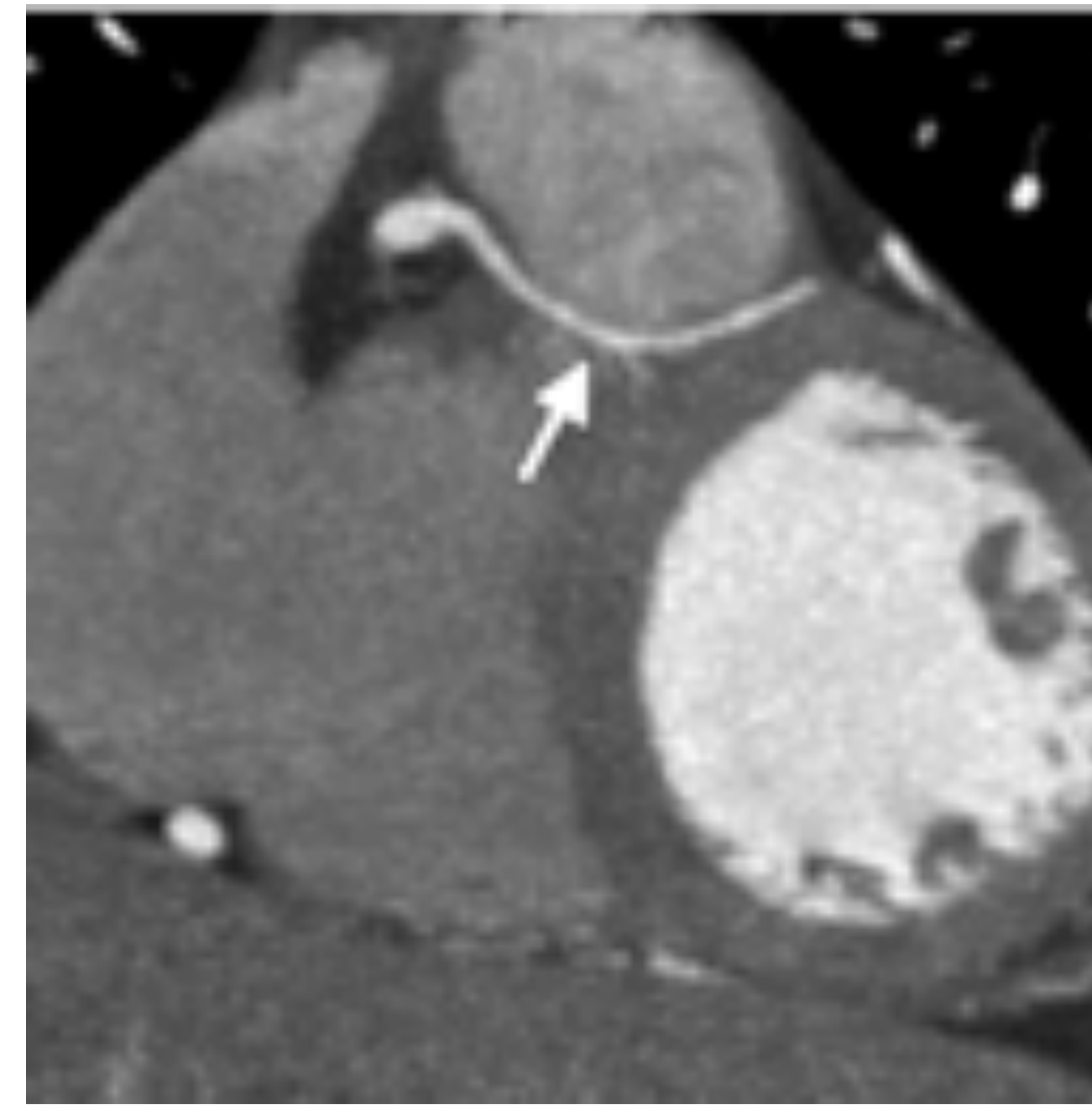
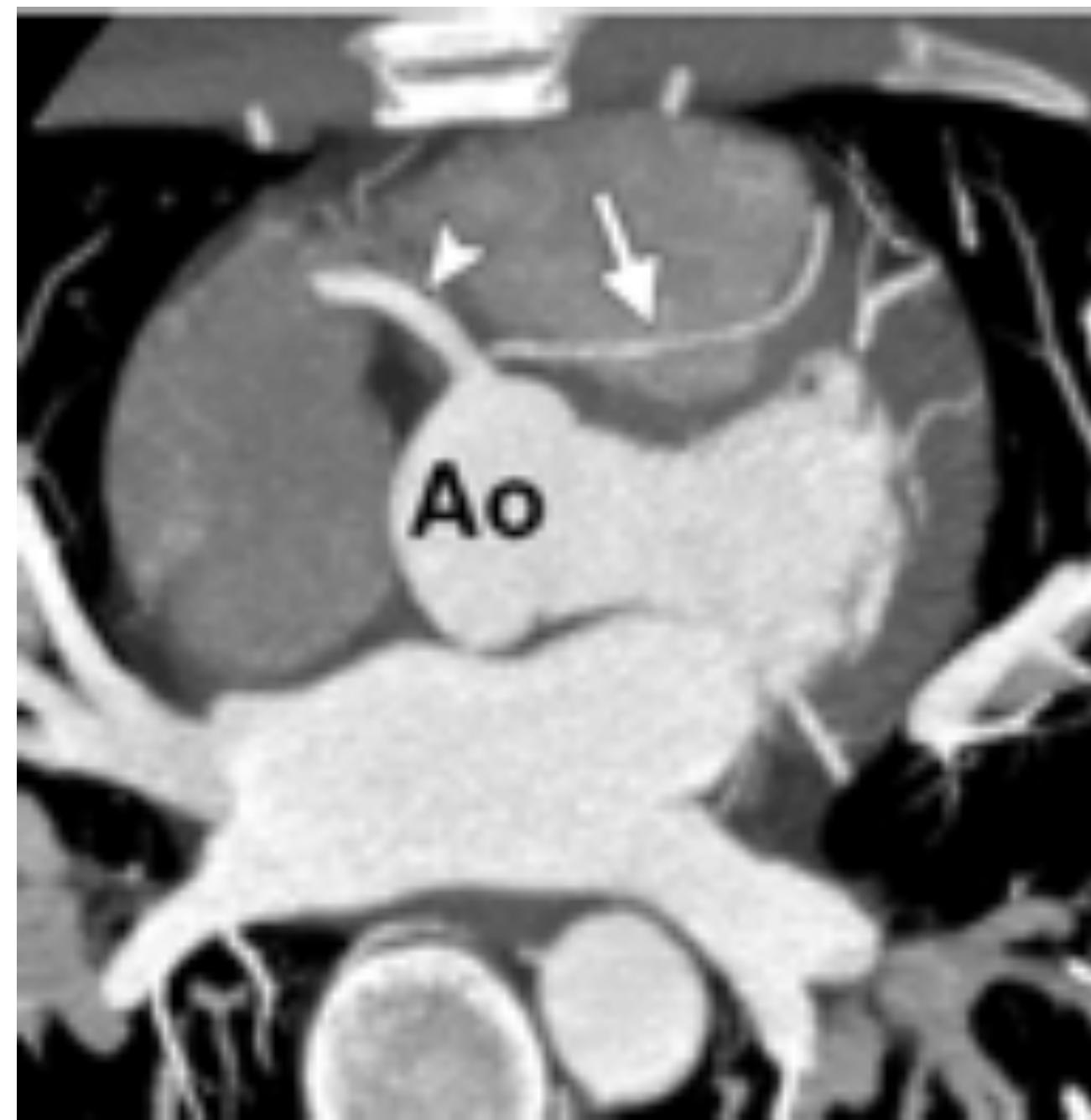Septal course of LAD in the conal septum

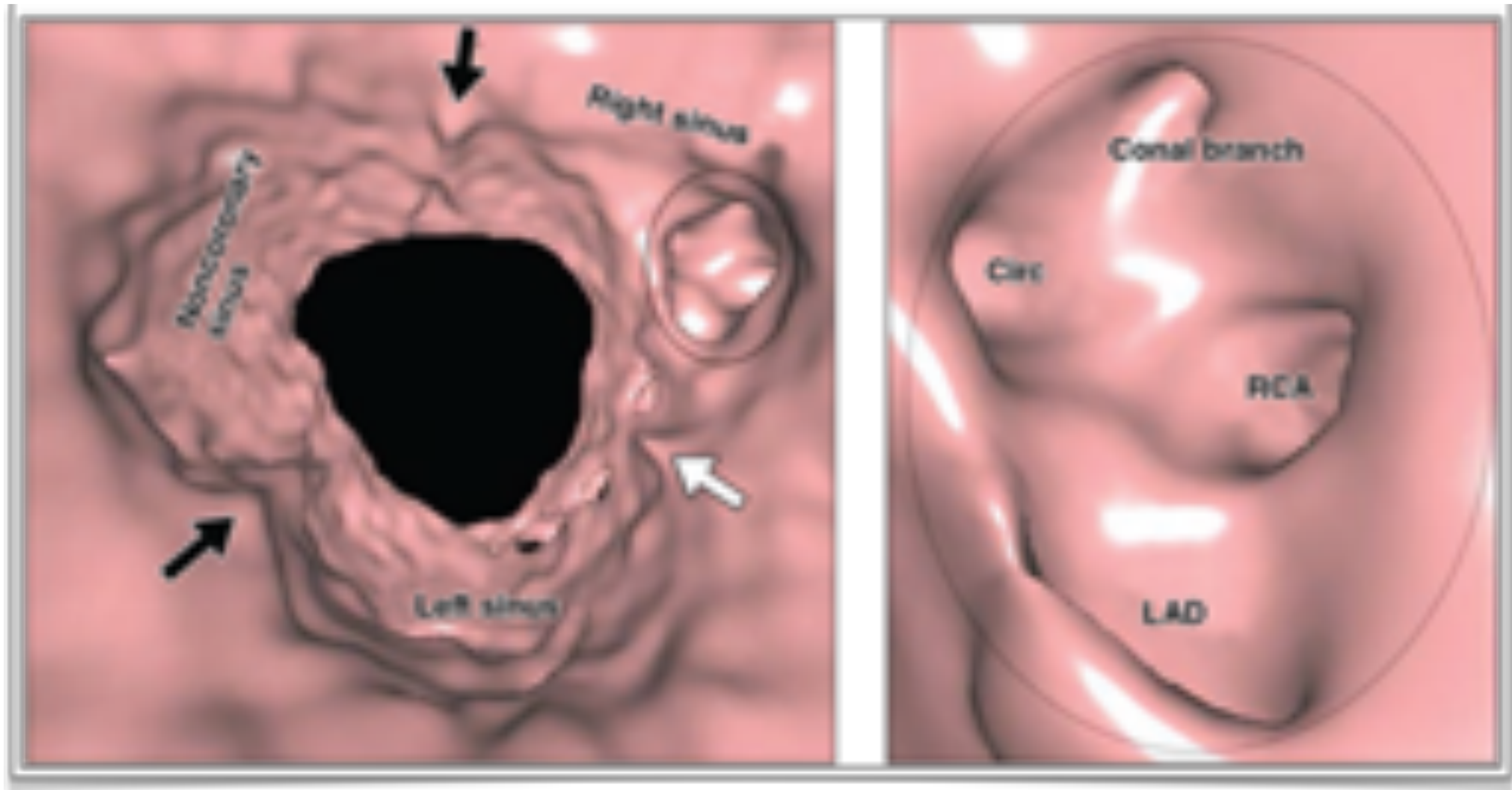




Normal course of LAD in the conal septum



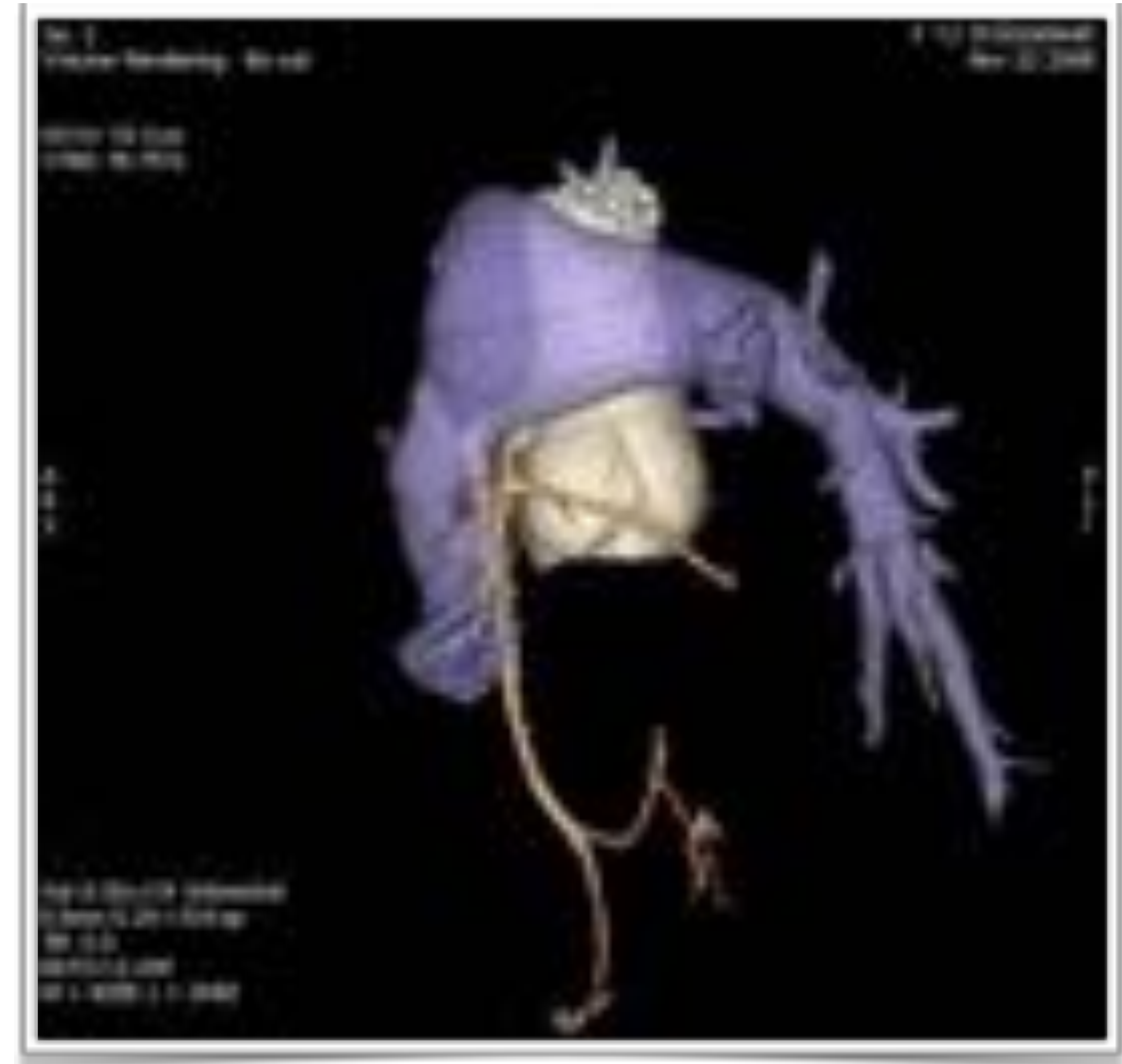
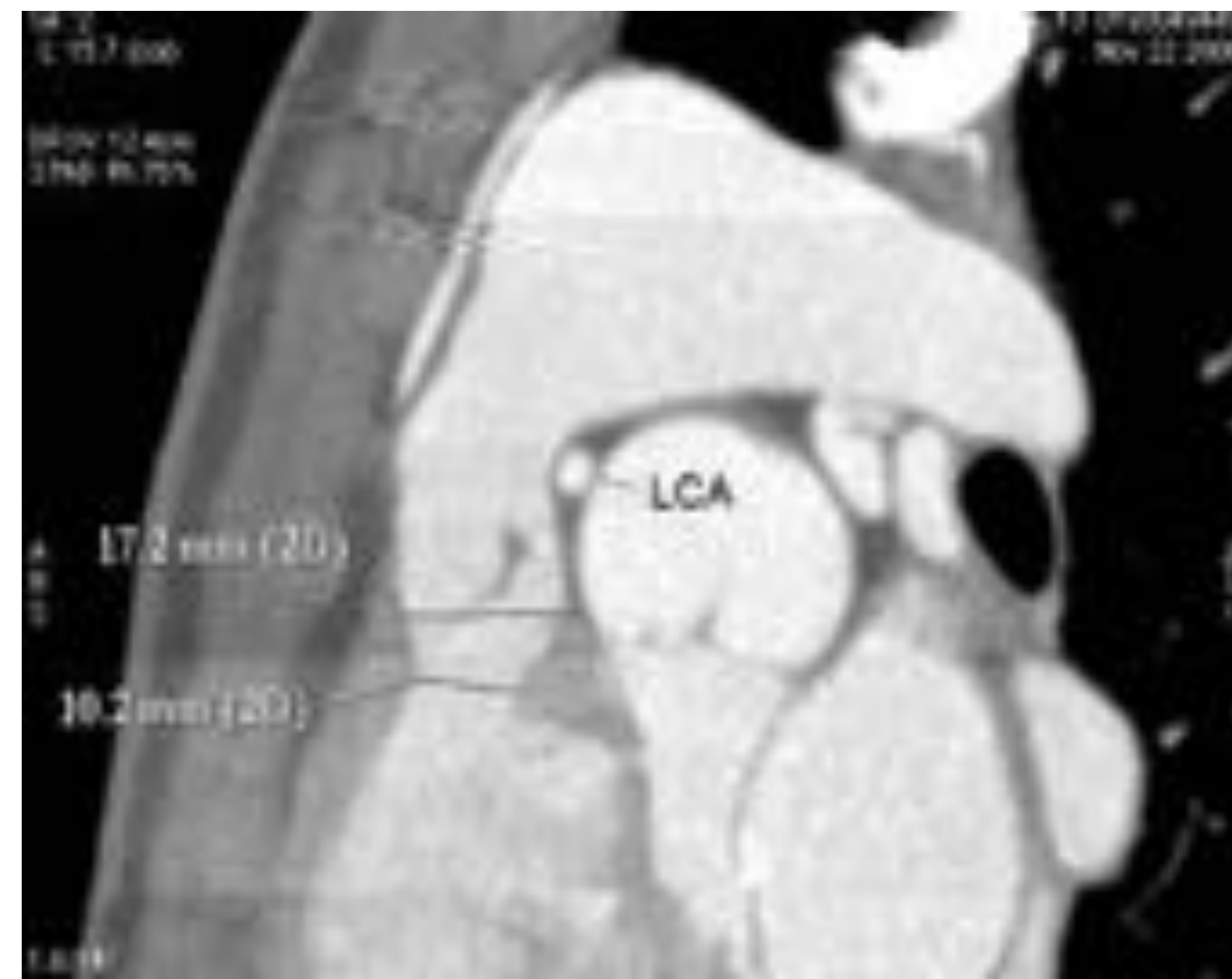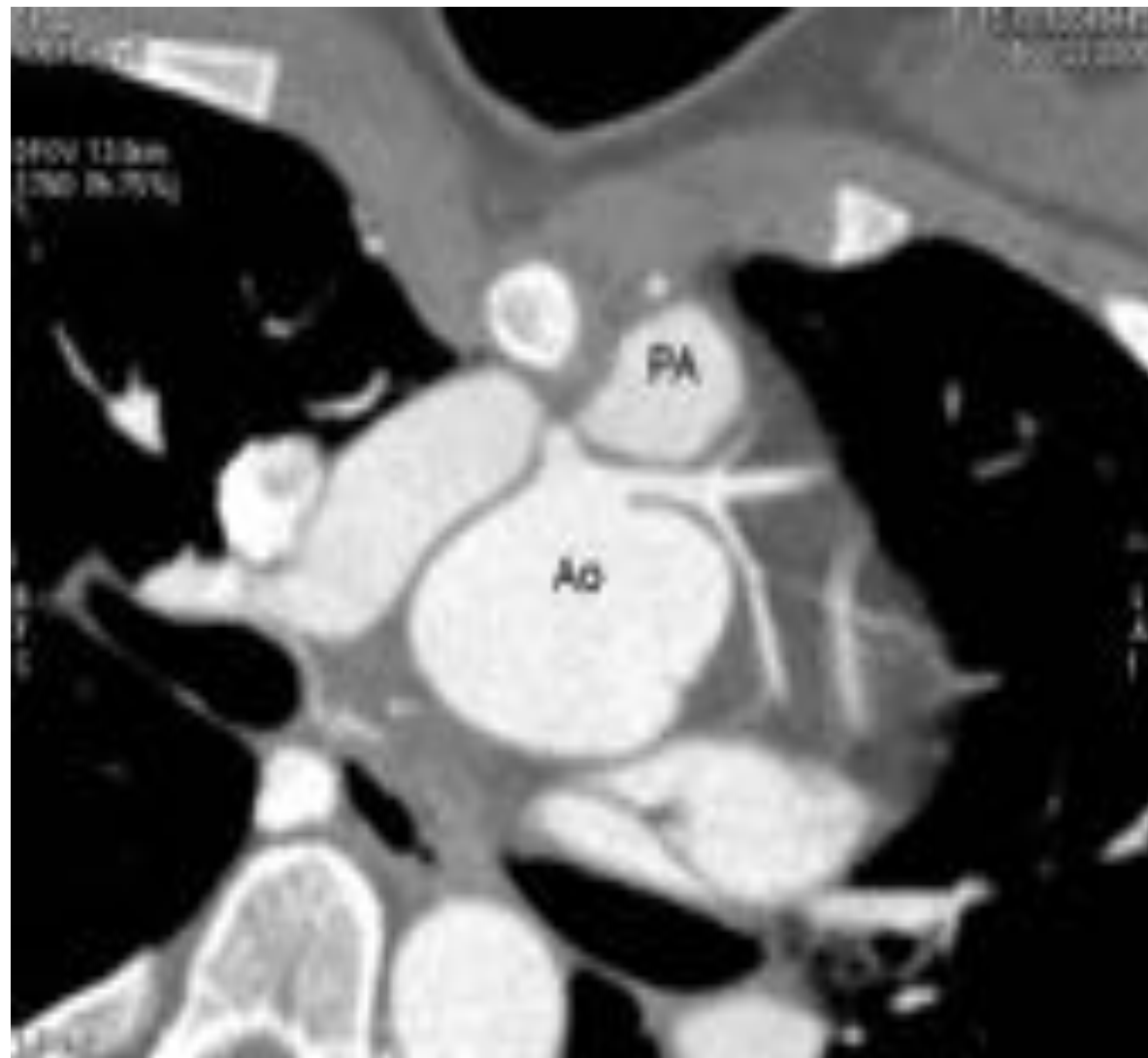




Intraseptal left anterior descending coronary artery

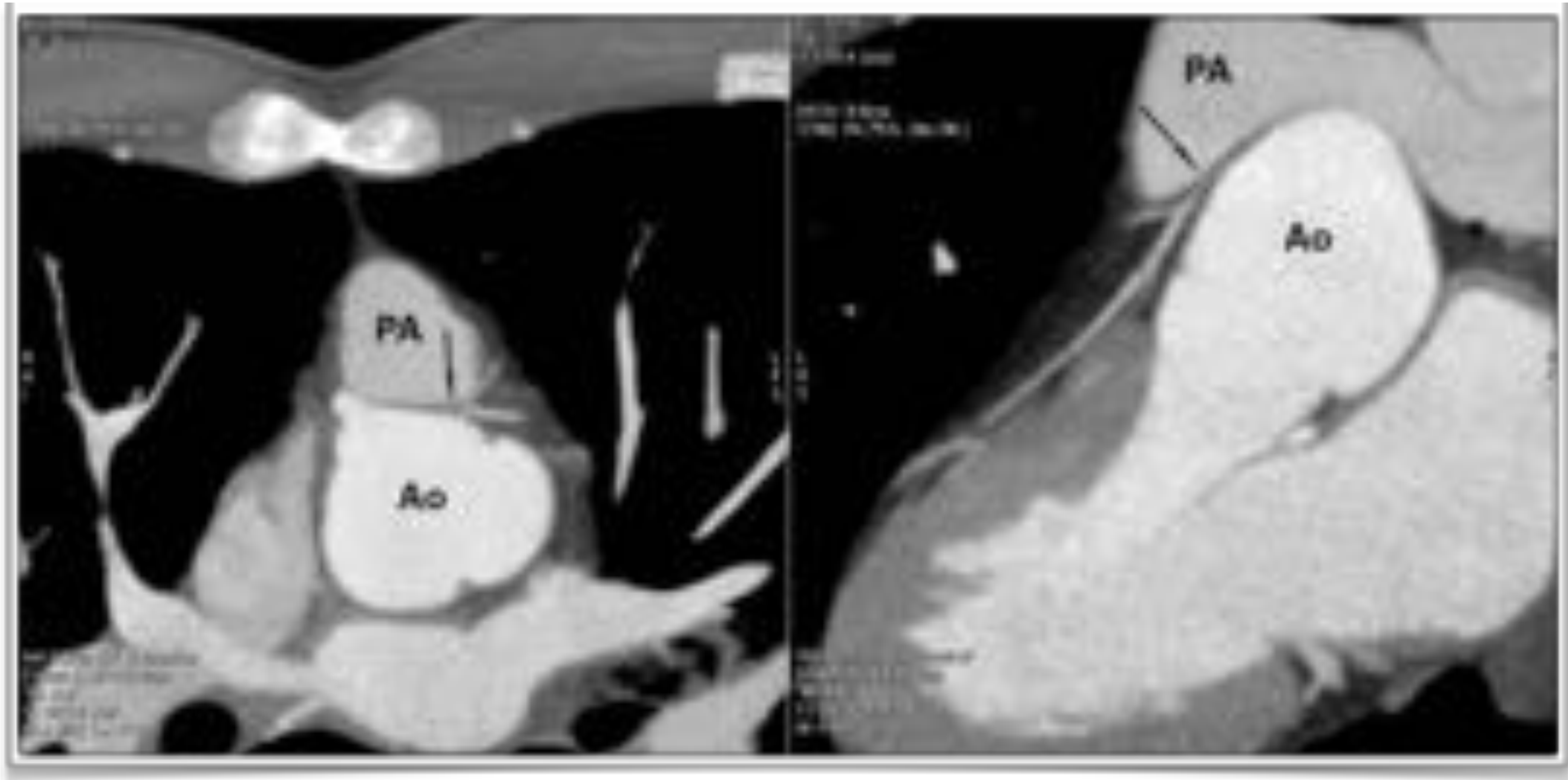
Acquired inter arterial course of coronary arteries

CT after arterial switch operation for TGA Abnormal course



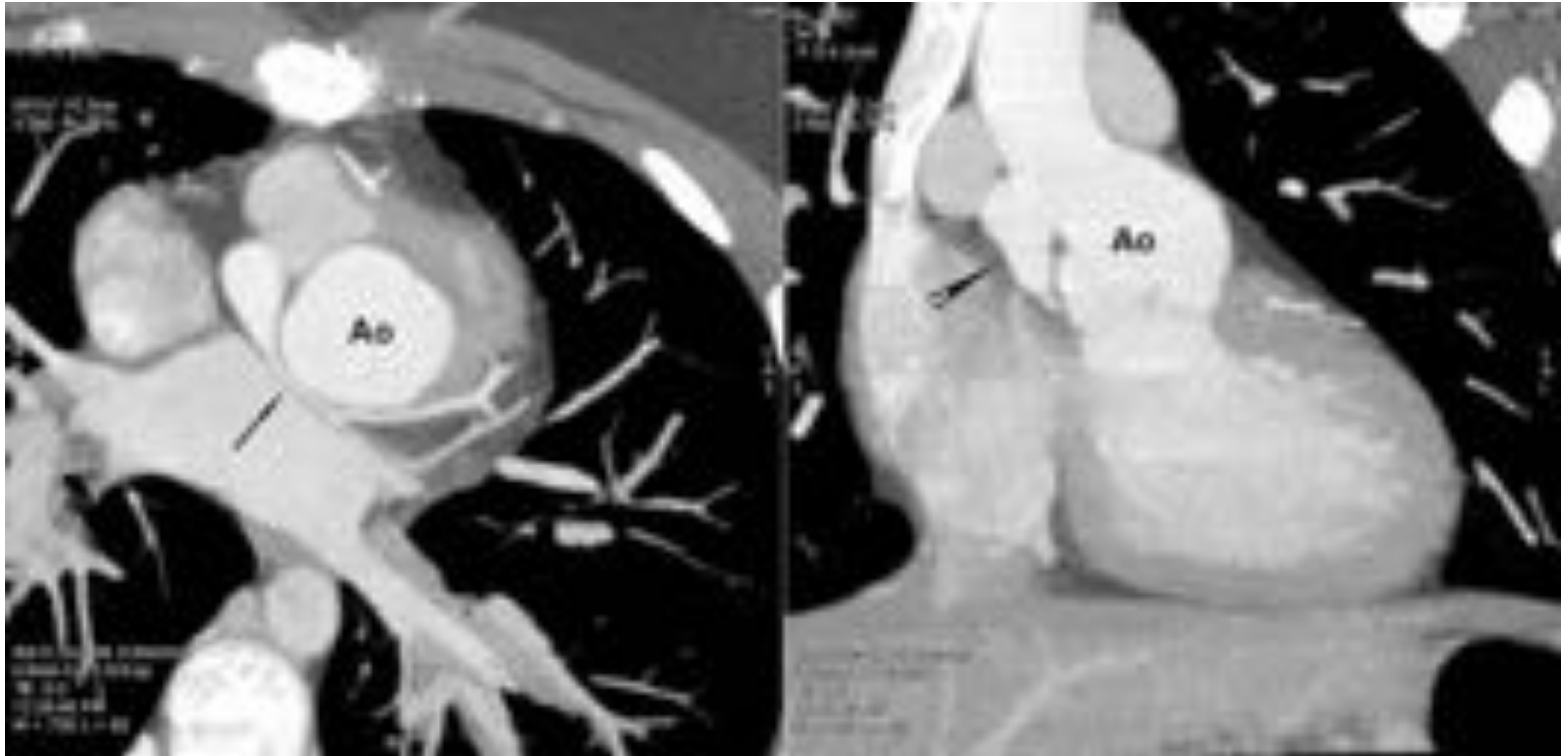Acquired inter arterial course of coronary arteries

CT after arterial switch operation for TGA Intramural left main CA

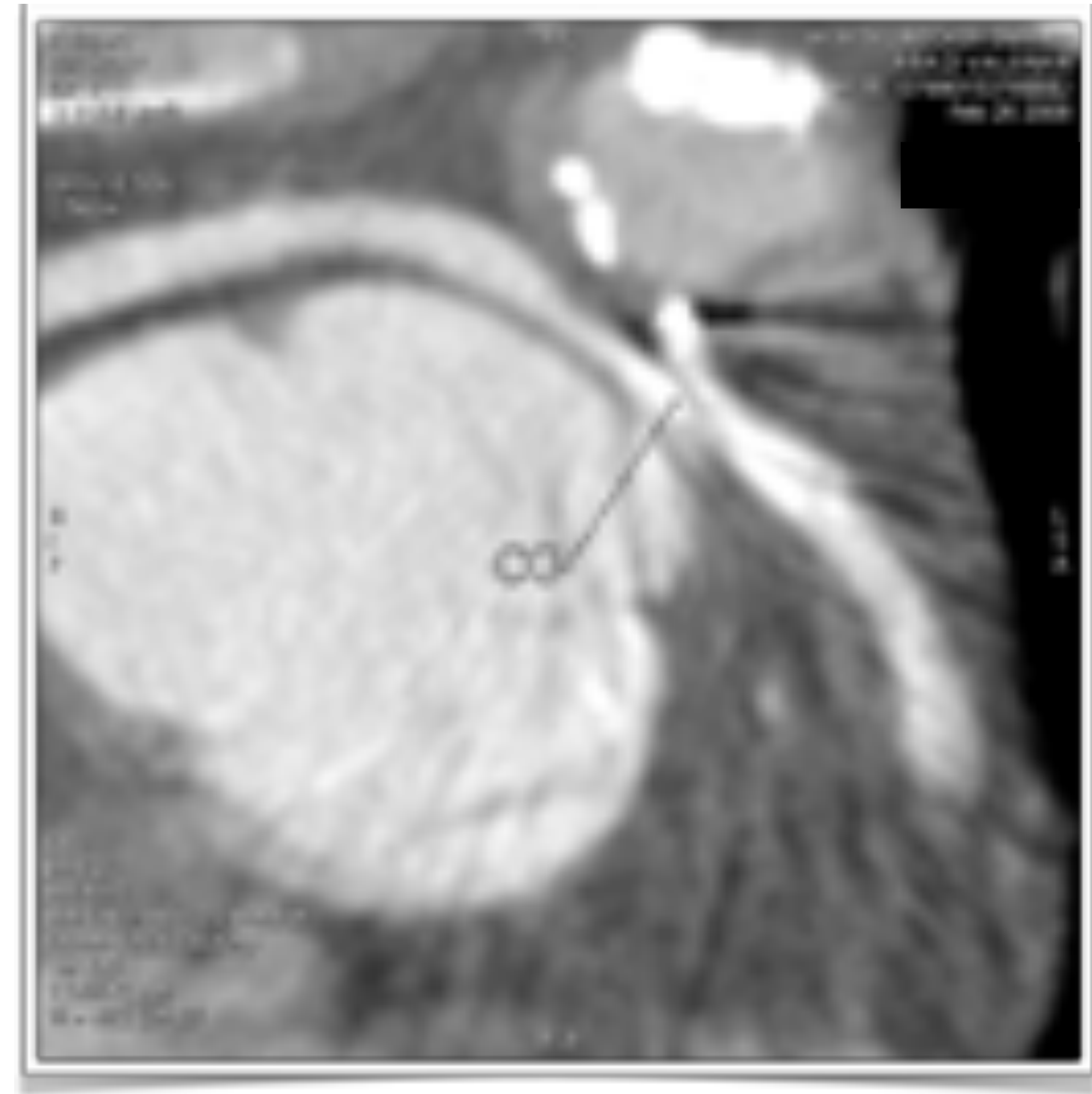
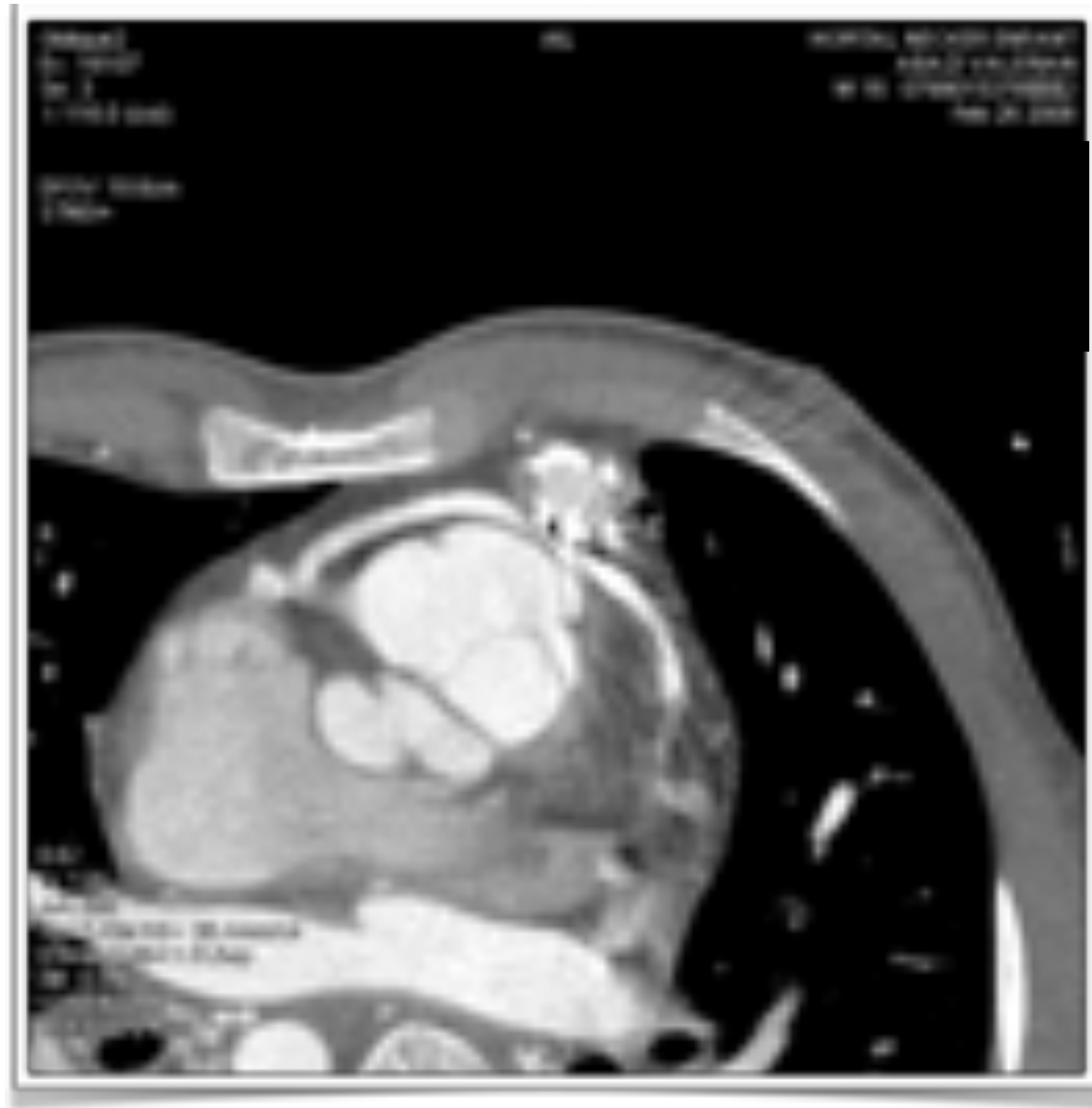
CT after arterial switch operation for TGA

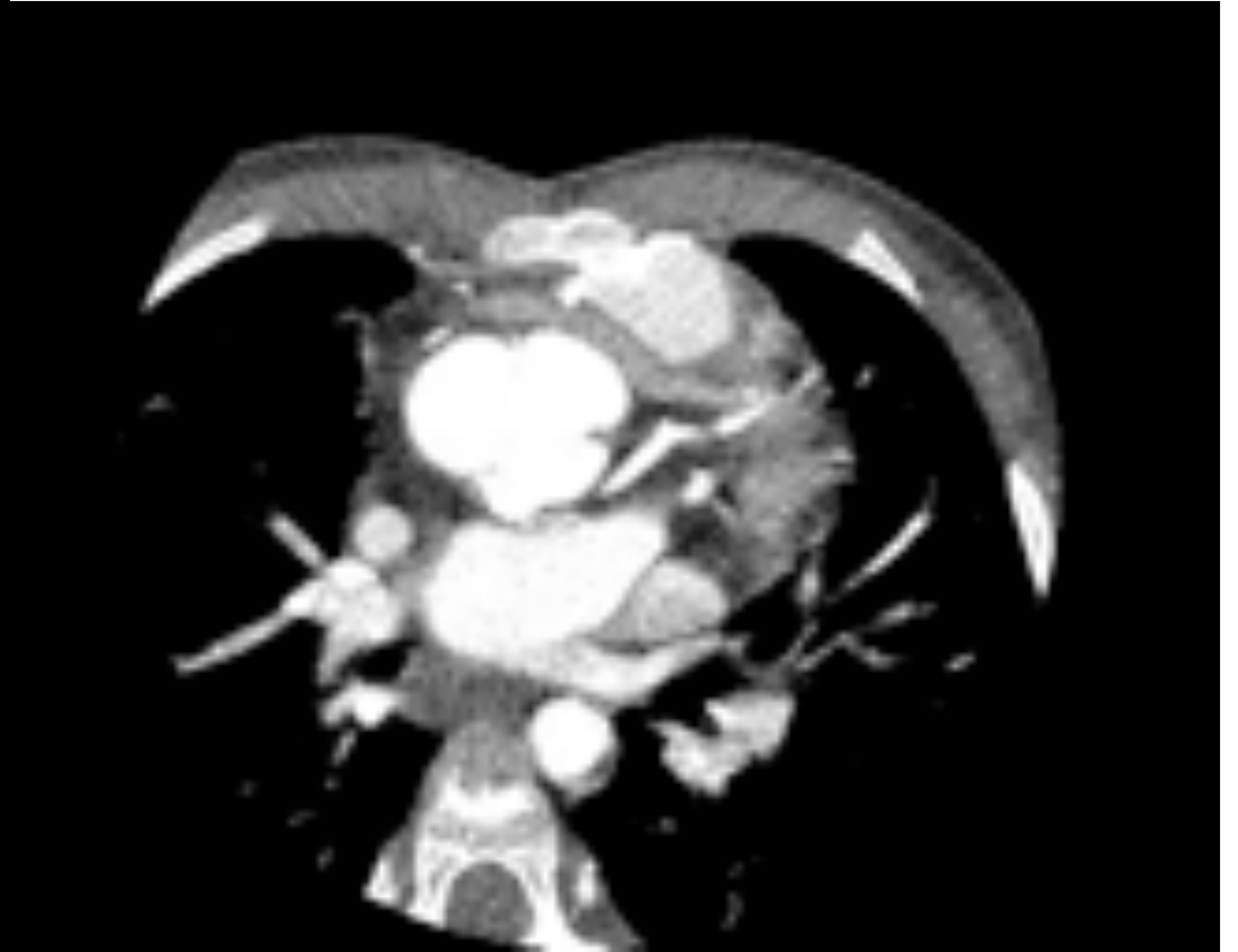
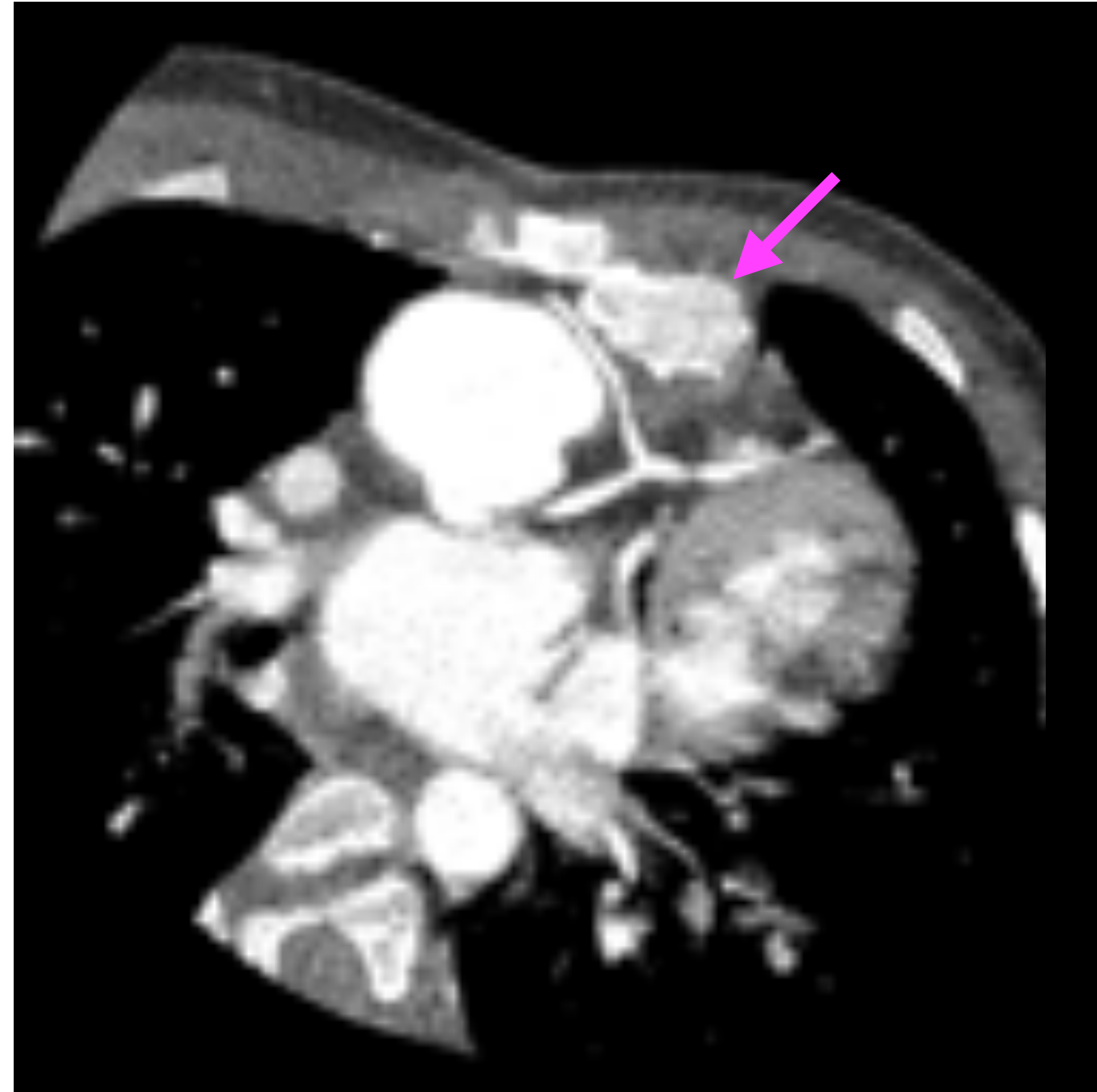Retroaortic course LMCA



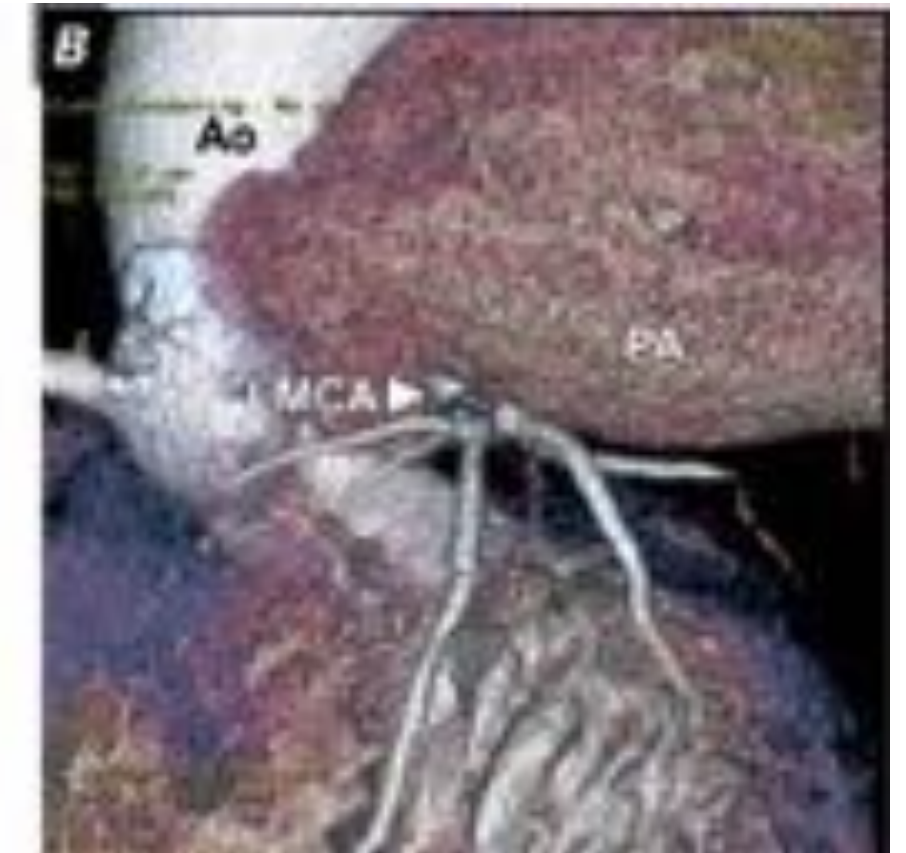
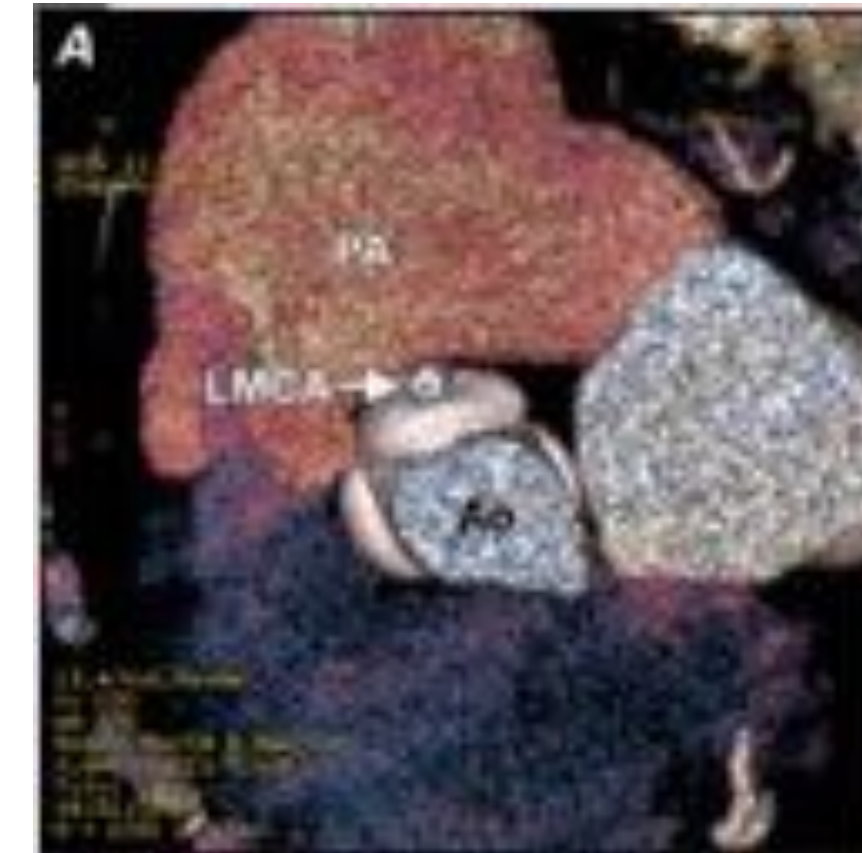
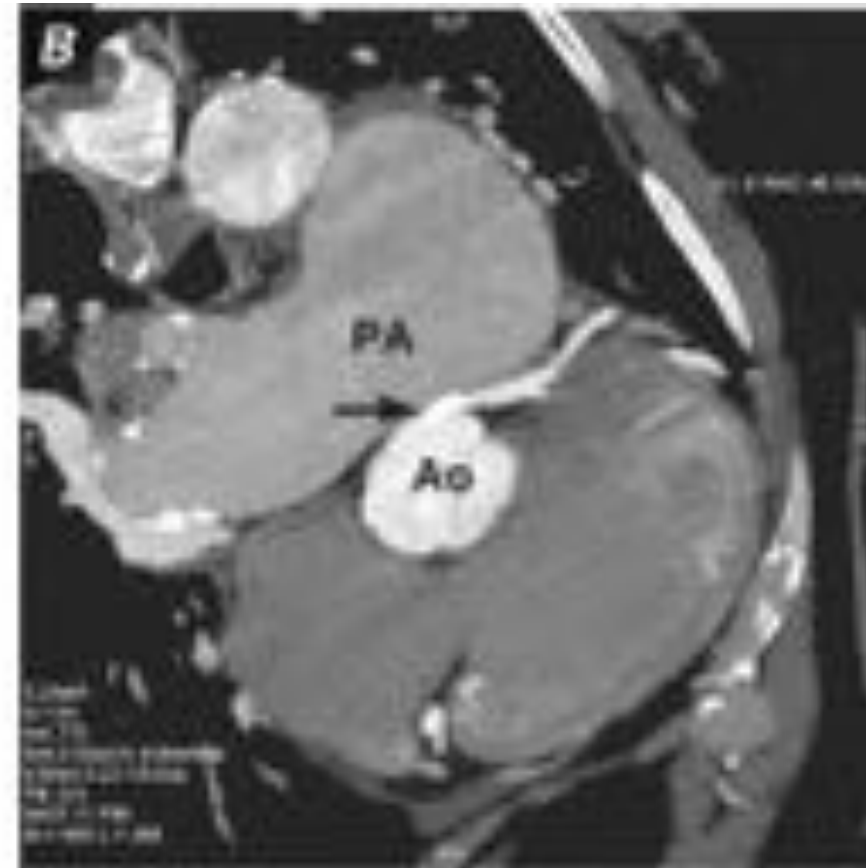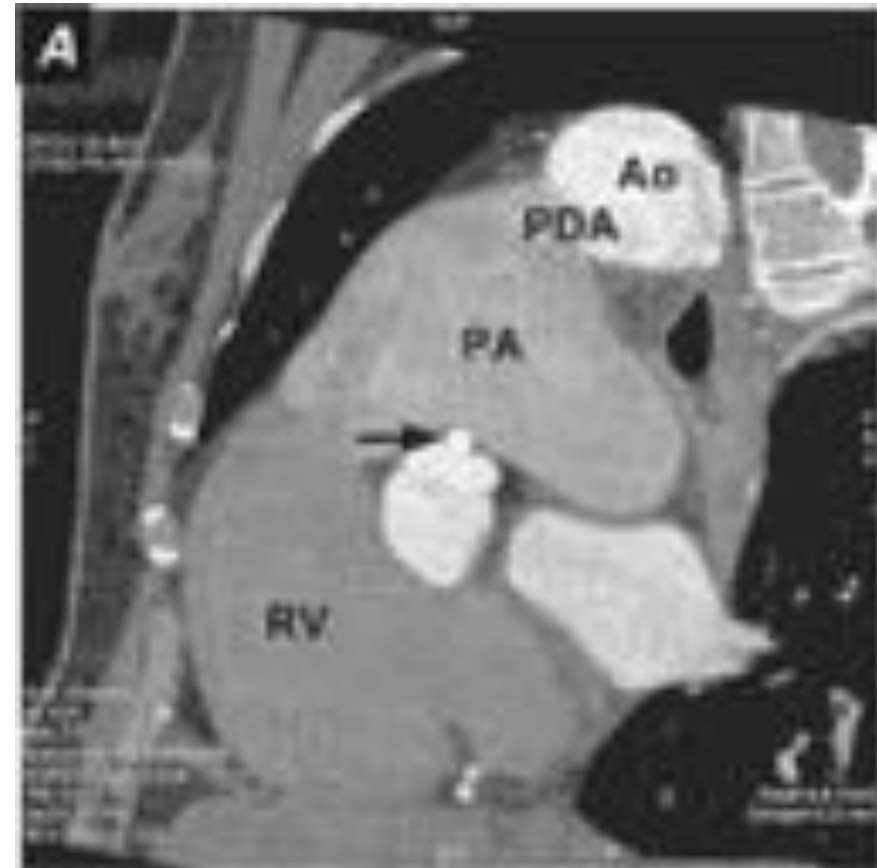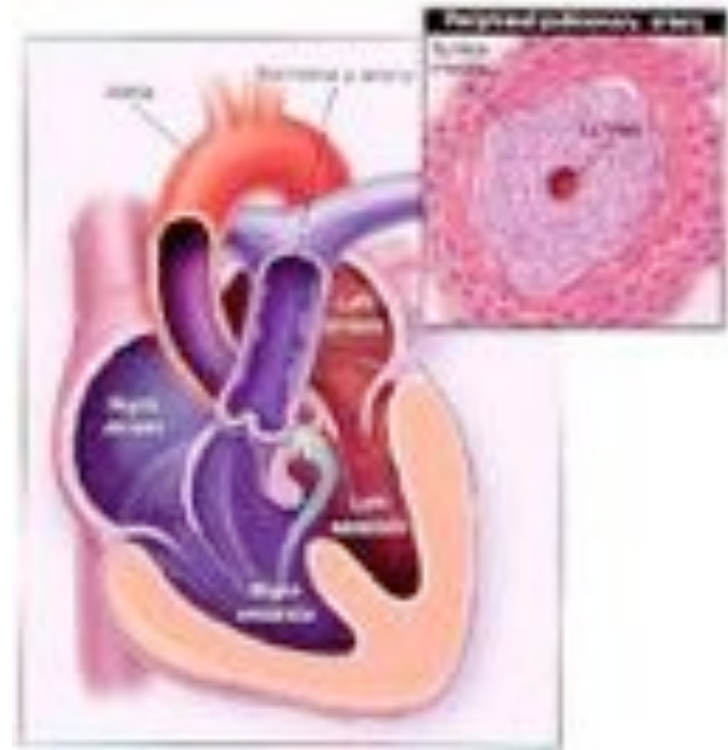Acquired inter arterial course of coronary arteries



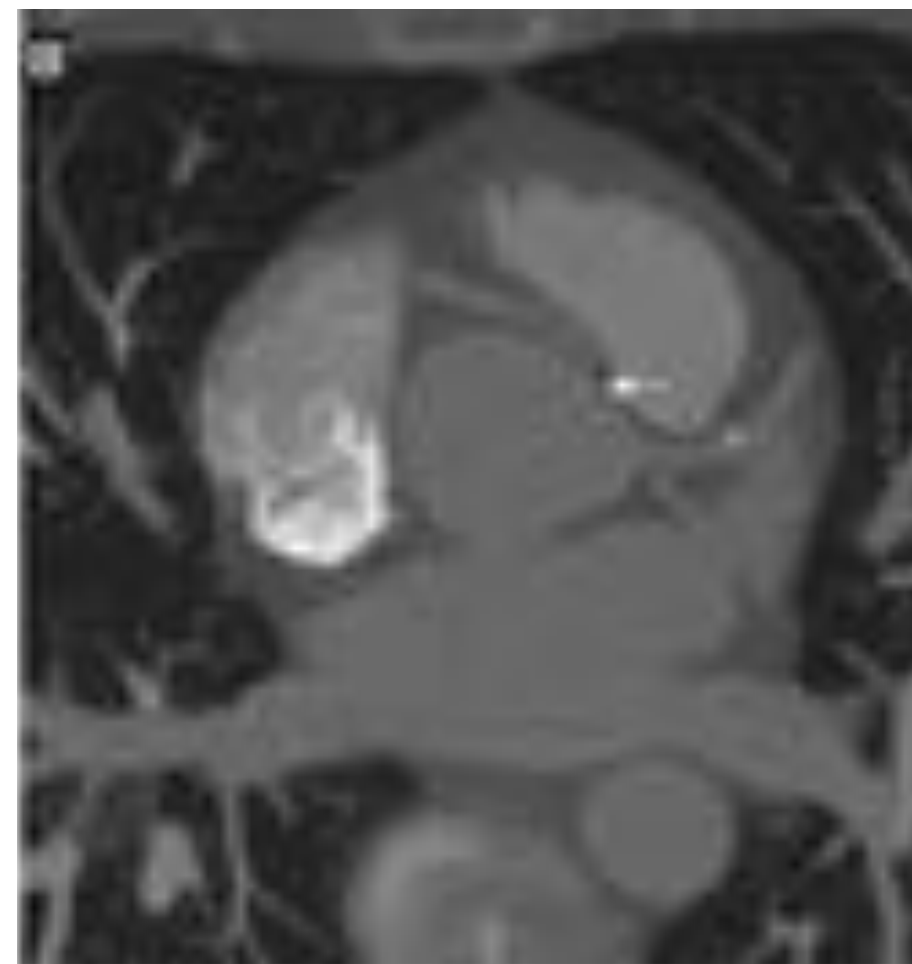
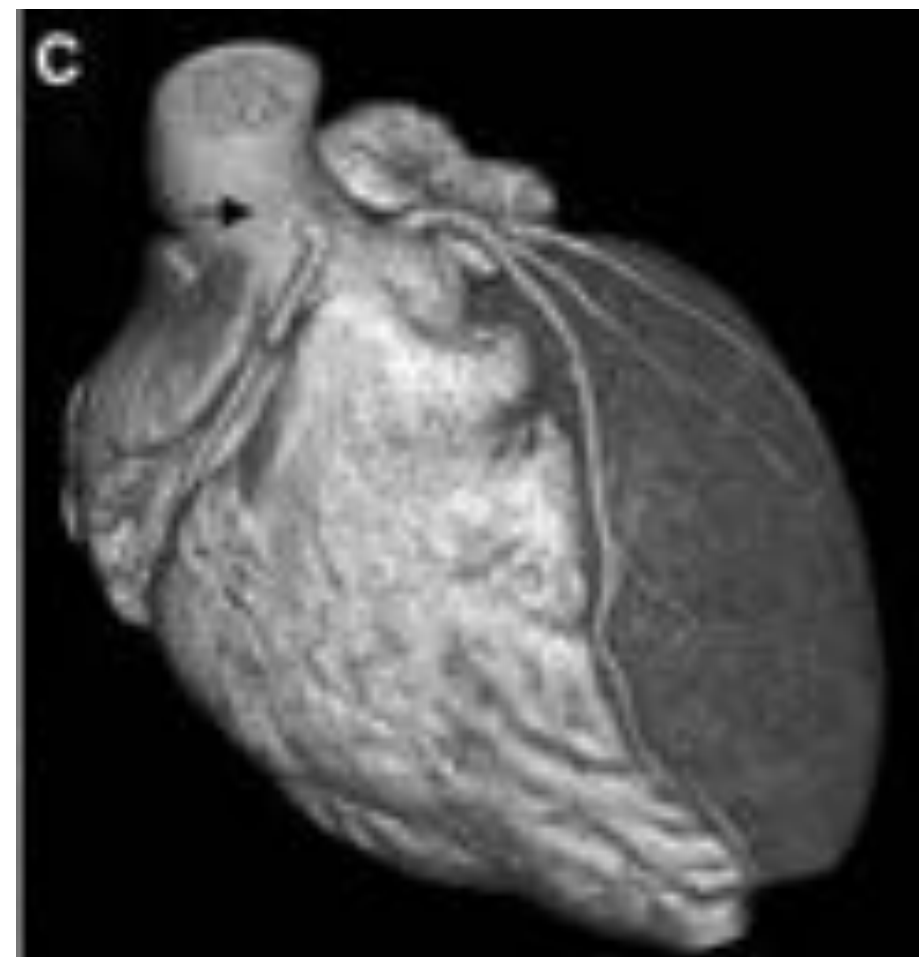
Compression of CA by a stent



Acquired inter arterial course of coronary arteries



Sivakumar,K, et al. *Tex Heart Inst J.* 2010; 37(1): 95-98.



Left Main Coronary Artery Compression During Primary Pulmonary Hypertension

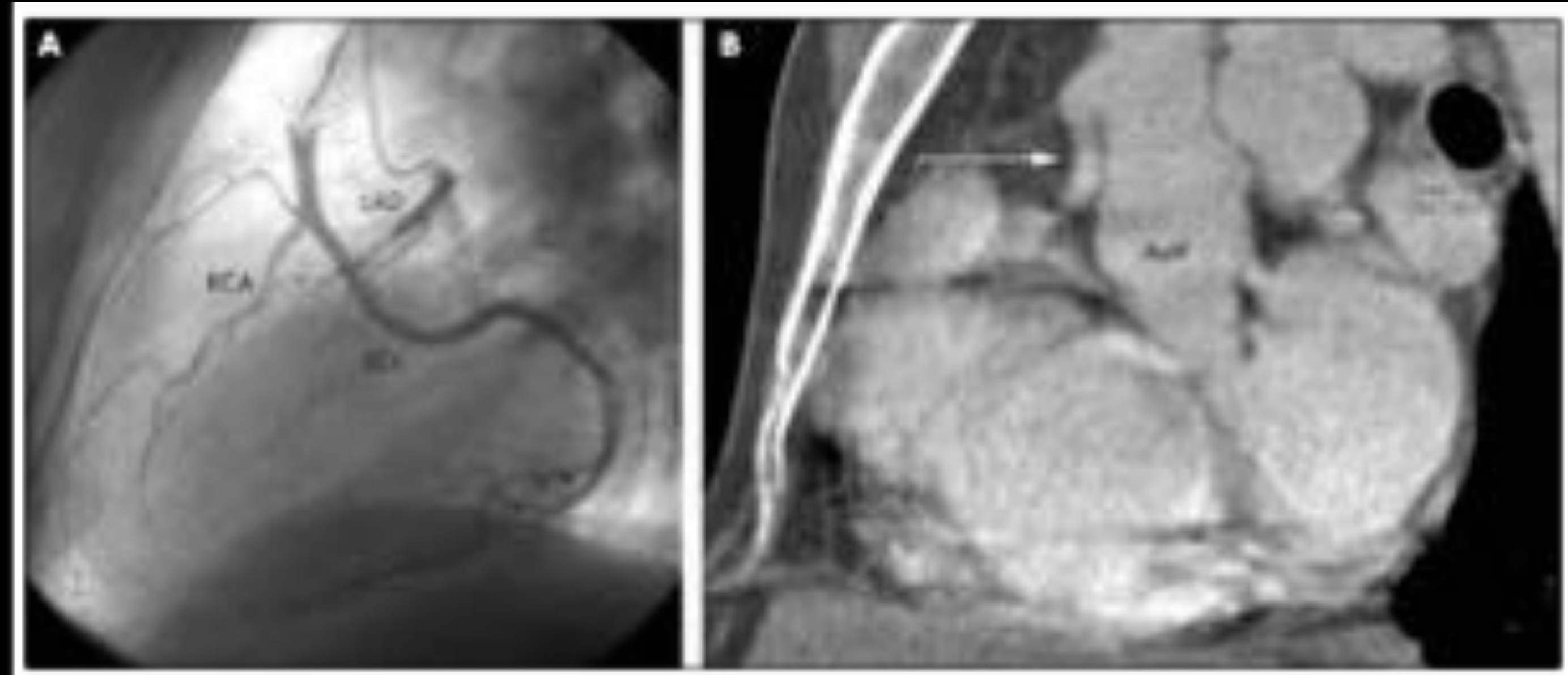
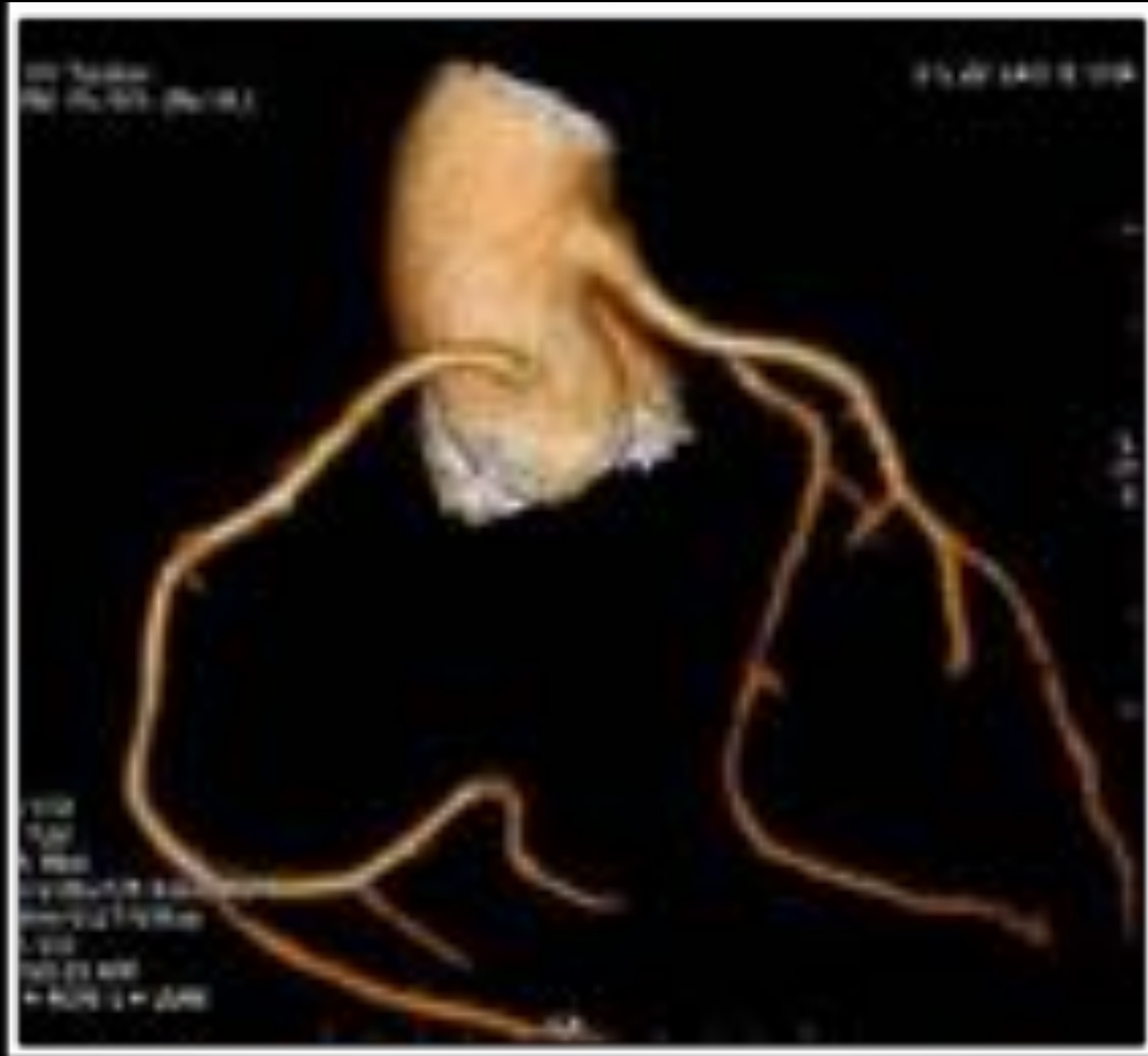Jean-Frédéric Patrat, Guillaume Jondeau, Olivier Dubourg, Pascal Lacombe, Michel Rigaud, Jean-Pierre Bourdarias and Iradj Gandjbakhch

Chest 1997;112;842-843

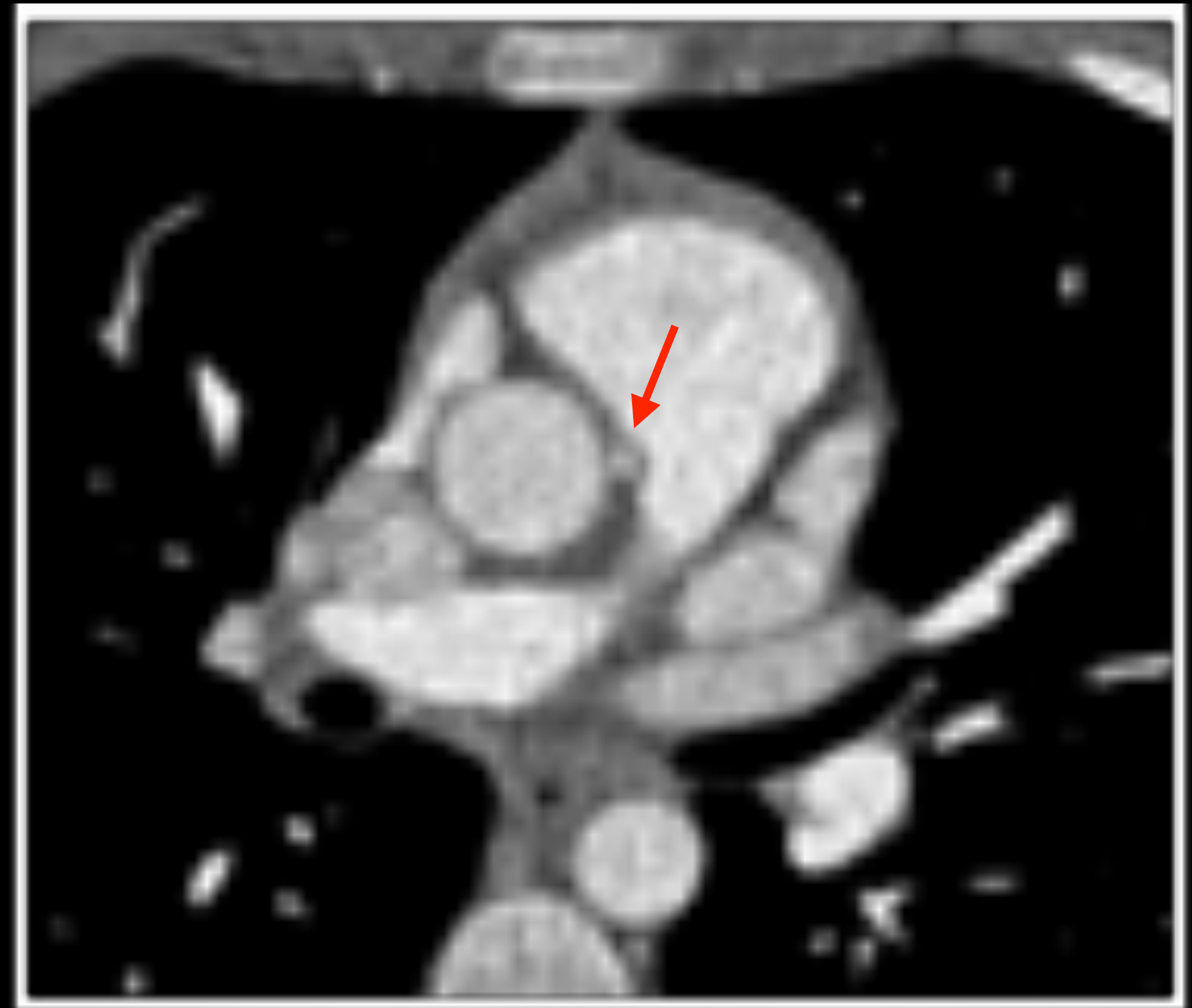
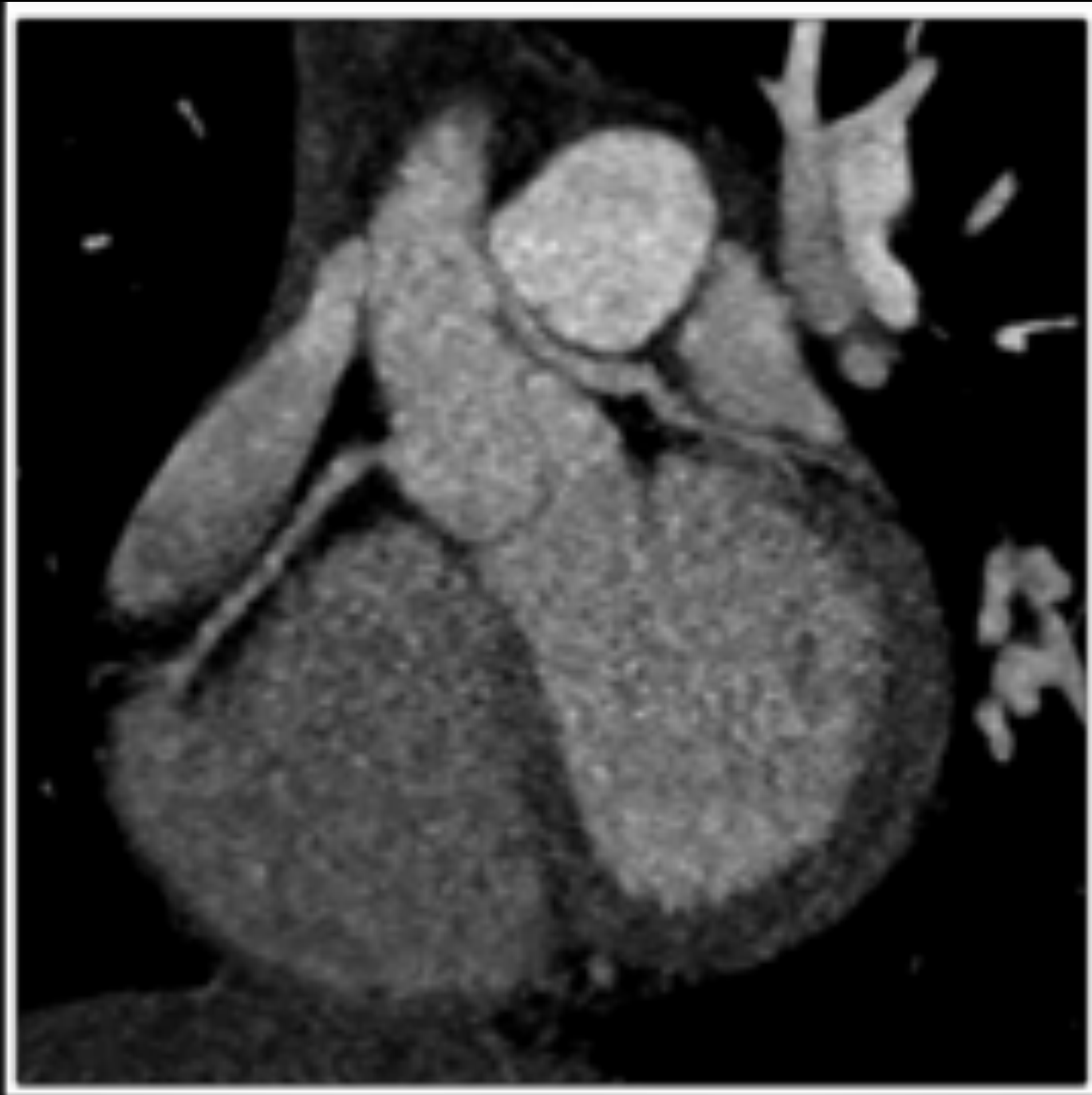Abnormal origin of coronary arteries

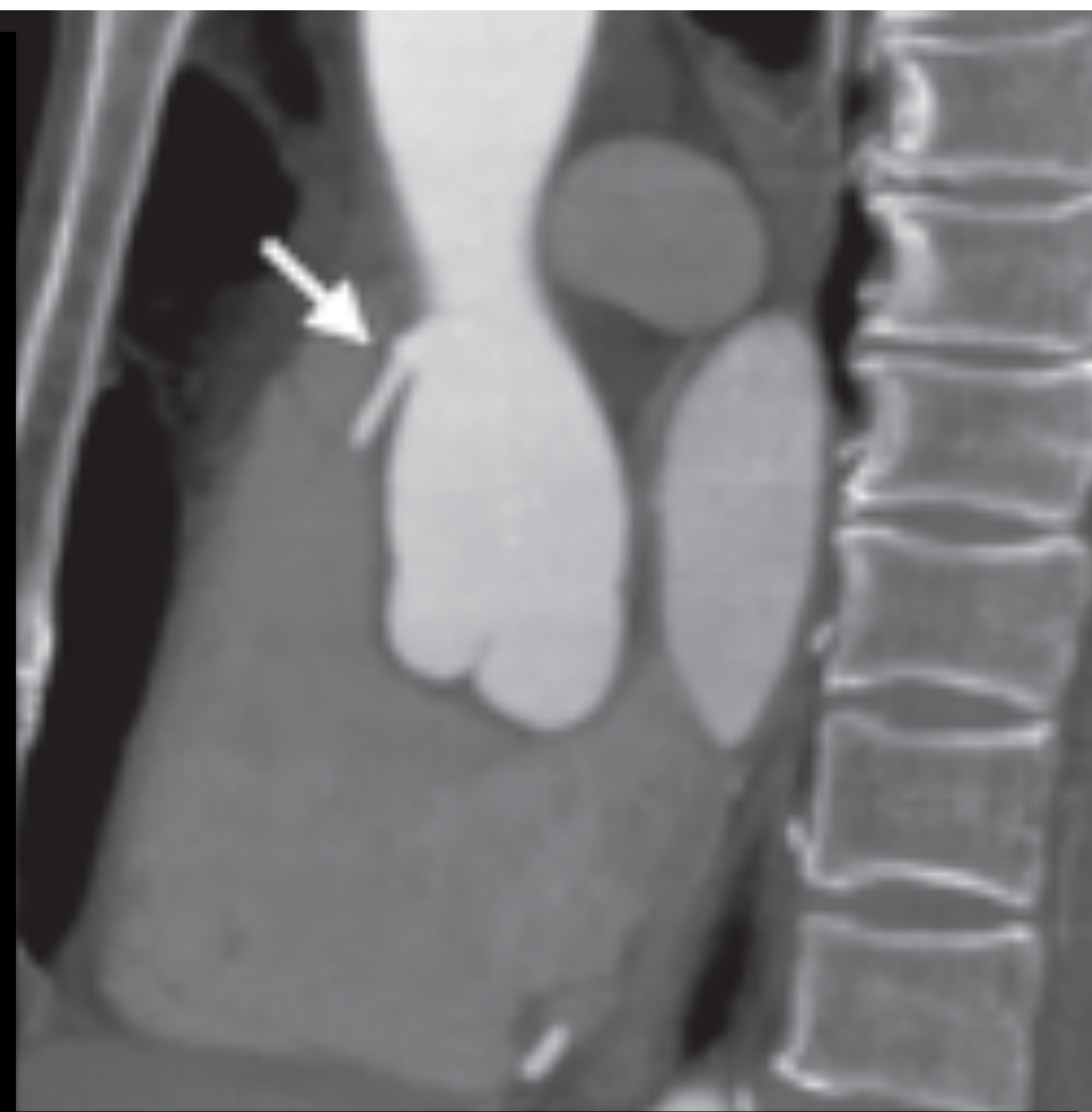
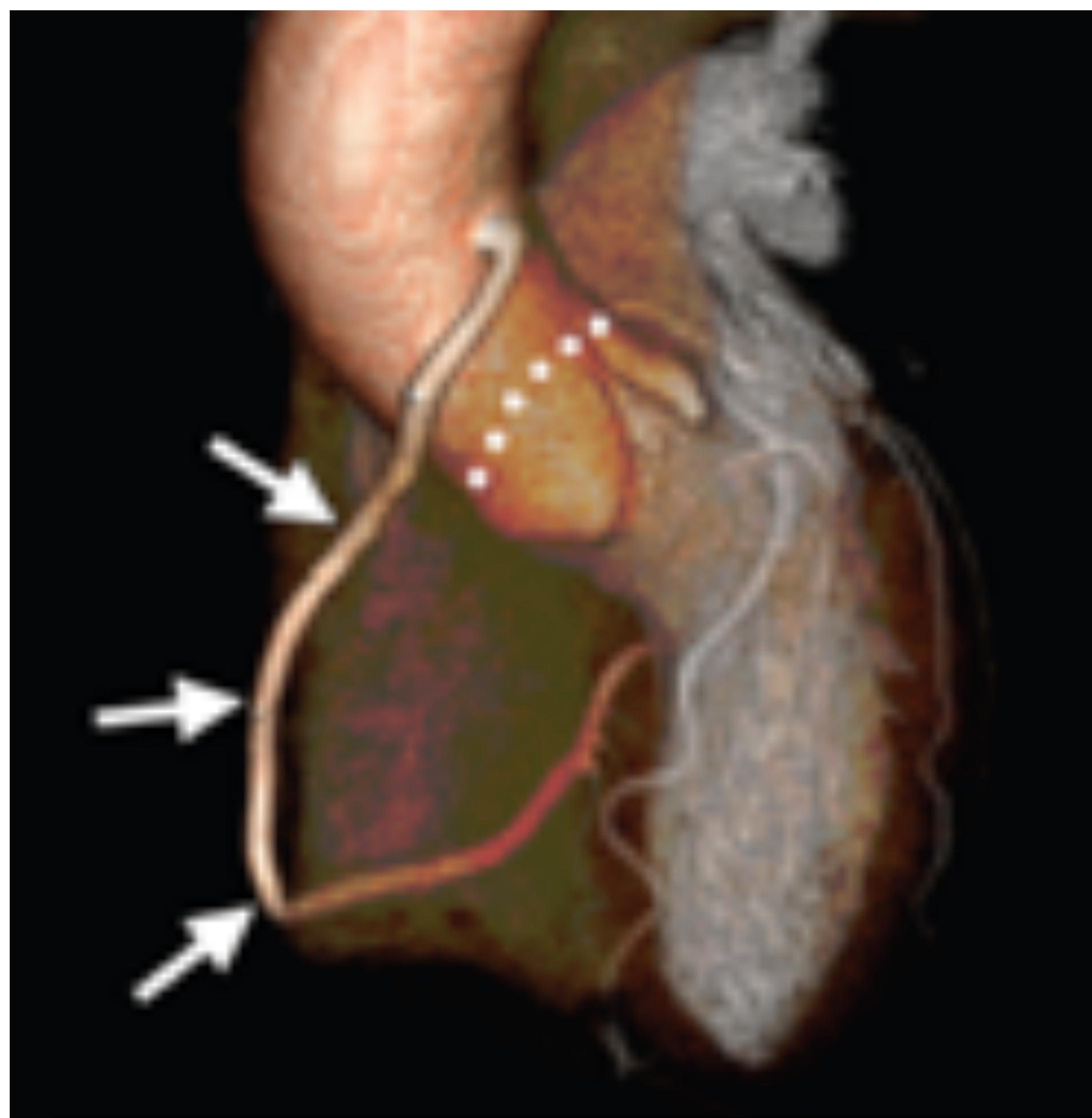
Abnormal origin from the aorta

High take off left coronary artery

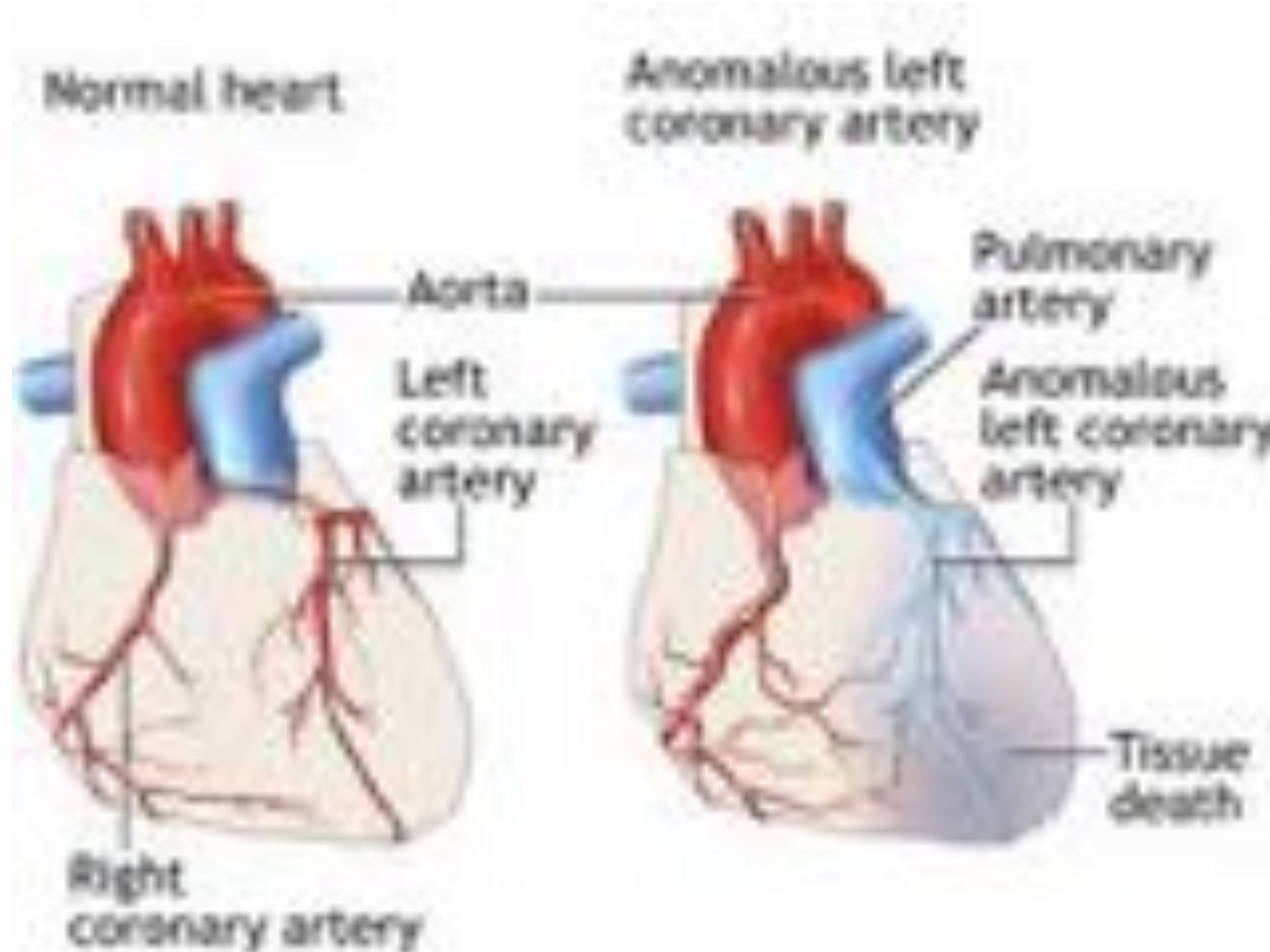


Abnormal origin from the aorta
High take off left coronary artery

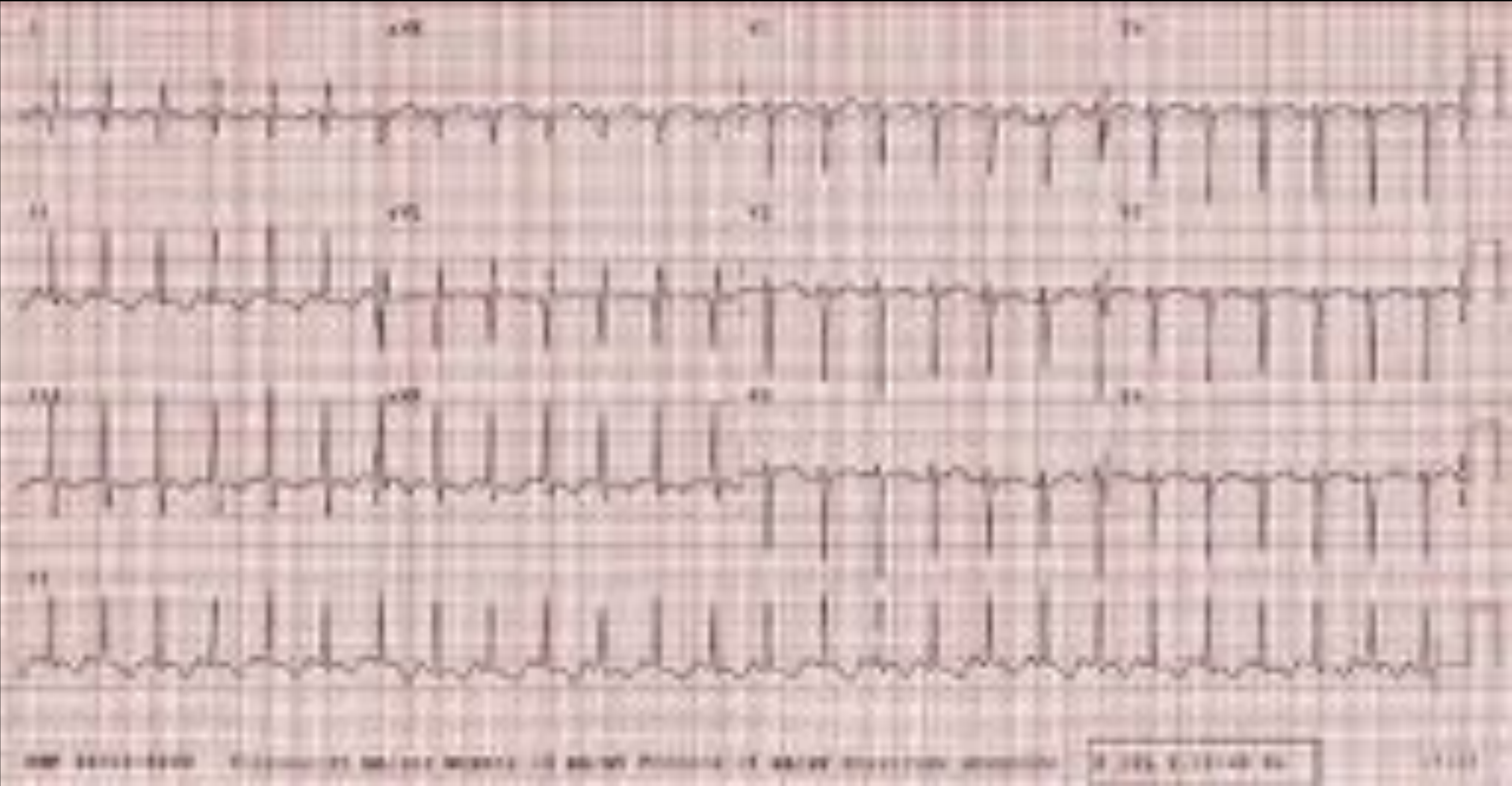




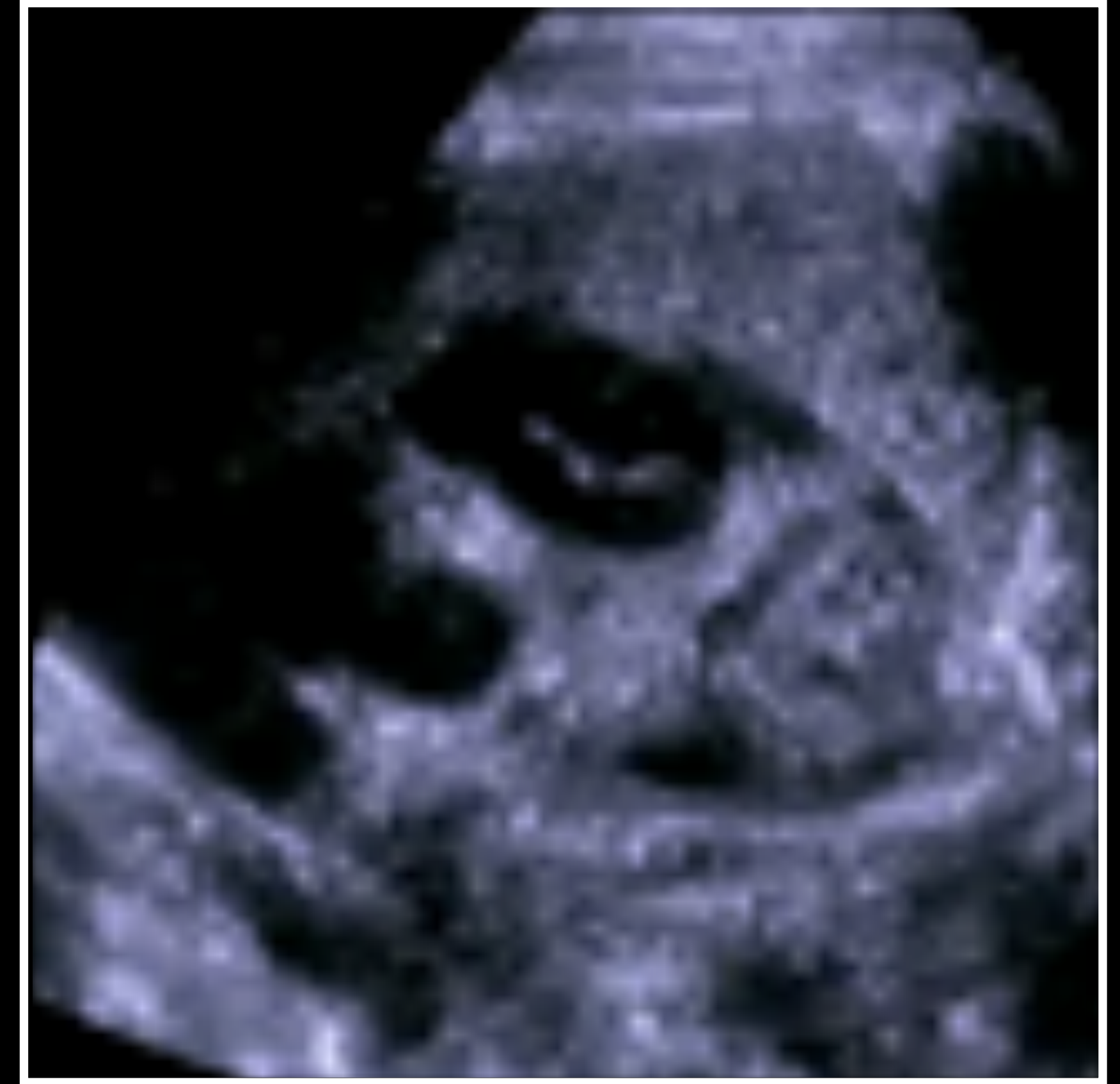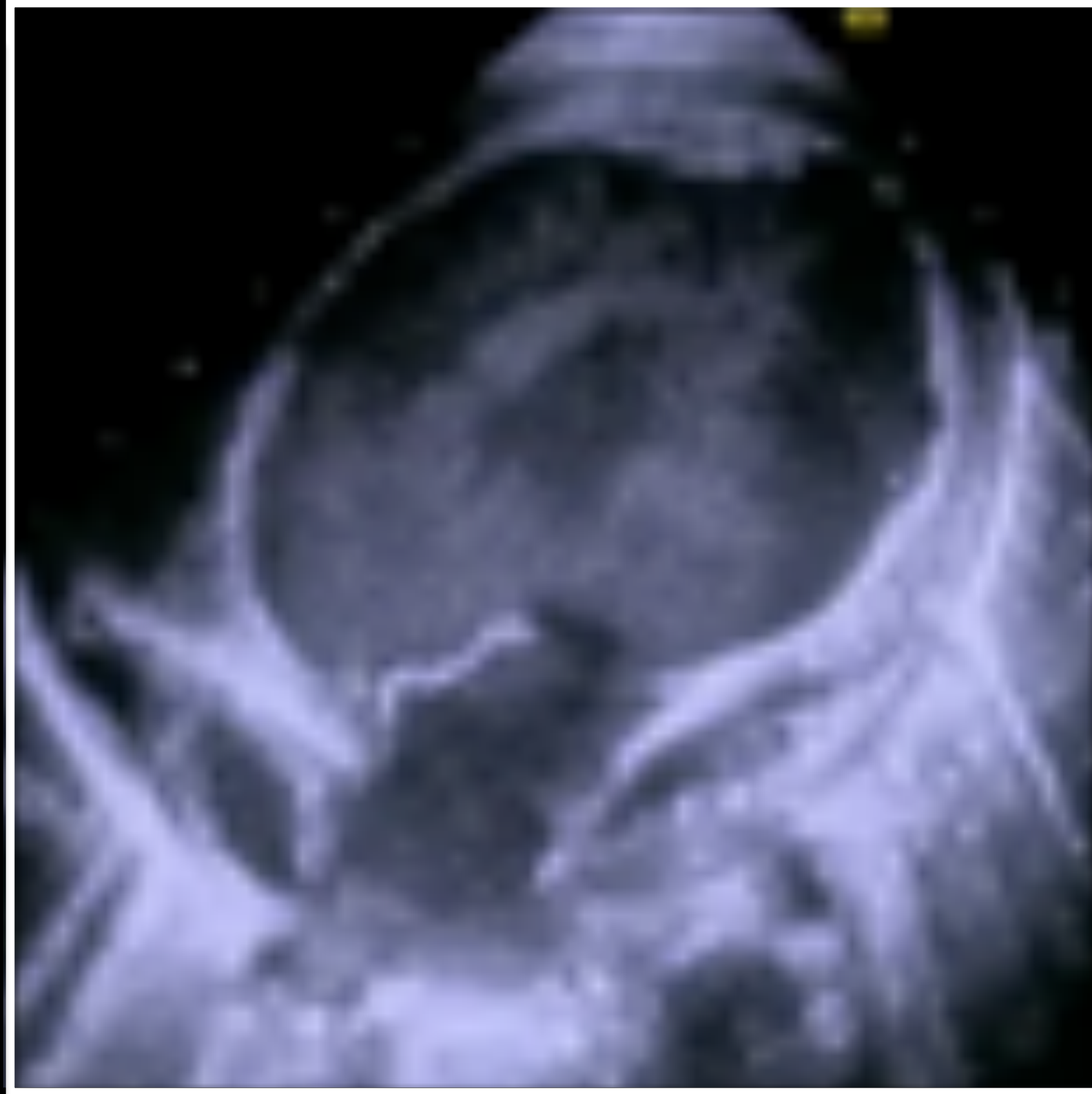
Abnormal origin from the pulmonary artery : ALCAPA



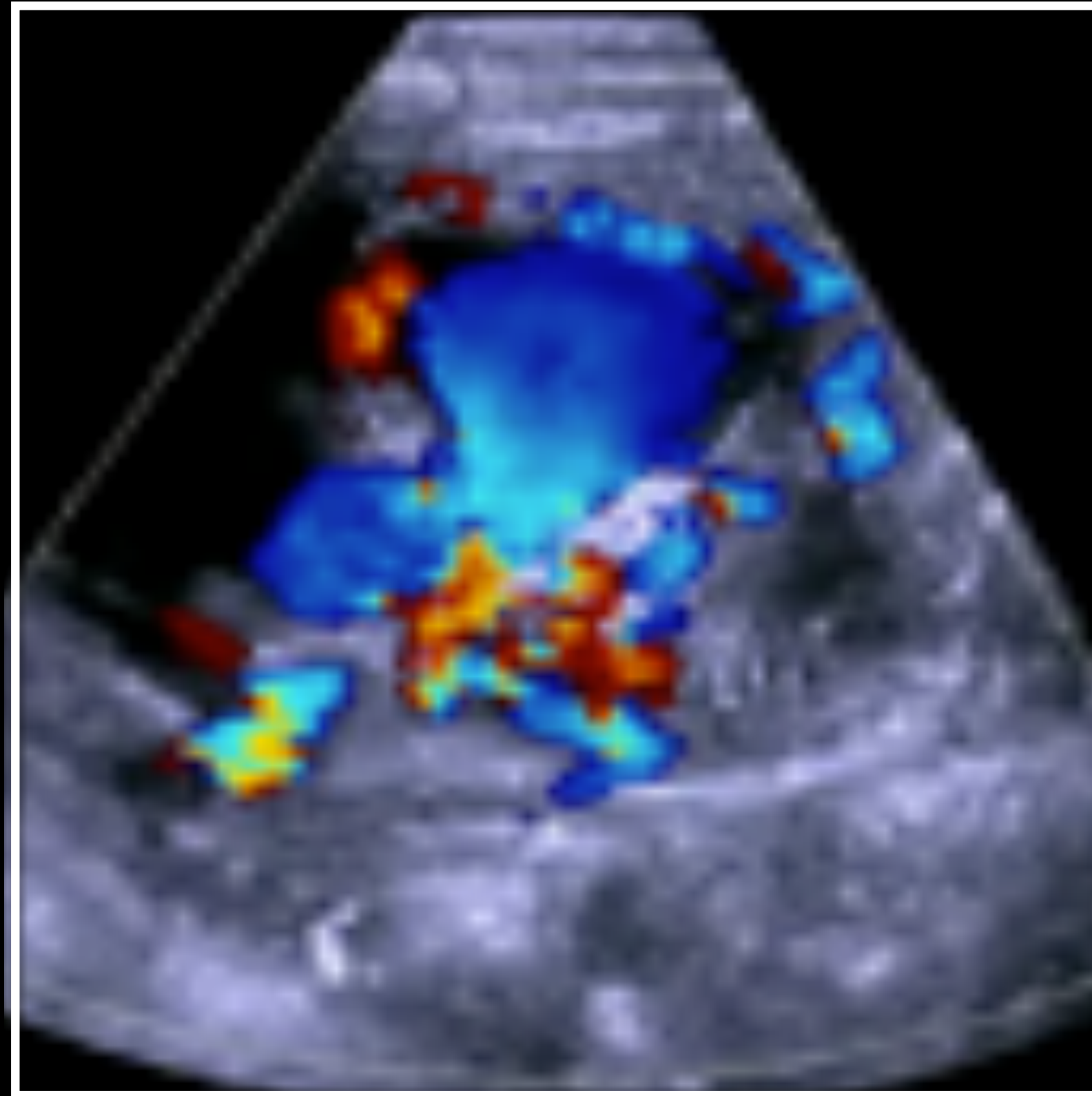
Abnormal origin from the pulmonary artery : ALCAPA



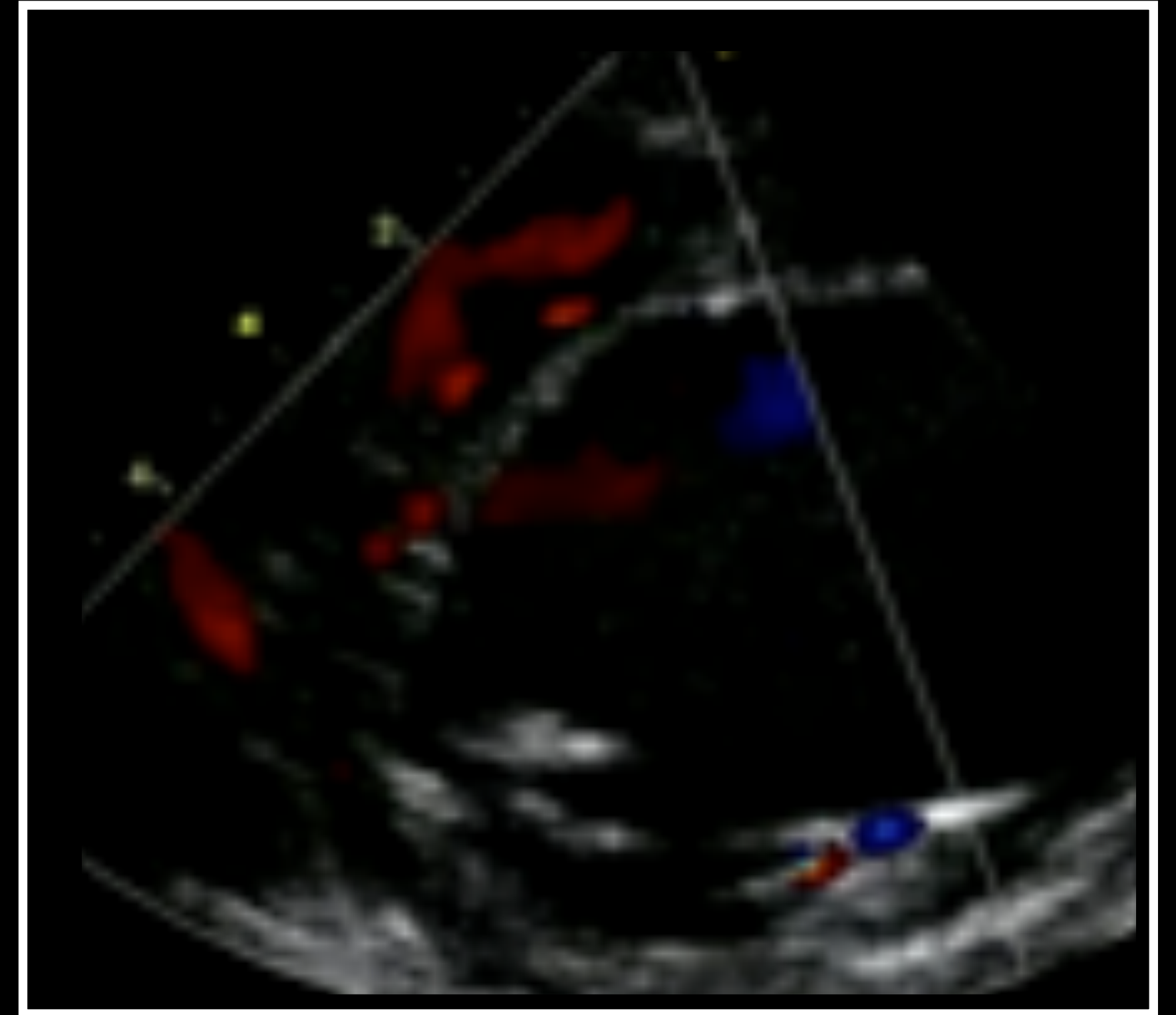
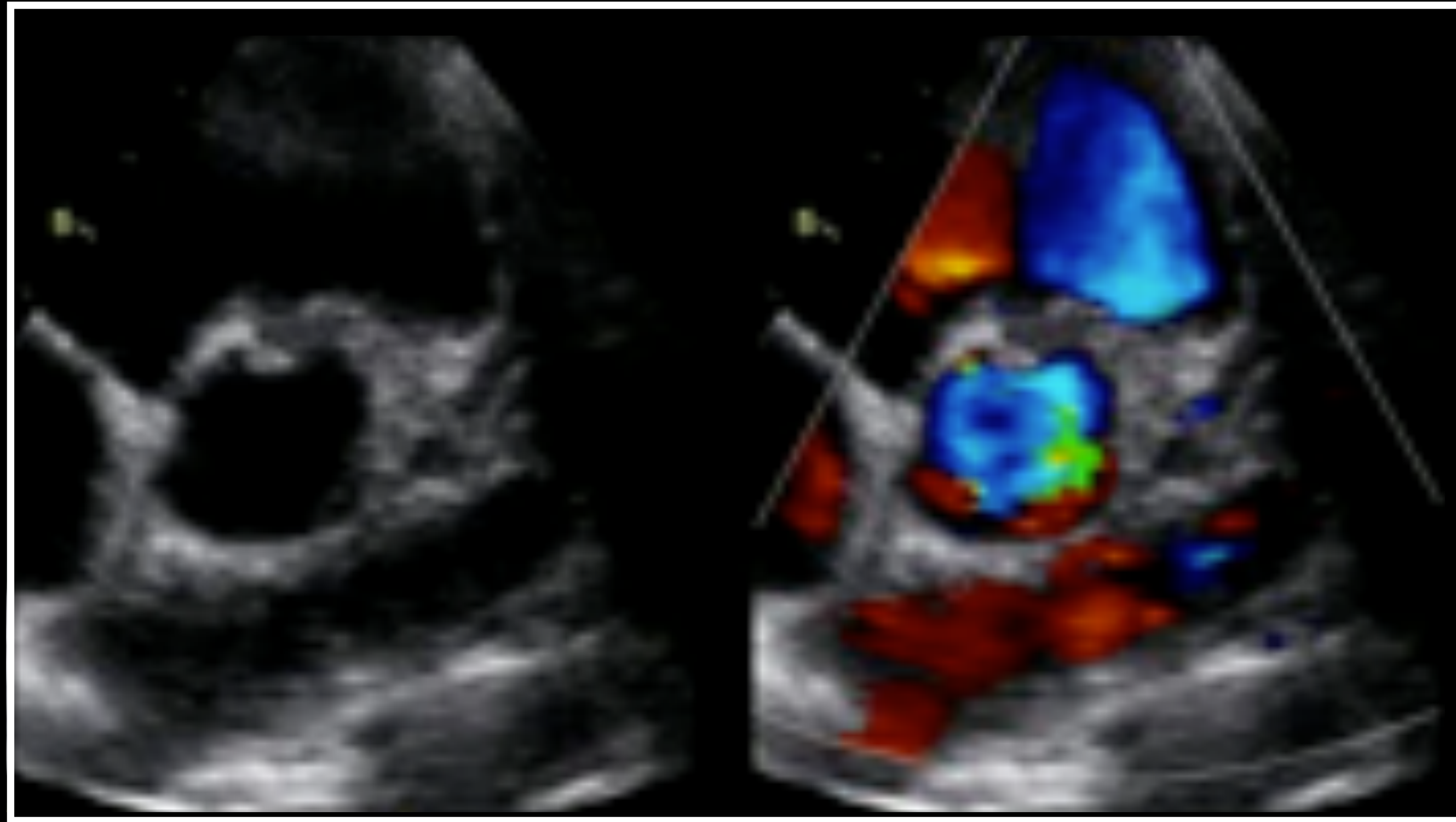
Abnormal origin from the pulmonary artery : ALCAPA



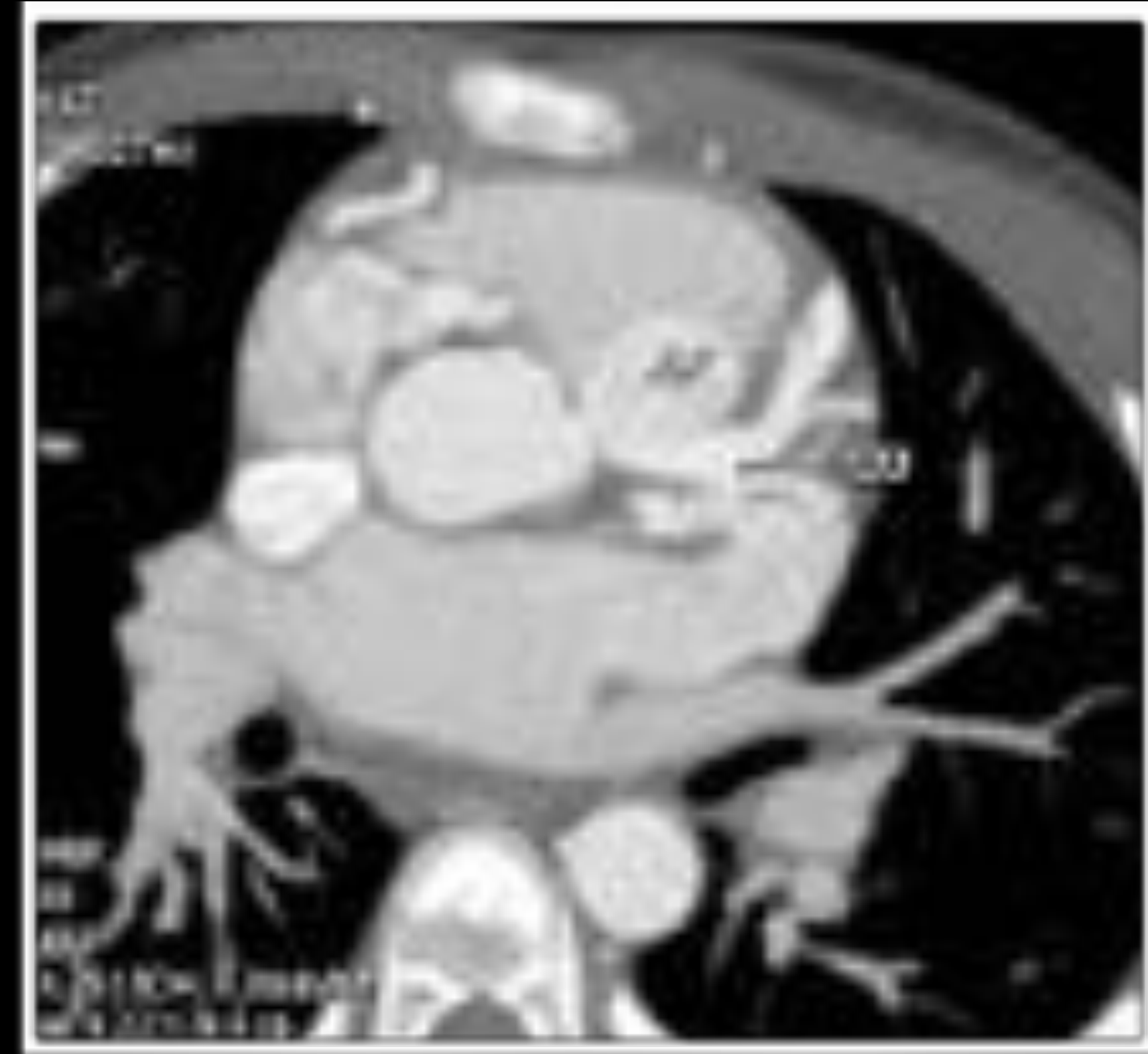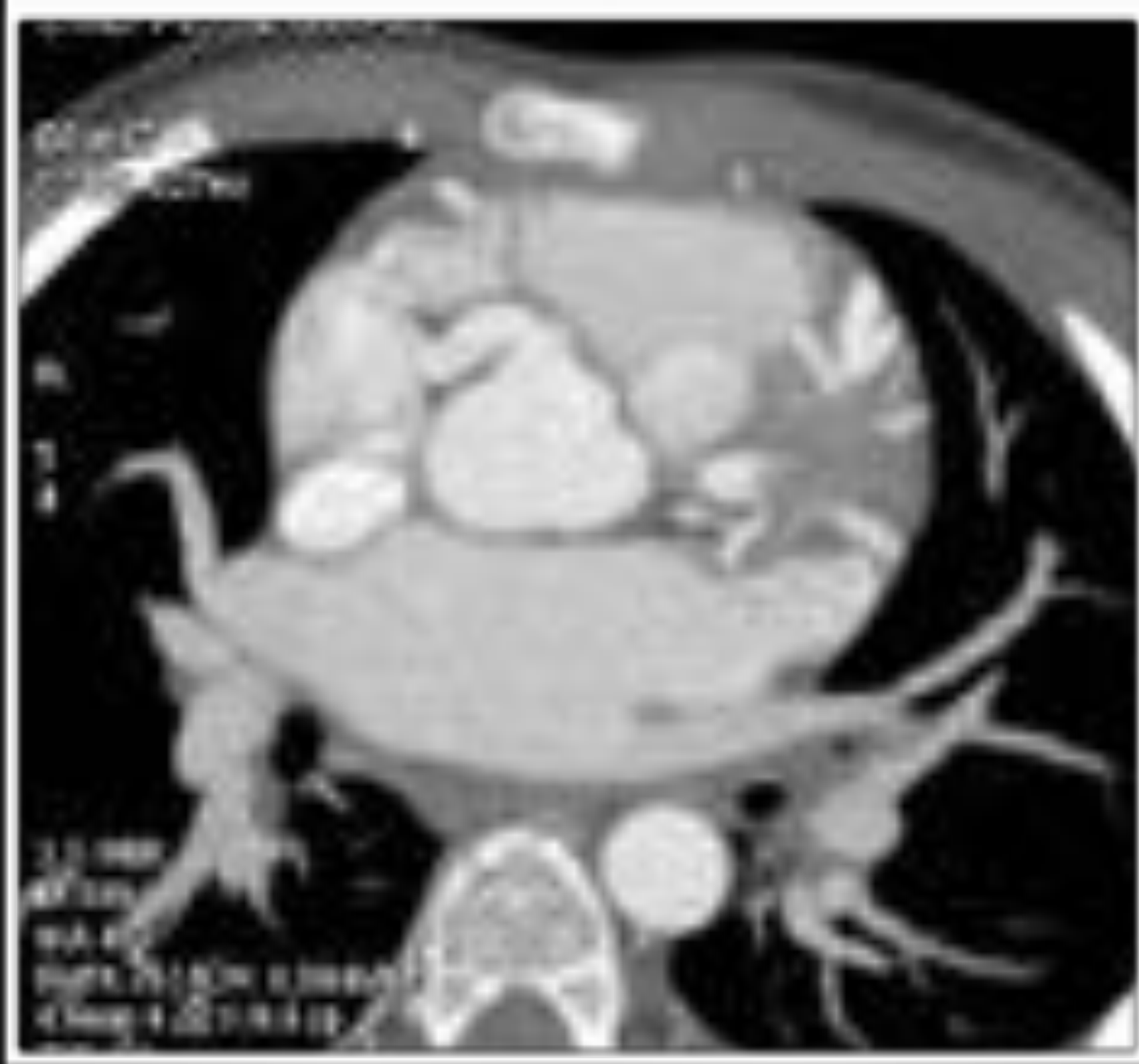Abnormal origin from the pulmonary artery : ALCAPA



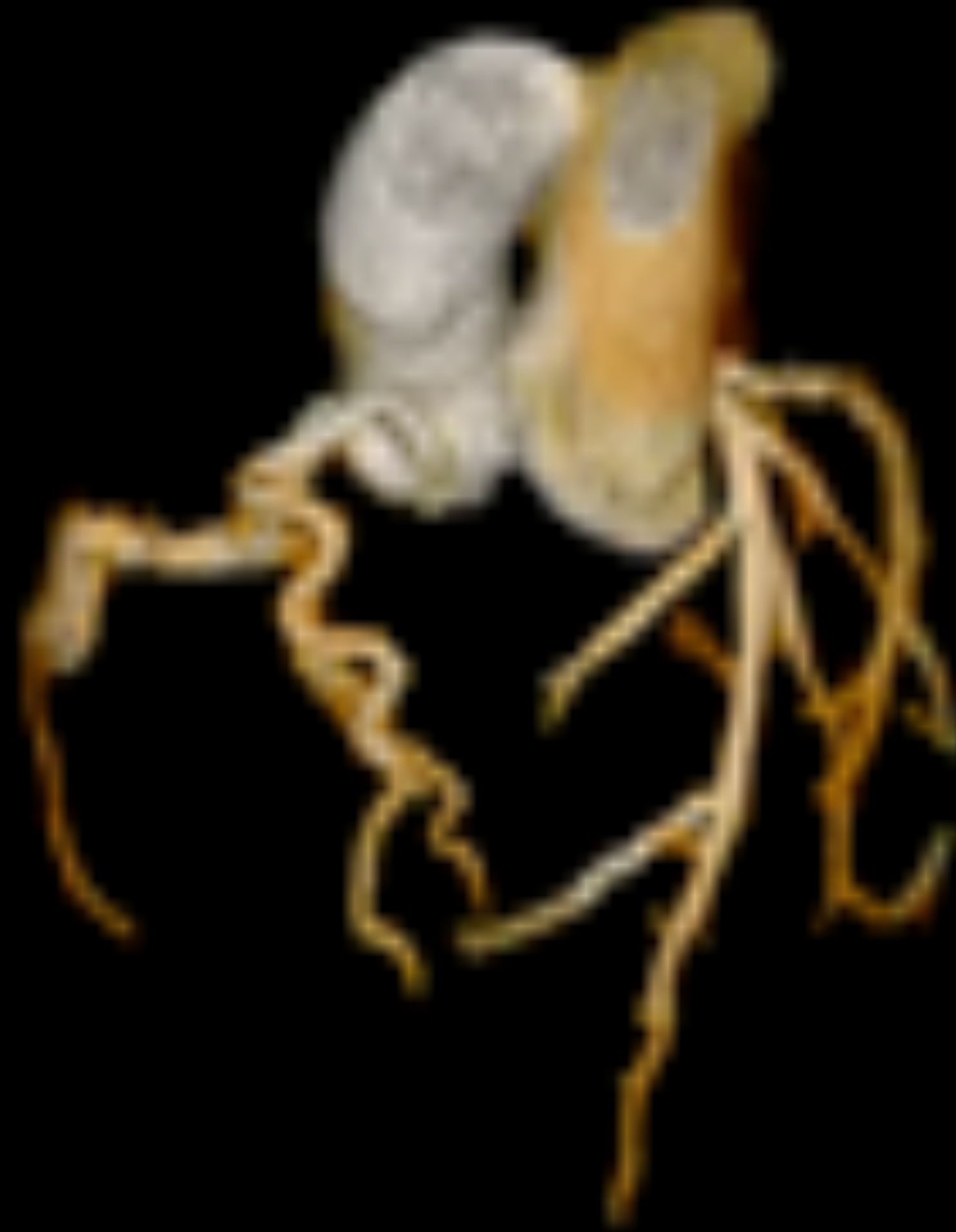Abnormal origin from the pulmonary artery : ALCAPA



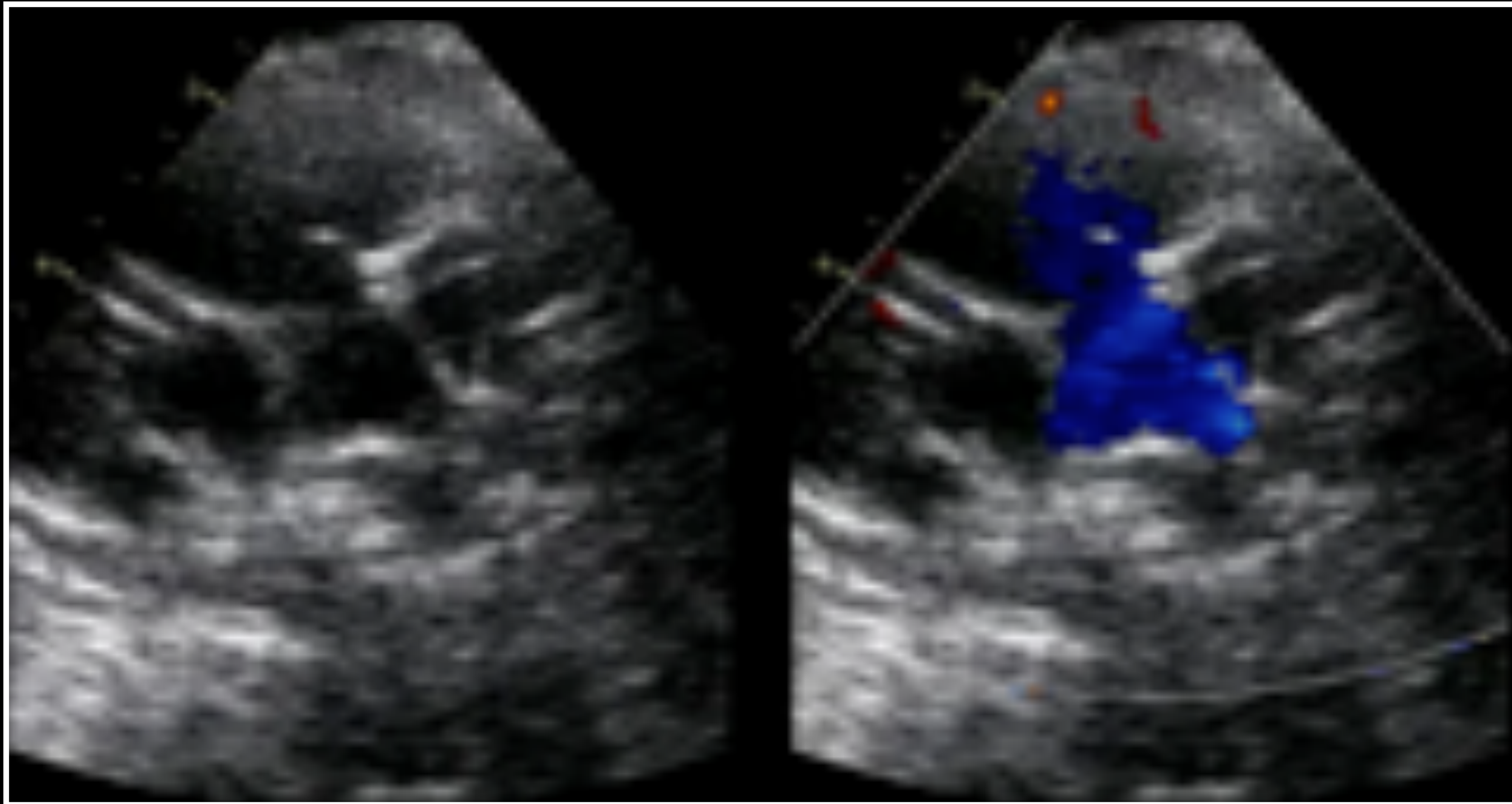
Abnormal origin from the pulmonary artery : ALCAPA



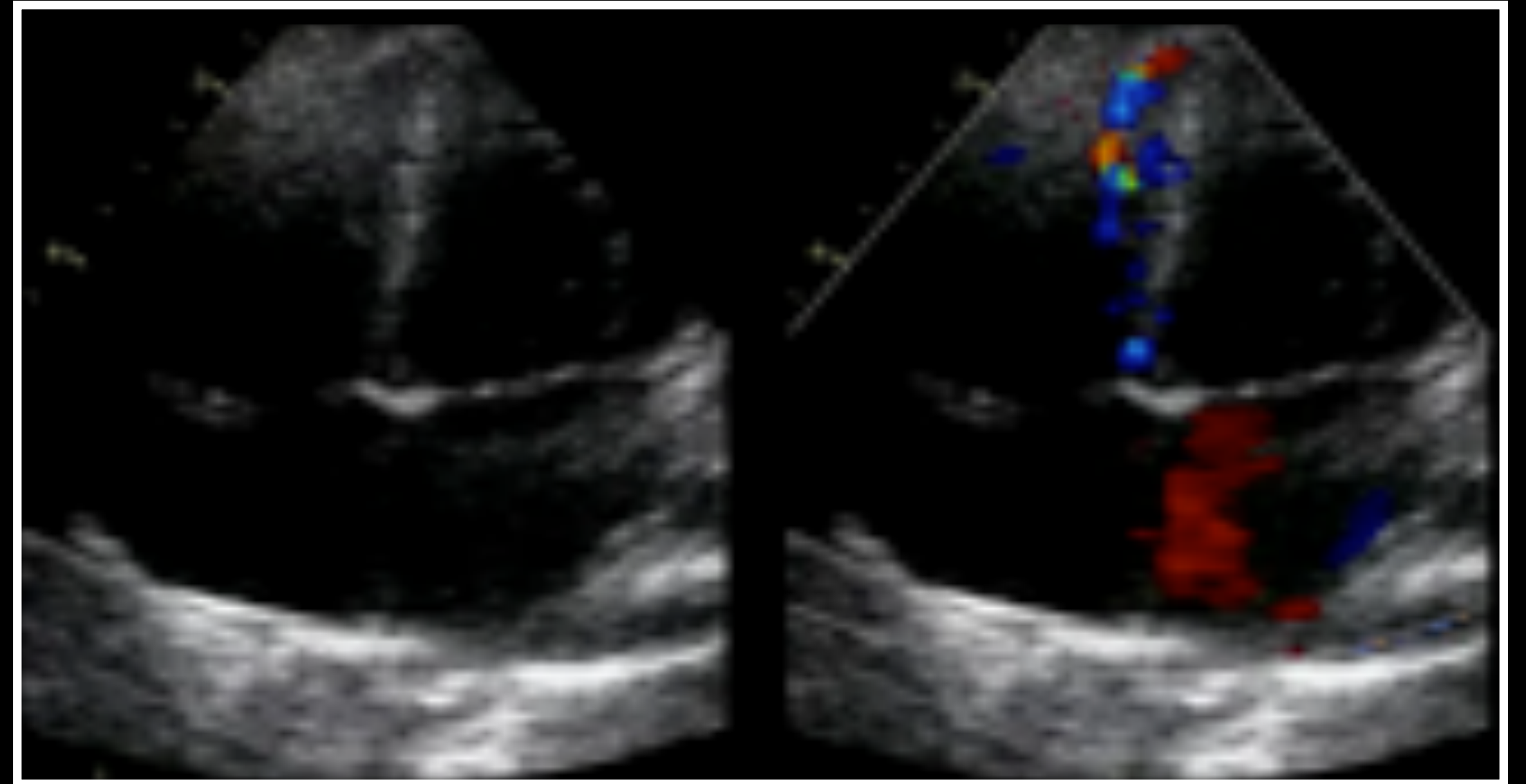
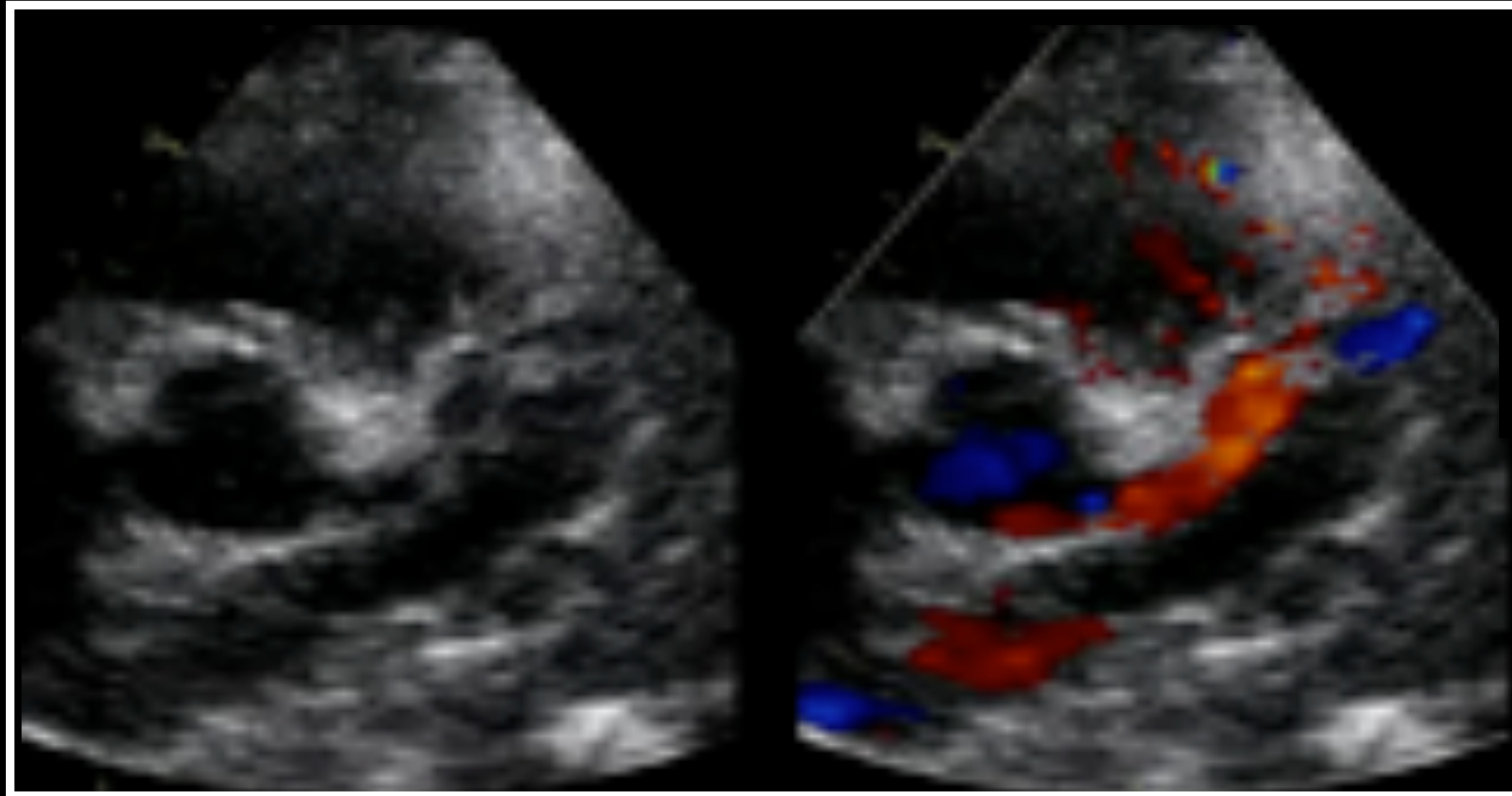
Abnormal origin from the pulmonary artery : ALCAPA



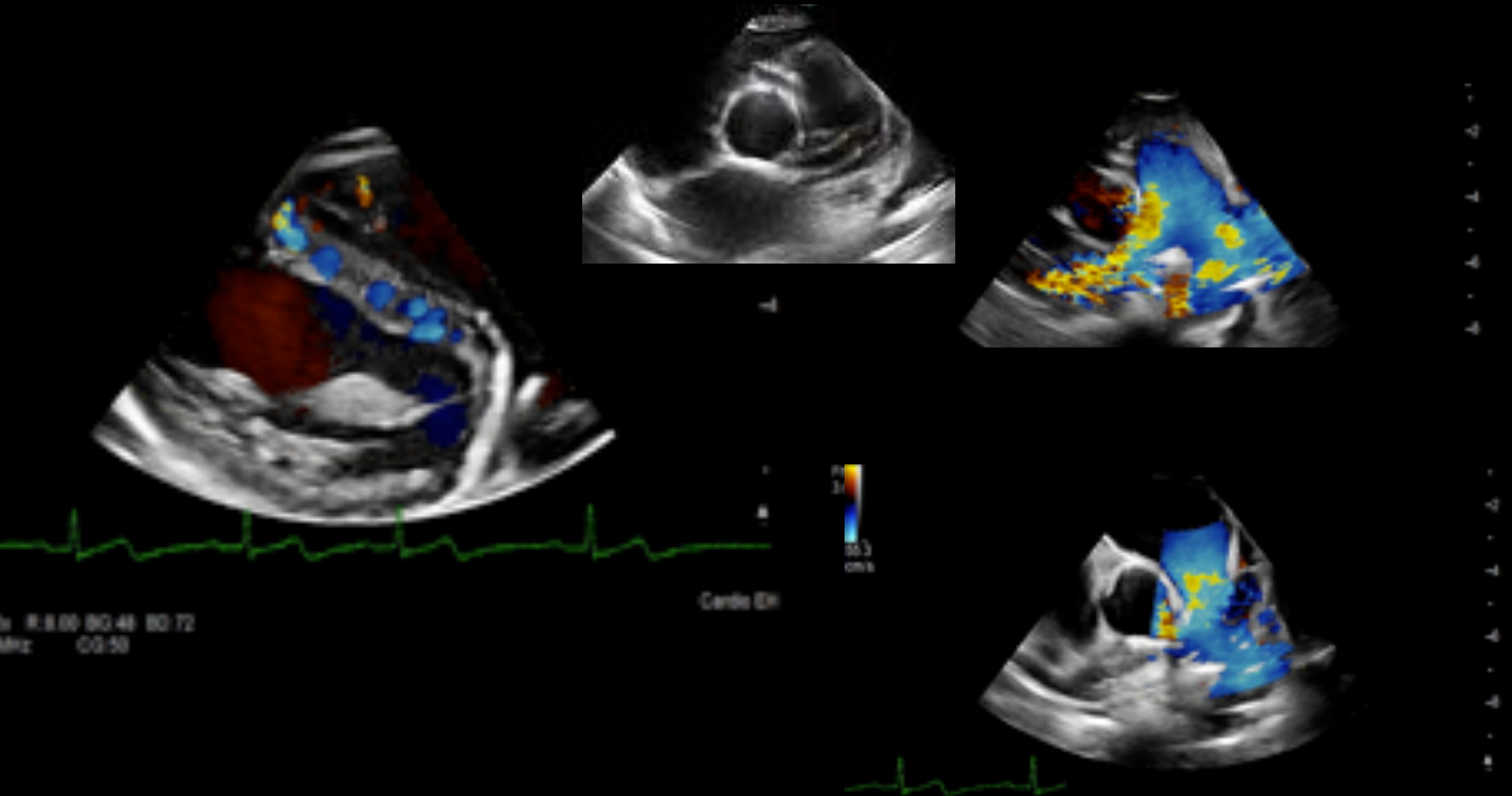
Abnormal origin from the pulmonary artery : ARCAPA



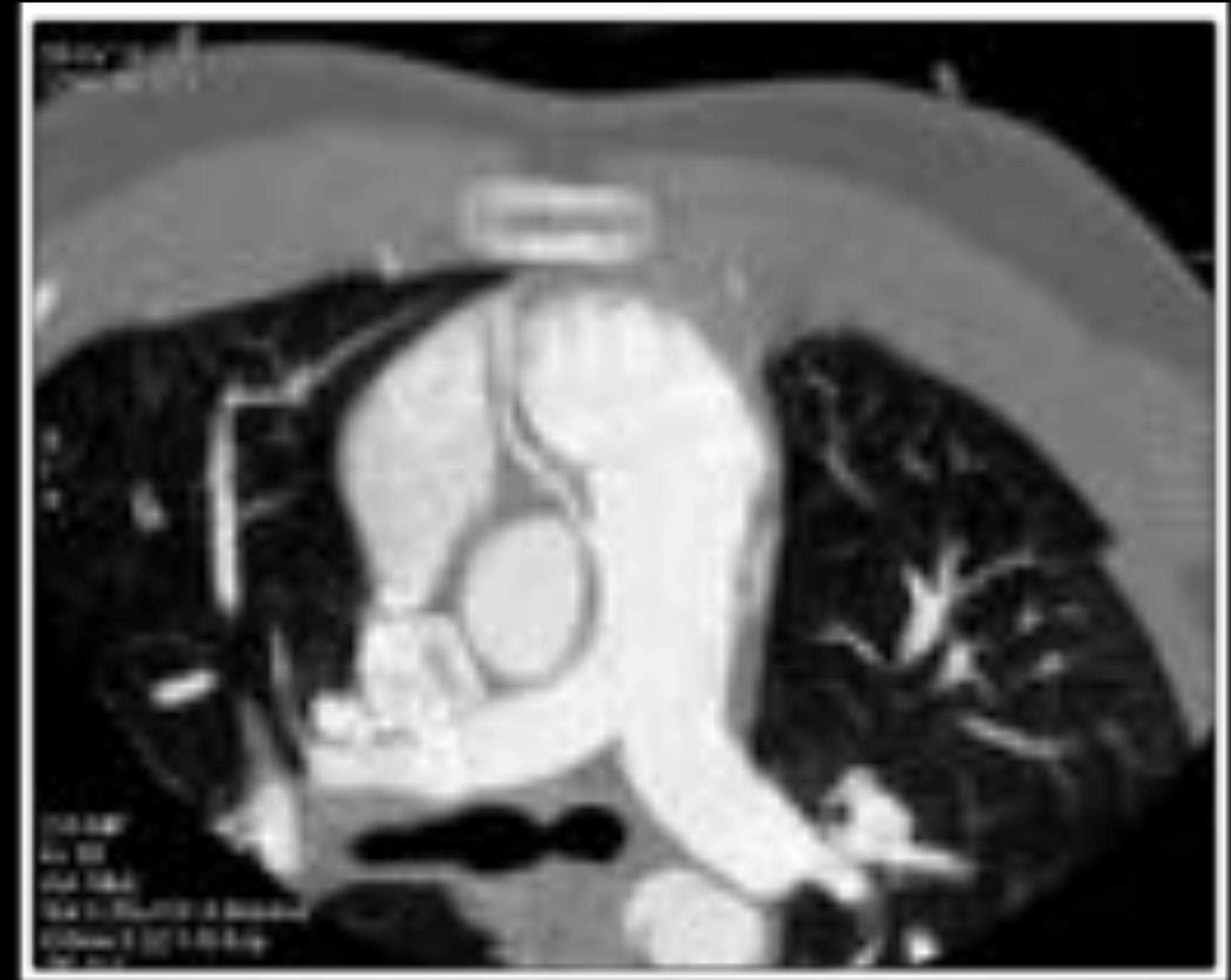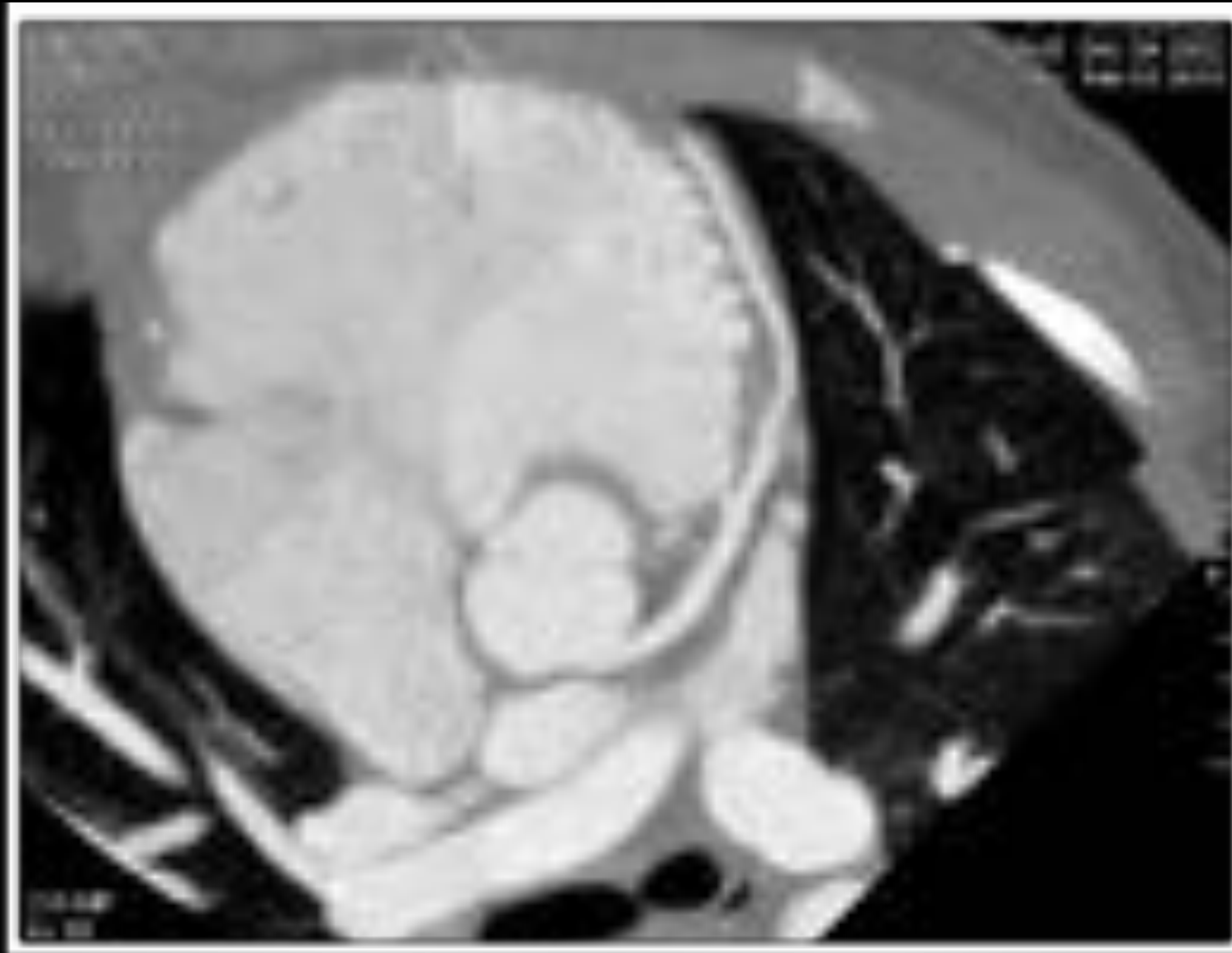
Abnormal origin from the pulmonary artery : ARCAPA



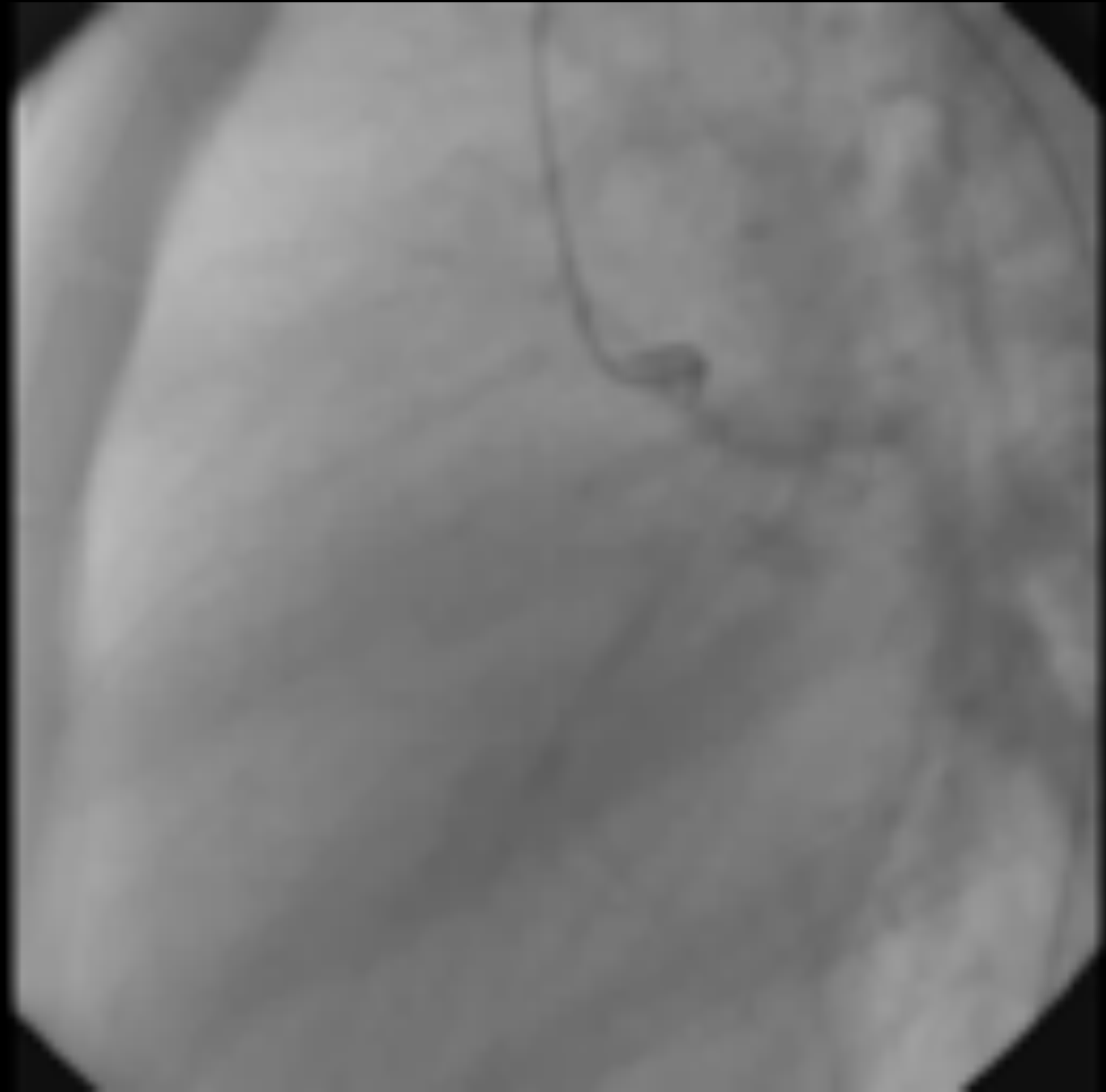
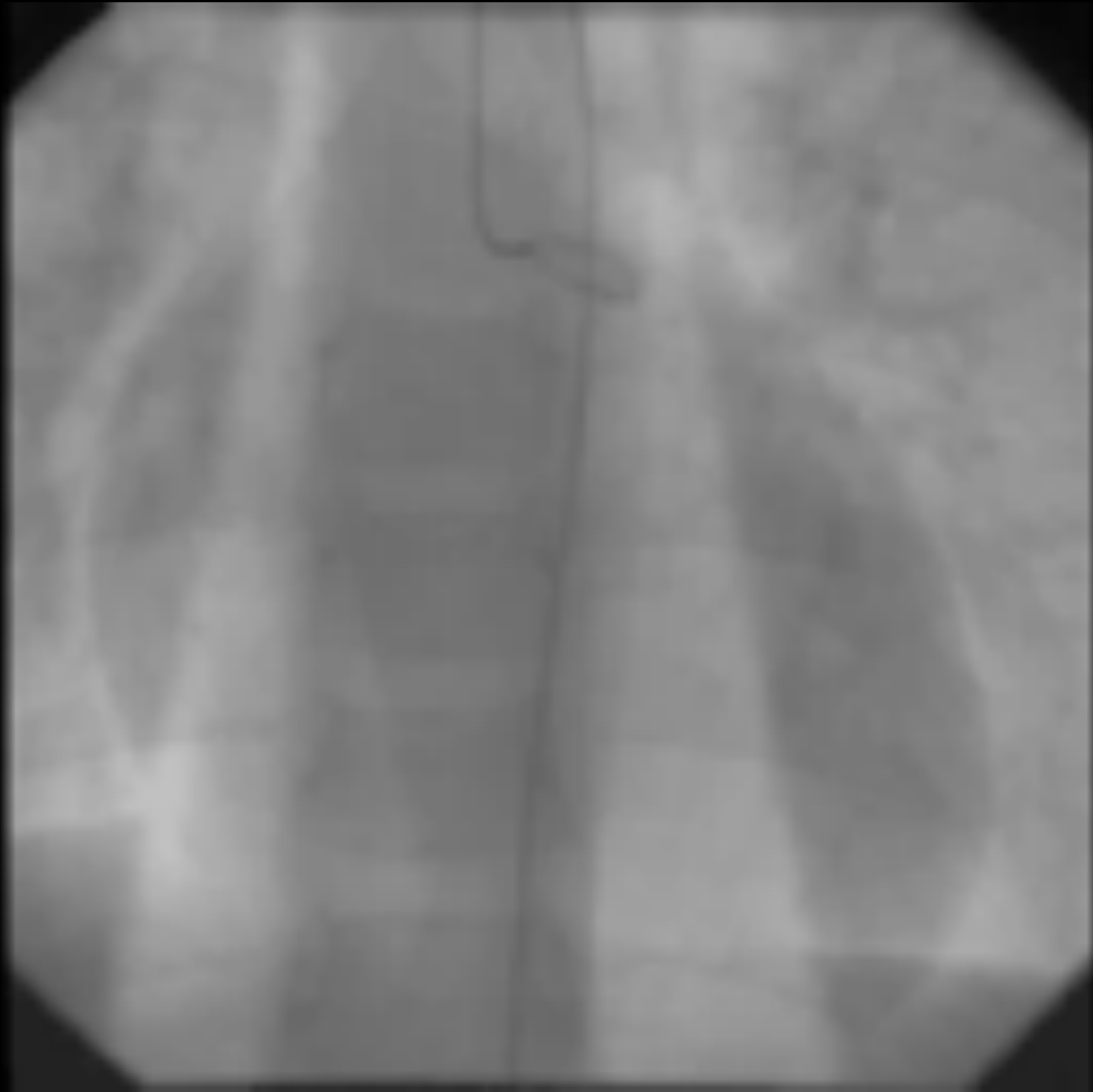Abnormal origin from the pulmonary artery : ARCAPA



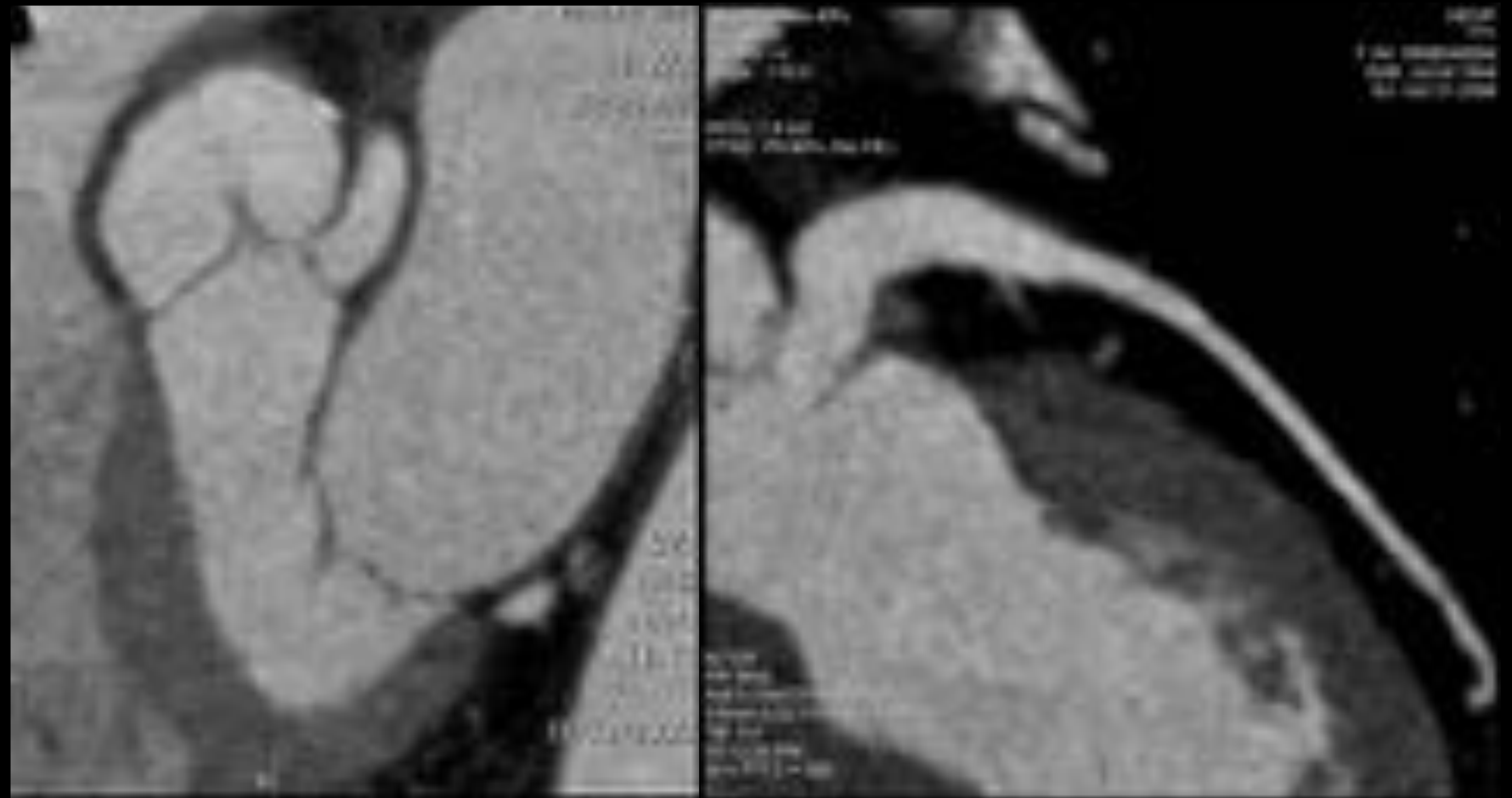
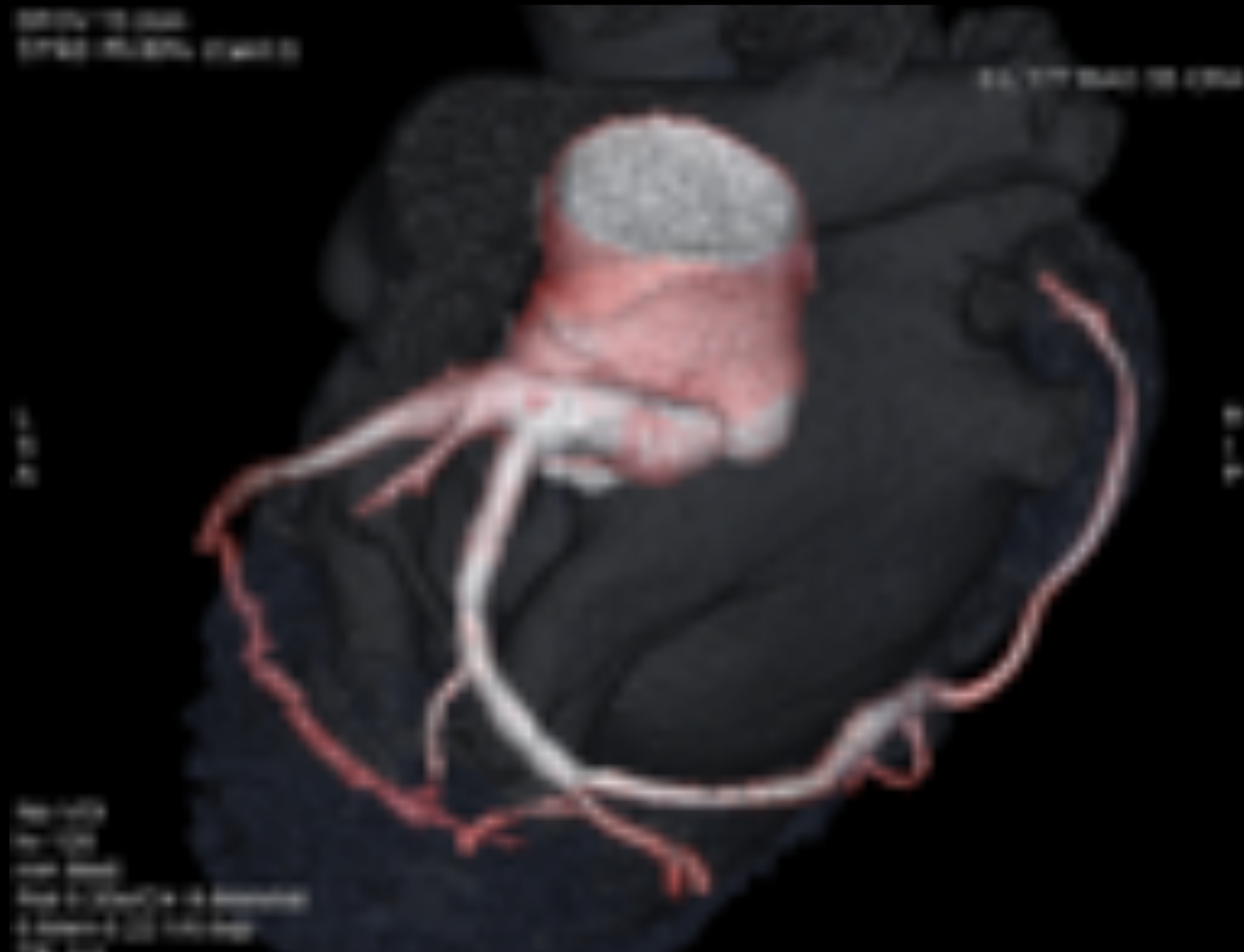Abnormal origin from the pulmonary artery : ARCAPA



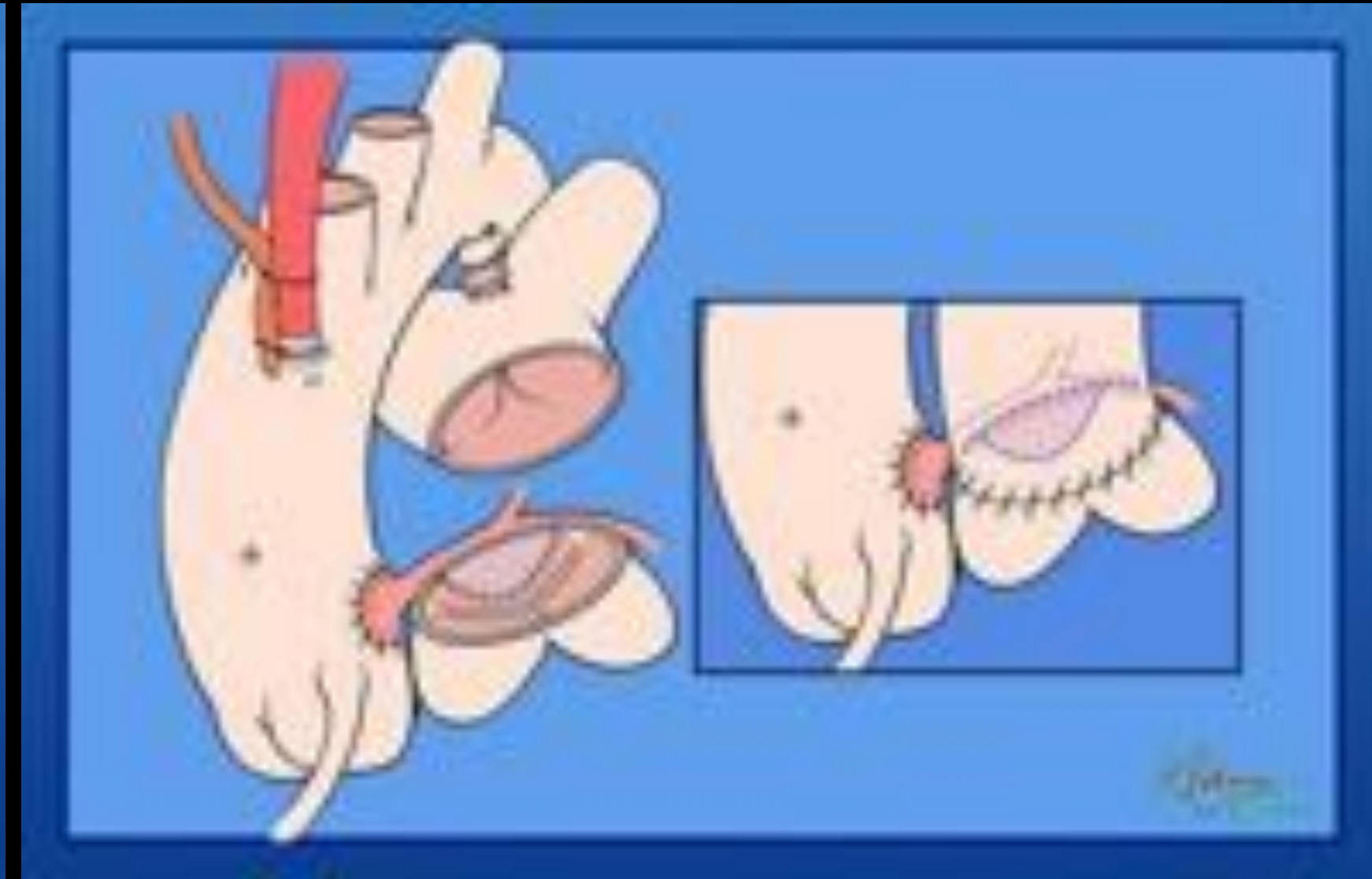
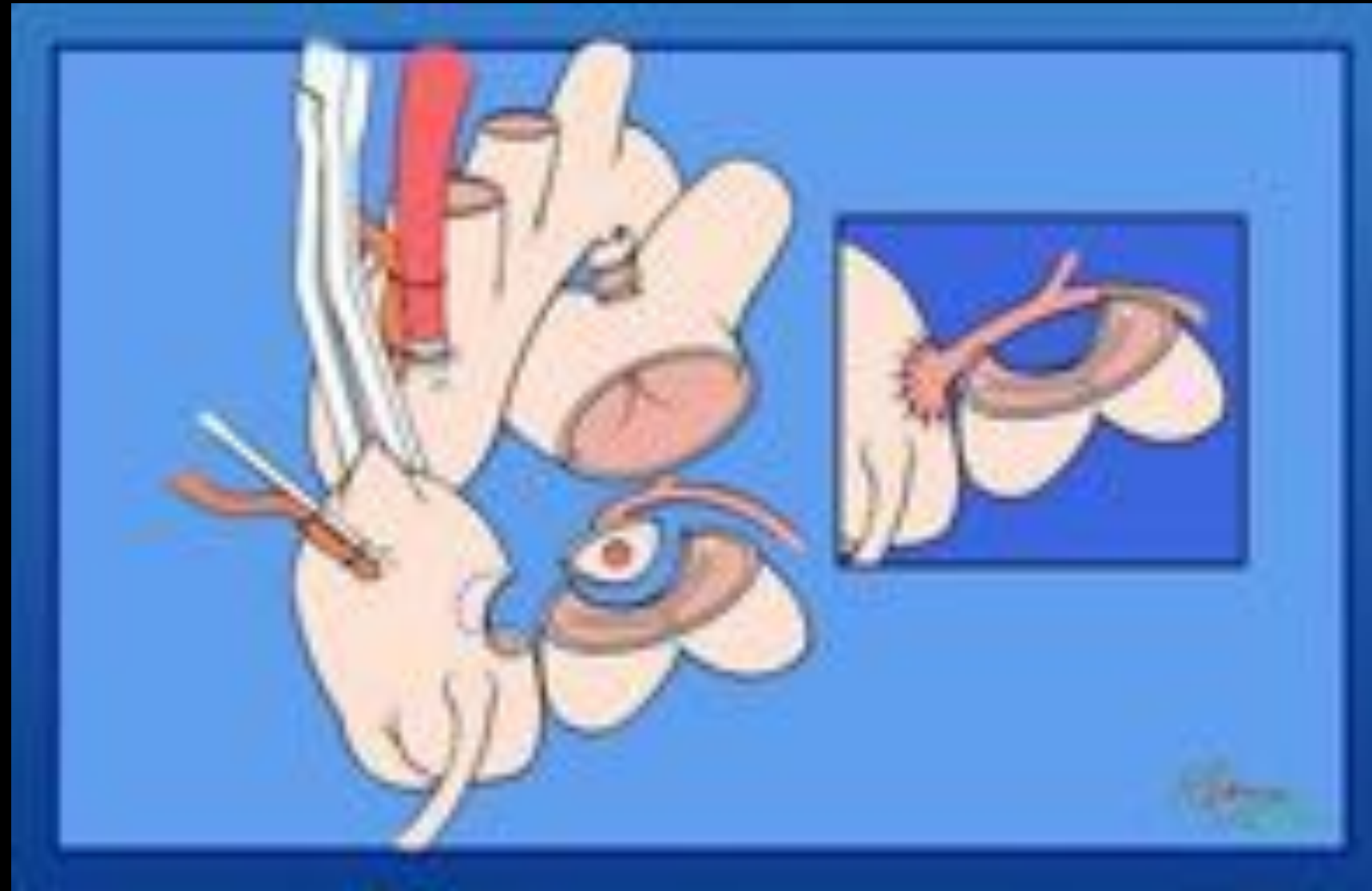
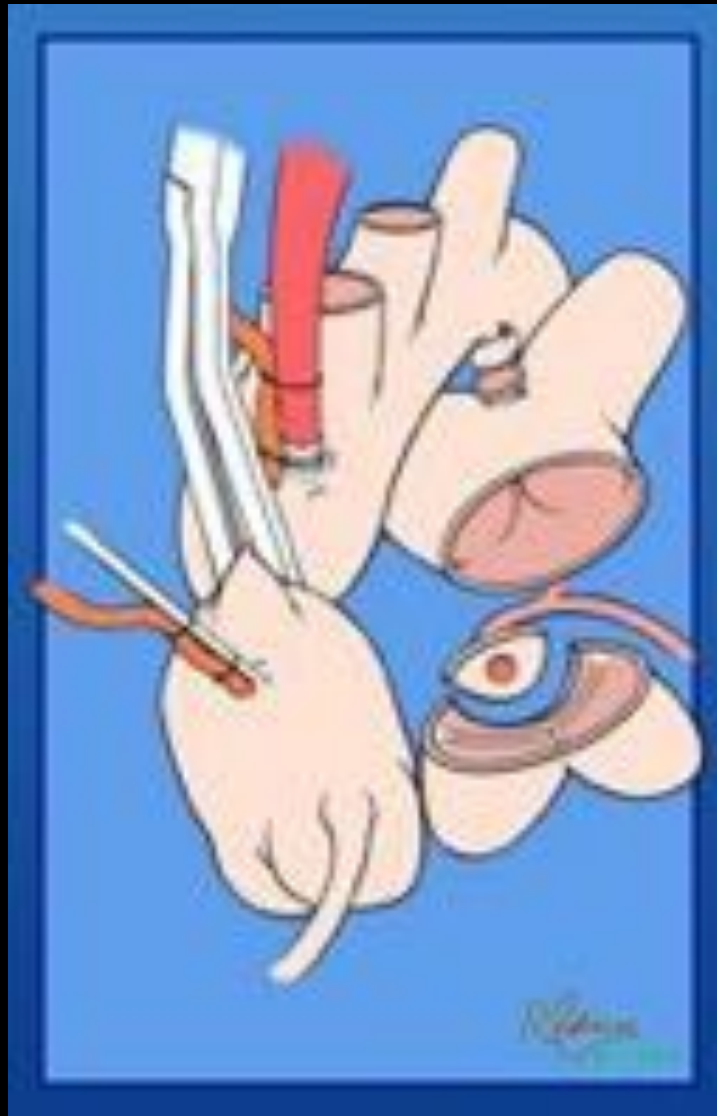
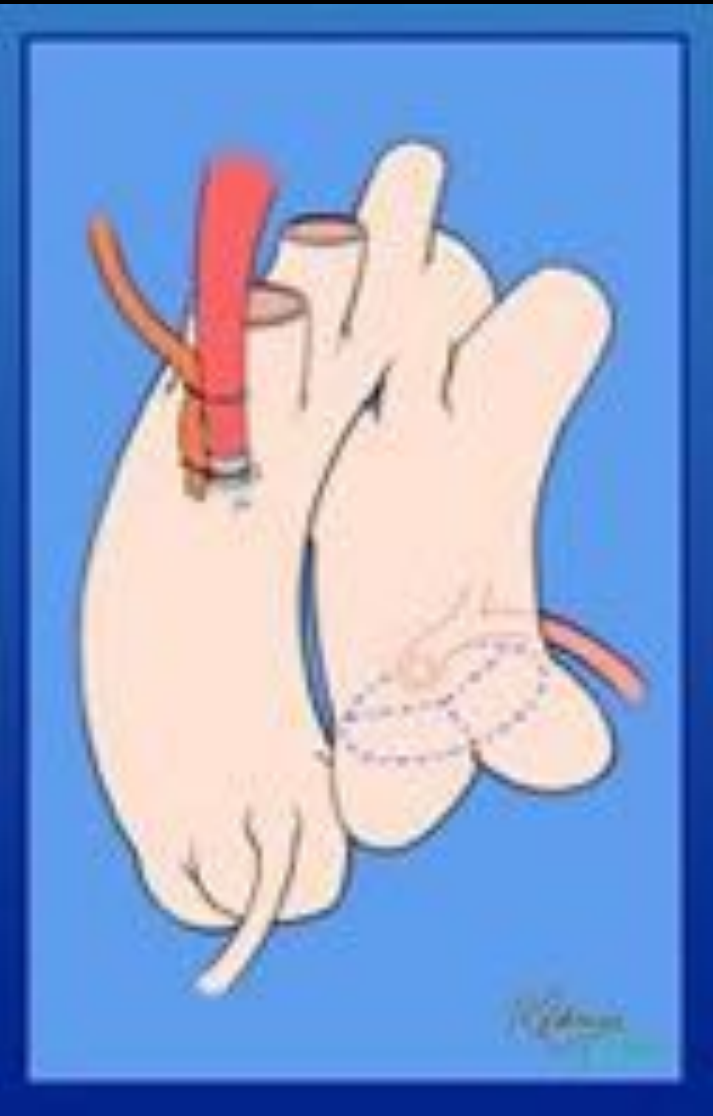Abnormal origin from the pulmonary artery : ARCAPA



Coronary artery from the left ventricle

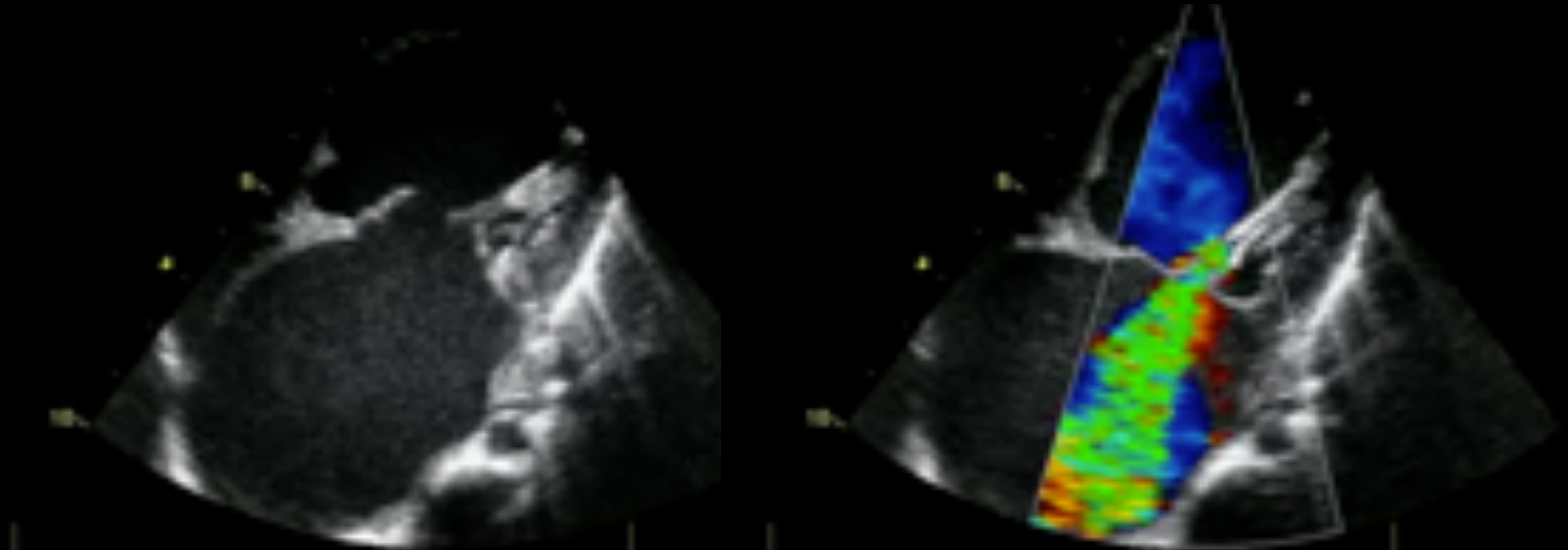

Abnormal origin from the pulmonary artery : ALCAPA surgery



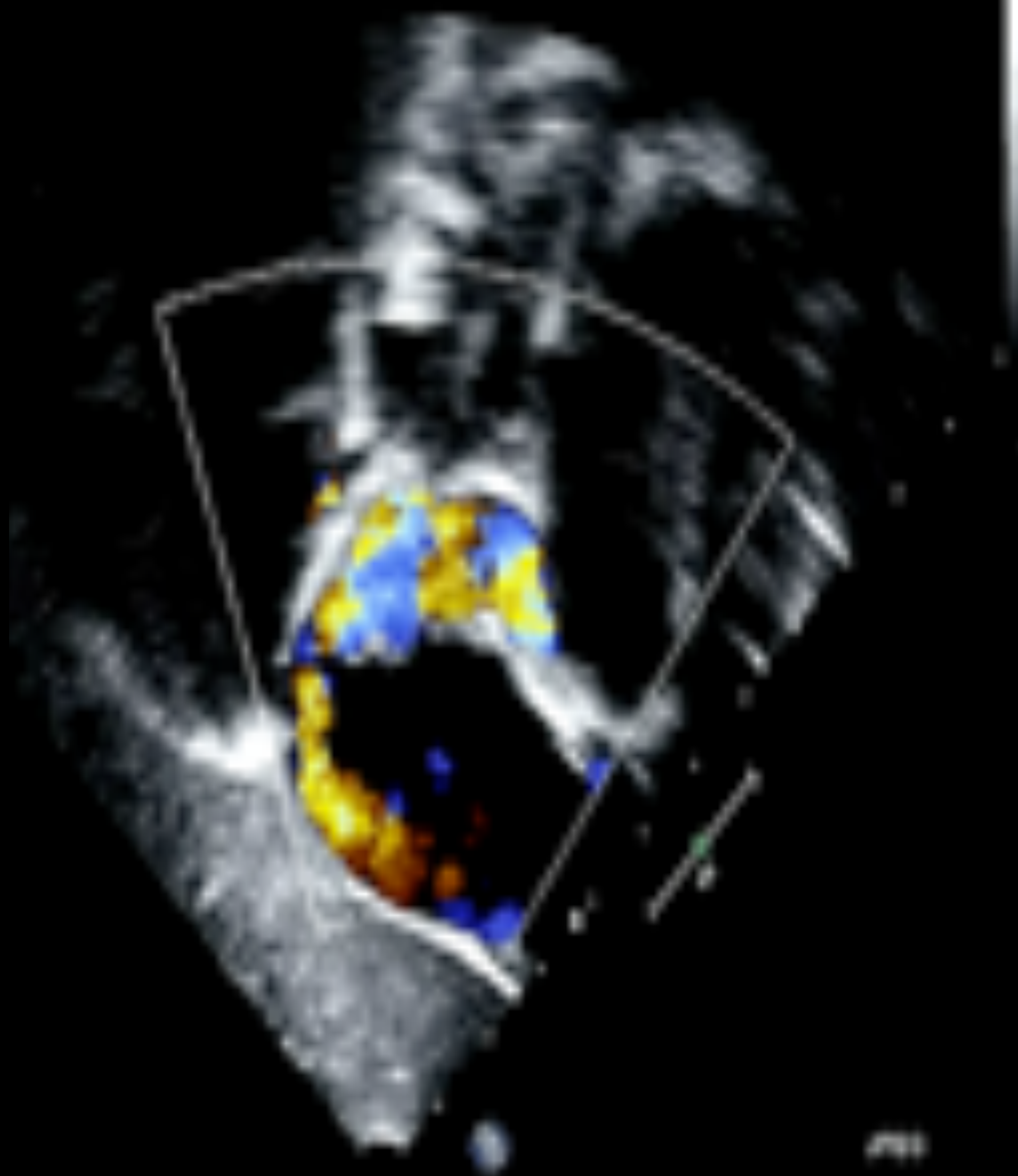
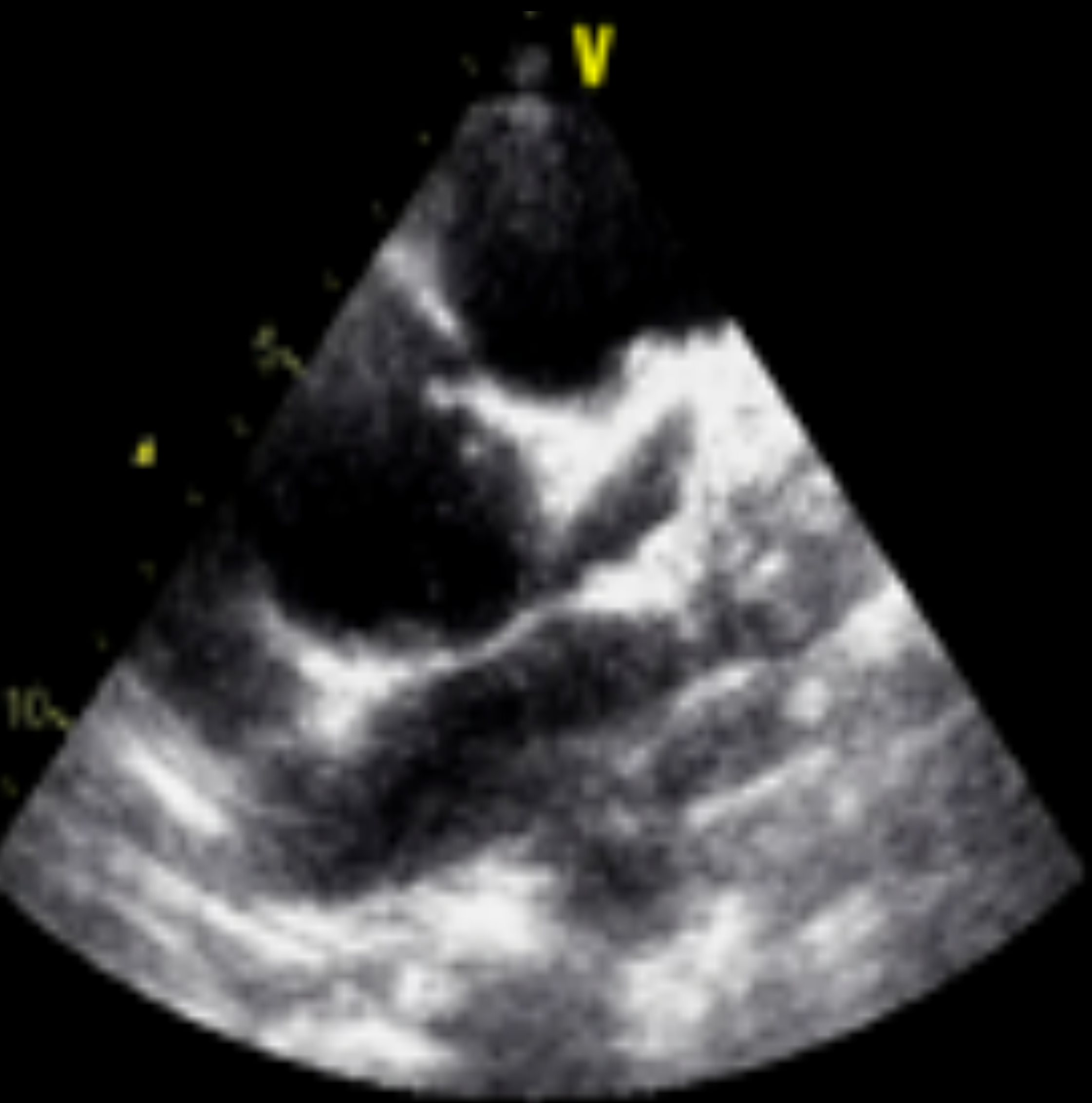
Abnormal origin from the pulmonary artery : ALCAPA

Mitral regurgitation

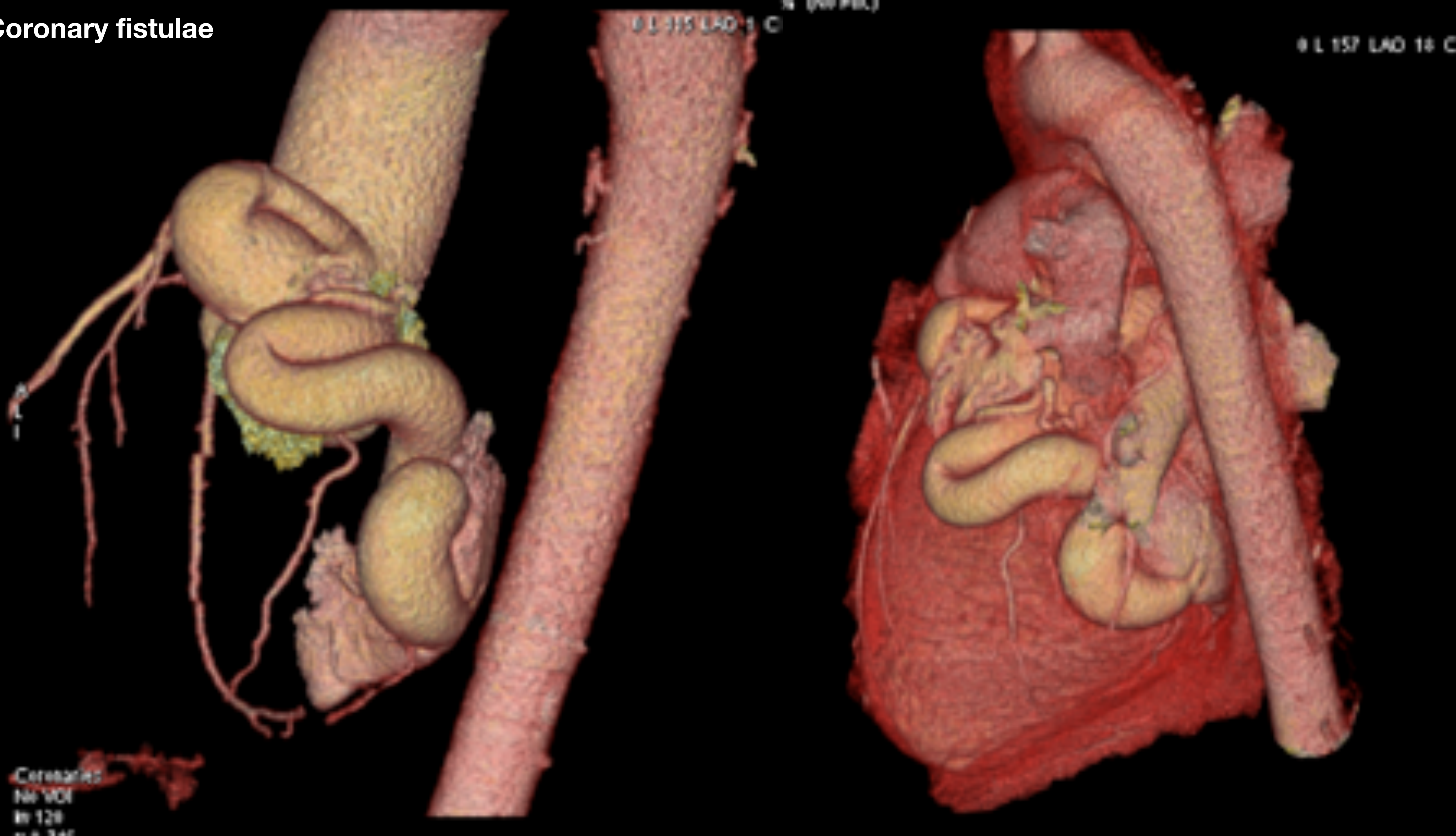


Coronary fistulae

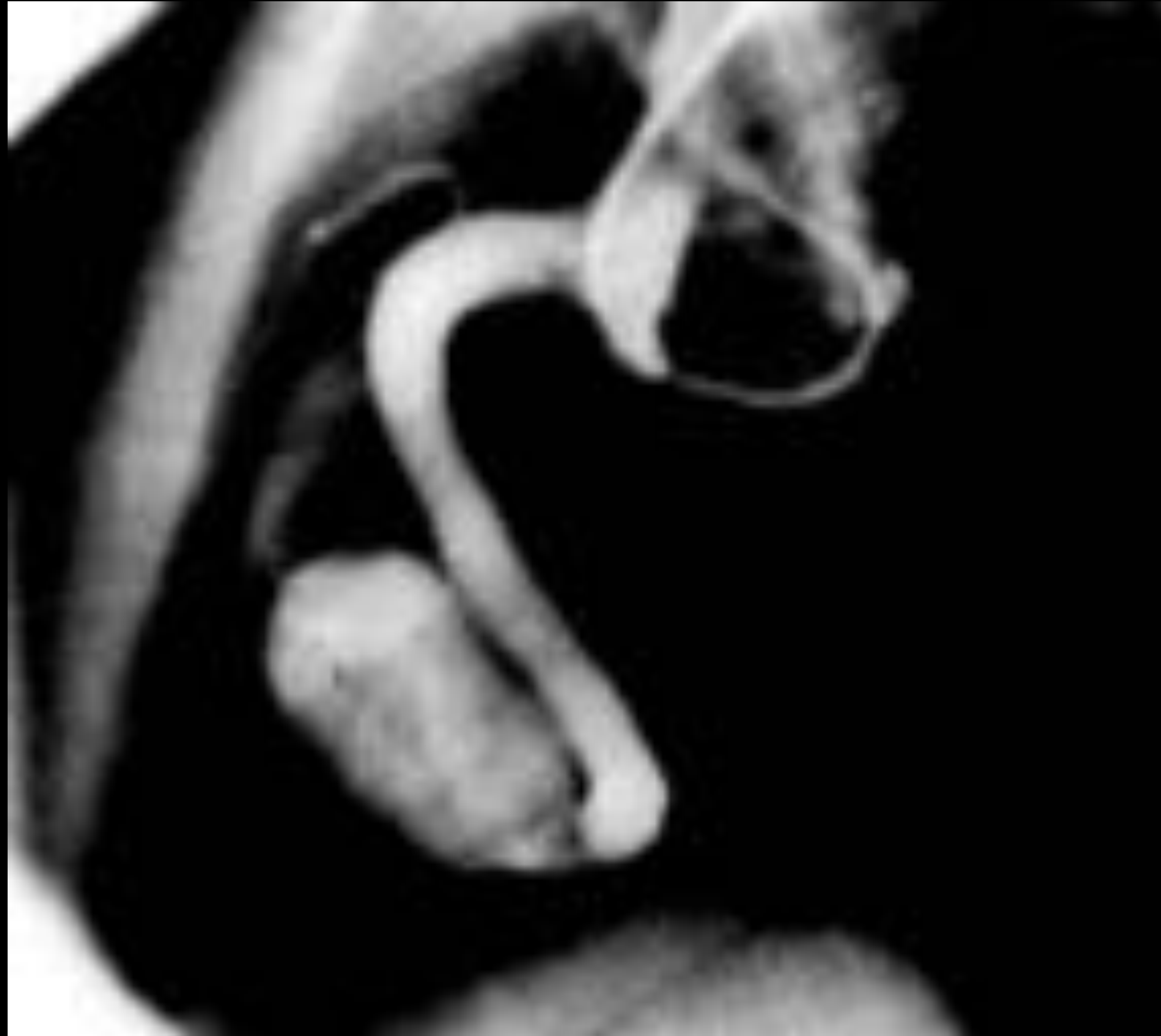Coronary fistulae



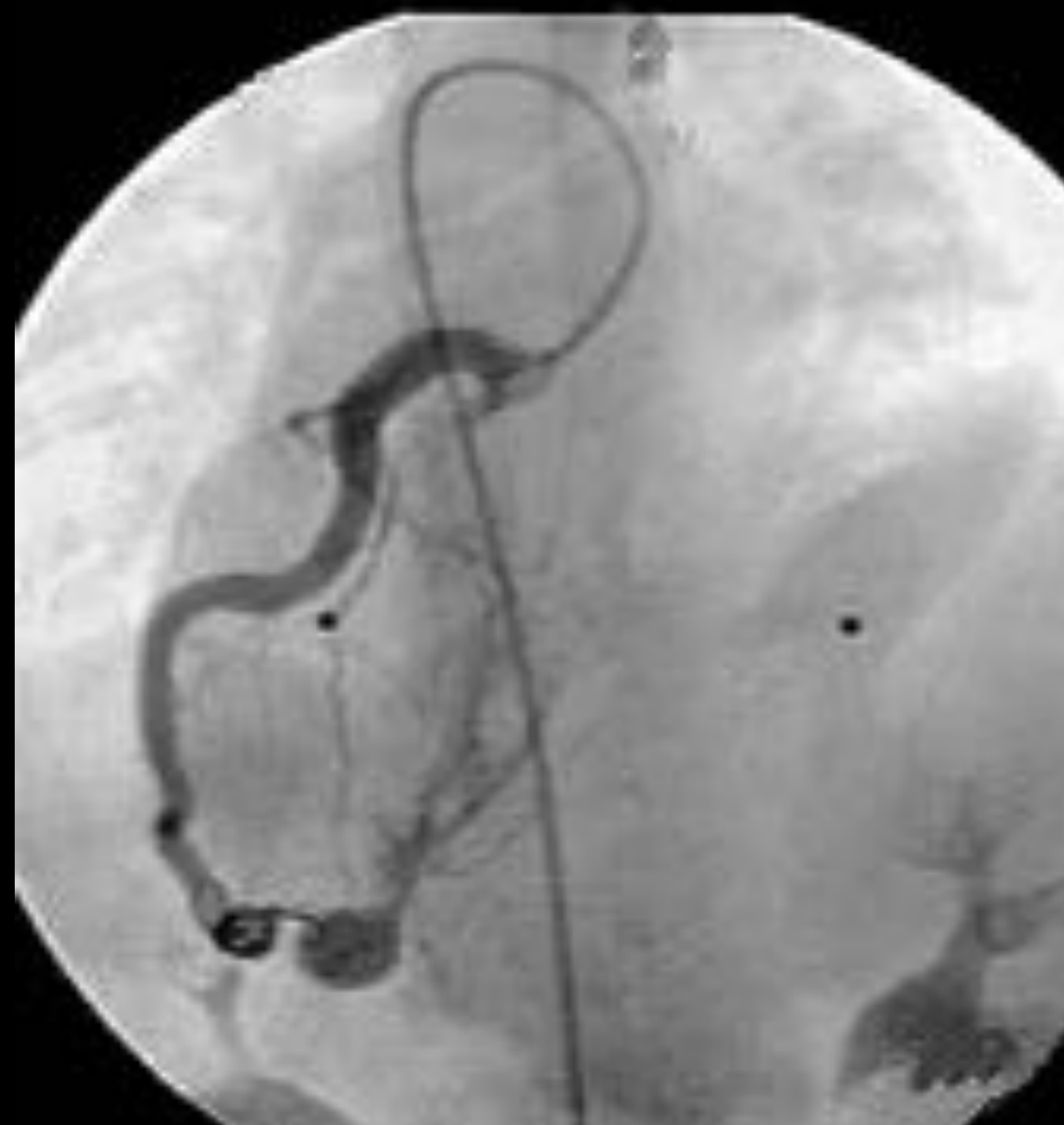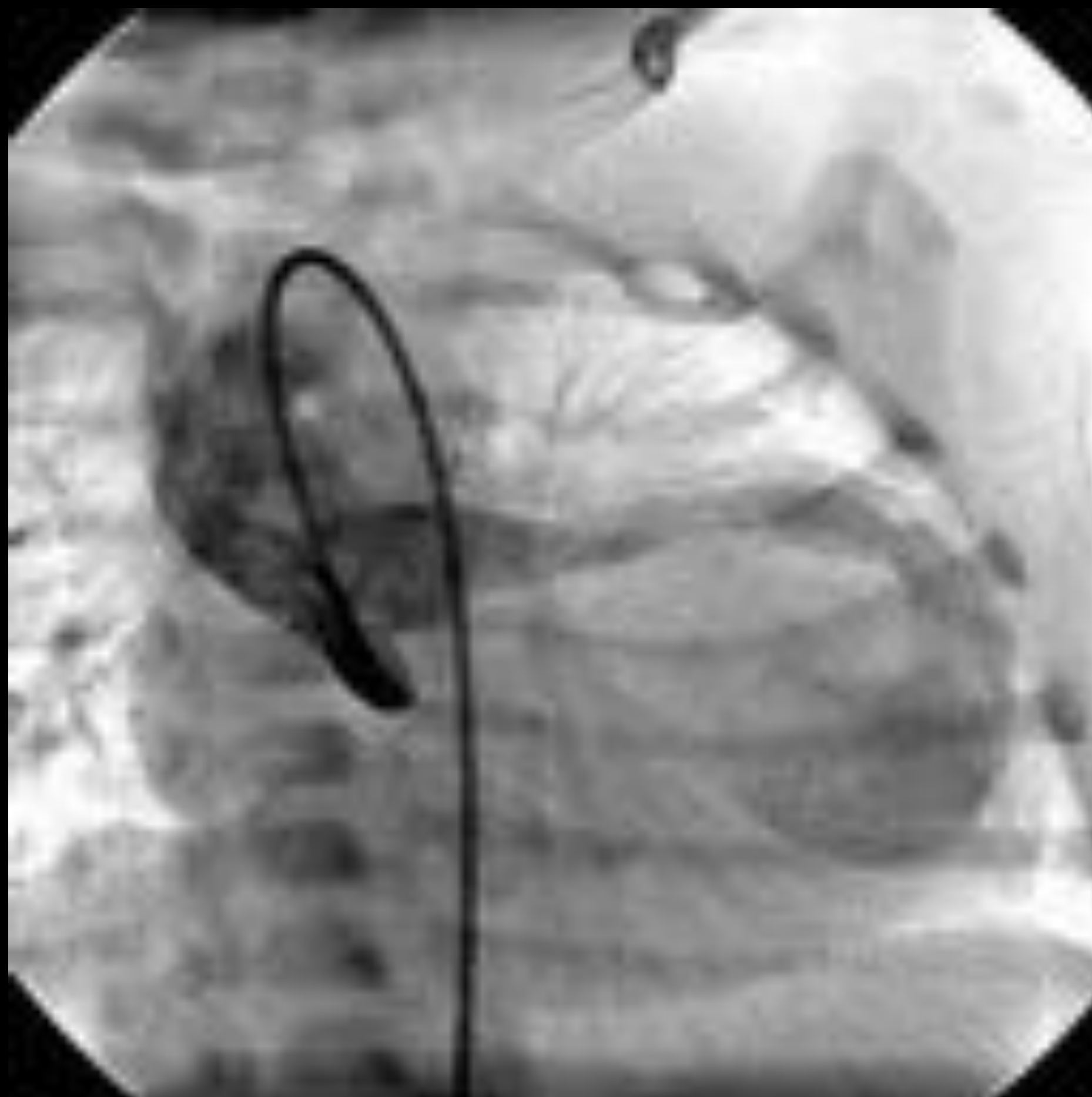Coronary fistulae



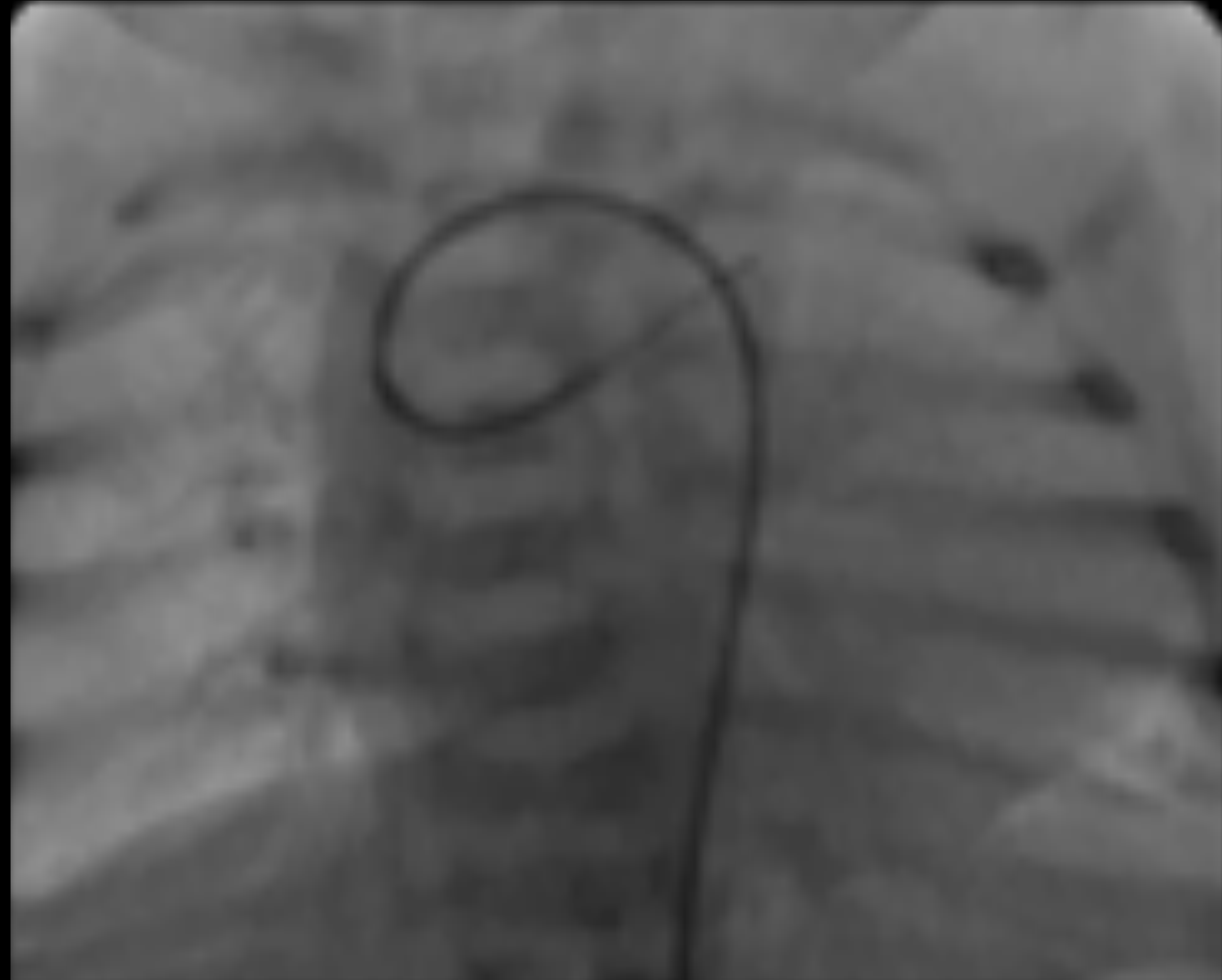Coronary fistulae



Coronary fistulae

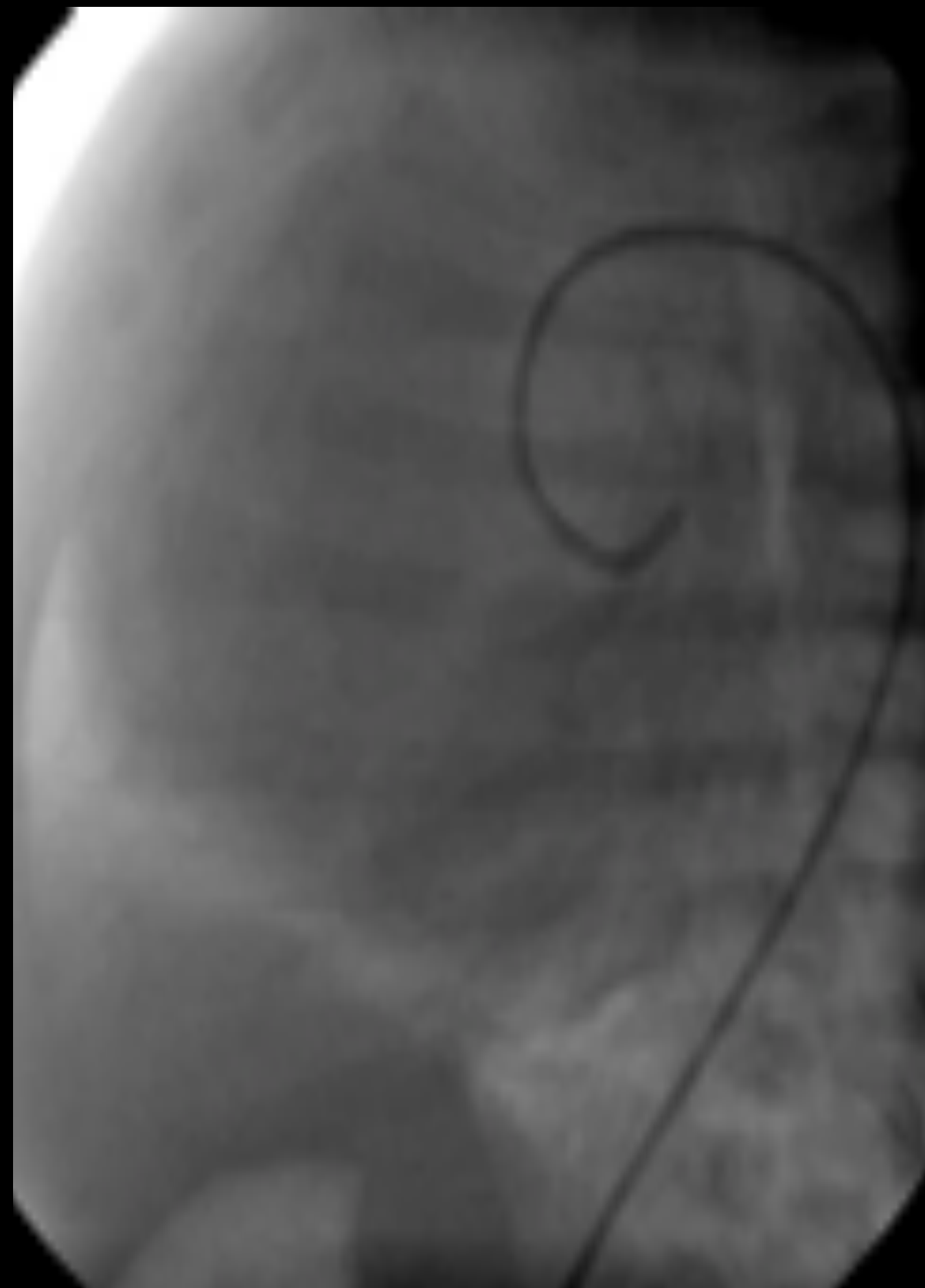
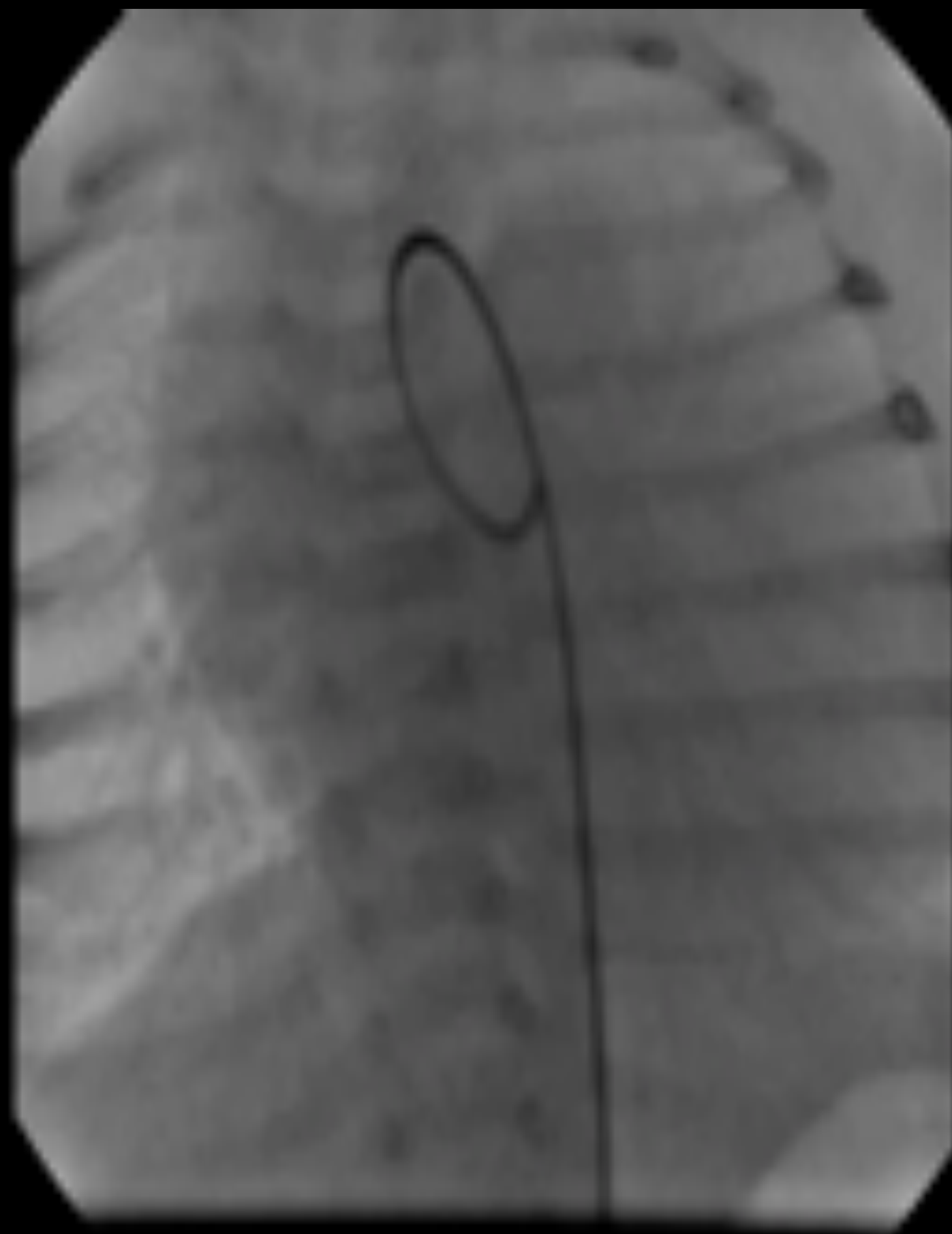


Coronary fistulae

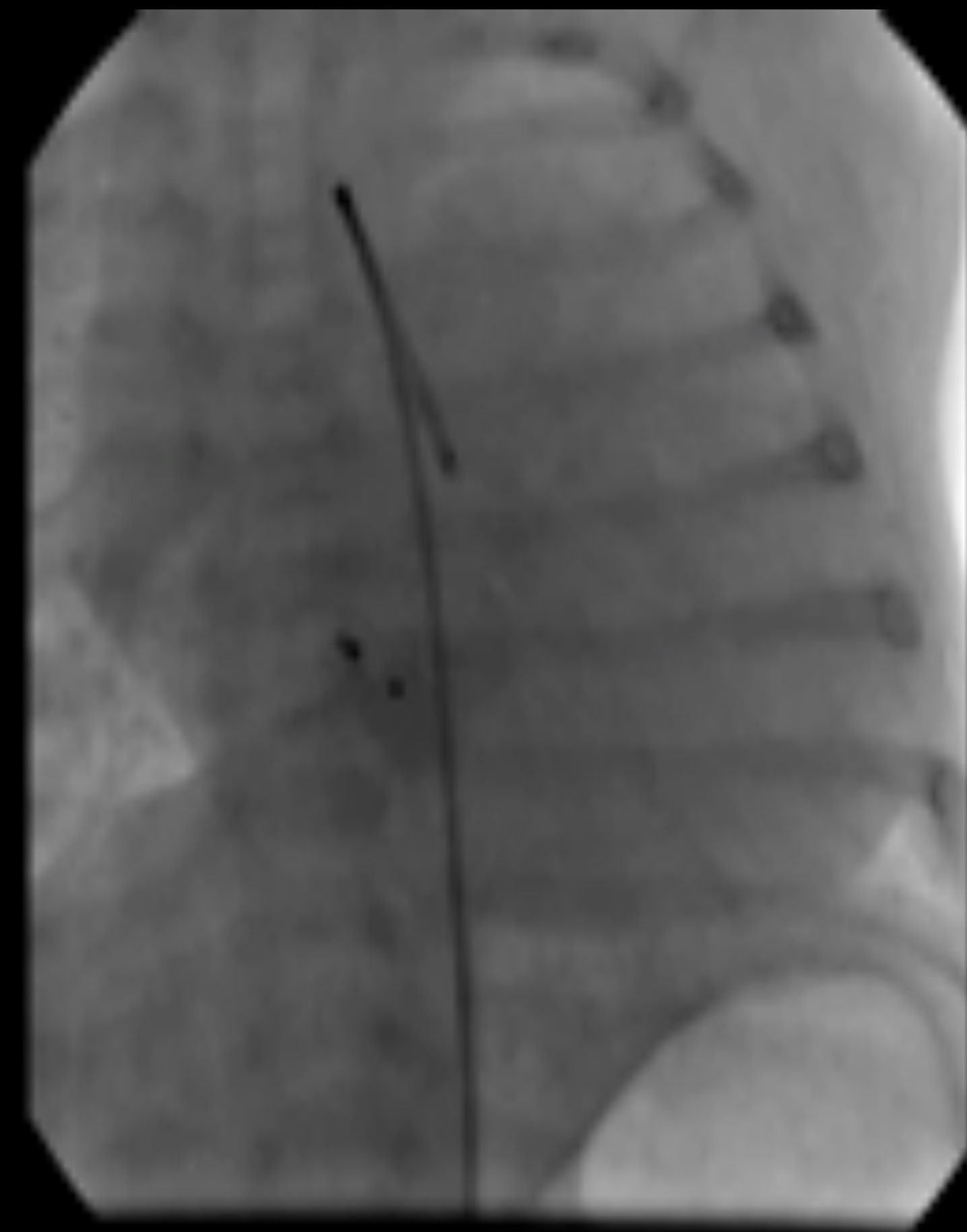

Coronary fistulae

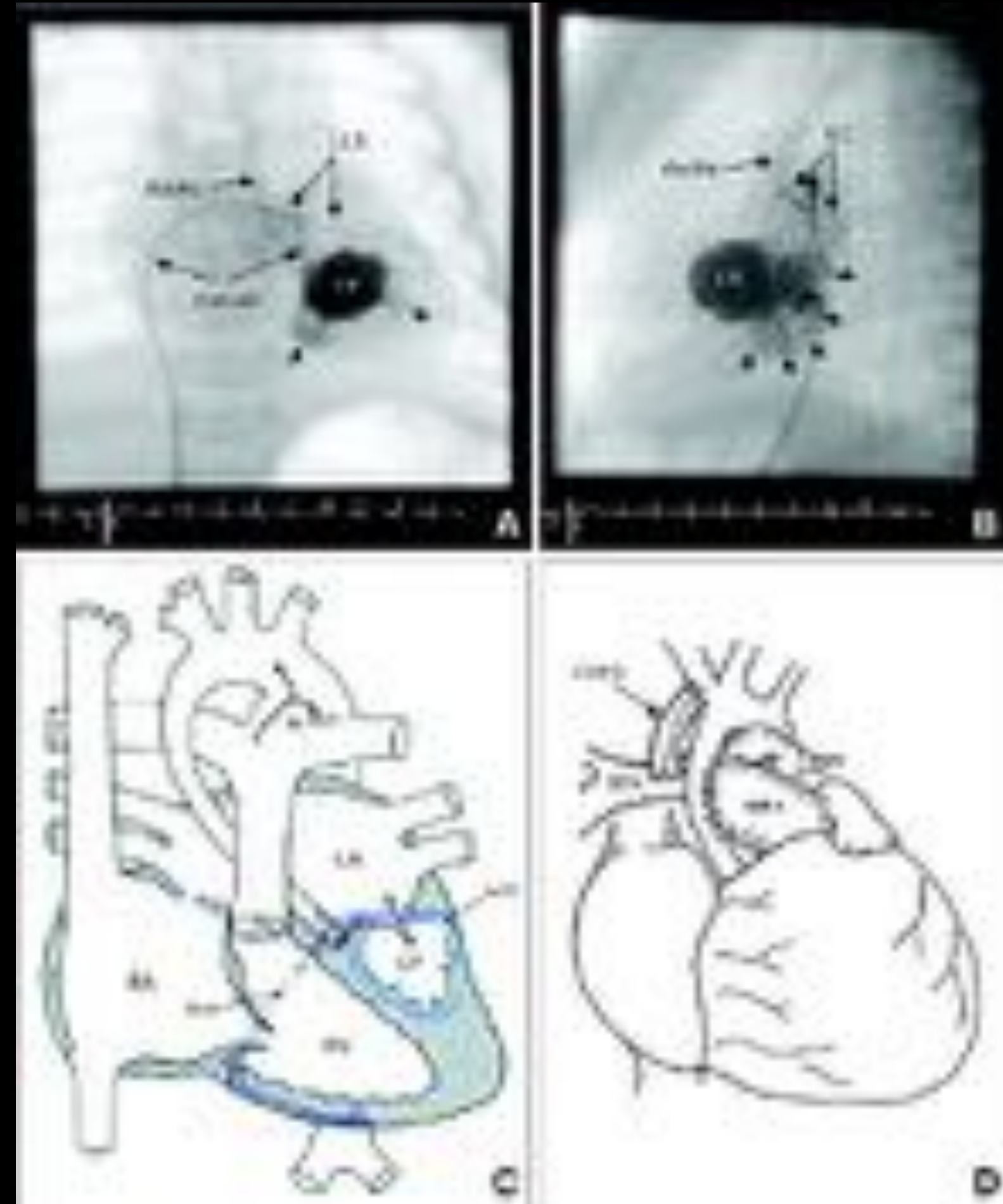
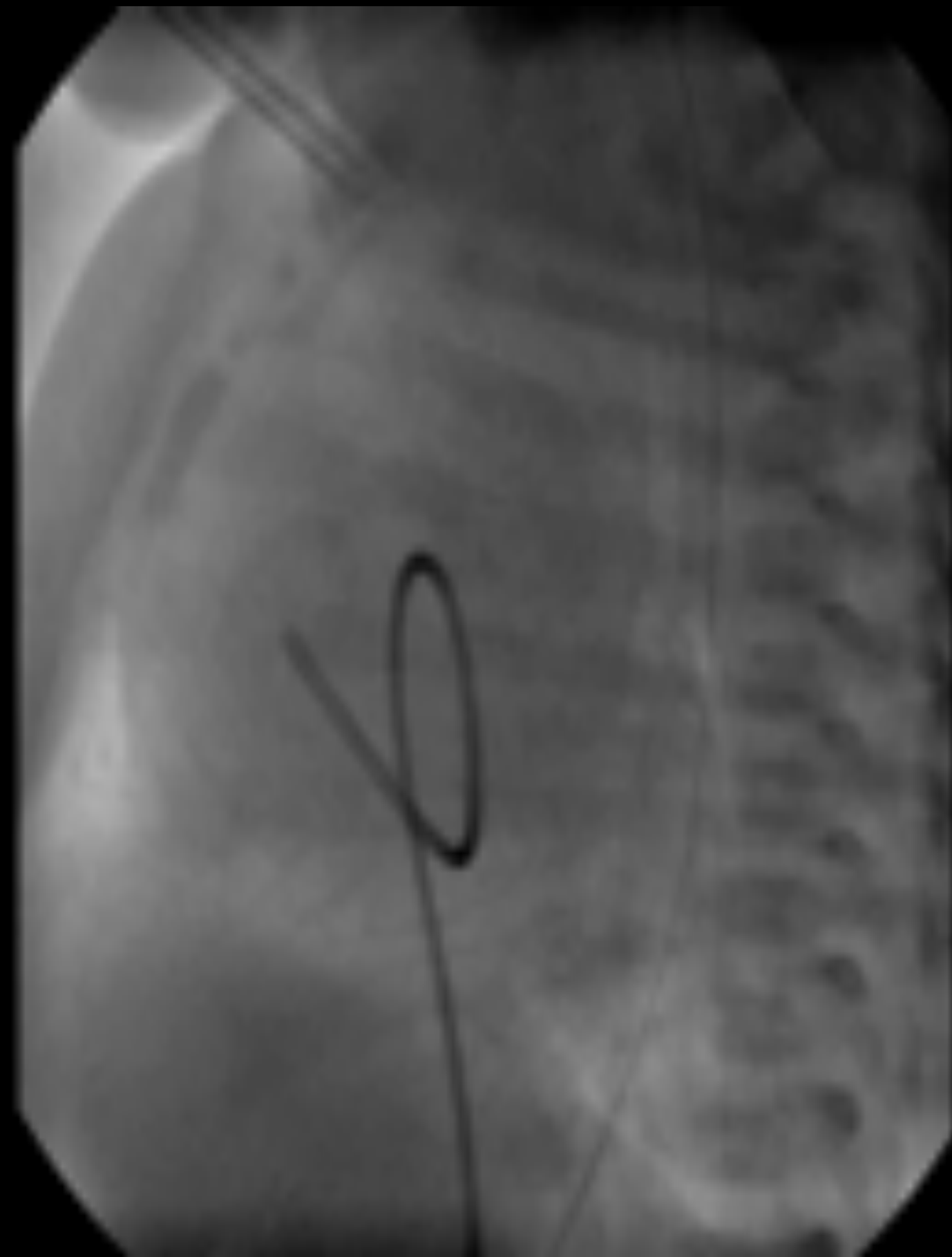Pre-embolization



Post-embolization

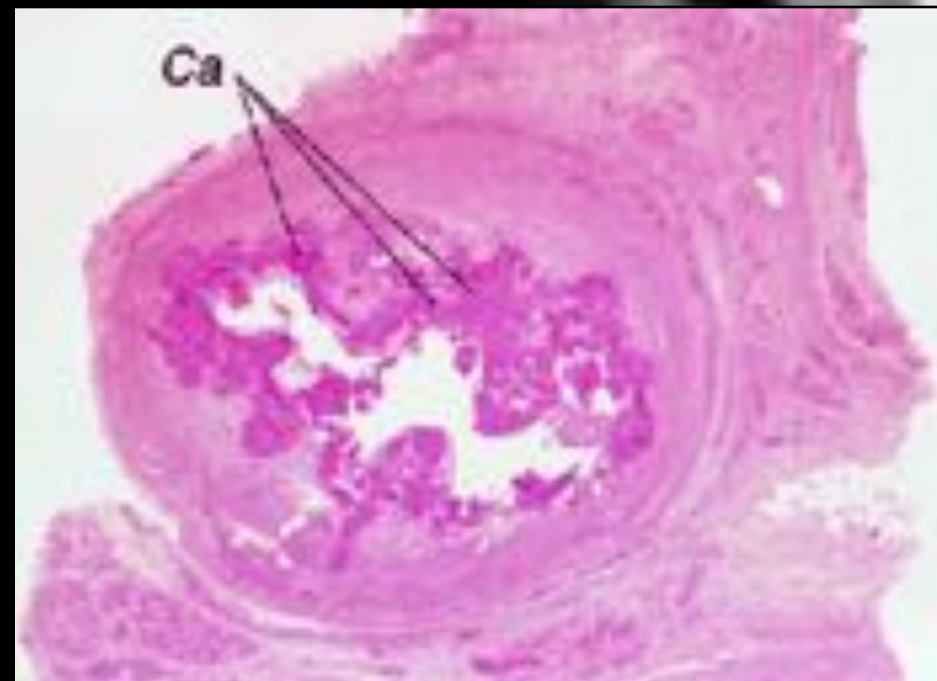
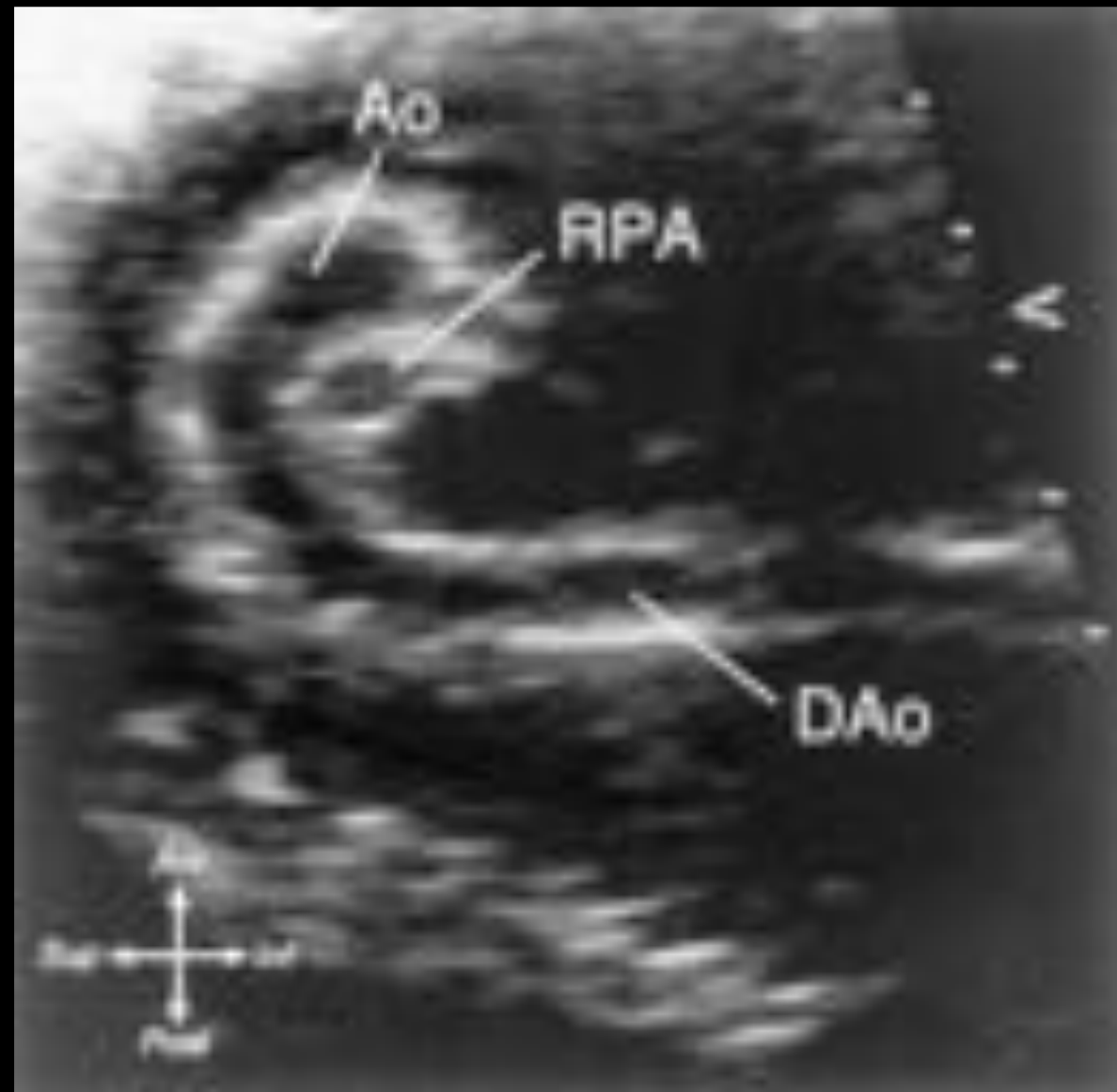
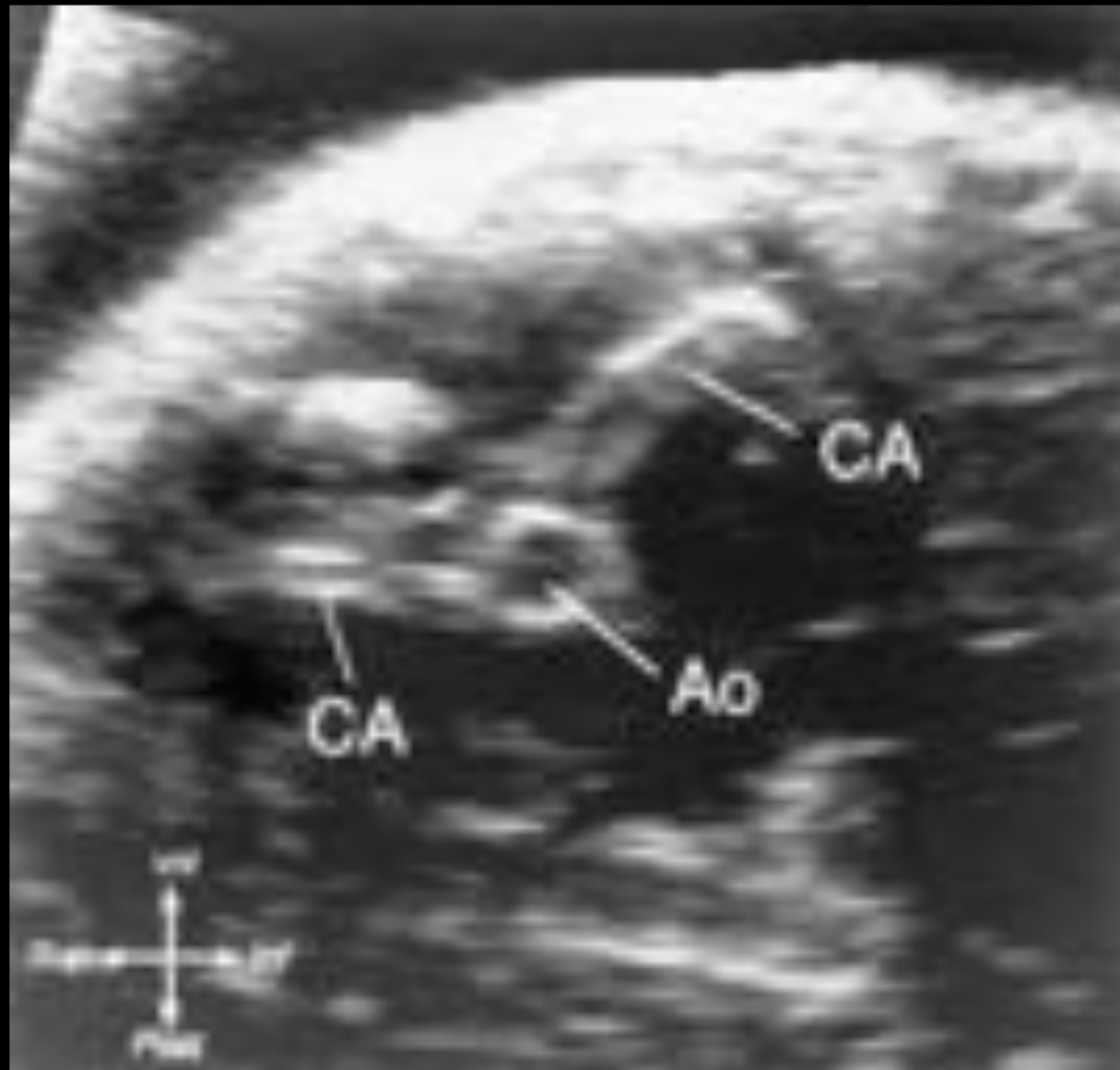
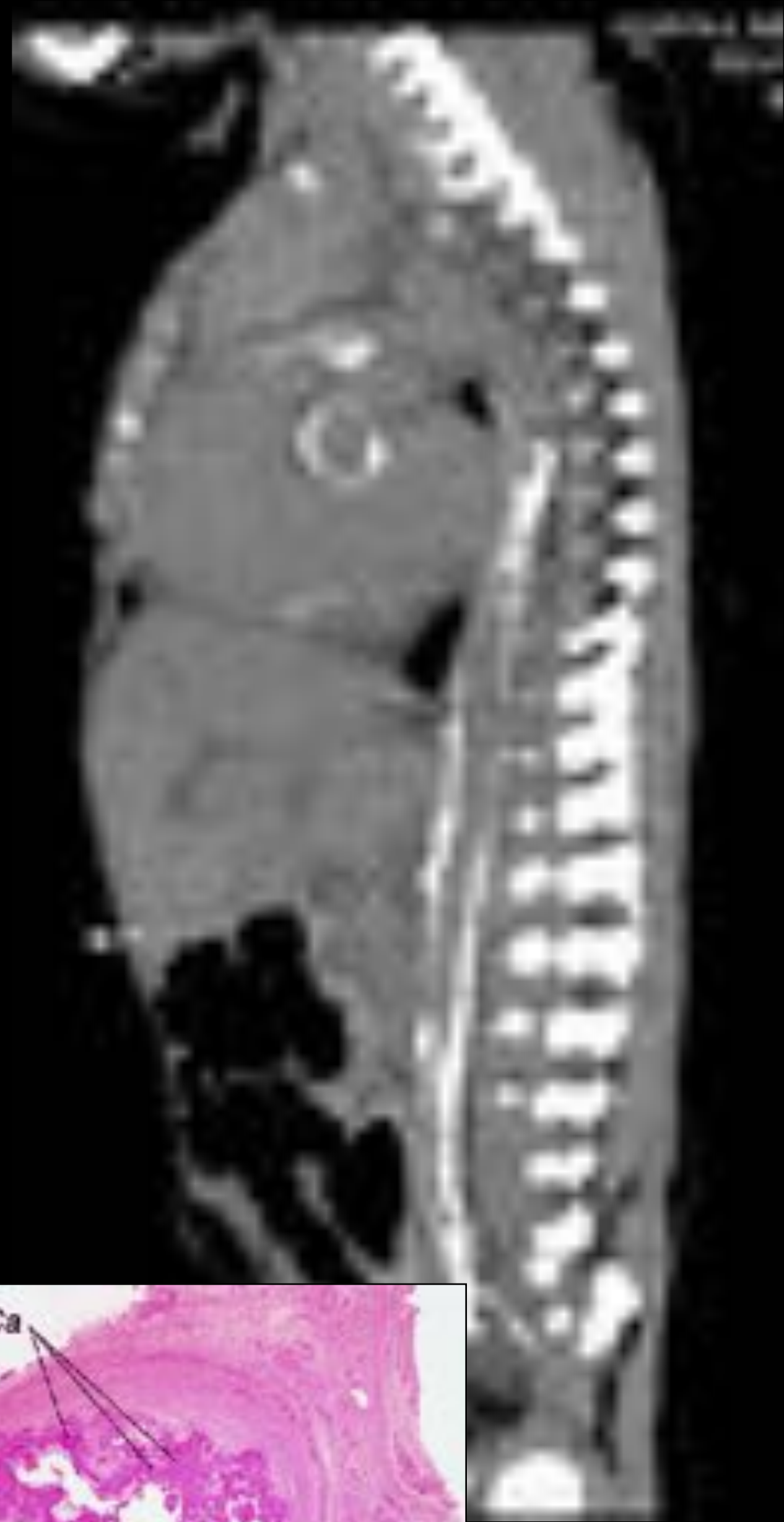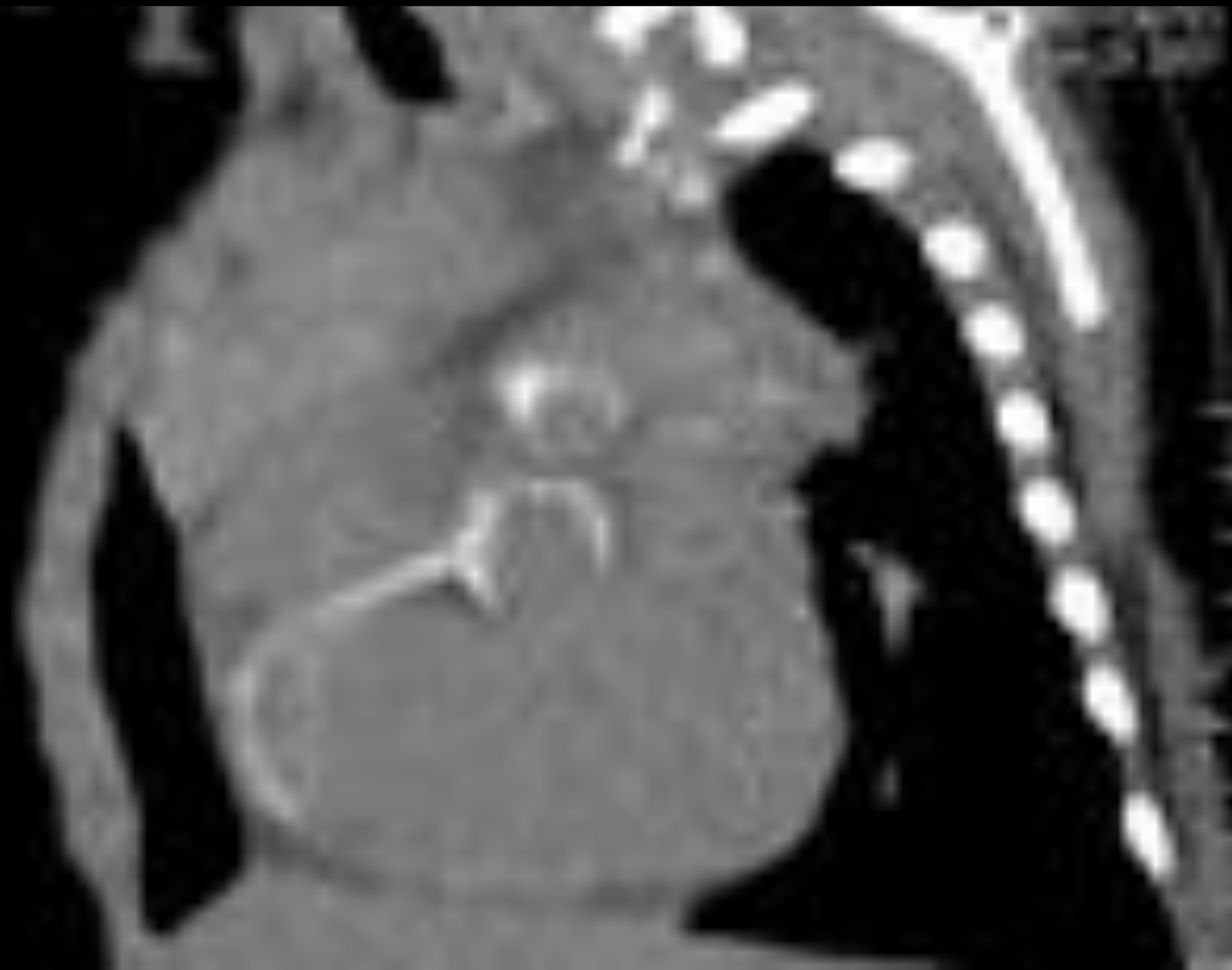Coronary fistulae in PA-IVS & HLHS

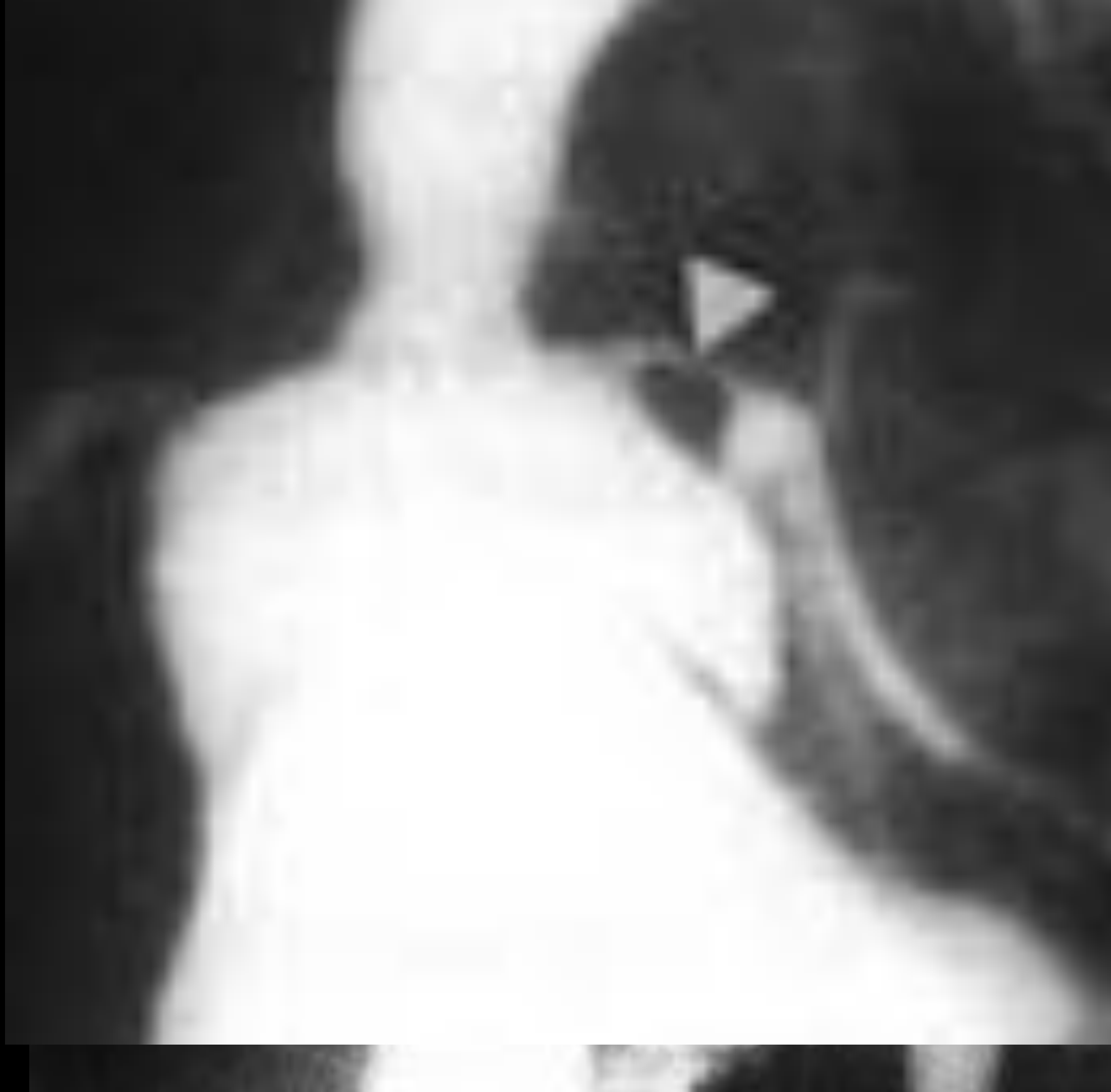

Rares anomalies

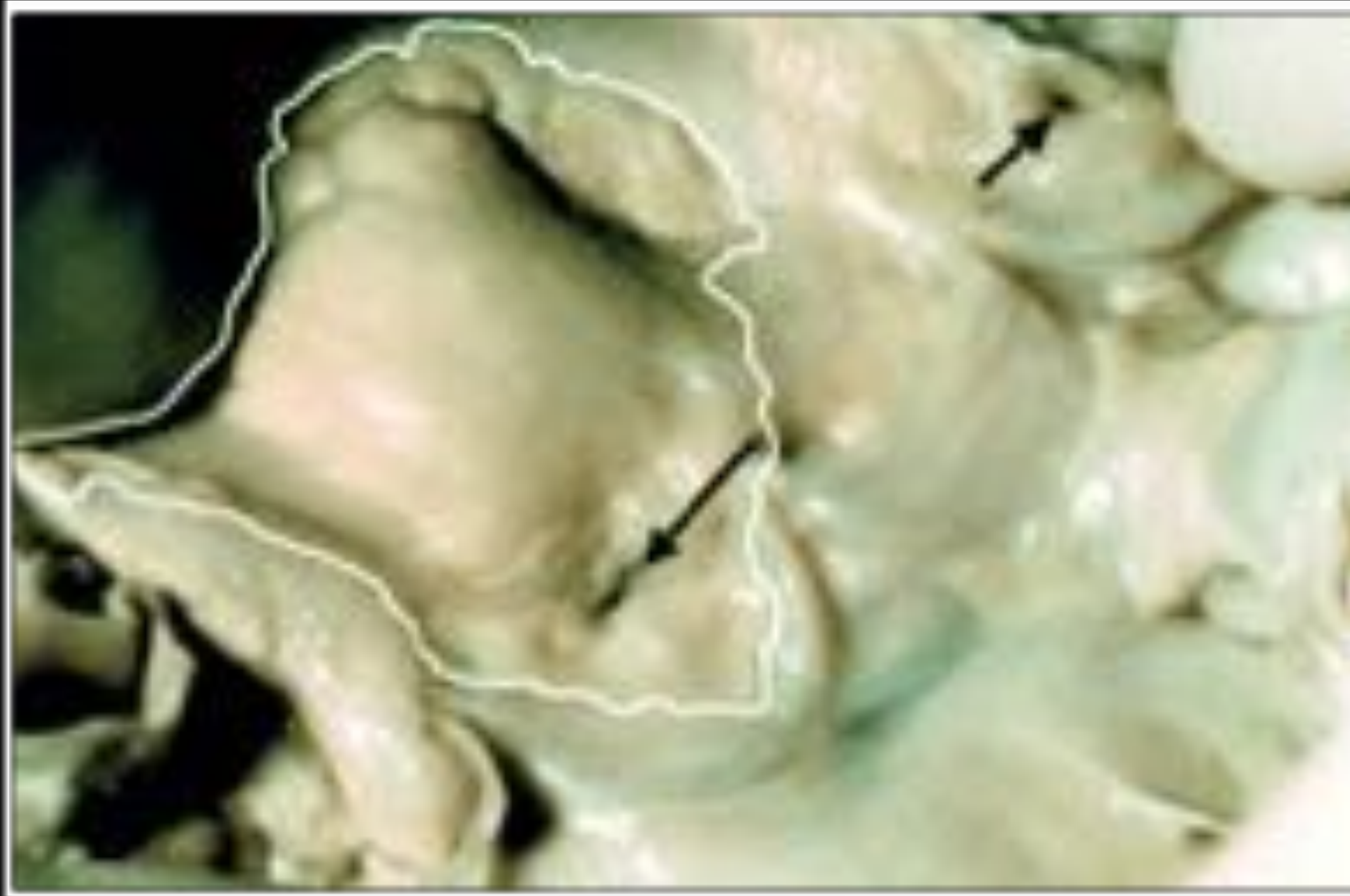
GACI



SVAS



Hypercholesterolemia



Acquired coronary anomalies

Kawasaki disease

Post-operative coronary obstructions

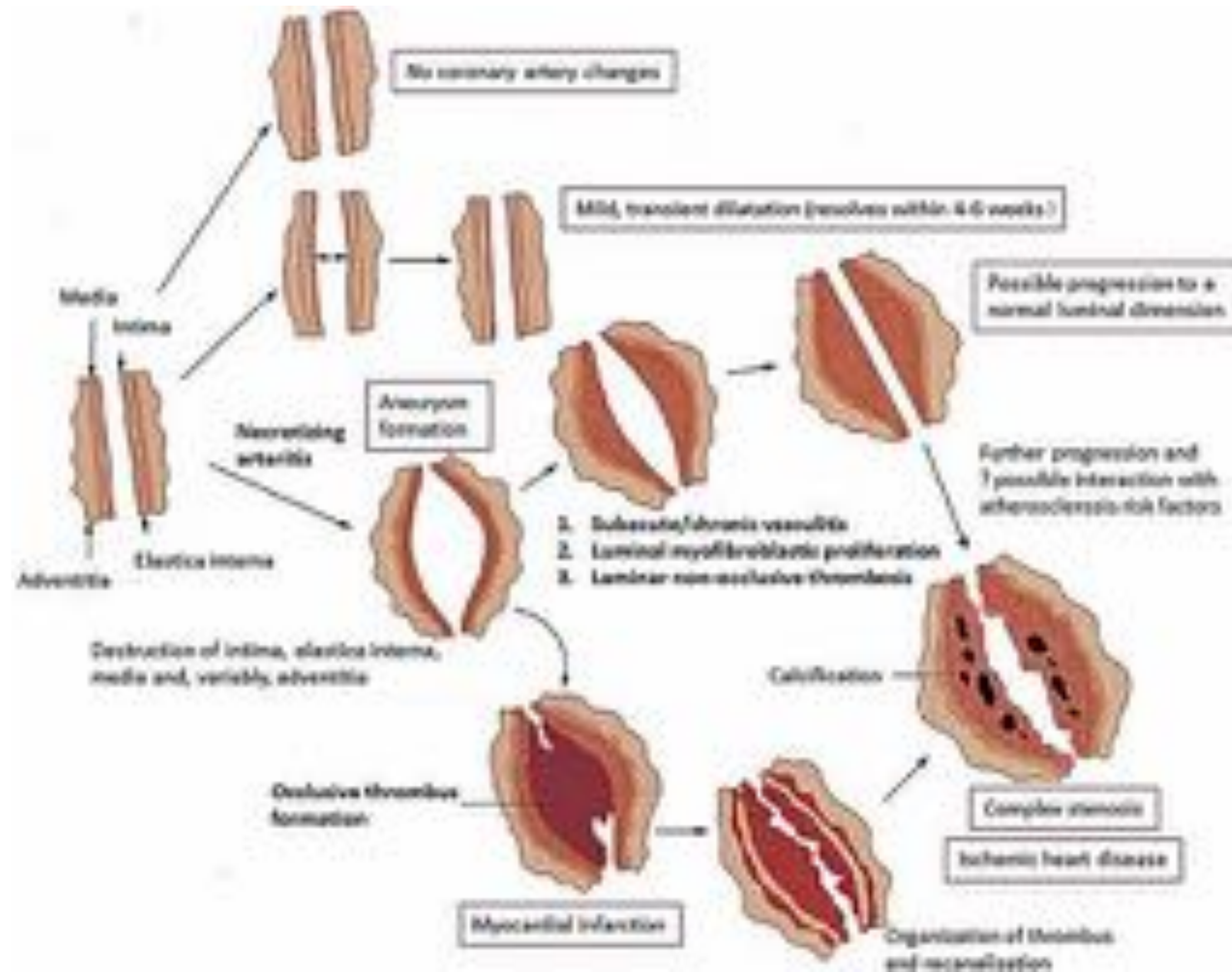
Kawasaki disease : Key points 1

1. Kawasaki disease (KD) is an acute, self-limited febrile illness of unknown cause that predominantly affects children <5 years of age.
2. KD is now **the most common cause of acquired heart disease in children in developed countries.**
3. In the **absence of pathognomonic tests**, the diagnosis continues to rest on the **identification of principal clinical findings** and the exclusion of other clinically similar entities with known causes.

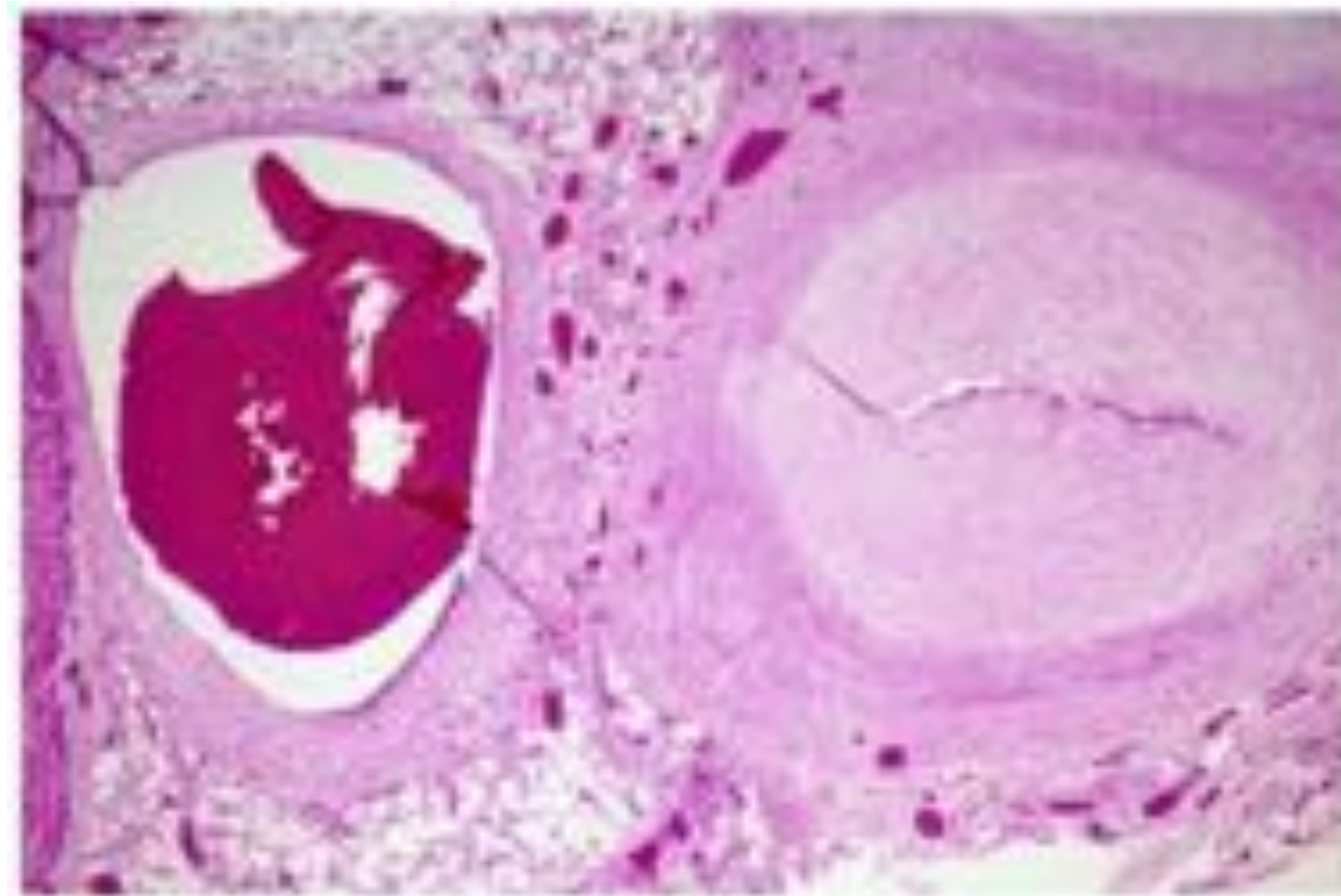
Kawasaki disease : Key points 2

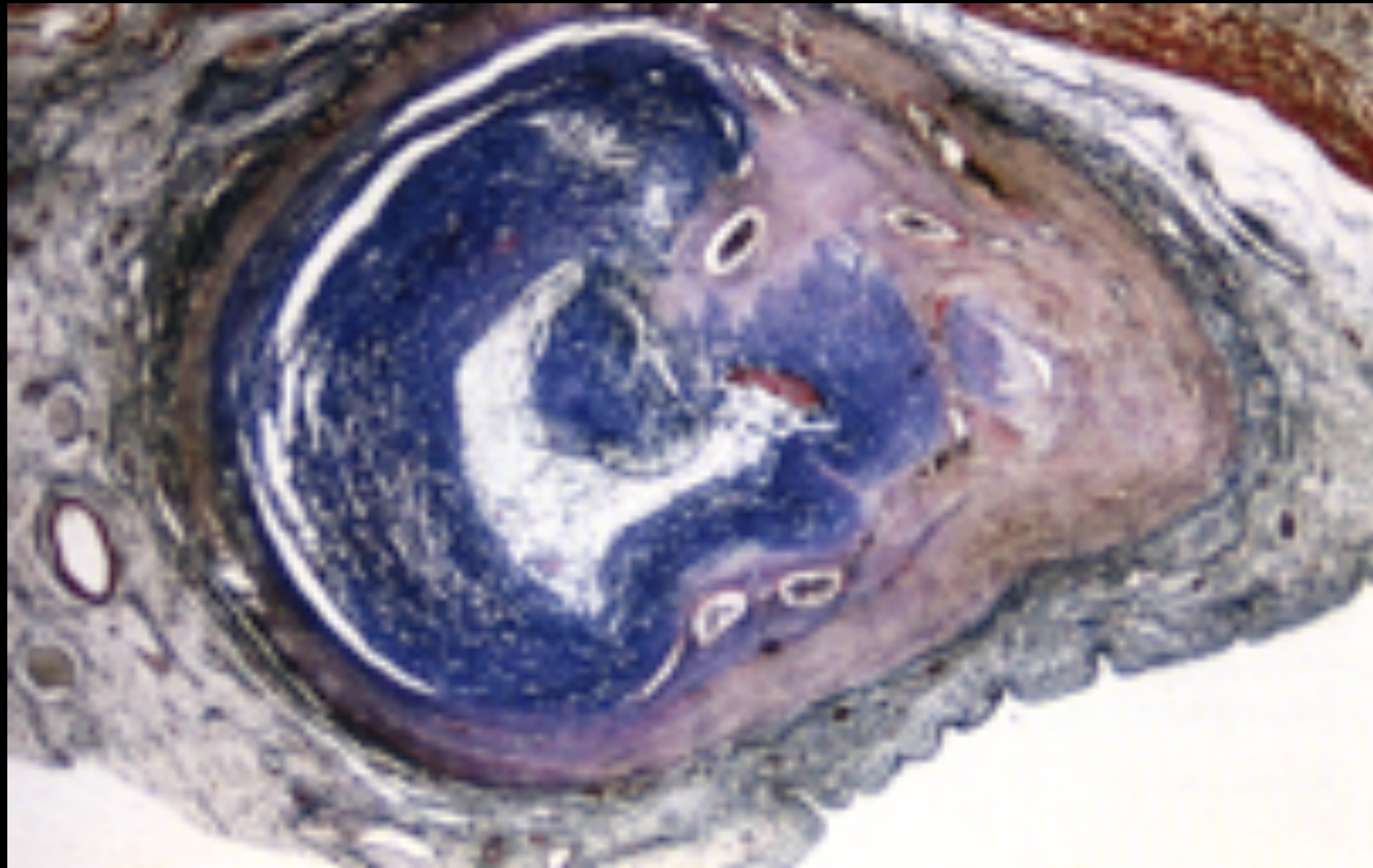
1. **Timely initiation of treatment with intravenous immunoglobulin (IVIG) has reduced the incidence of coronary artery aneurysms** defined from absolute luminal dimensions from 25% to $\approx 4\%$. Ongoing studies with **additional therapies have not substantially** reduced this residual risk.
2. **The long-term prognosis is determined by the initial and current level of coronary artery involvement.** Certain subsets of patients are at risk for myocardial ischemia from coronary artery thrombosis and stenoses.
3. Medical management of such patients hinges on judicious use of thromboprophylaxis and vigilance to identify evolving stenoses. Invasive revascularization procedures might be required for selected patients.

Natural history of coronary artery abnormalities

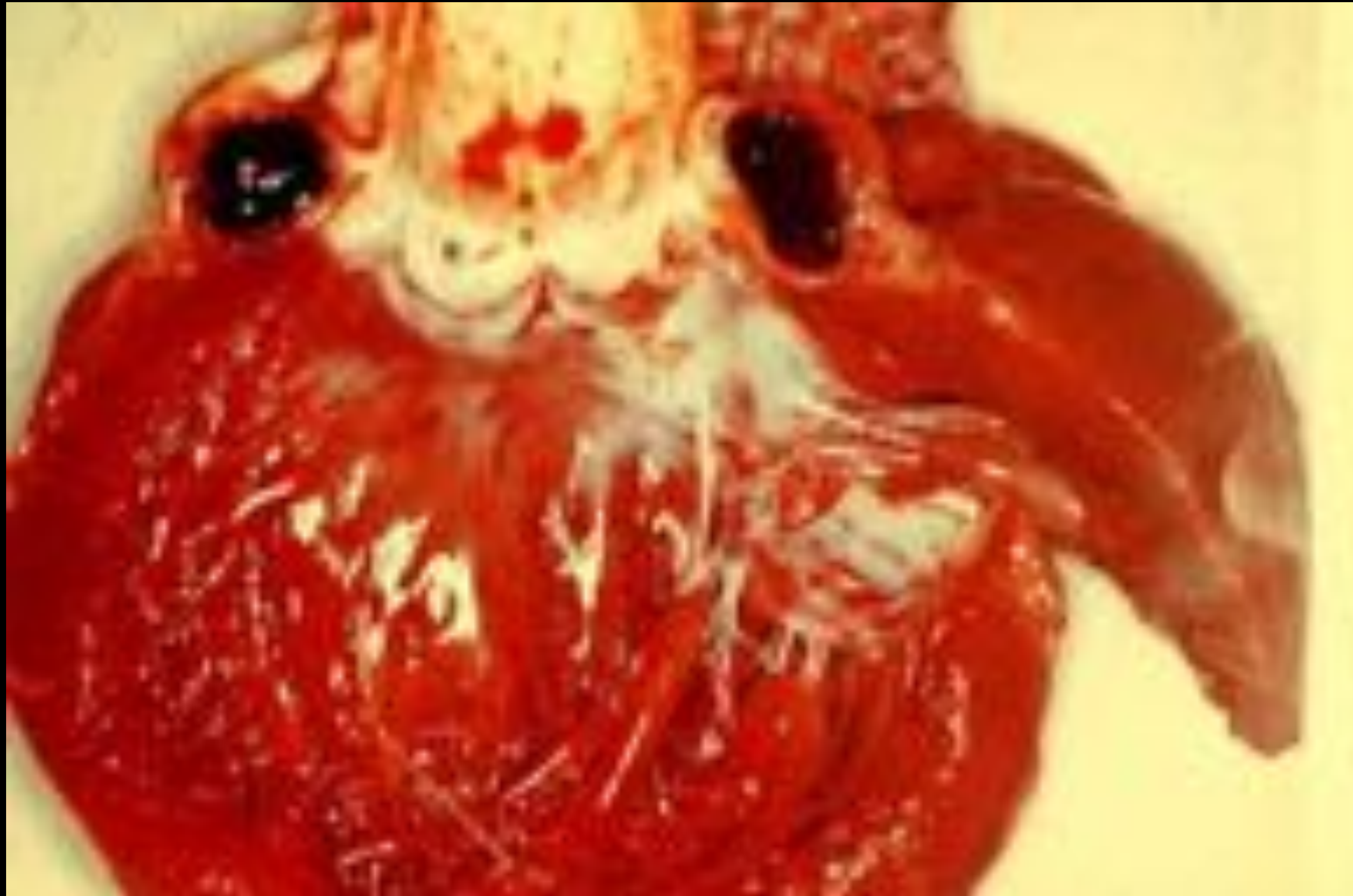

Epicardial coronary artery (right) and epicardial vein (left) from a 19-month-old child who died 10 months after Kawasaki disease onset.





Luminal myofibroblastic proliferation



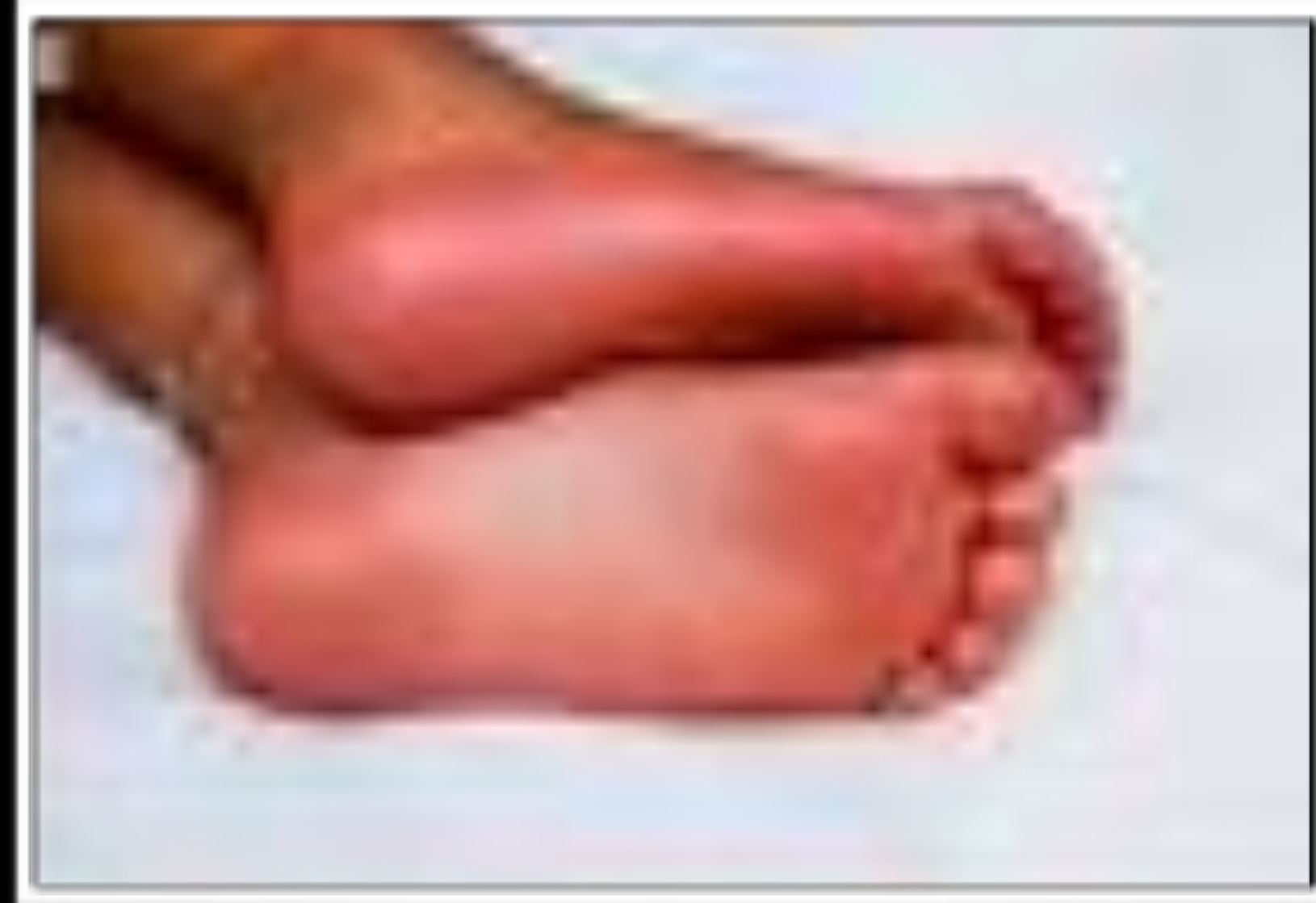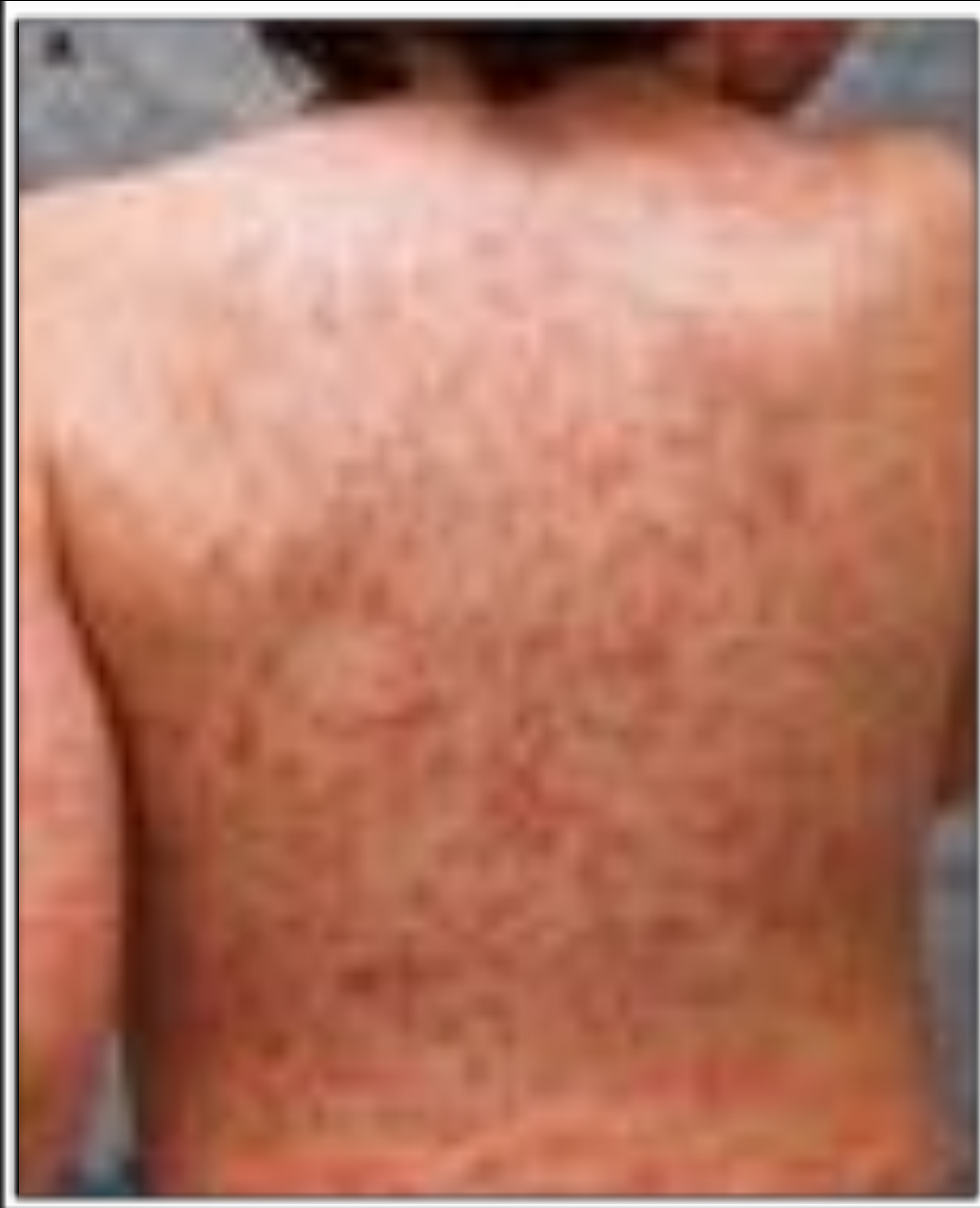Thrombosis of giant coronary artery aneurysms in Kawasaki disease

Clinical criteria for the diagnosis of Kawasaki disease

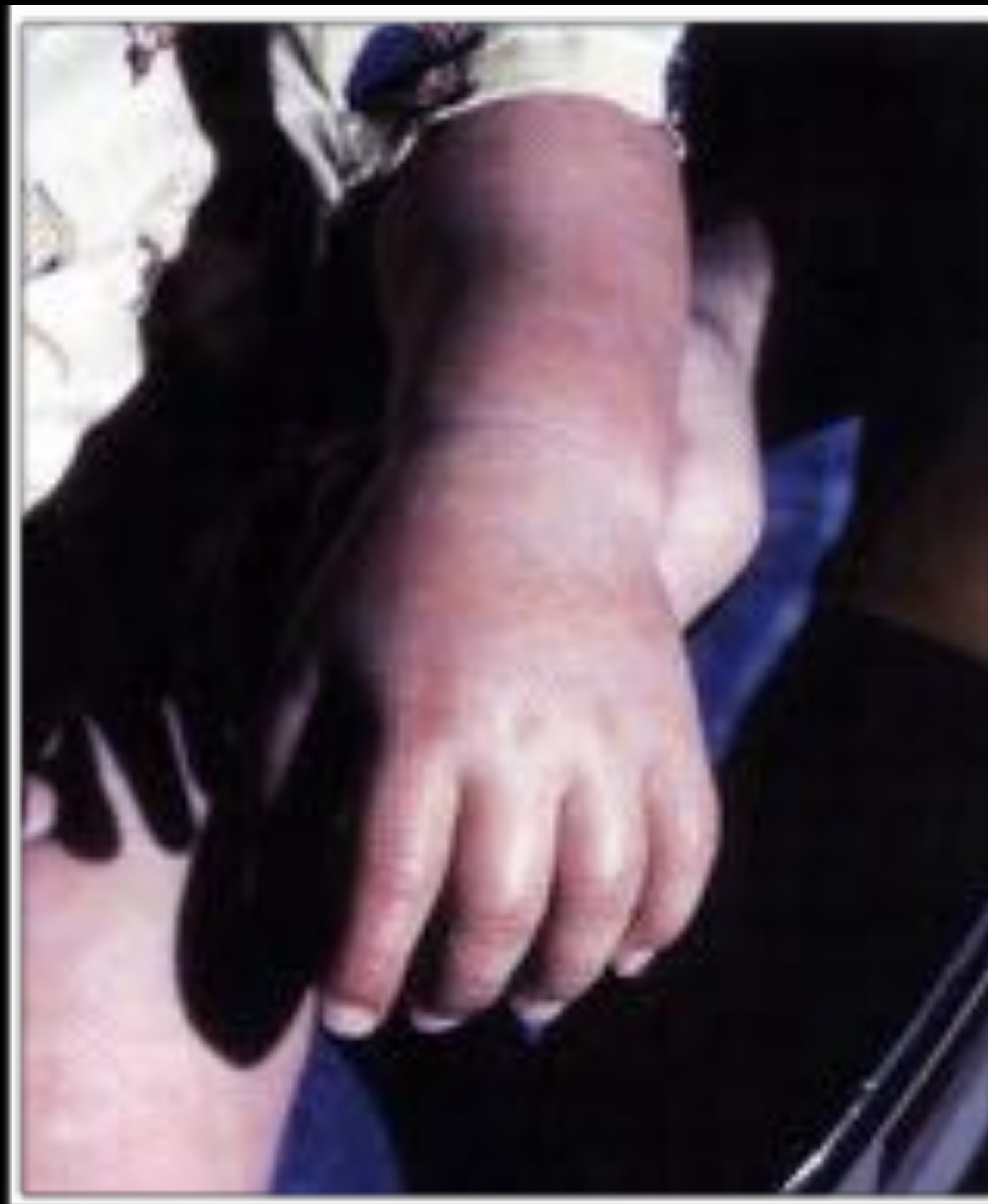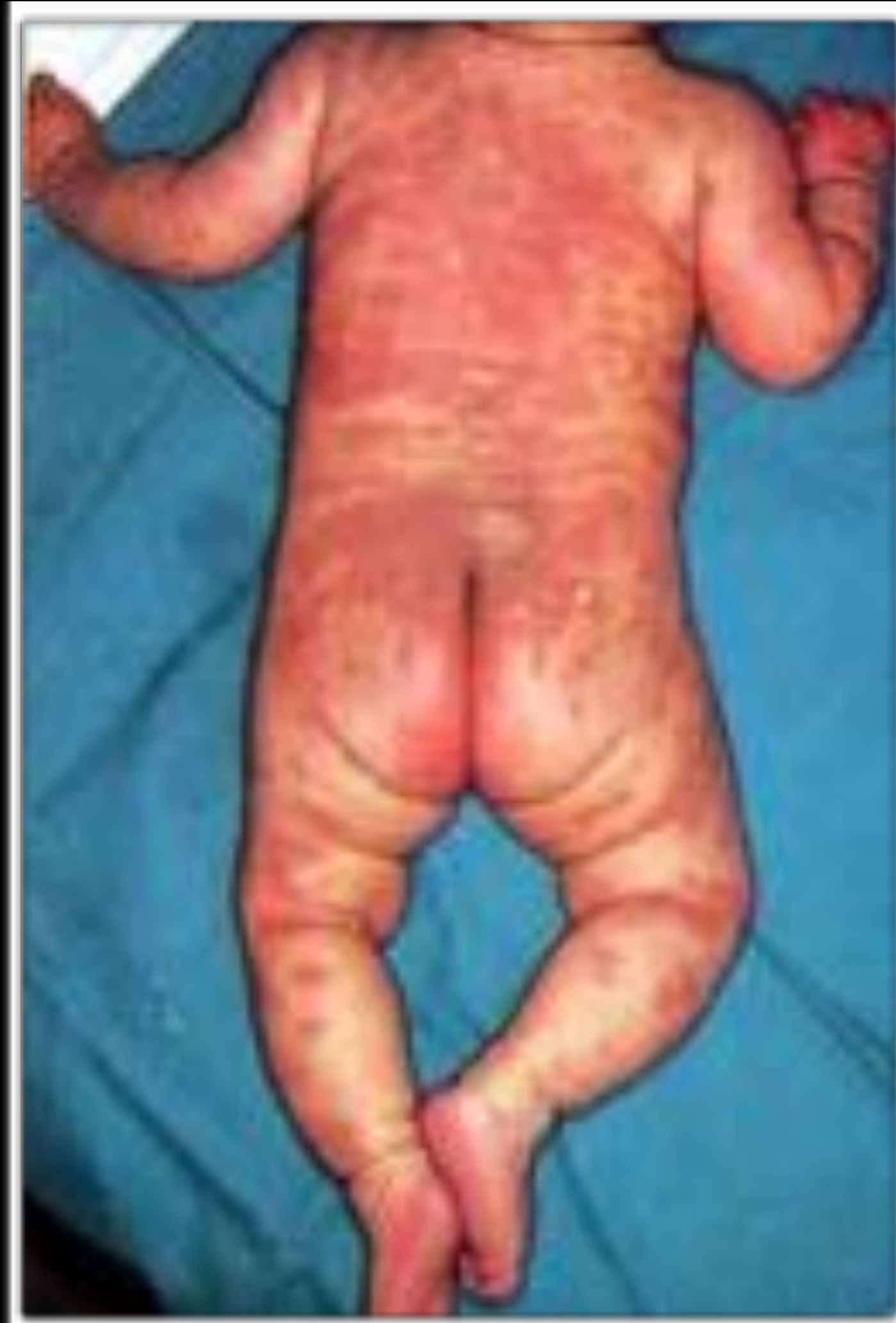Classic KD is diagnosed in the presence of **fever for at least 5 days** (the day of fever onset is taken to be the first day of fever) together **with at least 4 of the 5** following principal clinical features:

1. Erythema and cracking of lips, strawberry tongue, and/or erythema of oral and pharyngeal mucosa
2. Bilateral bulbar conjunctival injection without exudate
3. Rash: maculopapular, diffuse erythroderma, or erythema multiforme-like
4. Erythema and edema of the hands and feet in acute phase and/or periungual desquamation in subacute phase
5. Cervical lymphadenopathy (≥ 1.5 cm diameter), usually unilateral

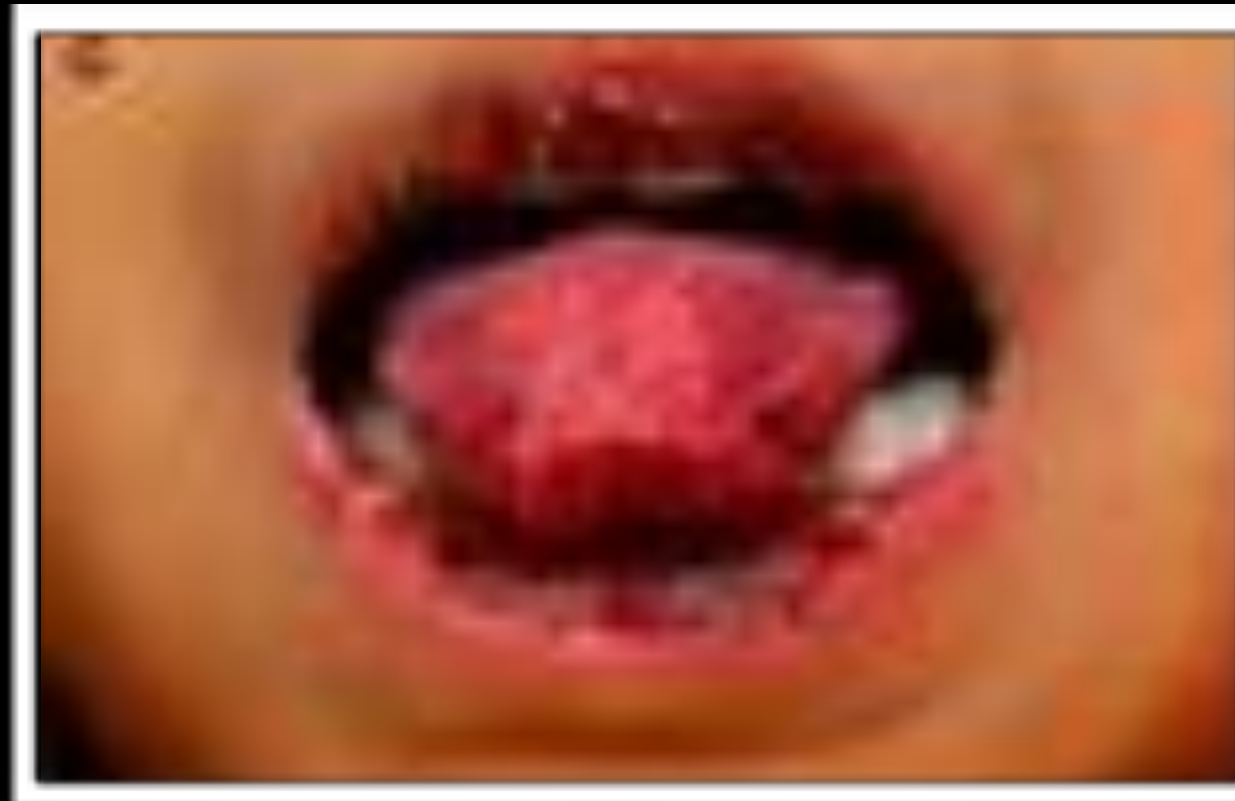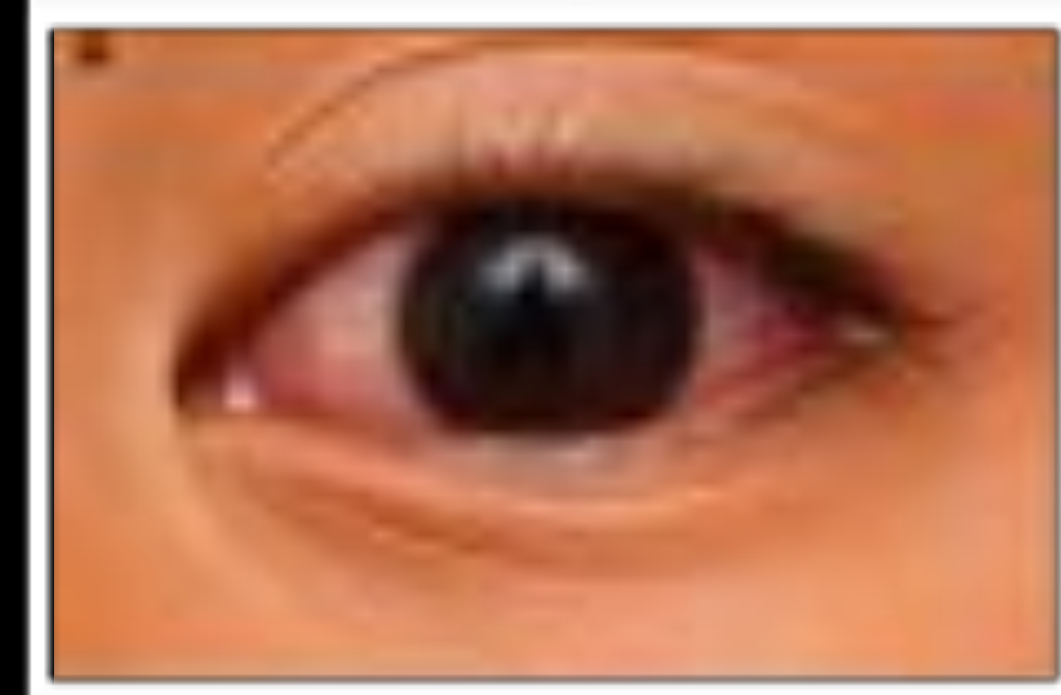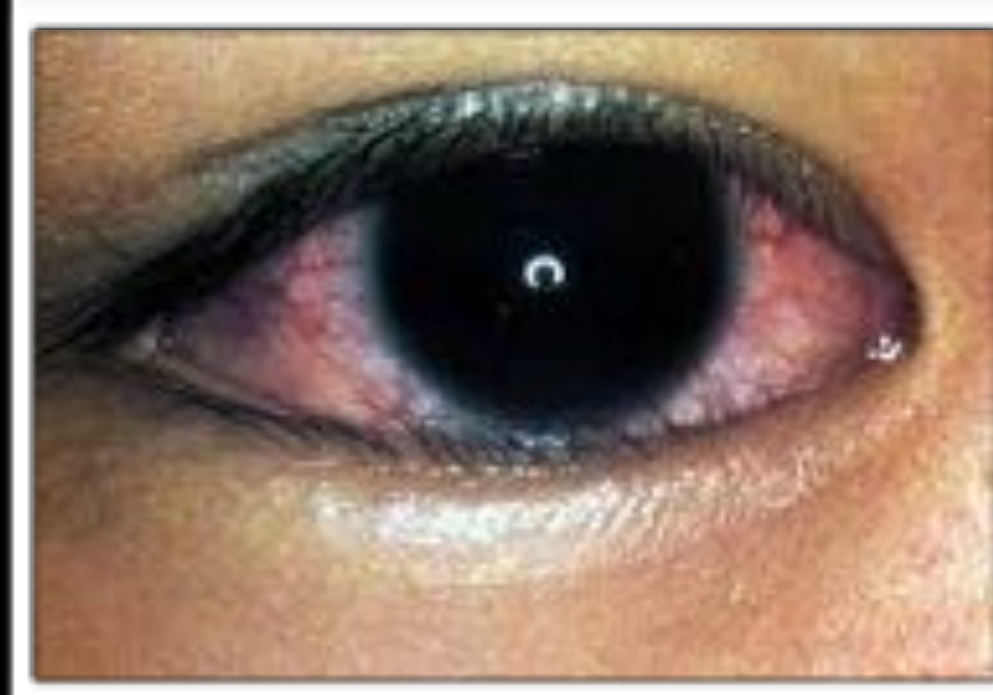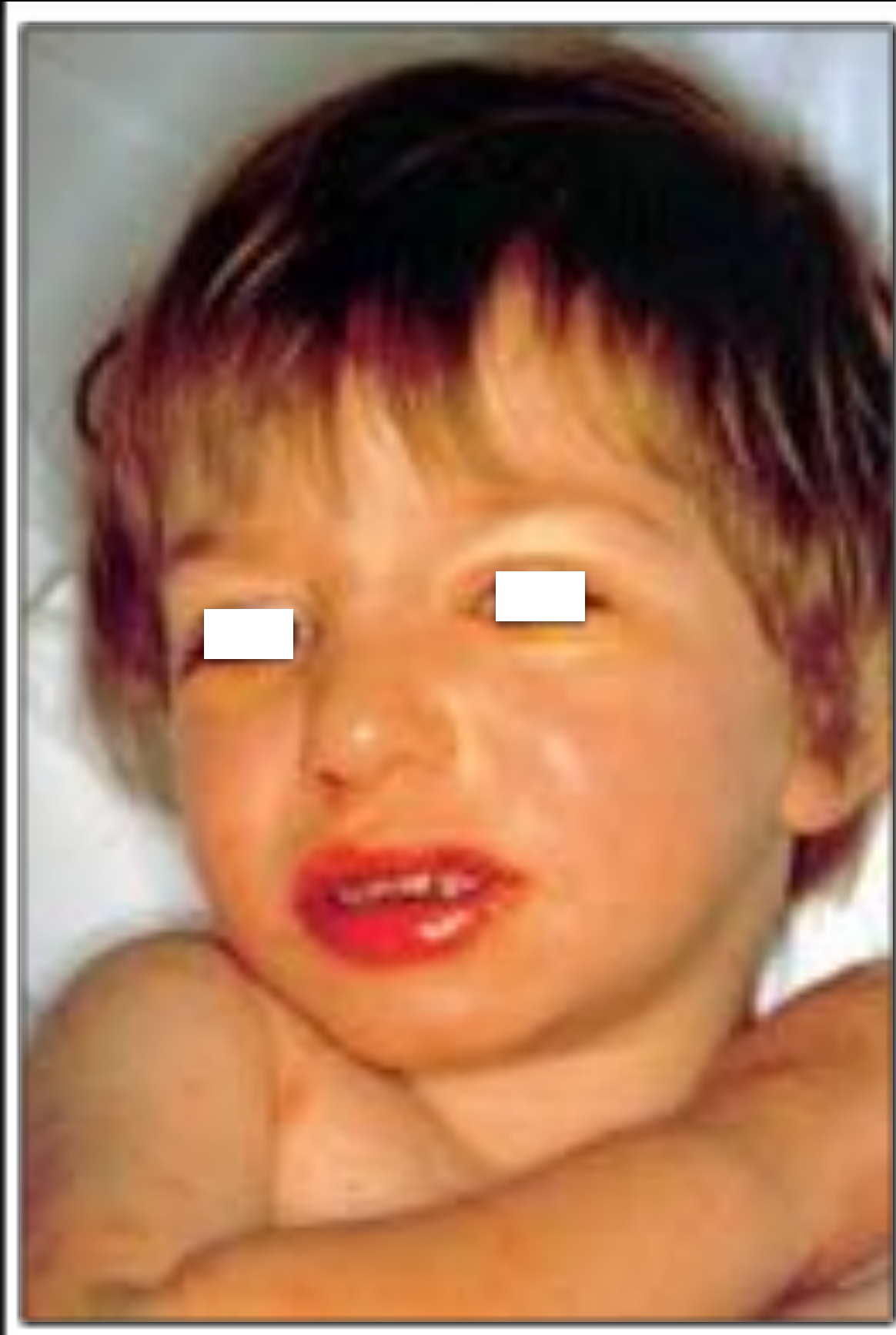Clinical features of classic Kawasaki disease.



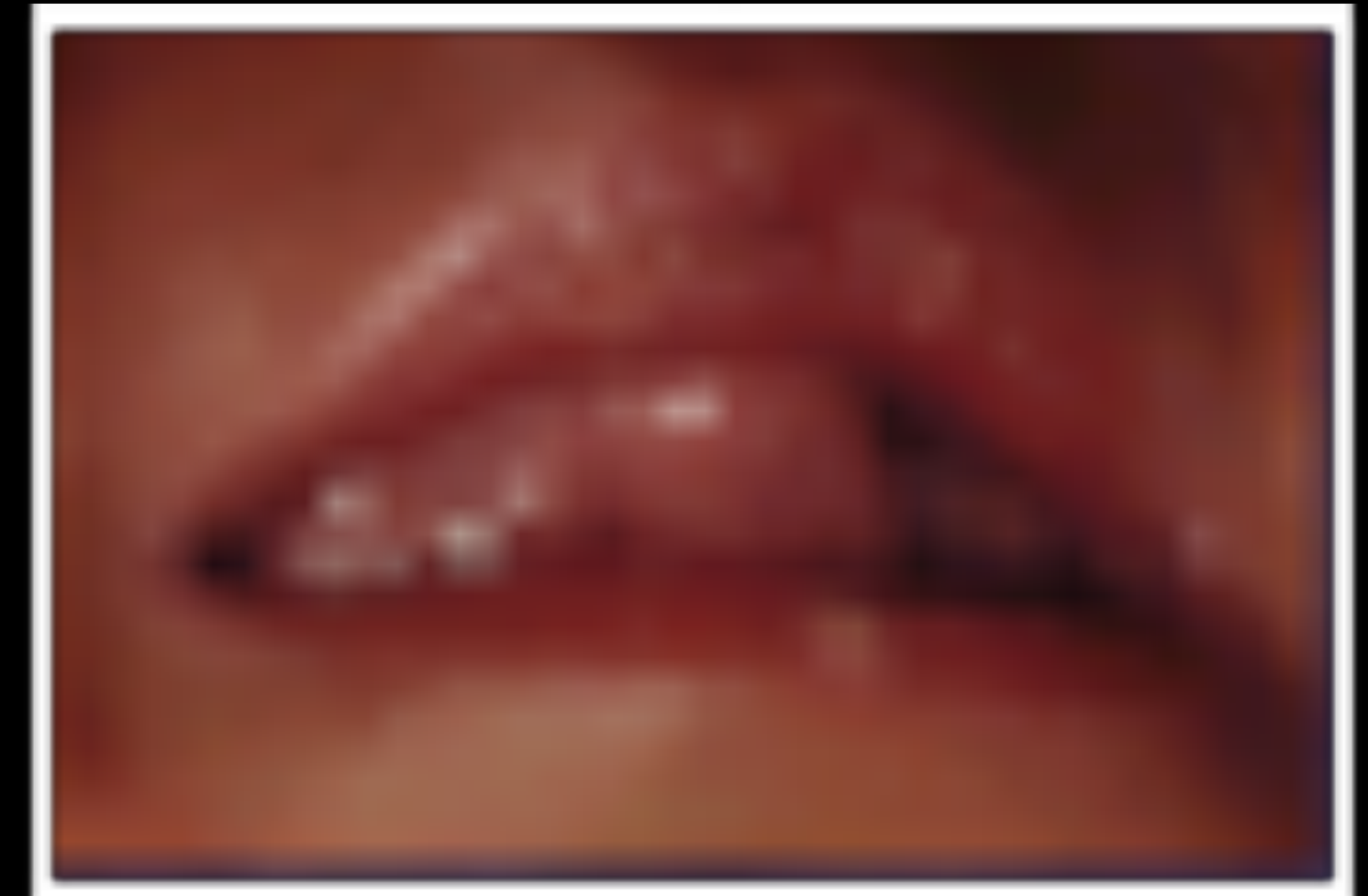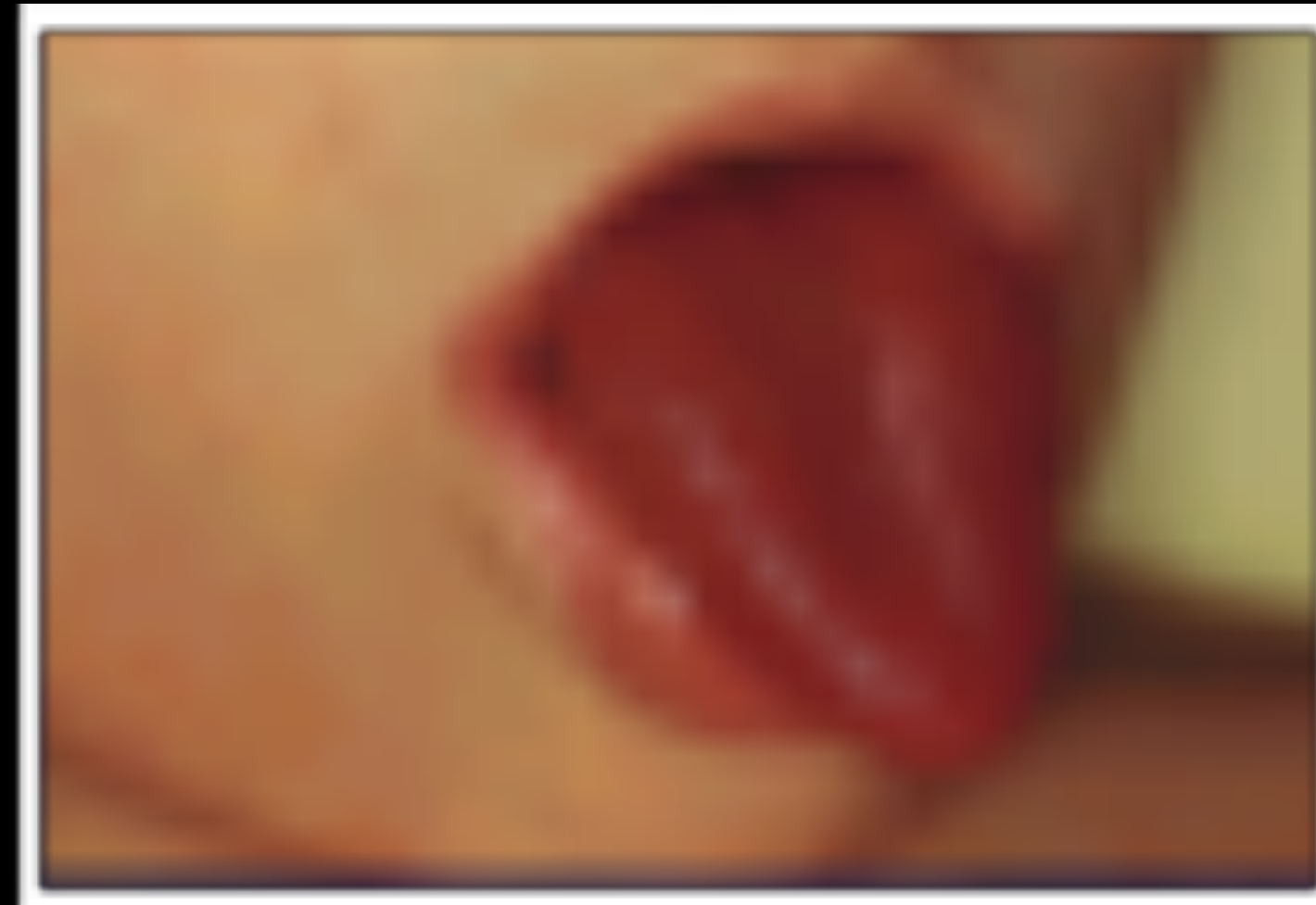
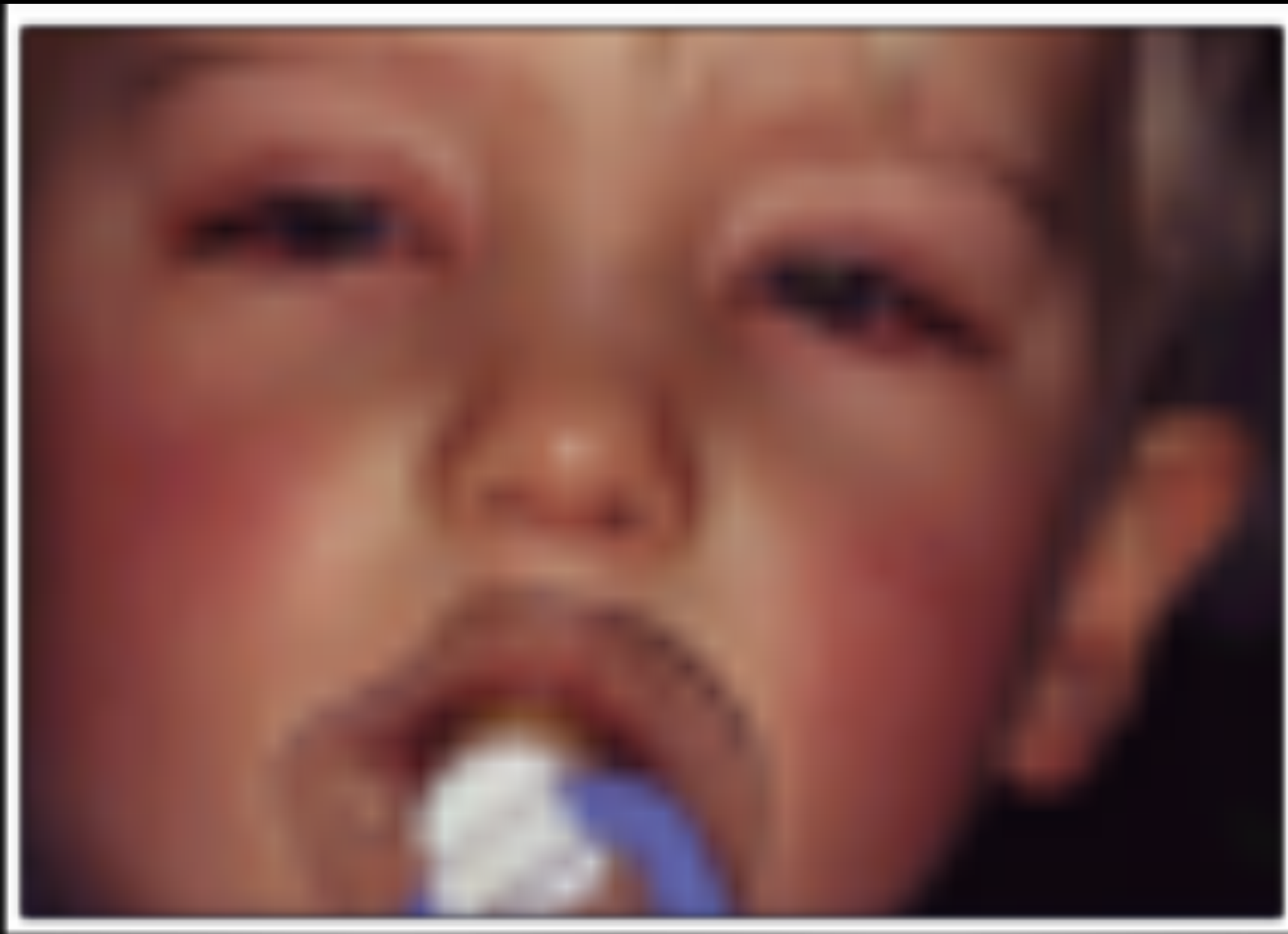Clinical features of classic Kawasaki disease.



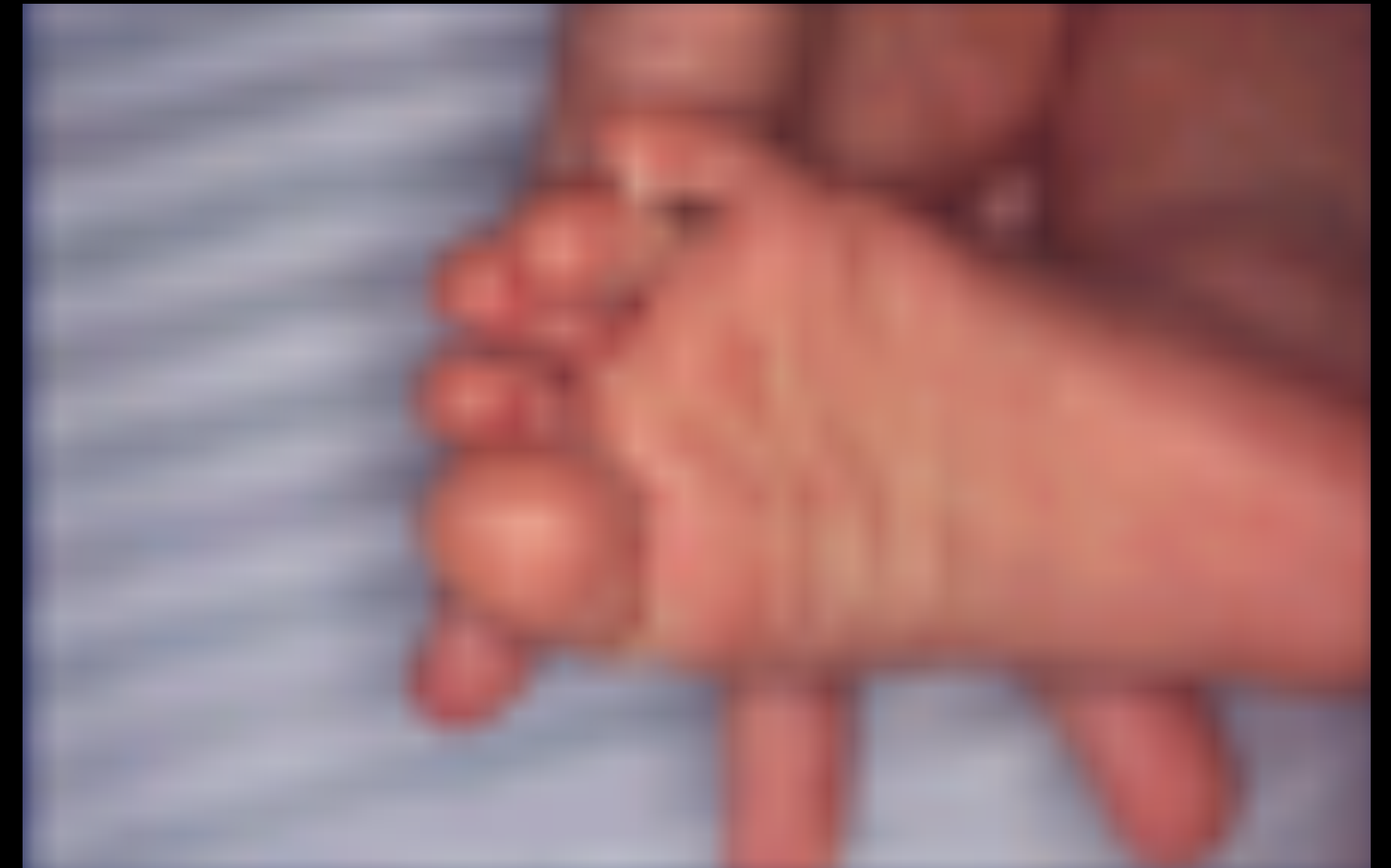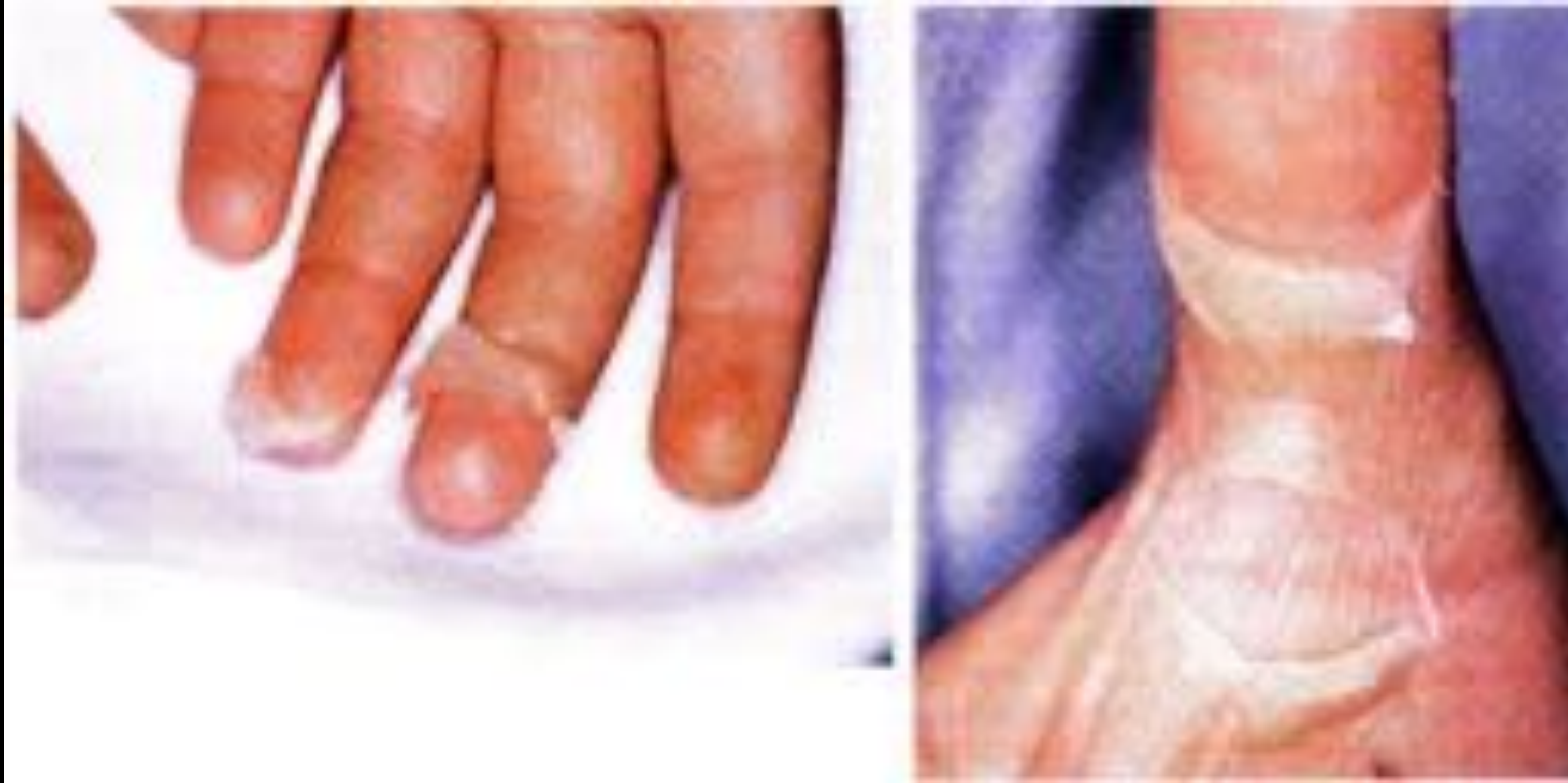Clinical features of classic Kawasaki disease.

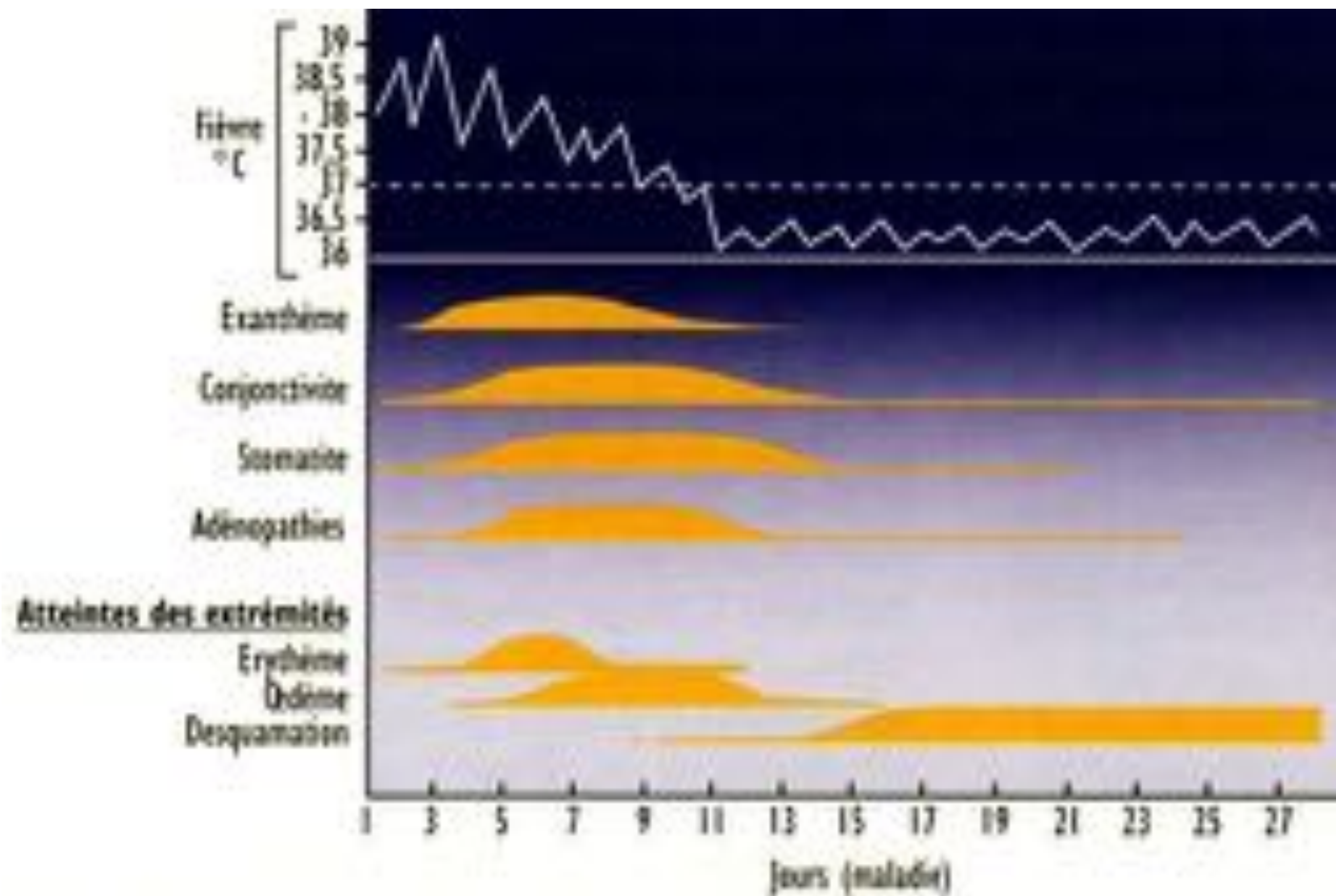


Clinical features of classic Kawasaki disease.

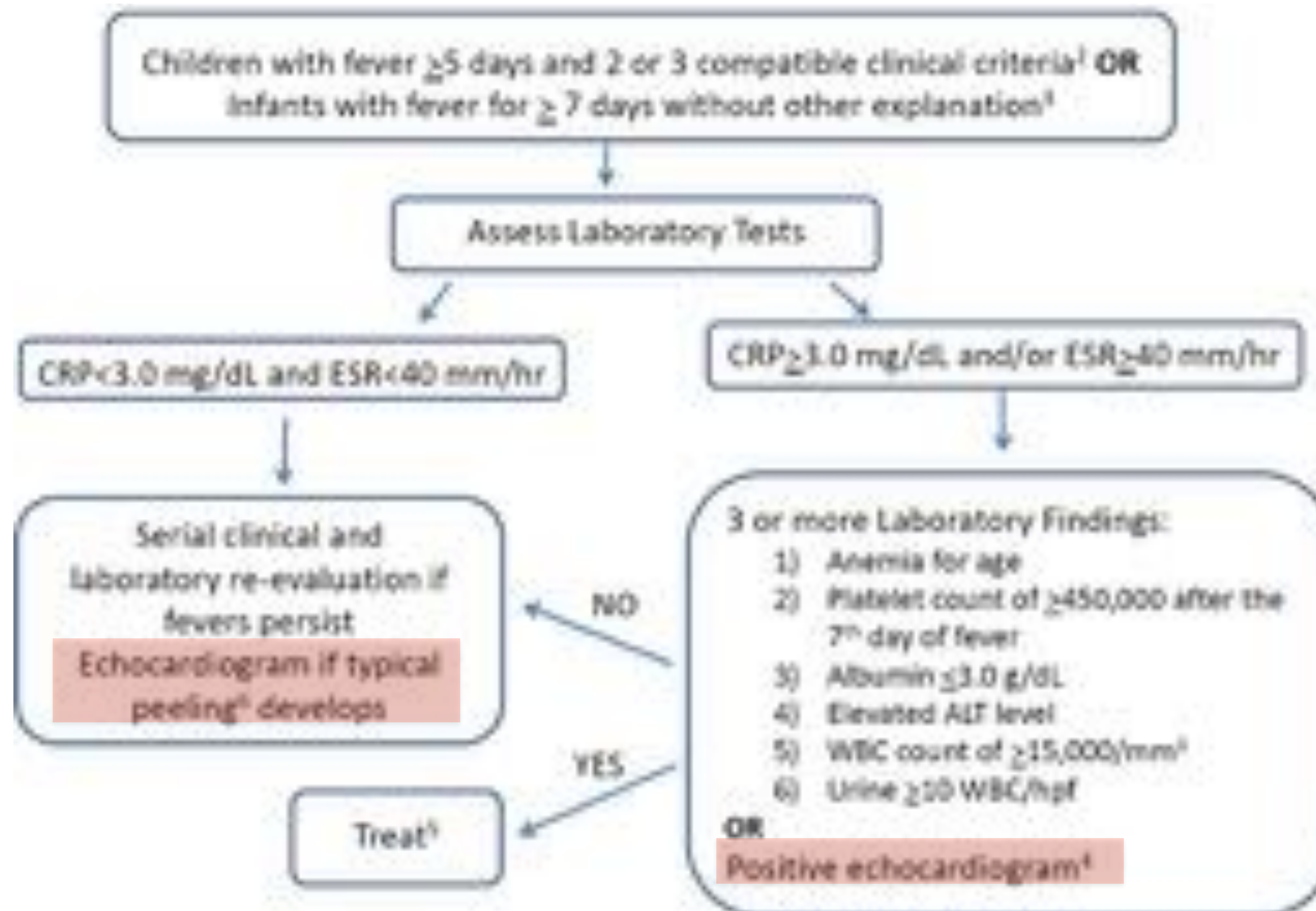


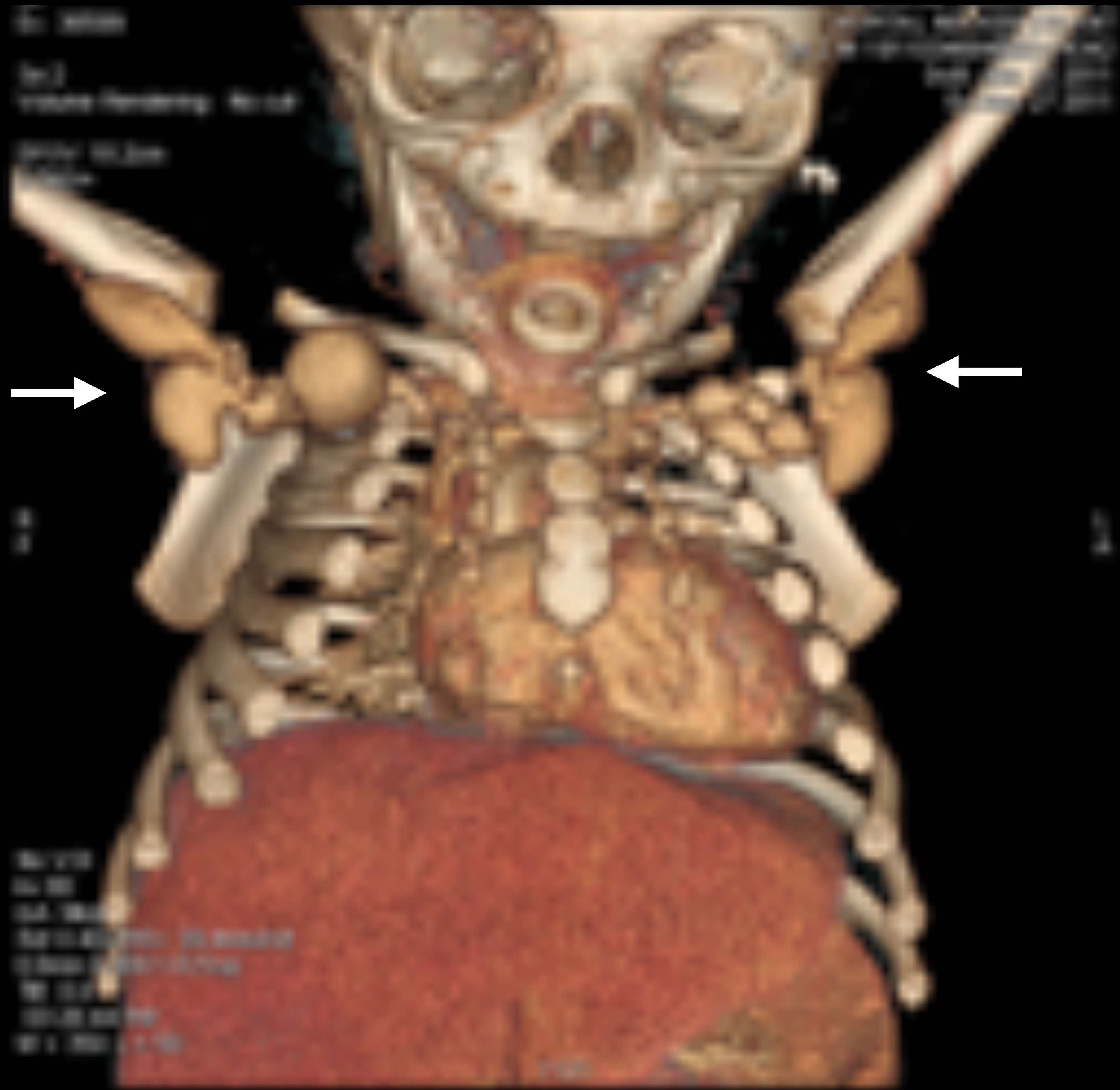
Clinical features of classic Kawasaki disease.



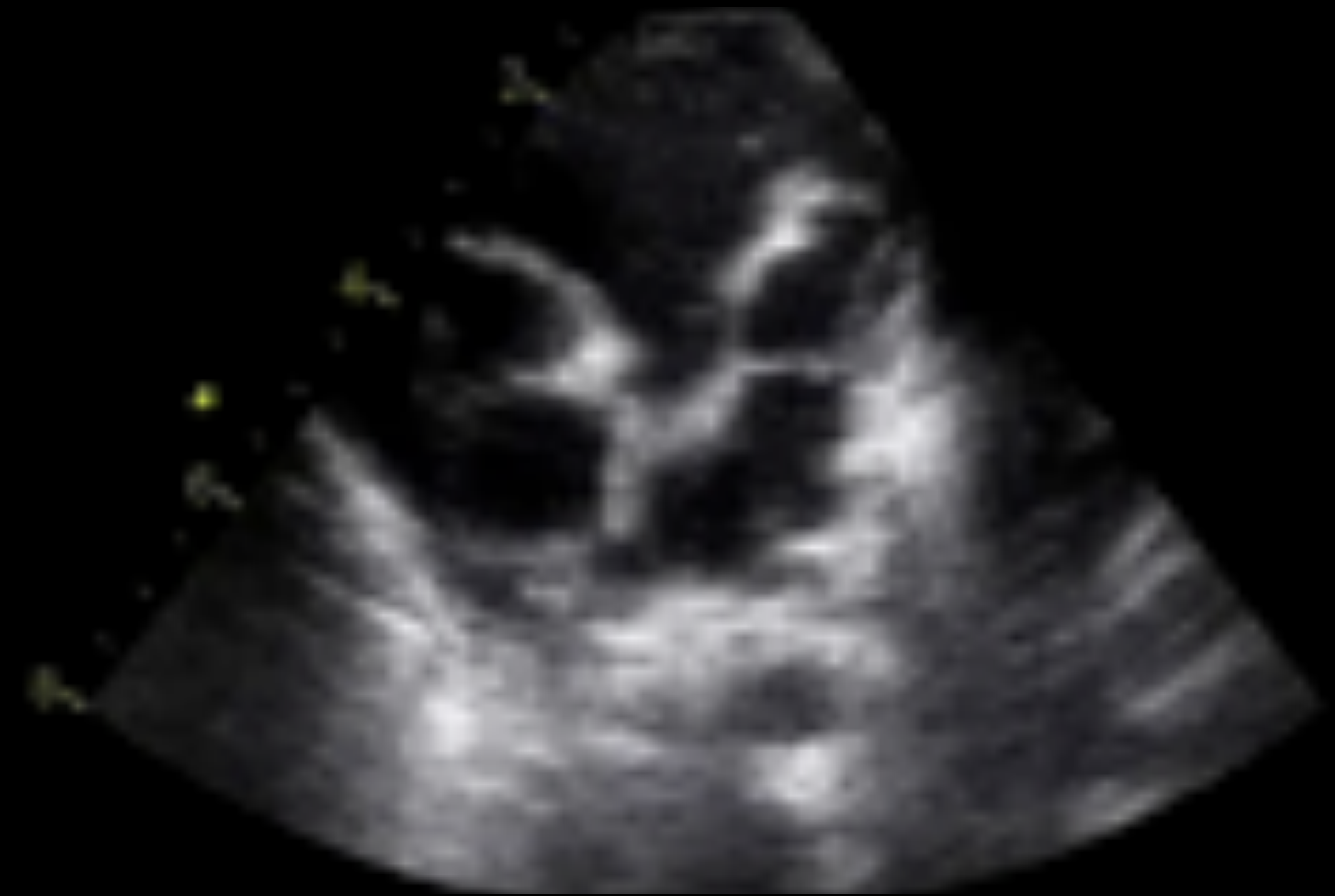
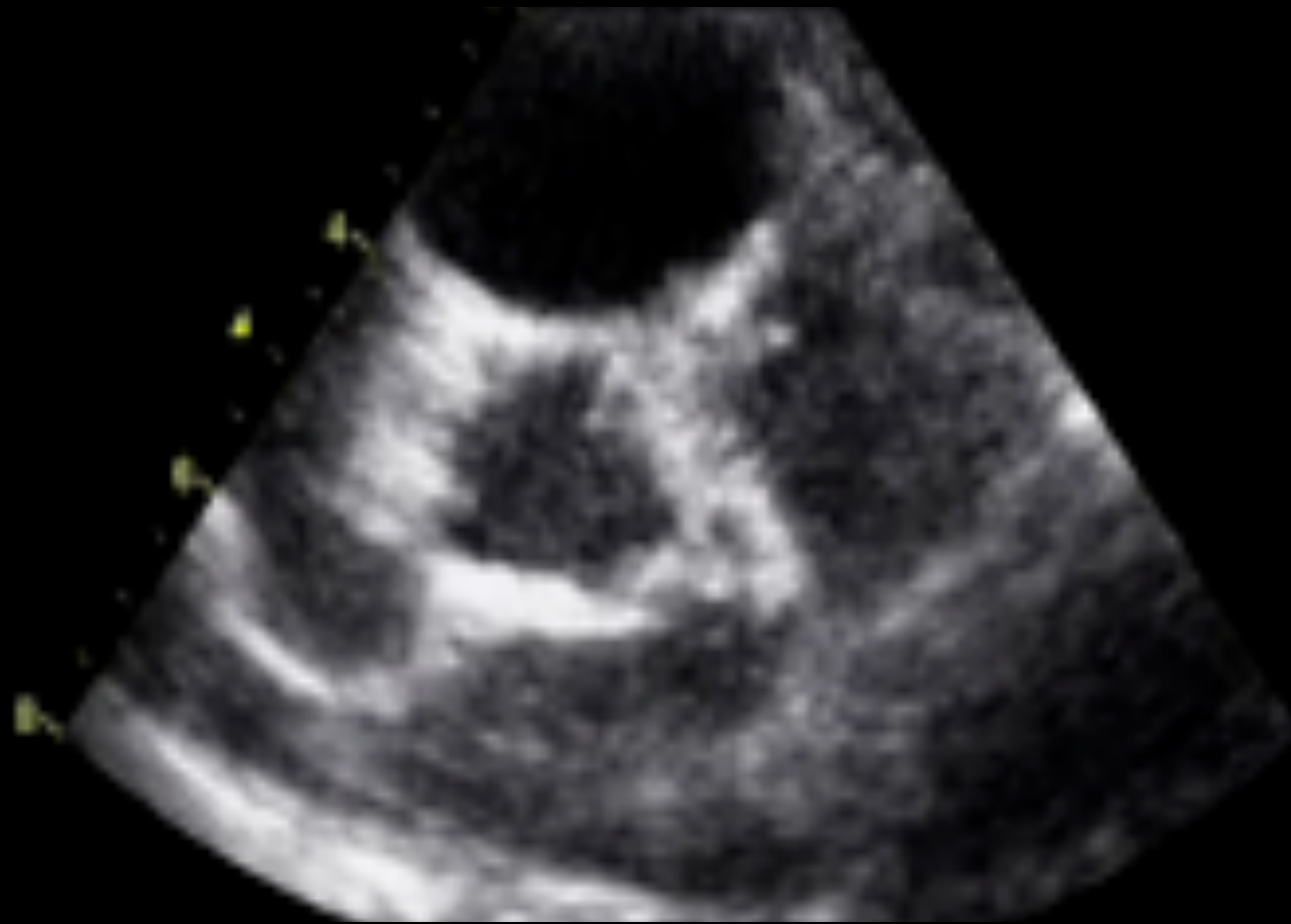
Evaluation of suspected incomplete Kawasaki disease



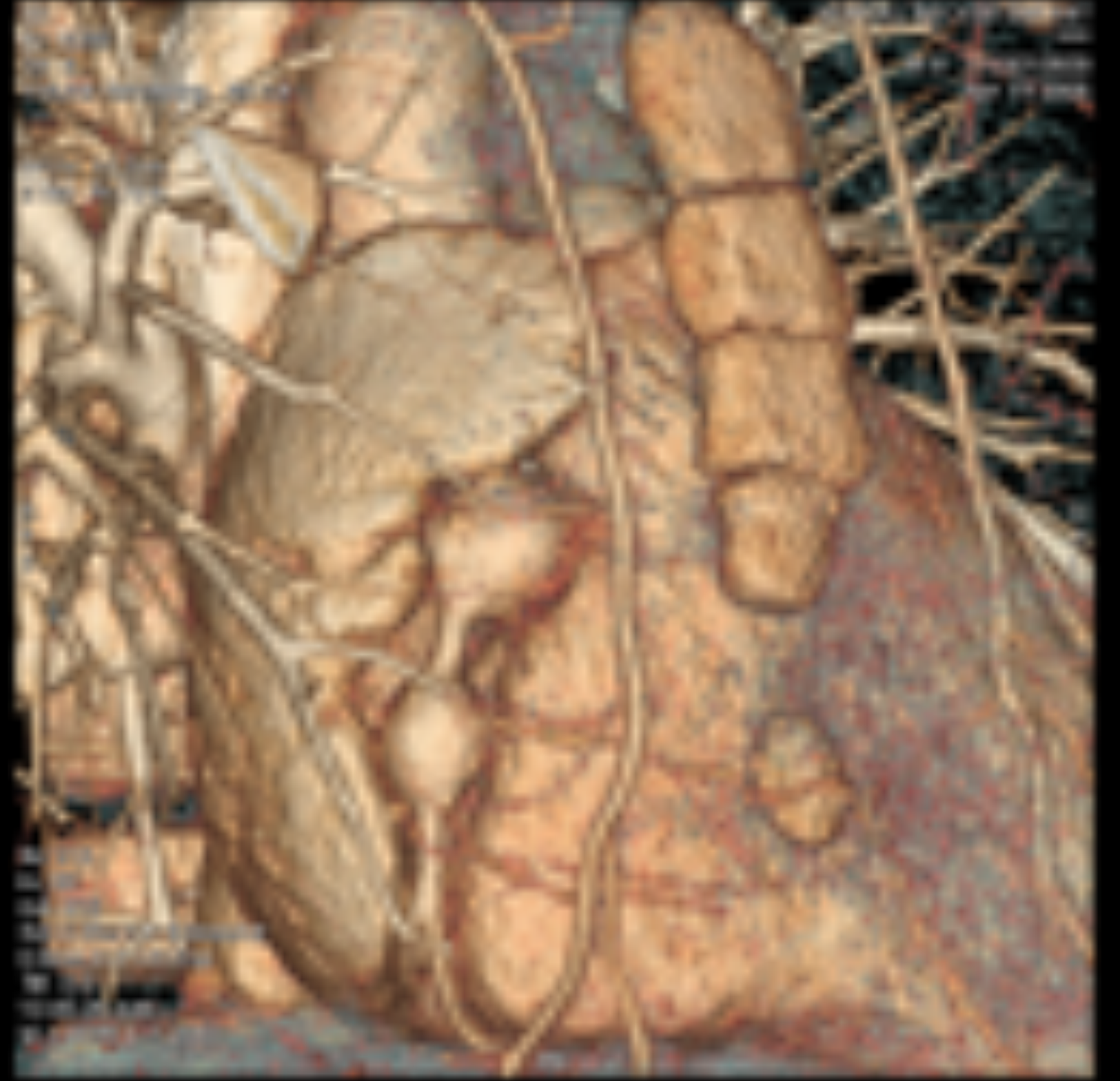


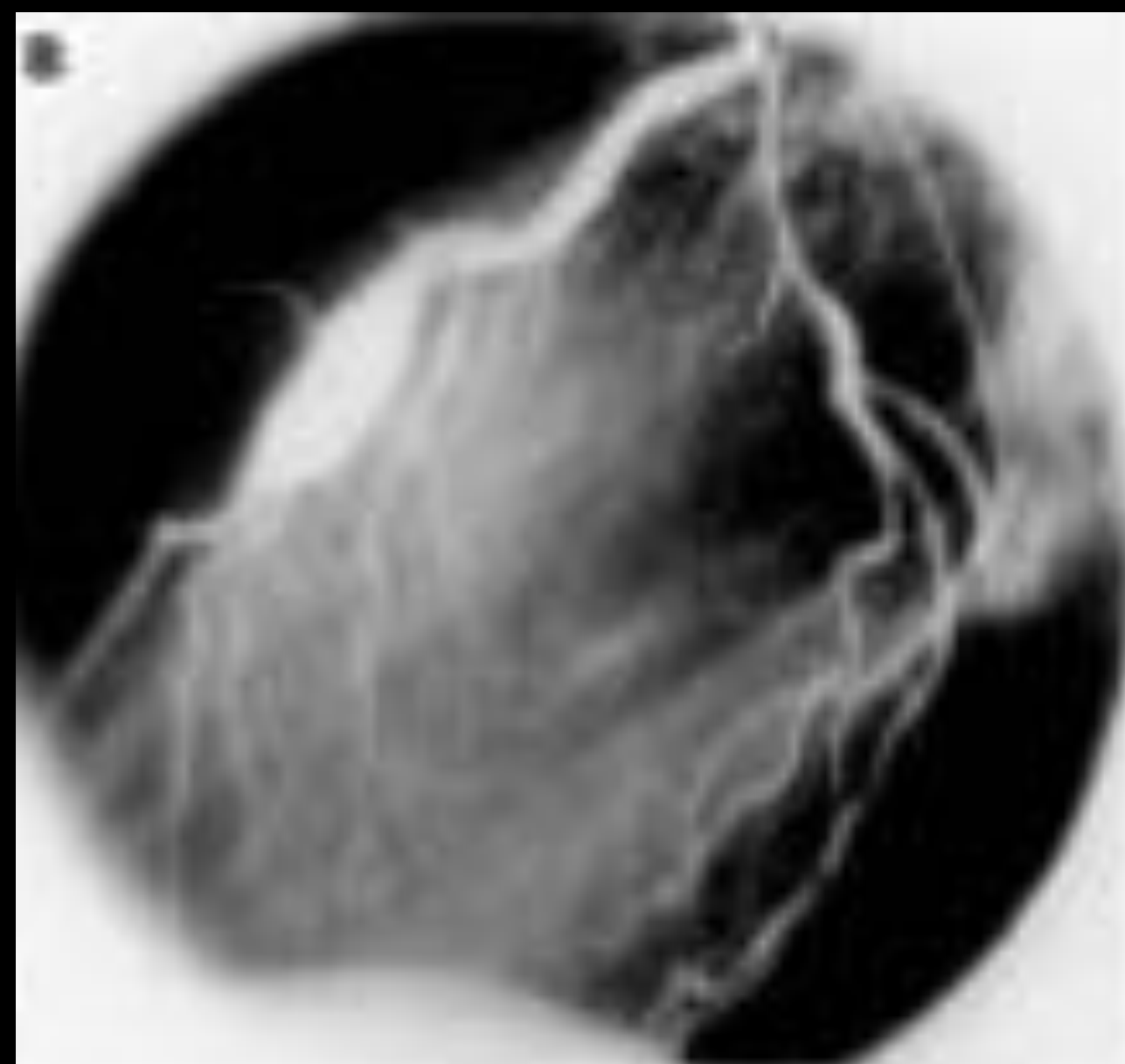
Kawasaki disease, coronary dilatation & aneurysms



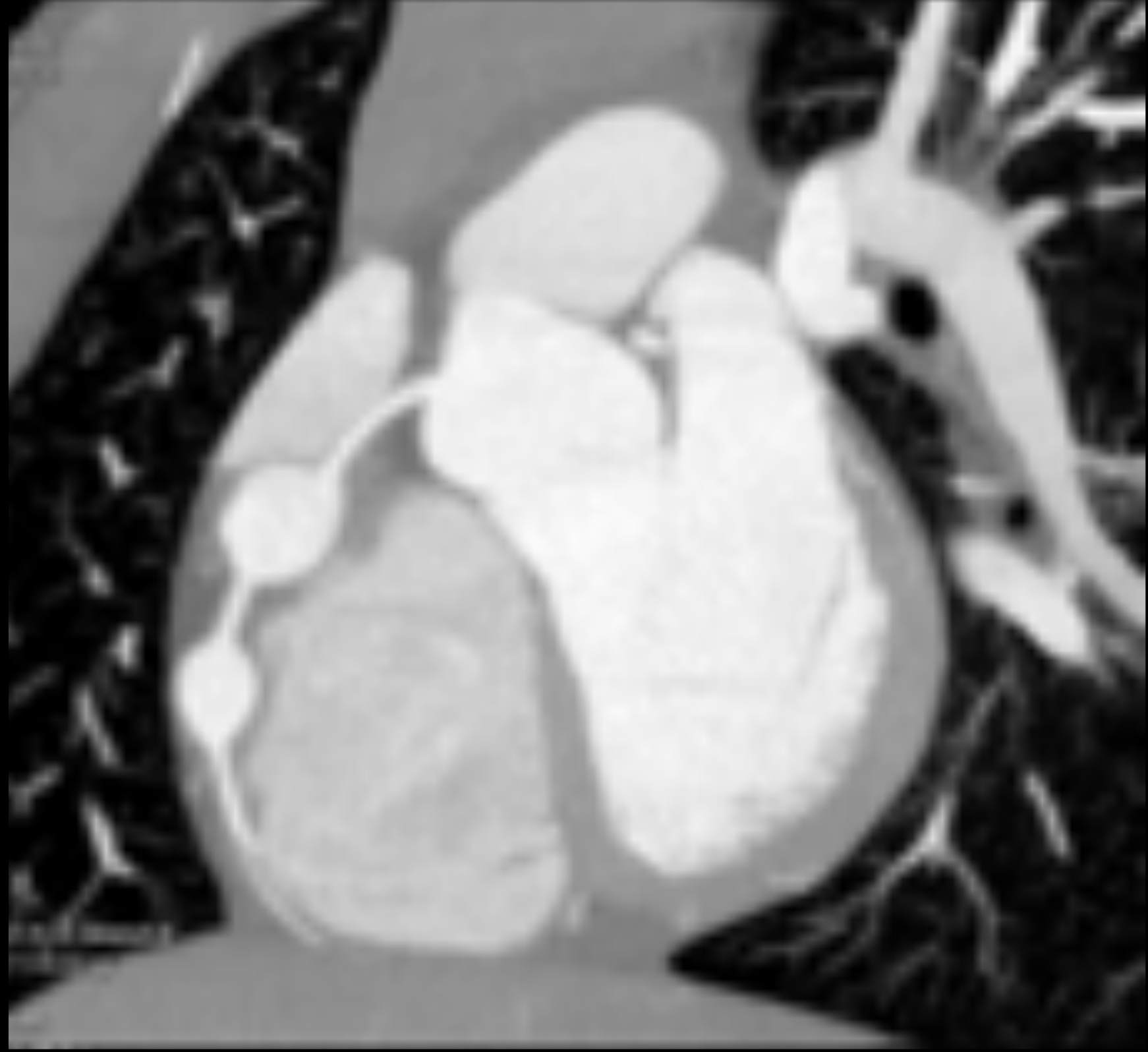

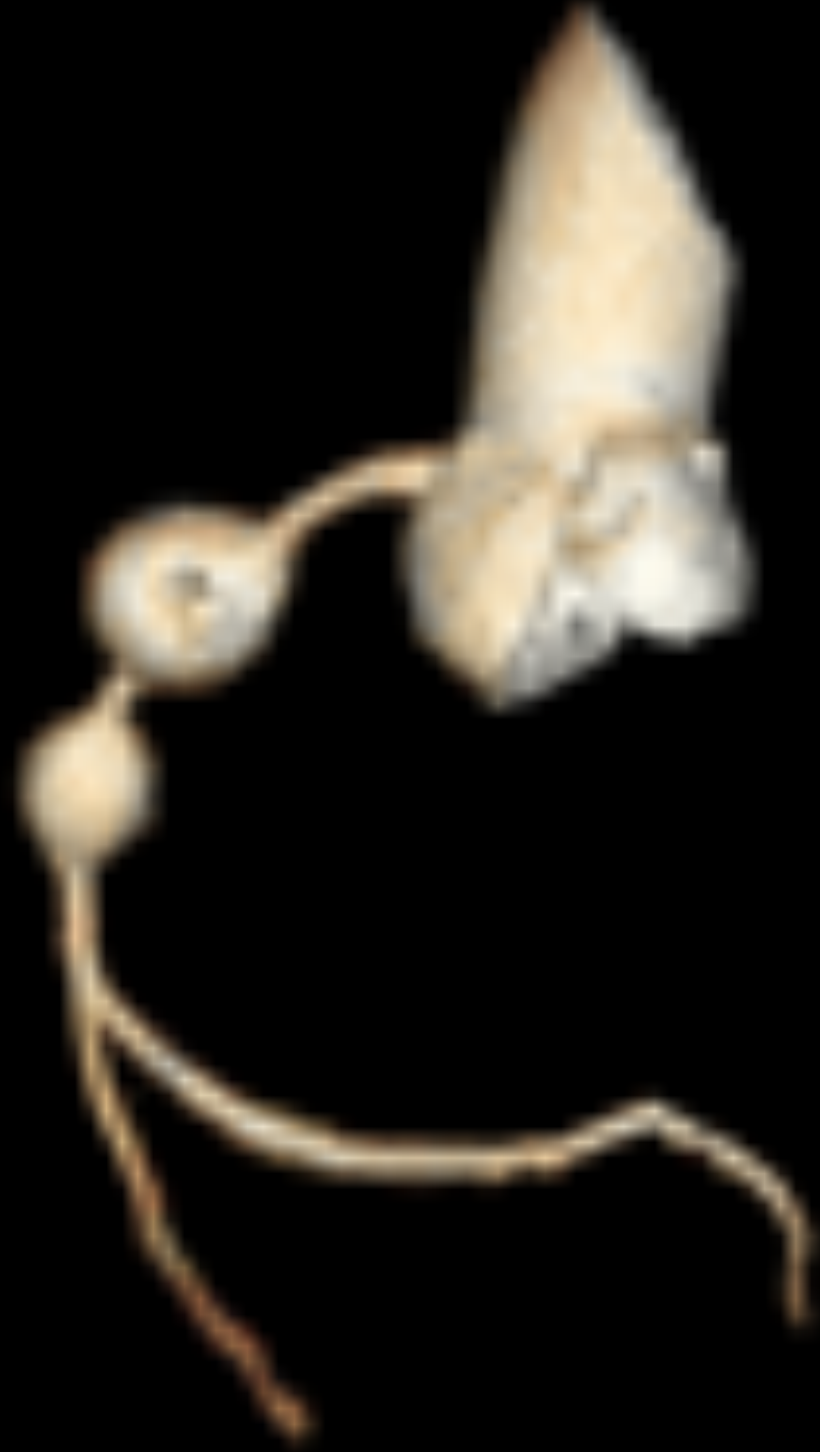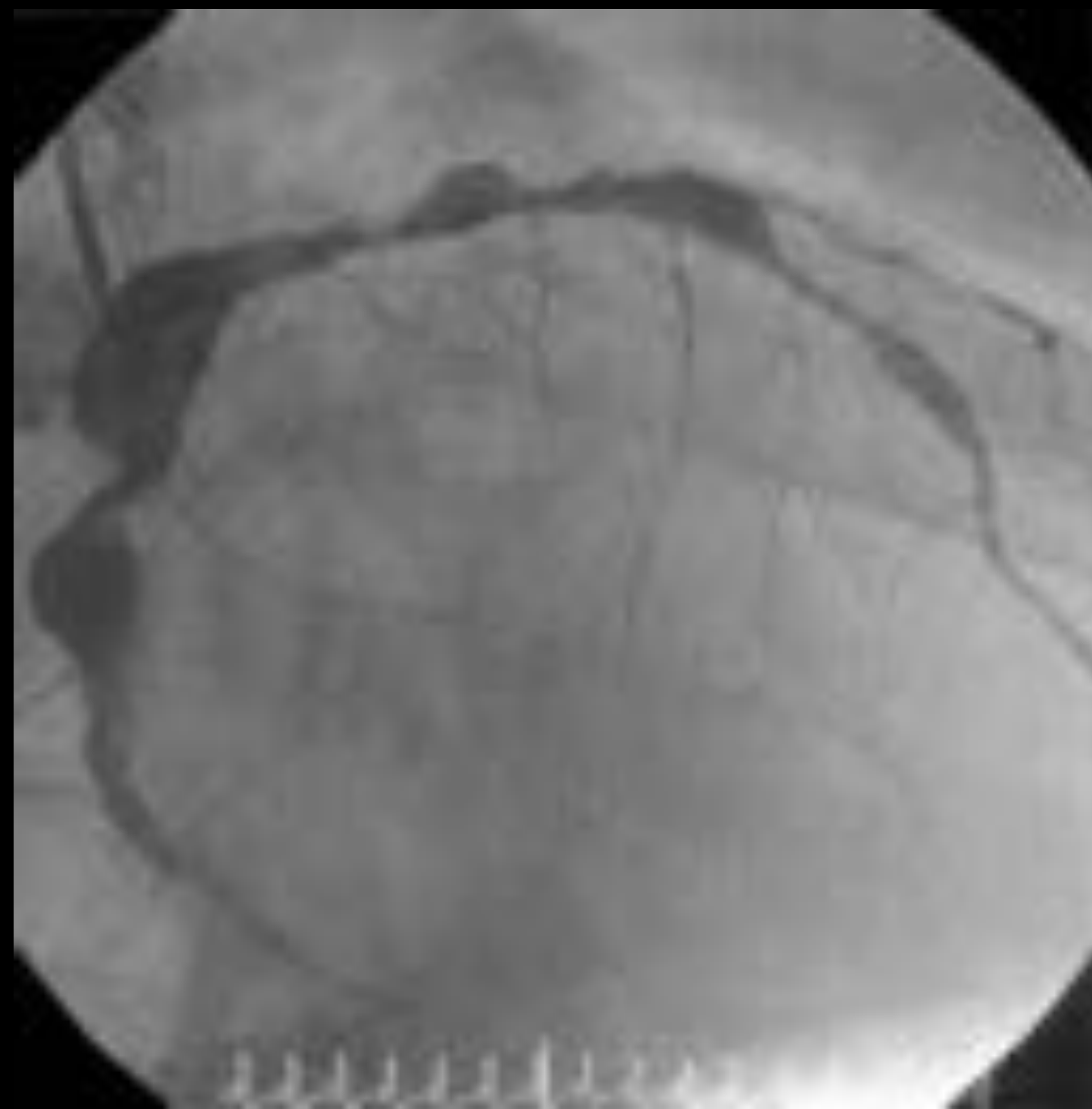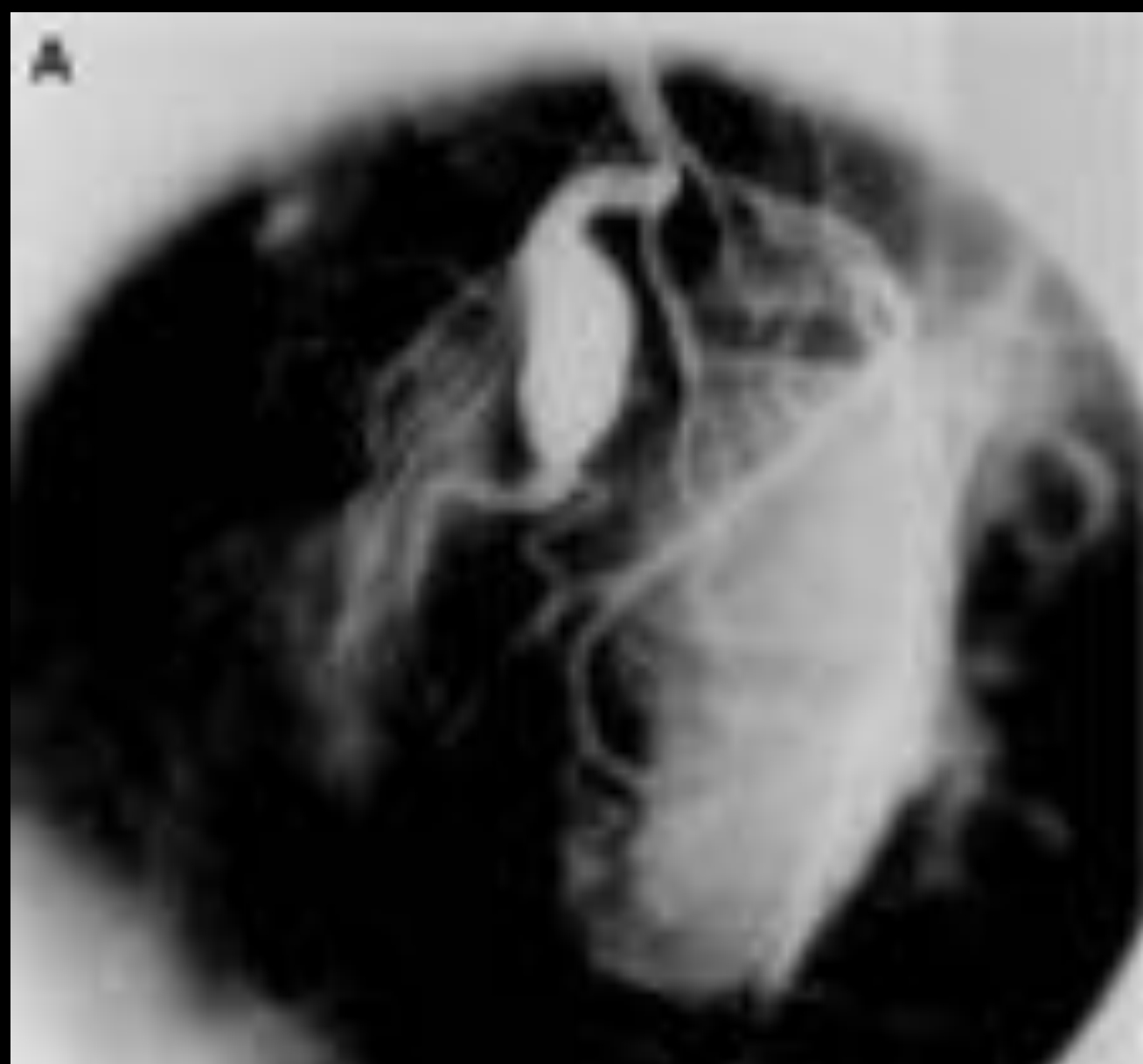Figure 1: A grayscale medical scan, likely a CT or MRI, showing a cross-section of a human torso. The image highlights the internal organs, including the lungs, heart, and major blood vessels. The lungs appear as dark, branching structures, while the heart and vessels are lighter, more solid masses. The overall image is in grayscale, typical of medical imaging.

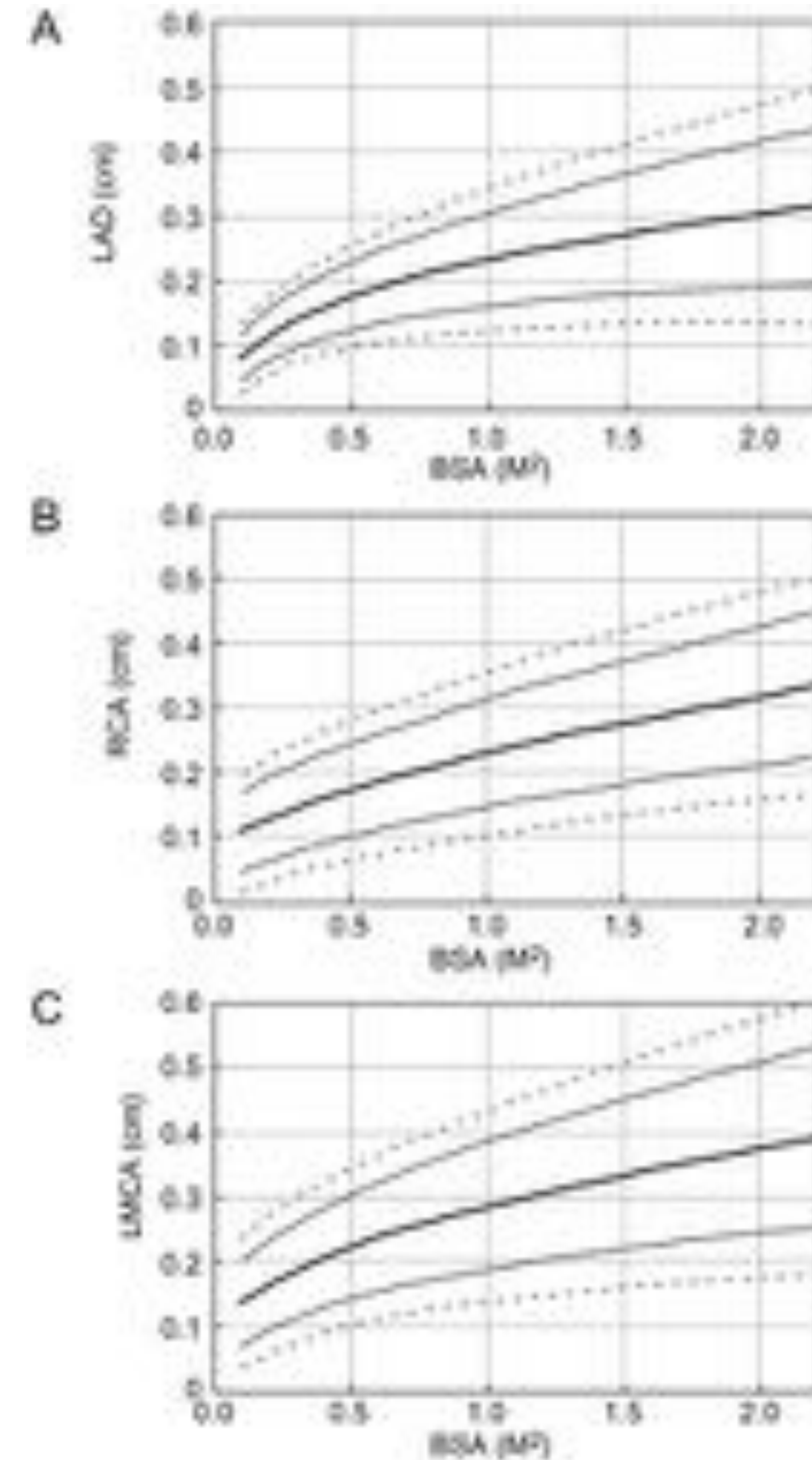




Z-Score Classification in Kawasaki disease

1. No involvement: Always <2
2. Dilation only: 2 to <2.5 ; or if initially <2 , a decrease in Z score during follow-up ≥ 1
3. Small aneurysm: ≥ 2.5 to <5
4. Medium aneurysm: ≥ 5 to <10 , and absolute dimension <8 mm
5. Large or giant aneurysm: ≥ 10 , or absolute dimension ≥ 8 mm

Mean and prediction limits for 2 and 3 SDs for size of (A) LAD, (B) proximal RCA, and (C) LMCA according to body



Recommendations for Cardiovascular Assessment for Diagnosis and Monitoring During the Acute Illness

1. **Echocardiography** should be performed when the diagnosis of KD is considered, but unavailability or technical limitations **should not delay treatment**.
2. Coronary arteries should be imaged, and **quantitative assessment of luminal dimensions**, normalized as Z scores adjusted for body surface, should be performed.
3. **For uncomplicated patients**, echocardiography should be repeated both within 1 to 2 weeks and 4 to 6 weeks after treatment.
4. **For patients with important and evolving coronary artery abnormalities** (Z score > 2.5) detected during the acute illness, more frequent echocardiography (**at least twice per week**) should be performed until luminal dimensions have stopped progressing to determine the risk for and presence of thrombosis.
5. To detect coronary artery thrombosis, it may be reasonable to perform echocardiography for **patients with expanding large or giant aneurysms twice per week while dimensions are expanding rapidly and at least once weekly in the first 45 days of illness, and then monthly until the third month after illness onset**, because the failure to escalate thromboprophylaxis in time with the rapid expansion of aneurysms is a primary cause of morbidity and mortality.

Recommendations for Initial Treatment With IVIG and ASA

1. Patients with complete KD criteria and those who meet the algorithm criteria for incomplete KD should be treated with **high-dose IVIG (2 g/kg given as a single intravenous infusion) within 10 days of illness onset** but as soon as possible after diagnosis.
2. It is reasonable to administer IVIG to children presenting **after the 10th day** of illness (ie, in whom the diagnosis was missed earlier) if they have either **persistent fever** without other explanation **or coronary artery abnormalities together with ongoing systemic inflammation**, as manifested by elevation of ESR or CRP (CRP > 3.0 mg/dL).
3. **Administration** of moderate- (30–50 mg/kg/d) to high-dose (80–100 mg/kg/d) **ASA** is reasonable **until the patient is afebrile**, although there is no evidence that it reduces coronary artery aneurysms.
4. **IVIG** generally should **not** be administered to patients **beyond the tenth day of illness in the absence of fever, significant elevation of inflammatory markers, or coronary artery abnormalities**.
5. The **ESR** is accelerated by IVIG therapy and therefore **should not be used to assess response to IVIG therapy**. A persistently high ESR alone should not be interpreted as a sign of IVIG resistance.

Recommendations for Adjunctive Therapies for Primary Treatment

1. Single-dose pulse **methylprednisolone** should not be administered with IVIG as routine primary therapy for patients with KD.
2. Administration of a longer course of corticosteroids (eg, tapering over 2–3 weeks), together with IVIG 2 g/kg and ASA, may be considered for treatment of high-risk patients with acute KD, when such high risk can be identified in patients before initiation of treatment

Recommendations for Adjunctive Therapies for Primary Treatment

1. It is reasonable to administer **a second dose of IVIG (2 g/kg)** to patients with persistent or recrudescent fever at **least 36 hours after the end of the first IVIG infusion** .
2. Administration of **high-dose pulse steroids usually methylprednisolone** 20–30 mg/kg intravenously for 3 days, with or without a subsequent course and taper of oral prednisone) **may be considered as an alternative to a second infusion of IVIG** or for retreatment of patients with KD who have had recurrent or recrudescent fever after additional IVIG .
3. Administration of a longer (eg, 2–3 weeks) tapering course of prednisolone or prednisone, together with IVIG 2 g/kg and ASA, may be considered in the retreatment of patients with KD who have had recurrent or recrudescent fever after initial IVIG treatment.
4. Administration of **infliximab** (5 mg/kg) **may be considered as an alternative to a second infusion of IVIG or corticosteroids for IVIG-resistant patients**.
5. Administration of **cyclosporine** may be considered **in patients with refractory KD** in whom a second IVIG infusion, infliximab, or a course of steroids has failed.
6. Administration of **immunomodulatory monoclonal antibody therapy** (except TNF- α blockers), cytotoxic agents, or (rarely) plasma exchange may be considered **in highly refractory patients** who have failed to respond to a second infusion of IVIG, an extended course of steroids, or infliximab.

Recommendations for Prevention of Thrombosis

During the Acute Illness

1. **Low-dose ASA** (3–5 mg/kg/d) should be administered to patients without evidence of coronary artery changes **until 4 to 6 weeks after onset of illness.**
2. For patients with **rapidly expanding coronary artery aneurysms or a maximum Z score of ≥ 10 , systemic anticoagulation** with LMWH or warfarin (international normalized ratio target 2.0–3.0) in addition to low-dose ASA is reasonable.
3. For patients at increased risk of thrombosis, for example, with large or giant aneurysms (≥ 8 mm or Z score ≥ 10) and a recent history of coronary artery thrombosis, “triple therapy” with ASA, a second antiplatelet agent, and anticoagulation with warfarin or LMWH may be considered.
4. Ibuprofen and other nonsteroidal antiinflammatory drugs with known or potential involvement of cyclooxygenase pathway may be harmful in patients taking ASA for its antiplatelet effects.

Acquired coronary anomalies

Kawasaki disease

Post-operative coronary obstructions

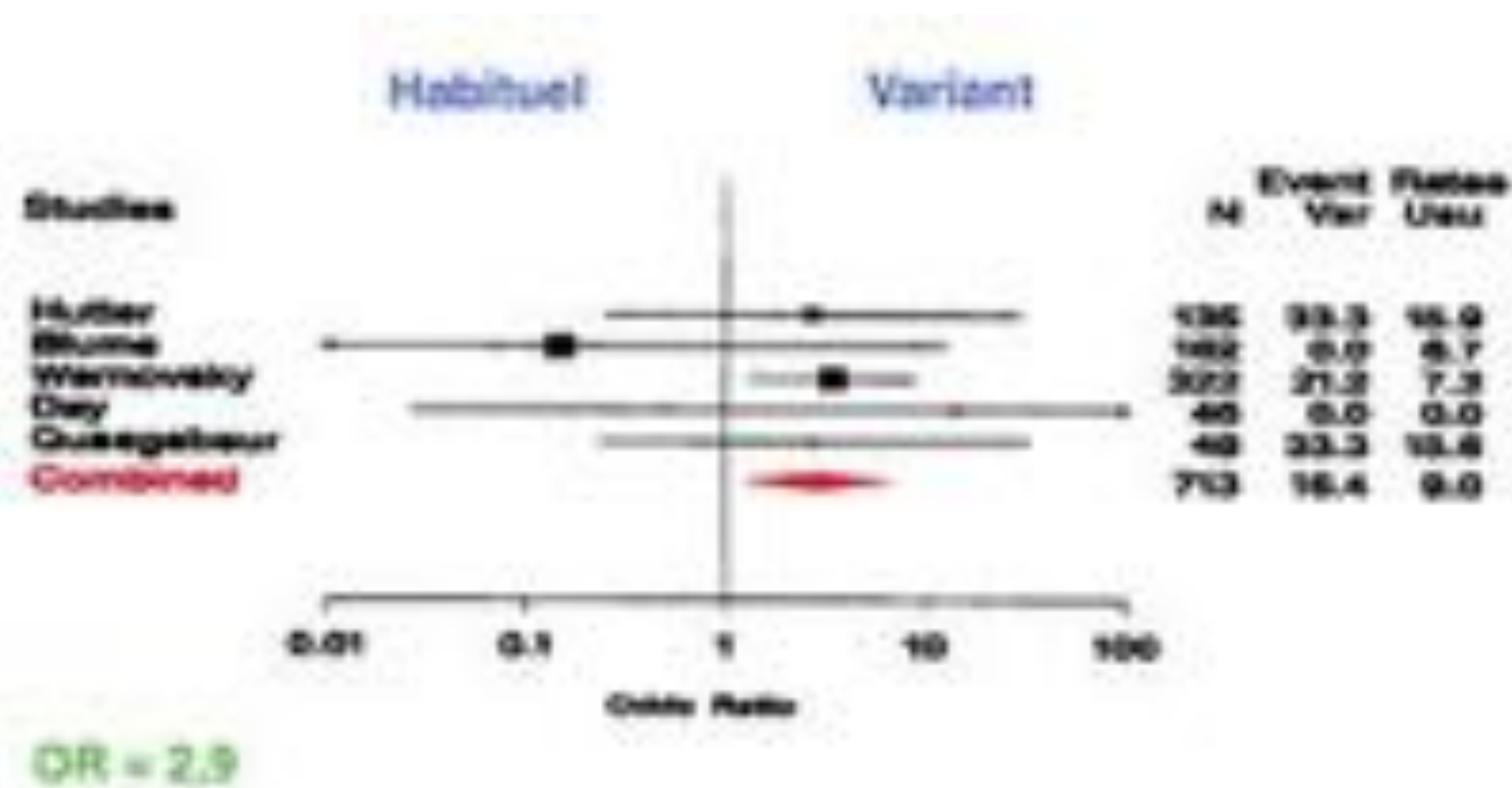
Aims of coronary artery evaluation in TGA

- Before arterial switch operation
 - No interest (except for the choice of the surgeon)
- CA status after arterial switch operation
 - Early postoperative control after CA transfer
 - In cases of difficult transfer : intramural course
 - Post-operative myocardial ischemia
 - Midterm control
 - Prevalence of CA obstruction = 5 to 7%
(Legendre et al. Circulation 2003;108 suppl1:II186-90)
 - Can be found in asymptomatic children

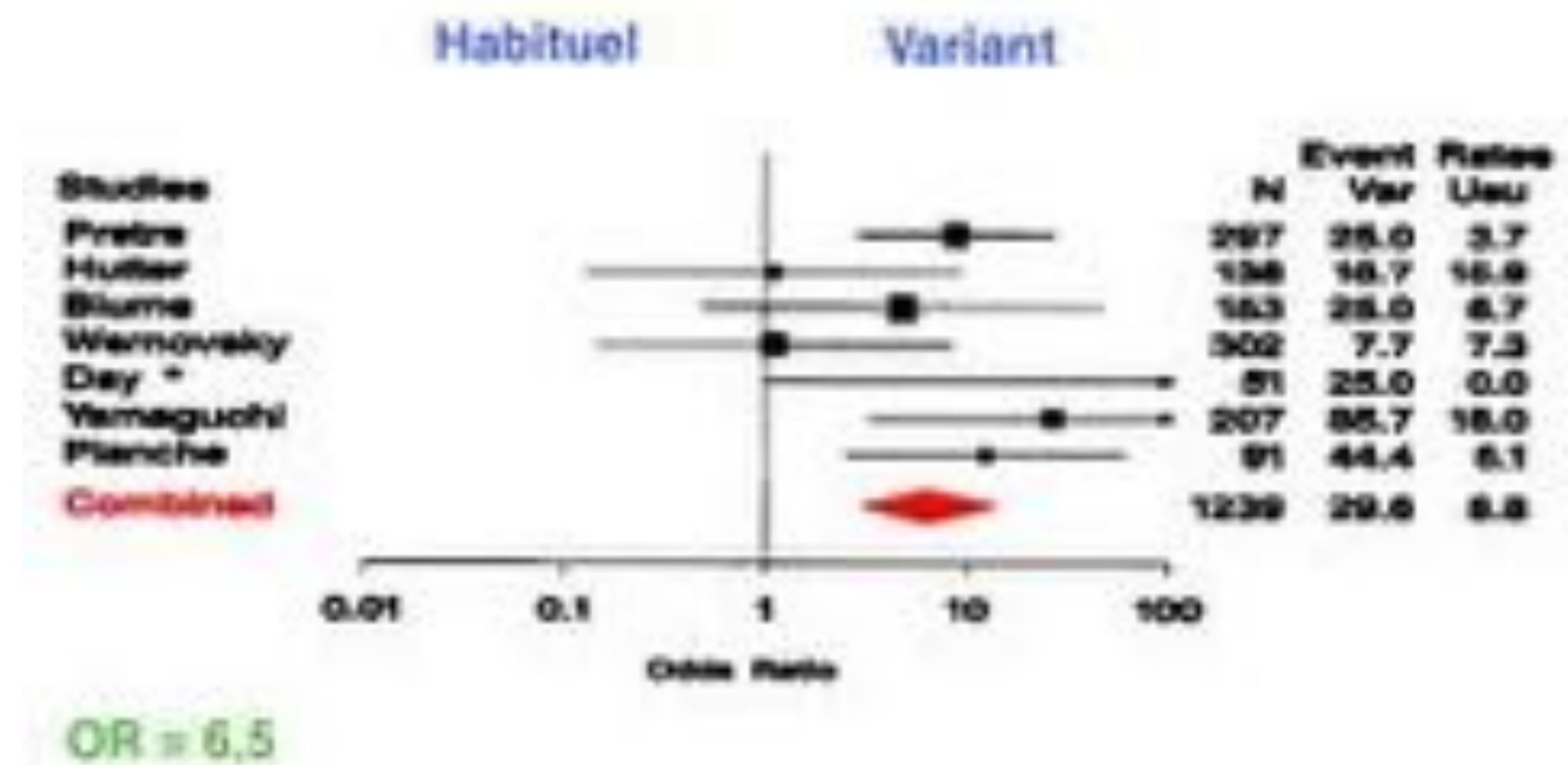
Coronary artery distribution and mortality after ASO

Pasquali, 2002

Type B

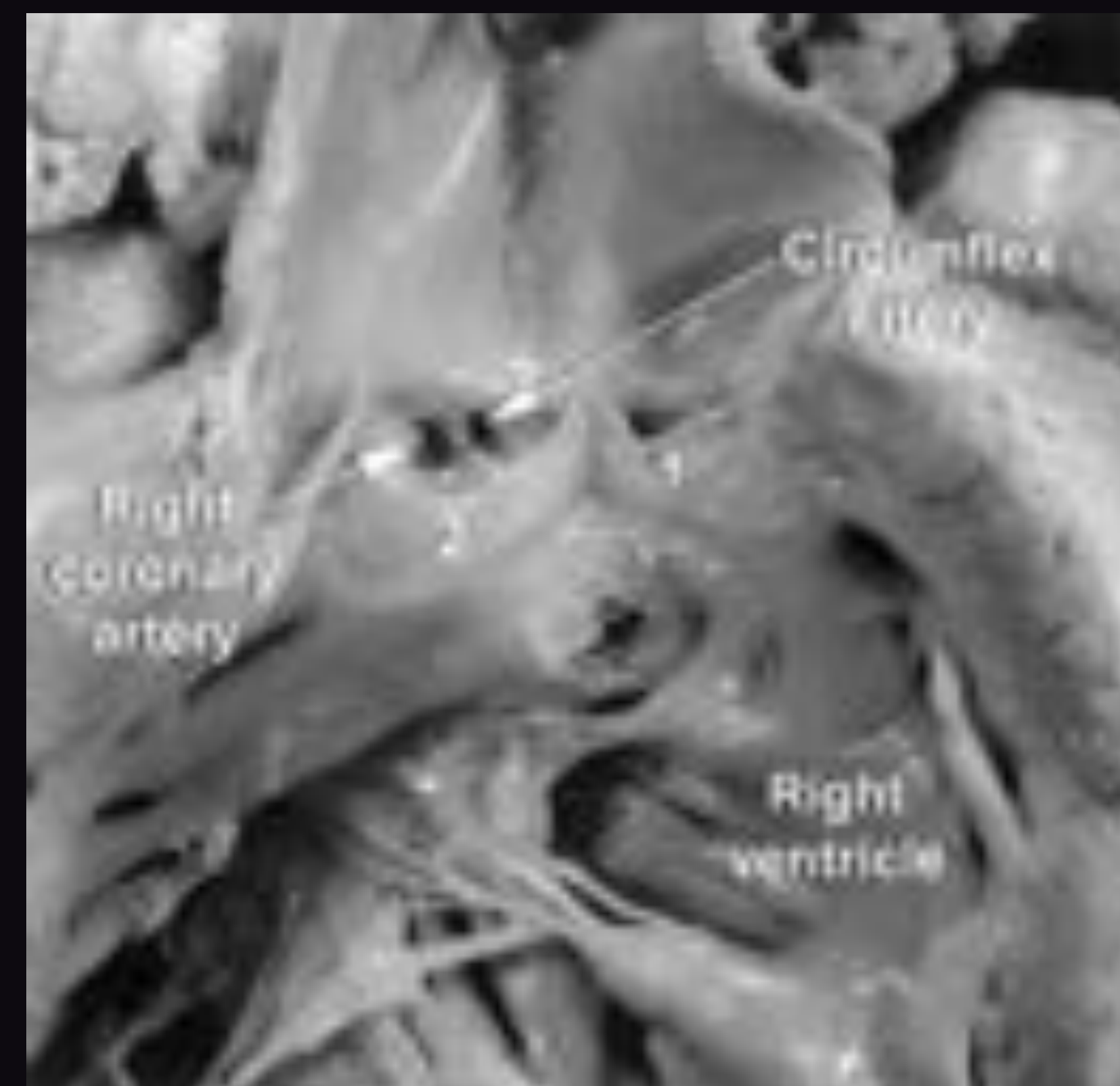
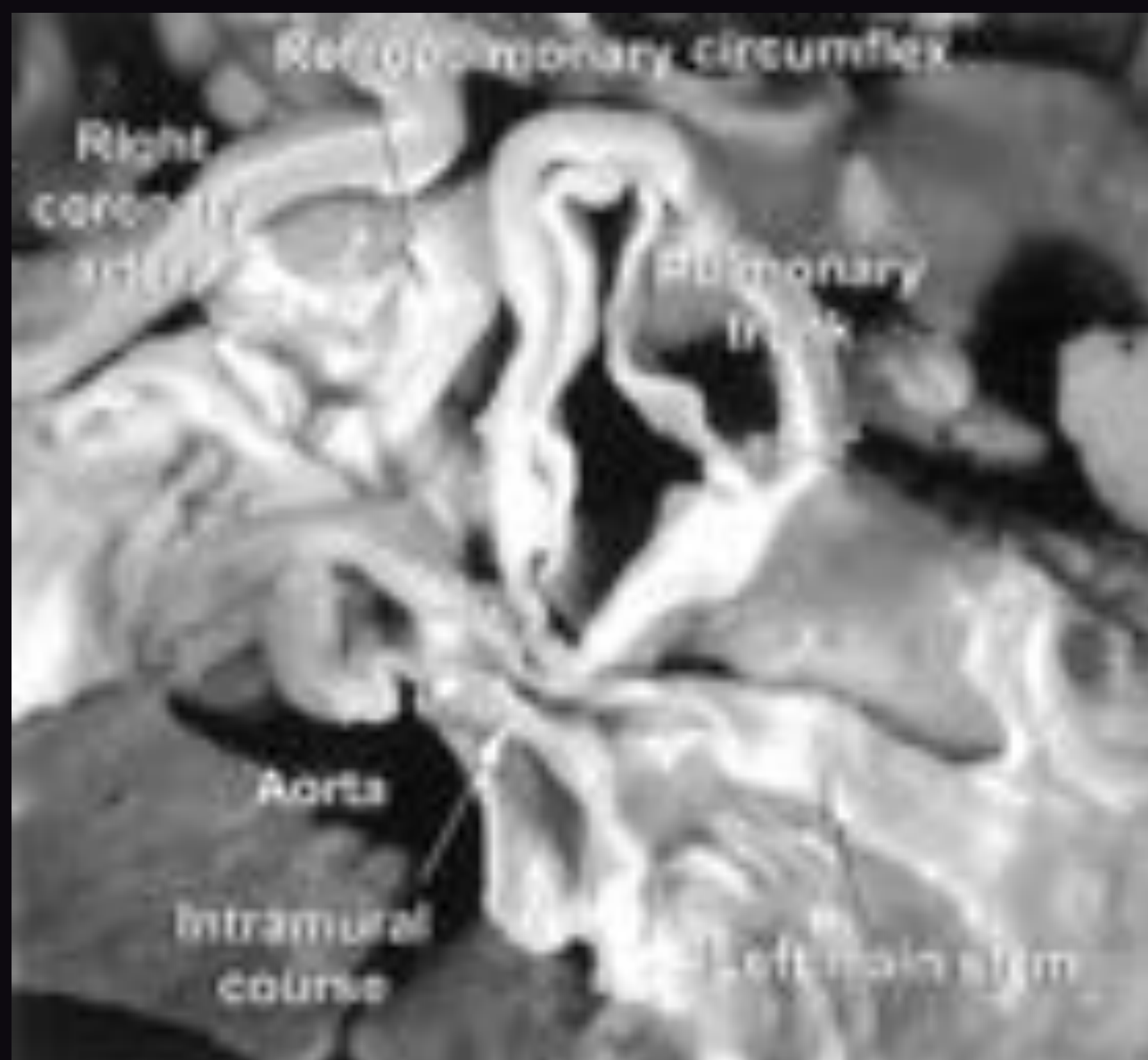
Intramural course



- Single ostium and intramural course increase the risk of postoperative death
- Postoperative mortality is increased in patients with abnormal coronary artery distribution (OR 1,7).





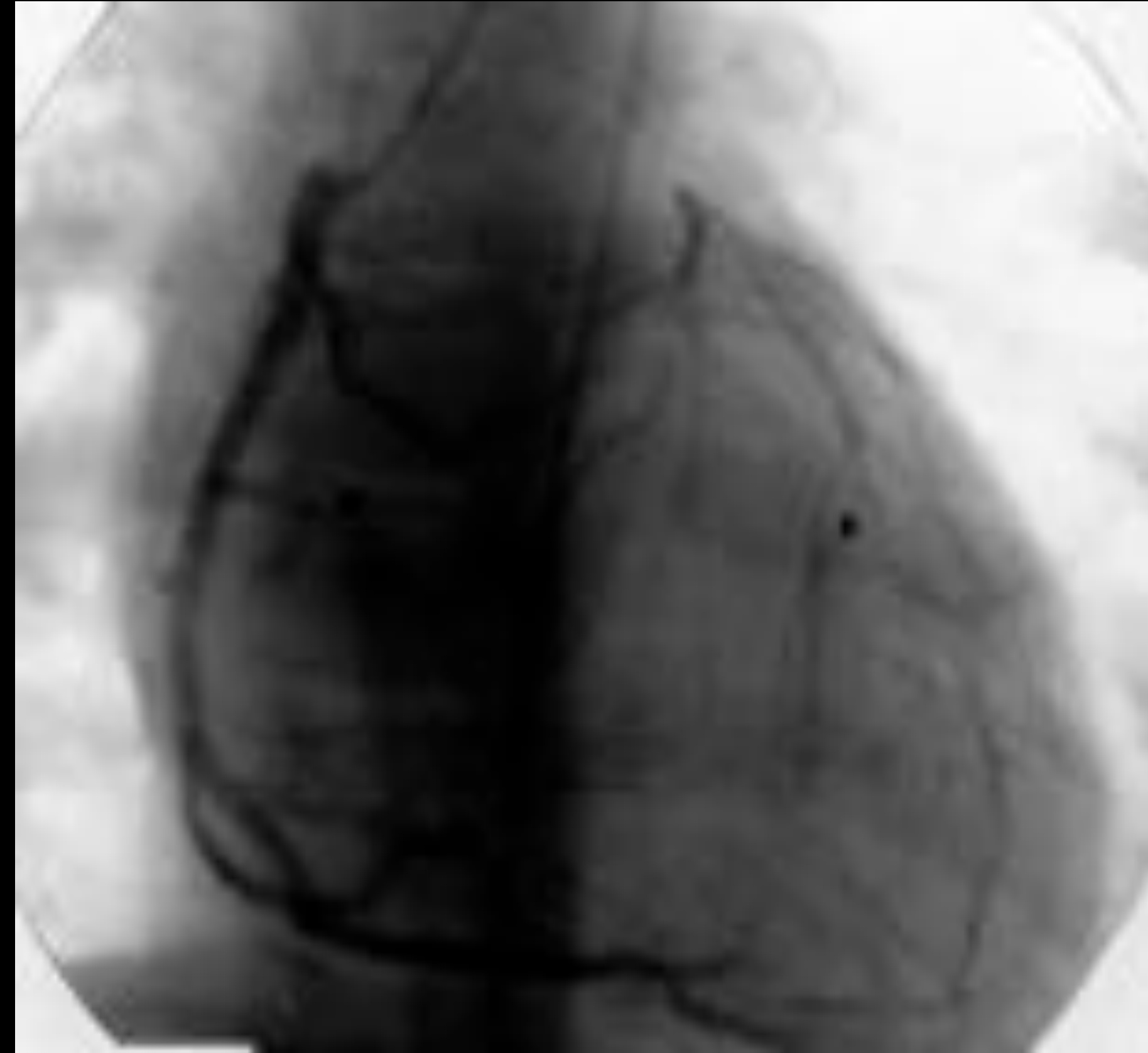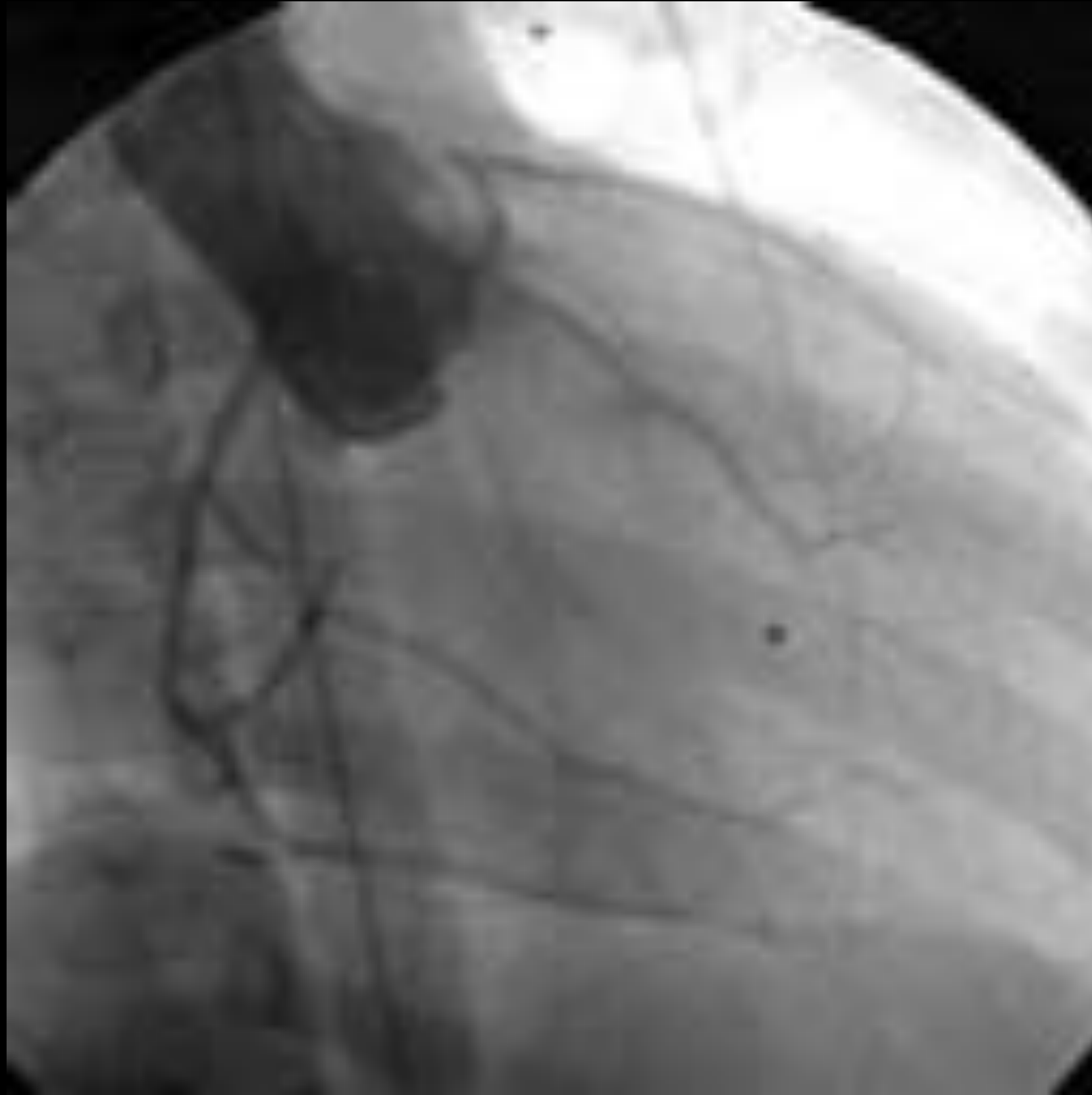
Late coronary artery anomalies after ASO

- Minor distortion during transfer ? : endothelium, intimal proliferation, ...
- Evolution : compression, stretching
- Outcome
 - Sudden death and myocardial infarction
 - Before 6 months of age
 - Asymptomatic myocardial ischemia
 - Balance between intimal proliferation and development of collateral circulation
 - Coronary occlusion without ischemia

Indications to control CA after ASO

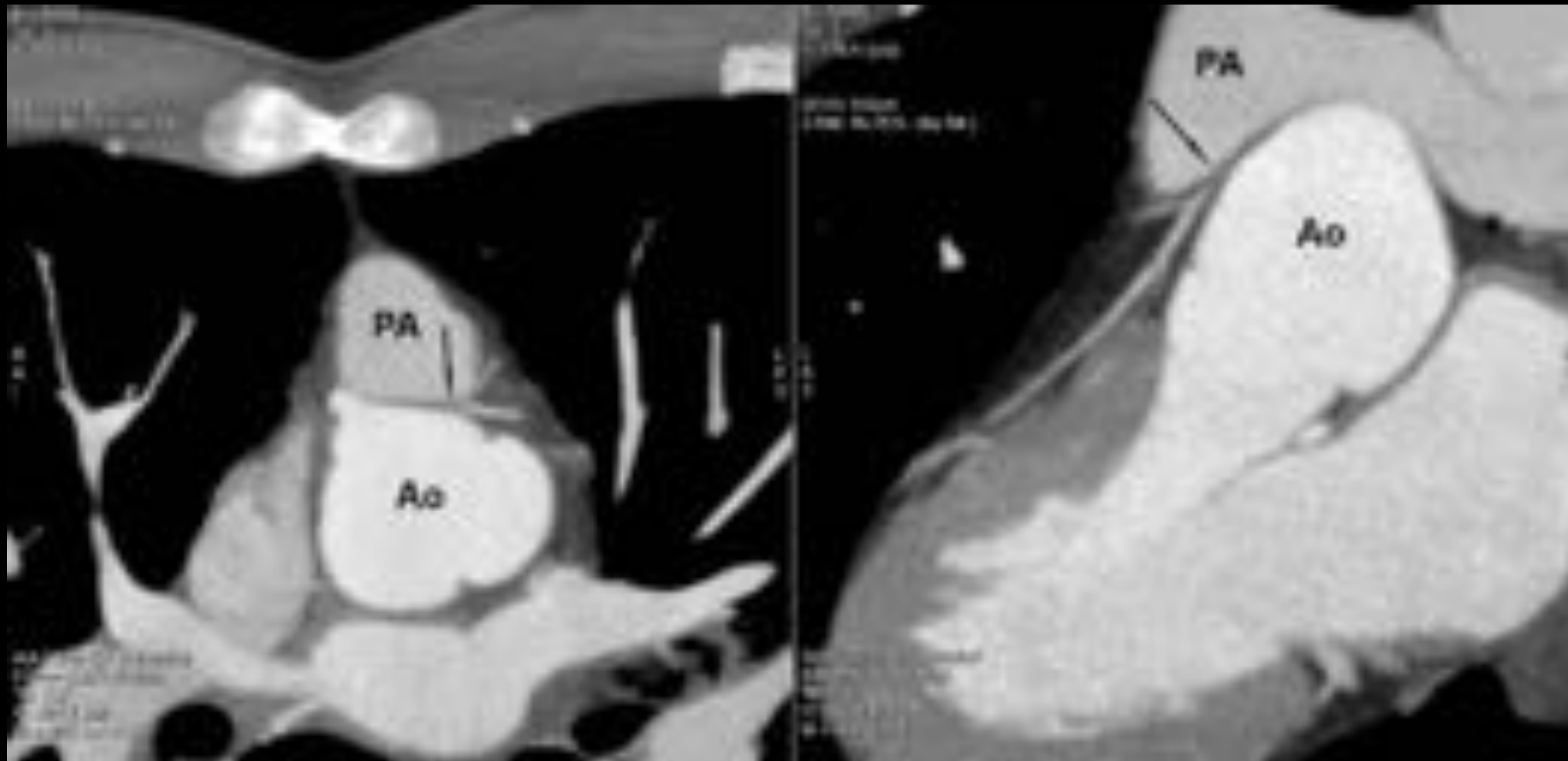
- Any time in case of patent myocardial ischemia
- Systematic screening in school age children
- What has to be detected?
 - CA obstruction : imaging
 - Prevalence vs risk of diagnostic procedure
 - Myocardial ischemia : function
 - Negative predictive value ? (>50% false negative)
 - Positive predictive value OK (few false positive)

Late coronary artery anomalies after ASO



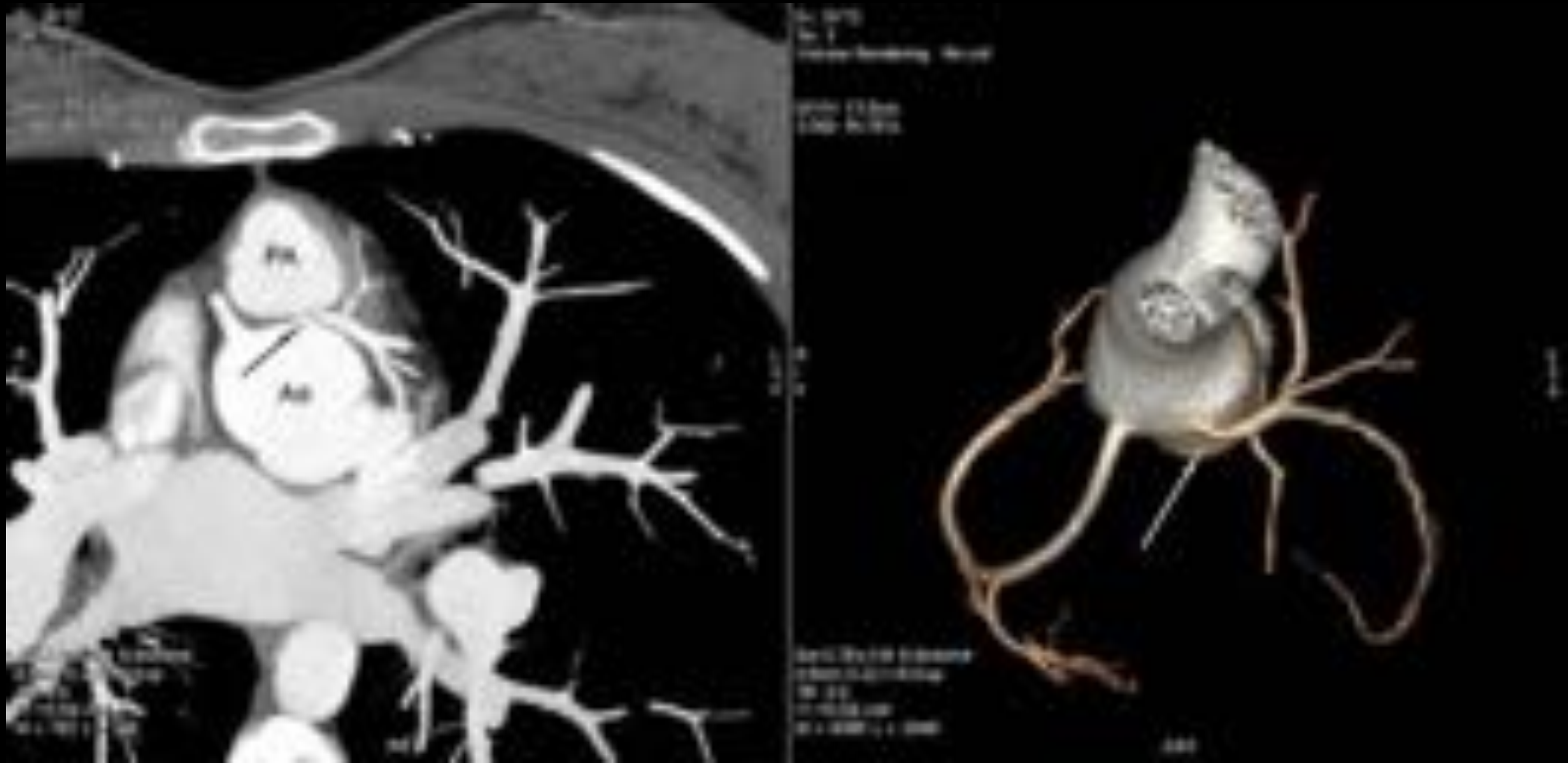64-slice CT after arterial switch operation for TGA

Intramural left main CA



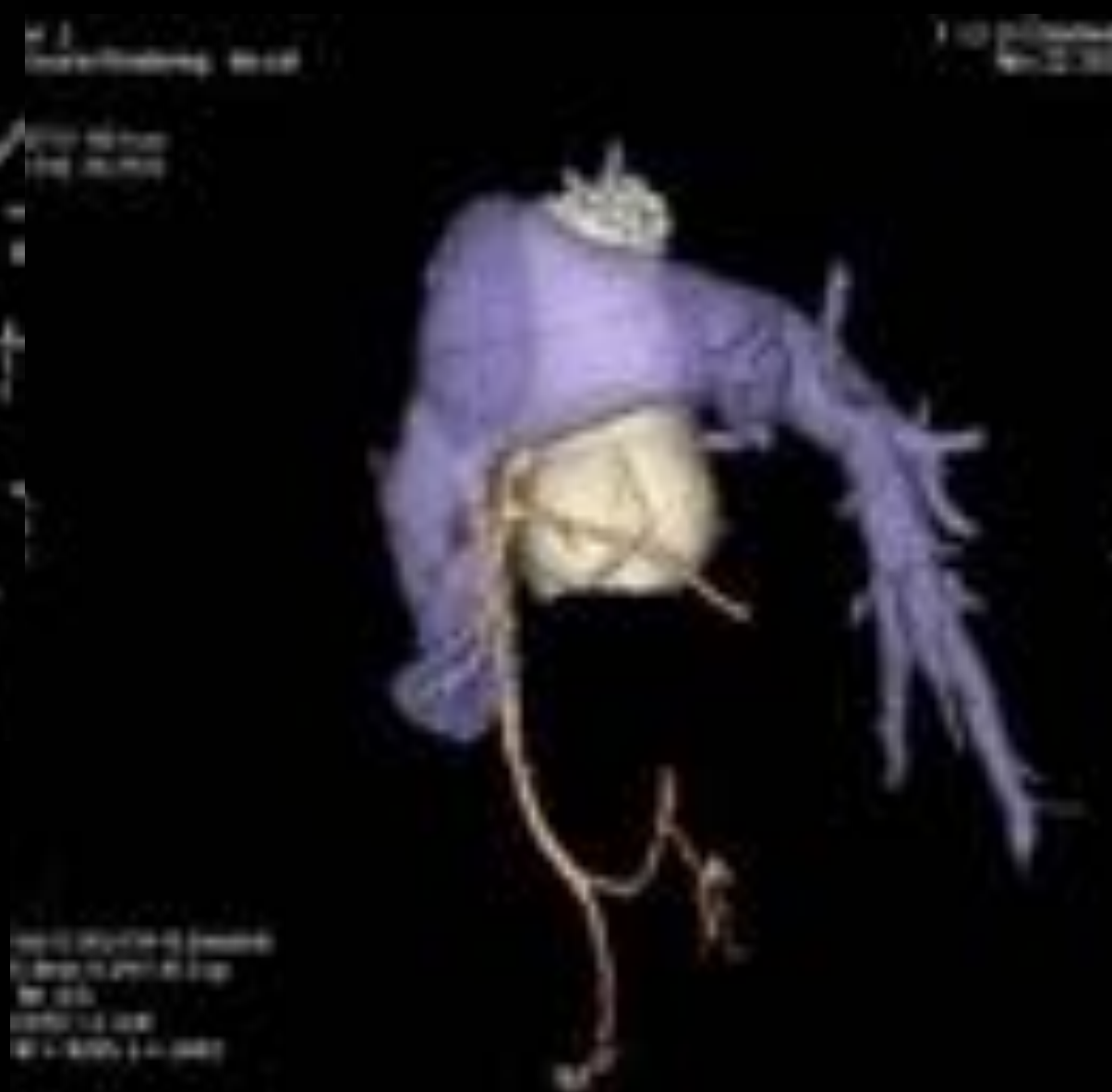
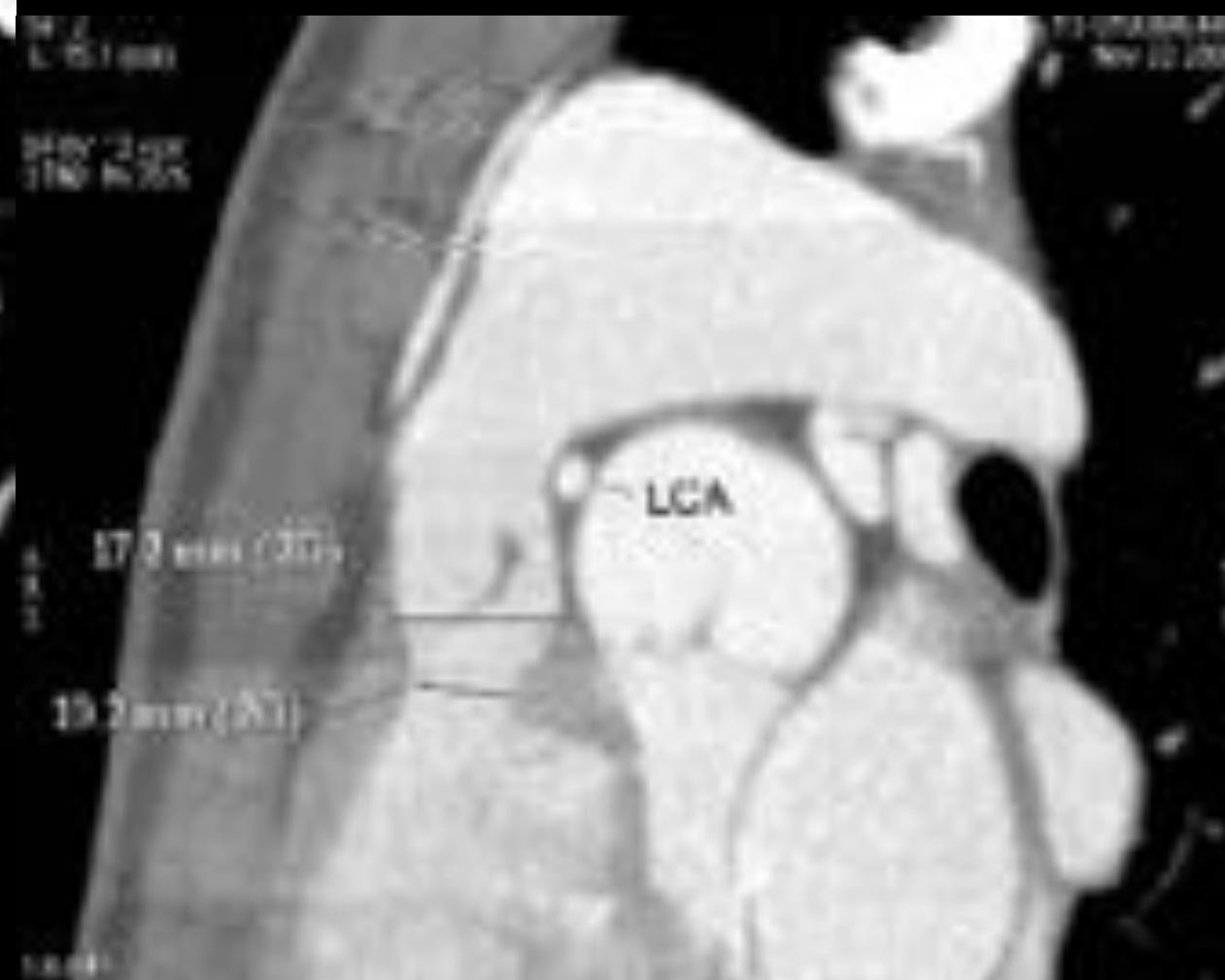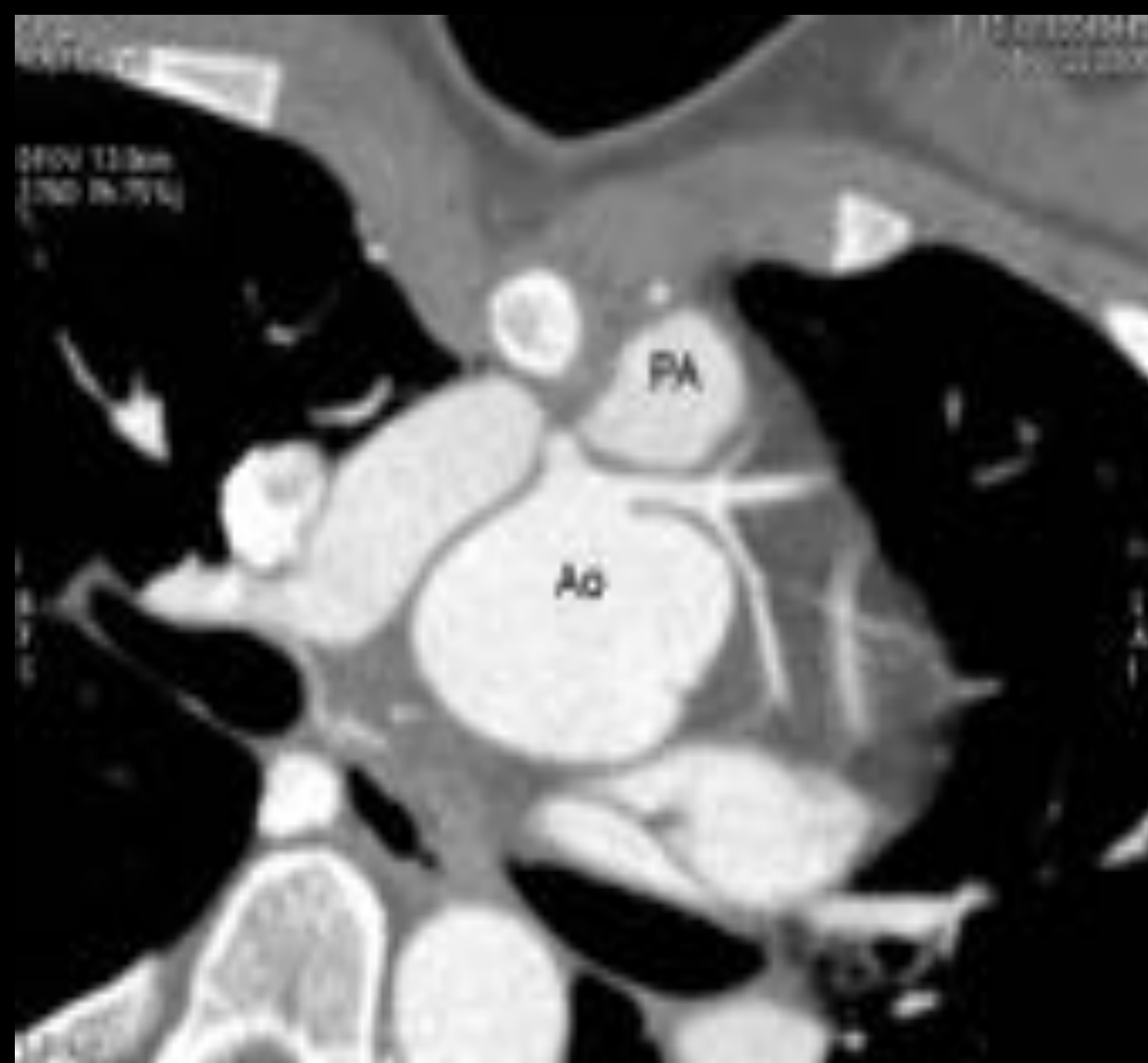
64-slice CT after arterial switch operation for TGA

LMCA stenosis



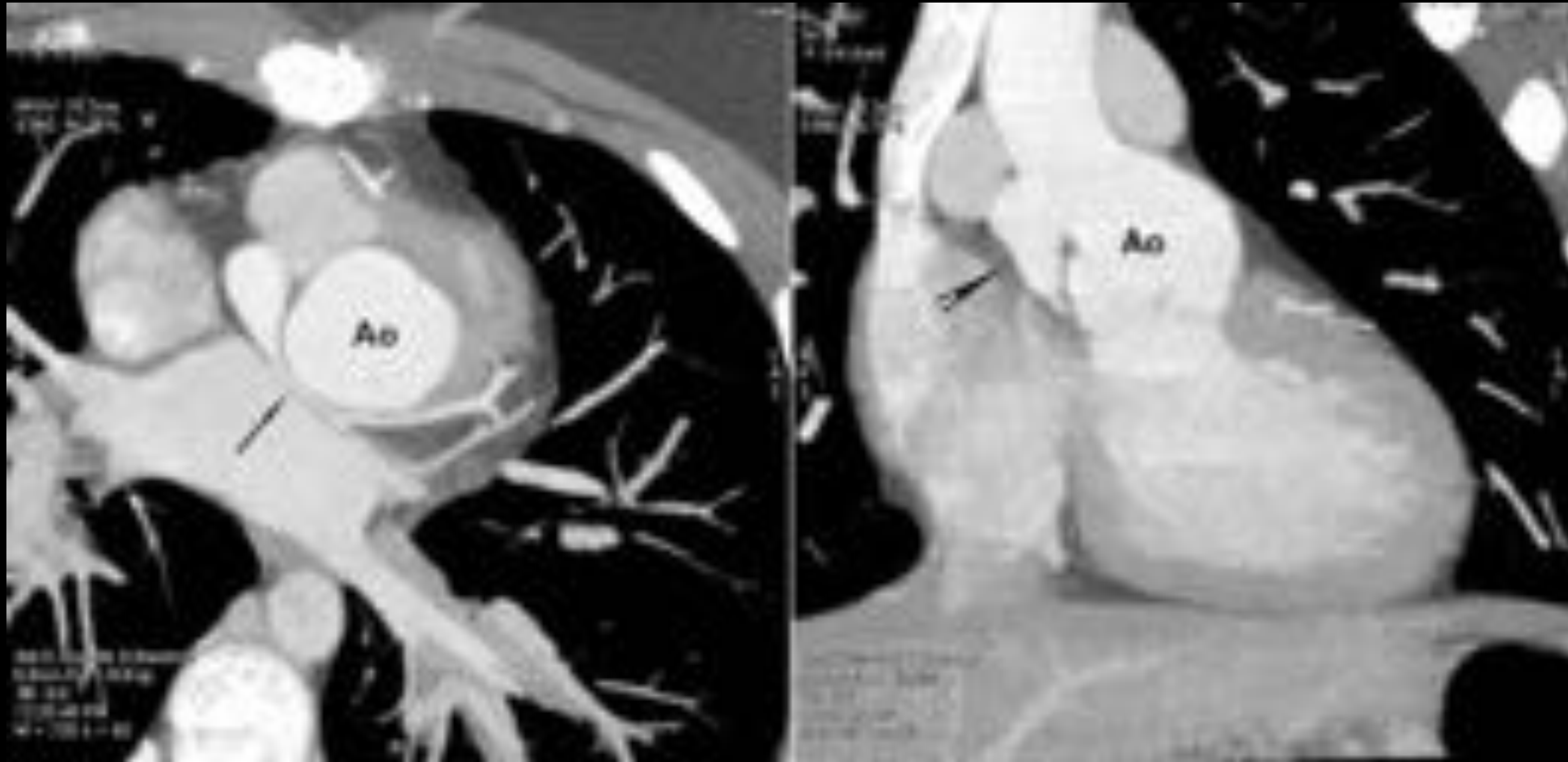64-slice CT after arterial switch operation for TGA

Abnormal course



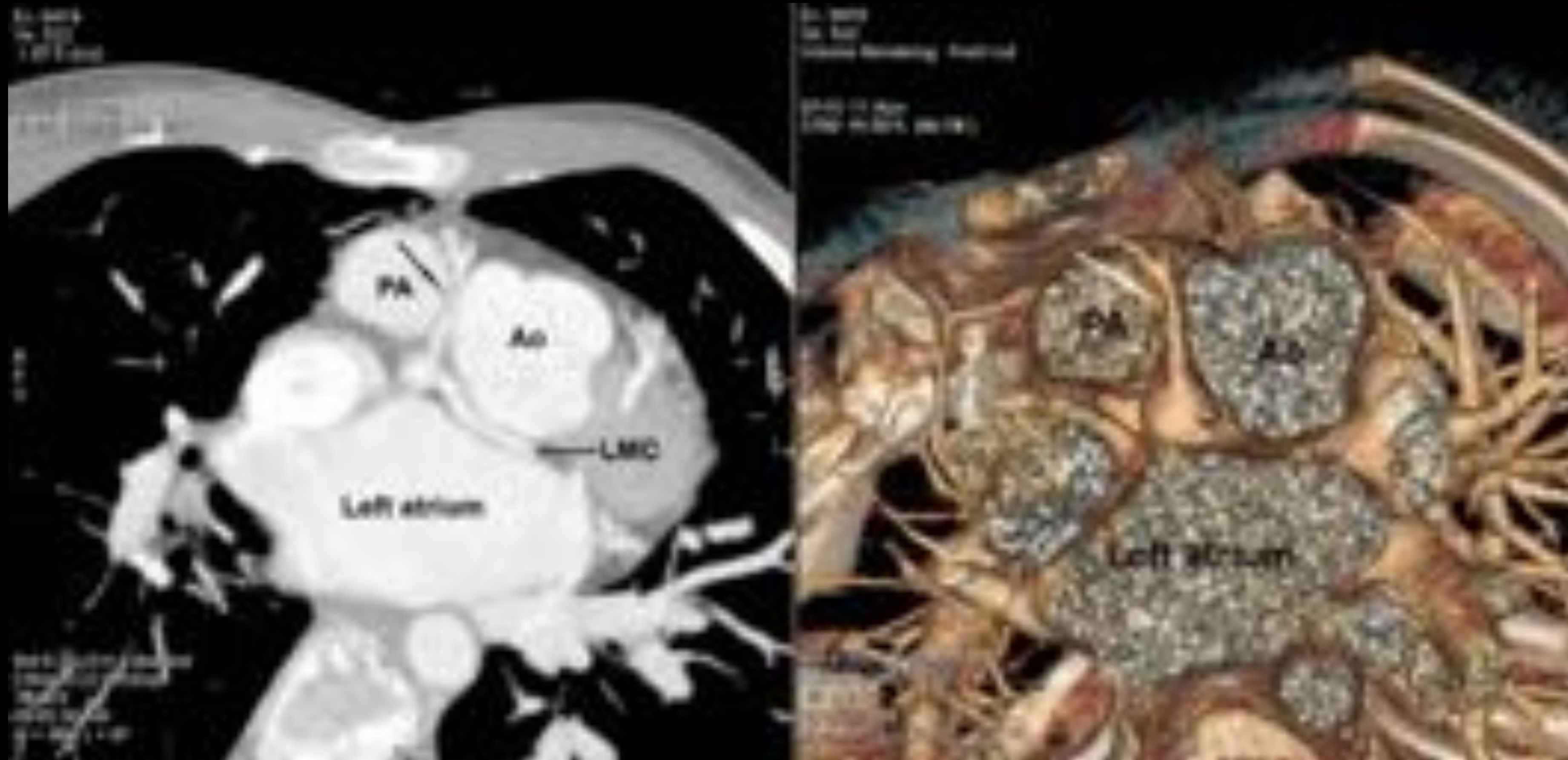
64-slice CT after arterial switch operation for TGA

LMCA retro-aortic course



64-slice CT after arterial switch operation for TGA

RCA compression



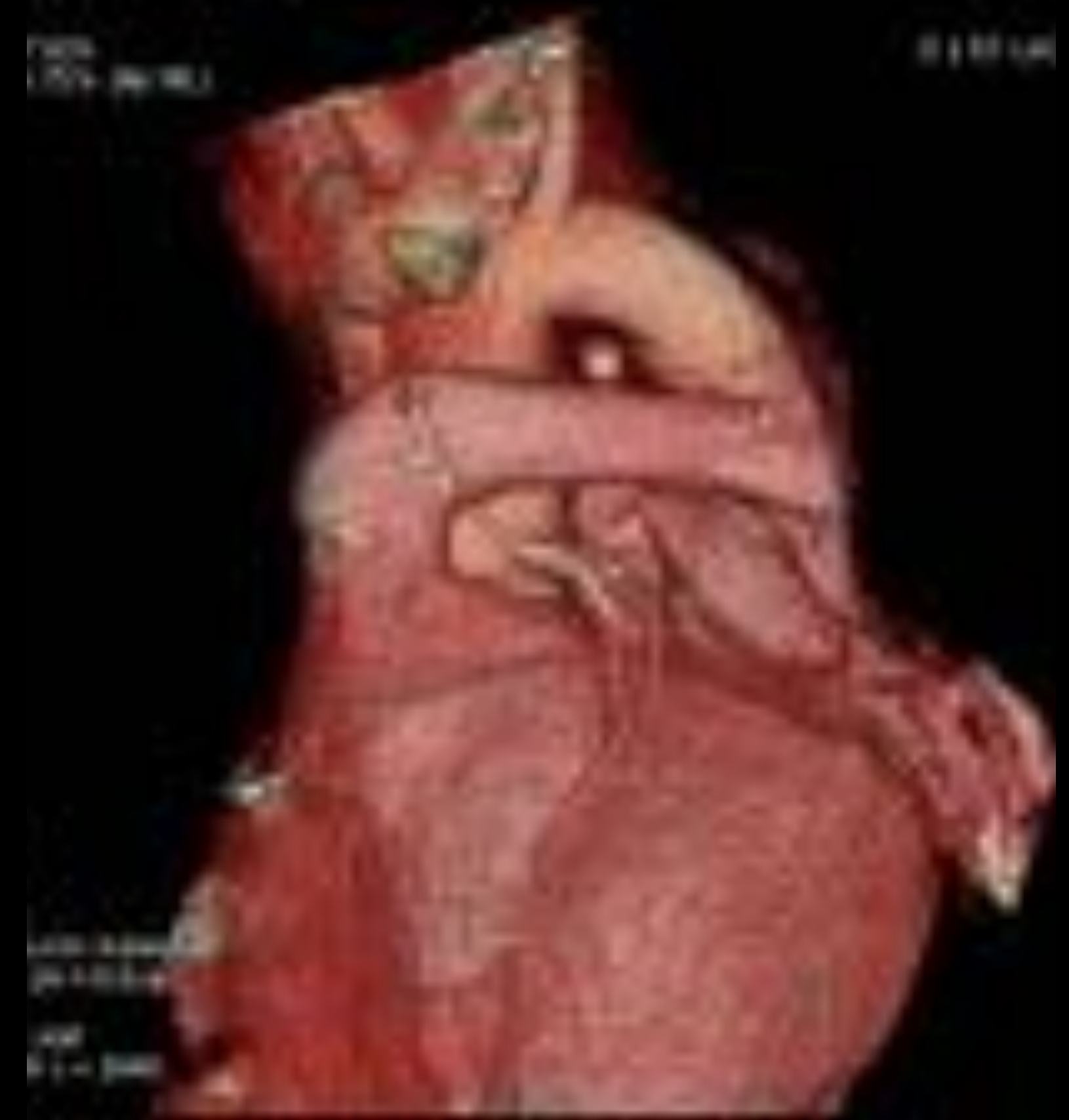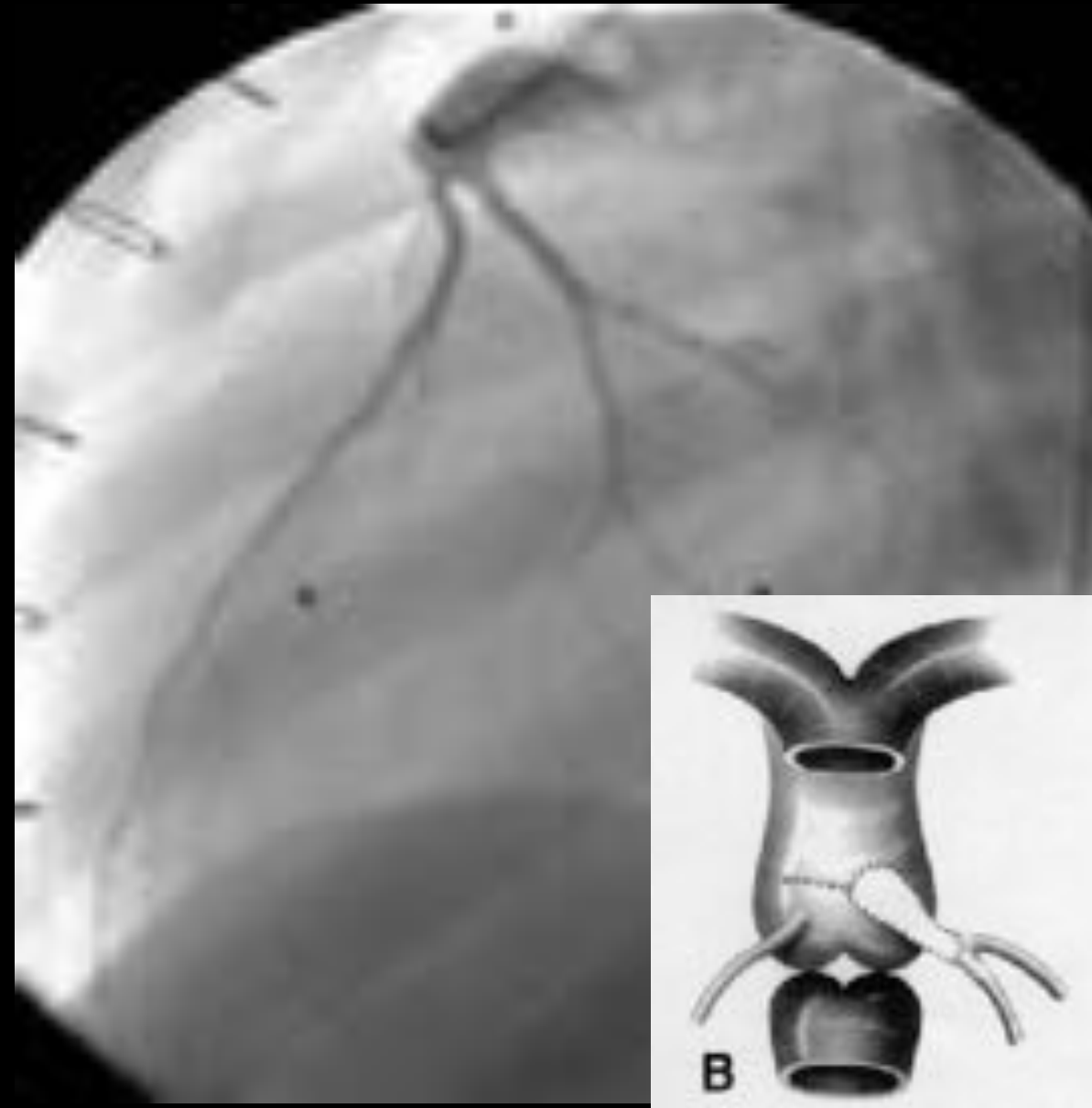
How to treat CA obstructions ?

CA surgical angioplasty

Raisky et al. Eur J Cardiothorac Surg 2007;31:895-9

PTCA

Kampmann et al. Ann Thorac Surg 2005;80:1641-6



Conclusion

- Wide variety of CA anomalies
- Recent advances in non invasive imaging in children
- New insights in the mechanisms of post-ASO coronary obstruction
- Still a surgical challenge in CHD

Thank you



Collective ignorance is the motivation
Curiosity is the strength
Research is the path

Individual experience is the brake
Indifference is the weakness
Authority argument is the threat