

Cite this article as: Moreau de Bellaing A, Mathiron A, Lecompte Y, Vouhé P. Mitral valve replacement with a pulmonary autograft: long-term follow-up in an infant. *Interact CardioVasc Thorac Surg* 2018; doi:10.1093/icvts/ivy322.

## Mitral valve replacement with a pulmonary autograft: long-term follow-up in an infant

Anne Moreau de Bellaing<sup>a,\*</sup>, Amel Mathiron<sup>b</sup>, Yves Lecompte<sup>a</sup> and Pascal Vouhé<sup>a</sup>

<sup>a</sup> M3C National Reference Center, Department of Pediatric Cardiology, Hôpital Necker-Enfants Malades, APHP, Université Paris Descartes, Paris, France

<sup>b</sup> Pediatric Cardiology Department, CHU Amiens-Picardie, Amiens, France

\* Corresponding author. Department of Pediatric Cardiology, Hôpital Universitaire Necker-Enfants Malades, 149 Rue de Sèvres, 75015 Paris, France. Tel: +33-6-13471532; fax: +33-1-44494340; e-mail: annemdb@aol.com (A. Moreau de Bellaing).

Received 4 August 2018; received in revised form 17 October 2018; accepted 28 October 2018

### Abstract

A 7-month-old boy with a complete atrioventricular septal defect presented with severe left atrioventricular valve regurgitation 4 months after complete repair. As the valve was unsuitable for the repair and the annulus was too small to accommodate a mechanical prosthesis, the modified mitral Ross operation was performed. The long-term outcome was uneventful for 12 years. The mitral Ross procedure is an old-described technique in which classically the pulmonary autograft is encased in a prosthetic conduit preventing any growth potential. On the contrary, the modified technique used in this case shows that the long-term function can be obtained. This procedure may be a valuable option when mitral valve replacement is necessary in infants.

**Keywords:** Mitral valve replacement • Mitral Ross • Ross II • Pulmonary autograft • Infant surgery • Congenital mitral defect

### INTRODUCTION

A 7-month-old baby was referred for massive left atrioventricular valve (LAV) regurgitation 4 months after an atrioventricular septal defect repair. As the patient's clinical conditions did not improve with medication, a surgical correction was indicated. Since the beginning of the operation, the repair of the valve was deemed impossible because of lack of the valvar tissue and severe malformation of the chordae. The LAV annulus was too small to accommodate the smallest mechanical valve, and the left atrium was not dilated enough to allow supra-annular implantation. We decided to use the modified 'top hat' mitral Ross procedure [Ross 2]. The pulmonary autograft was harvested. A cuff of the glutaraldehyde-treated autologous pericardium was sewn onto the proximal (infundibular) end of the autograft. The distal (pulmonary) end of the autograft was secured to the mitral annulus, whereas the native mitral apparatus was conserved to preserve the left ventricular function. At the level of the left atrial free wall, the pericardial cuff was progressively tailored and sewn onto the atrial wall to remain away from the ostia of the pulmonary veins and to maintain normal morphology of the autograft. At the level of the atrial septum, the autograft itself was used to close the ostium primum defect avoiding distortion of the autograft. There was no complication during the postoperative period. The echocardiography showed normal functioning of the autograft.

The course of the child was uneventful for more than 11 years. However, mitral stenosis and regurgitation progressively developed without significant pulmonary hypertension (Fig. 1).

Reoperation was performed at the age of 11.75 years. The autograft was severely degenerated but not calcified; this and the native, still identifiable LAV were resected. A 21 mm-mechanical prosthesis was implanted in the supra-annular position. The pulmonary heterograft was removed as well. Four years later, the patient's clinical conditions continue to be excellent.

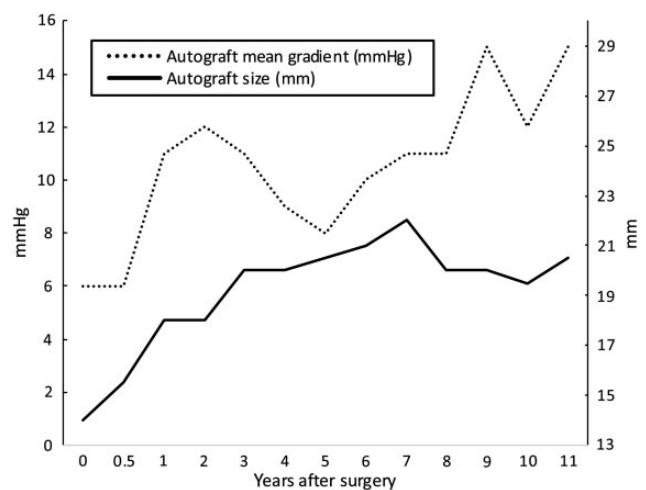
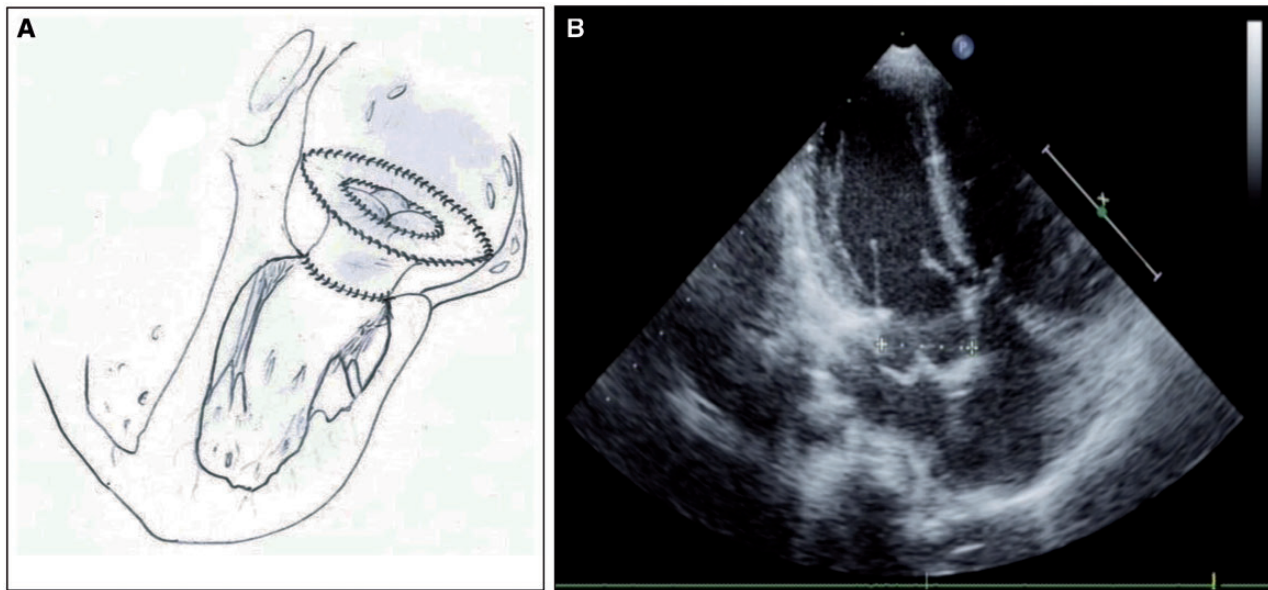


Figure 1: Echocardiographic follow-up after the Ross II procedure.



**Figure 2:** (A) The modified Ross II procedure using the pericardial cuff but without prosthetic support. (B) Postoperative echocardiography showing the atrial insertion of the autograft and the location recorded for the size graft follow-up (+.....+).

## COMMENTS

Whatever the mitral valve defect requiring surgery during childhood, conservative procedures should remain the first choice since they are the most compatible with regular child growth. Otherwise, when mitral valve repairs fail or are not technically feasible, surgical options for replacing the mitral valve in children are limited. Because mechanical mitral valve replacement (MVR) was challenging for infants or in developing countries, Ross and Kabbani [1] updated, in 1997, the procedure using the autologous pulmonary valve as an inverted autograft. This avoids anticoagulation treatment and size mismatch between the prosthesis and the LAV annulus.

The long-term course of 92 patients, all older than 4 years, was reported with good results in terms of freedom from degeneration, reoperation and death [2]. In a review of the literature, Athanasiou *et al.* [3] reported similar results, again without including infants. So far, there is only 1 medium-term follow-up reported in an 11-month-old infant [4]. An MVR was required 7 years after the Ross II procedure.

The conventional technique involves the implantation of the pulmonary autograft into a prosthetic conduit [1]. The latter reinforces the external wall of the autograft avoiding longitudinal deformation or constriction, but it prevents any growth potential of the valve. Slit opening of the prosthetic conduit, along 1 or both of its sides, as suggested by Kabbani *et al.* [2], has not been shown to solve the growth issue.

We used a technical modification without prosthetic support. Recently, Jeong and Yun [5] reported a similar procedure, but the long-term follow-up of their patient is still unknown. The autologous pericardial cuff allowed to secure the valve on the left atrial

free wall and the interatrial septum (Fig. 2). Precise tailoring and suturing of the cuff are of utmost importance to avoid any distortion and dysfunction of the autograft.

## CONCLUSION

In conclusion, we report the favourable long-term follow-up of a child having undergone MVR using a pulmonary graft without a prosthetic material. In case of irreparable congenital mitral malformation, this procedure could be an alternative substitute, especially for infants in whom mechanical MVR remains a concern. Further experience is obviously necessary before recommending its widespread use. However, this alternative should be kept in mind when the MVR is required in infants.

**Conflict of interest:** none declared.

## REFERENCES

- [1] Ross DN, Kabbani S. Mitral valve replacement with a pulmonary autograft: the mitral top hat. *J Heart Valve Dis* 1997;6:542-5.
- [2] Kabbani S, Jamil H, Nabhani F, Hamoud A, Katan K, Sabbagh N *et al.* Analysis of 92 mitral pulmonary autograft replacement (Ross II) operations. *J Thorac Cardiovasc Surg* 2007;134:902-8.
- [3] Athanasiou T, Cherian A, Ross D. The Ross II procedure: pulmonary autograft in the mitral position. *Ann Thorac Surg* 2004;78:1489-95.
- [4] Kanzaki T, Yamagishi M, Yashima M, Yaku H. Seven-year outcome of pulmonary valve autograft replacement of the mitral valve in an infant. *J Thorac Cardiovasc Surg* 2011;141:e33-5.
- [5] Jeong YH, Yun T-J. Mitral valve replacement with a pulmonary autograft in an infant. *Korean J Thorac Cardiovasc Surg* 2018;51:149-52.